Med
A

269

ARCHIVES

OF

OPHTHALMOLOGY

EDITED IN ENGLISH AND GERMAN

BY

DR. H. KNAPP
OF NEW YORK

AND

DR. C. SCHWEIGGER
OF BERLIN

DR. F. E. D'OENCH
OF NEW YORK
ASSISTANT EDITOR

VOLUME XXI.

GENERAL INDEX TO VOLS. XV.–XXI.

403138
18.5.42

NEW YORK
G. P. PUTNAM'S SONS, 27 & 29 WEST 23D STREET
AND NEW ROCHELLE, N. Y.
LONDON: 24 BEDFORD STREET, STRAND
WIESBADEN: J. F. BERGMANN'S Verlag
PARIS: J. B. BAILLIÈRE, 19 Rue Hautefeuille
1892

RE
1
.A74
v.21

Copyright, 1892
by
G. P. Putnam's Sons

Printed, and Bound by
The Knickerbocker Press, New York
G. P. Putnam's Sons

CONTENTS OF VOLUME XXI.

NUMBER I.

PAGE

1. Observations on the Macula Lutea. By G. Lindsay Johnson, M.A., M.D., B.S., Cantab., F.R.C.S., London. (With 16 figures on the colored plates A–D.) 1

2. The Etiology of Inflammation of the Eye after Injury with Foreign Bodies. By Dr. Stanislawa Poplawska, Warsaw, Poland. Translated by Dr. Ward A. Holden, New York. (With plates vi., vii., and viii., figs. 1–10, of vol. xxii. German edition.) . . . 22

3. Anatomical Contribution to the Knowledge of the Development of Myopia. By Dr. Alexander Krotoschin, Berlin. Translated by J. H. Claiborne, M.D., New York. (With plate ix. of vol. xxii. German edition.) 33

4. Profound Affection of the Eyes in a Case of Pernicious Anæmia. By Elizabeth Sargent, M.D., San Francisco 39

5. Jequirity a Perfectly Safe Remedy. By Chas. E. Michel, M.D., St. Louis, Mo. 48

6. A Statistical Review of the Proportion and Cause of Blindness in Thirty-two Thousand Eyes Consecutively Treated in the Jefferson College Hospital. By Howard F. Hansell, M.D., and James H. Bell, M.D., Philadelphia 51

7. Objective Strabismometry. By Ernest E. Maddox, M.D., Edinburgh 56

8. Traumatic Panophthalmitis; Enucleation; Uncontrollable Hemorrhage; Death. By J. H. Thompson, M.D., Kansas City, Mo., 63

9. The Correlation of Cranial and Oculo-Bulbar Conformations. By C. M. Culver, M.A., M.D., Albany, N. Y. (With one drawing and one plate in the text.) 68

10. Europhen and Cantharidate of Soda in Ophthalmology. By Juan Santos Fernandez, M.D., Havana, Cuba 73

11. A Contribution to the Histology of Some of the Rarer Forms of Tumor of the Choroid. By Ward A. Holden, A.M., M.D., New York. (With five figures in the text.) 76

PAGE

12. Two Cases of Papilloma of the Conjunctiva Encroaching upon the Cornea. By Dr. F. H. Sims, of Mobile, Ala. 91

13. Optic Neuritis after Measles and Intermittent Fever. By Hiram Woods, M.D., Baltimore, Md. 95

14. Report of a Case in Which there is Binocular Absence of the Choroid, Showing a Rich Plexus of Cilio-Retinal Vessels Supplying the Region of the Yellow Spot in Both Eyes. By Warwick M. Cowgill, M.D., Paducah, Ky. (With two drawings.) . 105

15. Temporary Hypermetropic Astigmatism Following an Attack of Measles. By F. W. Marlow, M.D., M.R.C.S., New York . 107

16. Living Larvæ in the Conjunctival Sac. By R. J. Phillips, M.D., Philadelphia. (With a drawing.) 110

17. How shall We Treat Trachoma To-day? By Dr. E. Jaesche, Dorpat. Translated by Dr. Ward A. Holden, New York . . 113

18. Remarks on the Treatment of Trachoma by the Expression of the Morbid Substance with a Roller Forceps, based on a Series of 114 Successive Cases. By H. Knapp. (With one woodcut.) . . 119

19. Systematic Report on the Progress of Ophthalmology during the First Quarter of the Year 1891. By St. Bernheimer, Heidelberg; C. Horstmann, and P. Silex, Berlin. With the Co-operation of S. M. Burnett, Washington; Dantone, Rome; Hirschmann, Charkow; E. Marckwort, Antwerp; P. v. Mittelstädt, Metz; L. Werner, Dublin; C. H. A. Westhoff, Amsterdam; Schiötz and Ole Bull, Christiania, and Deus, Berlin. Translated by Dr. F. E. D'Oench, New York 128

A.—Dr. St. Bernheimer. Text-books, monographs, treatises on general, bibliographical, and historical subjects, 128; General pathology, diagnosis, and therapeutics, 130; Anatomy, 131; Physiology, 134.

B.—Dr. Horstmann. Anomalies of refraction and accommodation, 135; Lids, 137; Lachrymal apparatus, 140; Muscles and nerves, 142; Orbit and neighboring cavities, 144; Conjunctiva, cornea, sclera, anterior chamber, 148.

C.—Dr. P. Silex. Iris, 153; Choroid, 154; Glaucoma, 155; Sympathetic ophthalmia, 155; Vitreous, 155; Lens, 156; Retina and functional disturbances, 157; Optic nerve, 161; Injuries, foreign bodies (parasites), 161; Ocular affections in constitutional diseases, 162.

20. Miscellaneous Notes 169

A.—Reviews.
B.—News.—A New Eye and Ear Hospital (With a plate in the text) . . 168

NUMBER 2.

1. Further Experiments on the Lymph-Streams and Lymph-Channels of the Eye. By H. Gifford, Omaha, Neb. (With plate) . . 171

2. Binocular Metamorphopsia Produced by Correcting Glasses. By Harry Friedenwald, A.B., M.D., Baltimore. 204

3. An Iris Shield—A New Cataract Instrument. By Charles W. Dodd, M.D., Cincinnati. (With a woodcut) 213

PAGE

4. On Vaccine Blepharitis. By Charles Zimmerman, M.D., Milwaukee, Wis. 215

5. Idiopathic Vitreous Hemorrhages. By Dr. James A. Spalding, Portland, Me. 220

6. Retention Cyst of the Conjunctiva of Traumatic Origin. By Dr. Enrique Lopez, Habana. Translated by Dr. C. E. Finlay. . 231

7. Some Squint Statistics. By H. H. Seabrook, M.D., New York. . 234

8. Contributions to Clinical Ophthalmology · being Gleanings from my Case-Books. By Swan M. Burnett, M.D., Ph.D., Washington, D.C. (With eight illustrations) 248

CASE I.—Retro-bulbar neuritis, without discoverable cause; marked shot-silk retina; central scotoma for red; peculiar visual fields. CASE II.—Cyst of the iris. CASE III.—Loss of eye in early life from inflammation (traumatic); sympathetic irido-choroiditis many years after; enucleation of the atrophic ball; relief to the irido-choroiditis; formation of bone in the vitreous or retina, springing from the optic disc. CASE IV.—Total dislocation of the lens under the conjunctiva to the nasal side from a blow; removal; preservation of the eyeball. CASE V.—A case of partial dislocation of the lens under the conjunctiva upward. CASE VI.—Successful extraction of a floating degenerated lens from the vitreous chamber. CASE VII.—Chemosis of the conjunctiva and lid caused by the ingestion of a single grain of quinine. CASE VIII.—Periodic congestion of the conjunctiva from vaso-motor disturbance. CASE IX.—Wrinkling of the cornea.

9. On Congenital Coloboma of the Optic Nerve. By Prof. W. Manz, Freiburg, Baden. Translated by Dr. Ward A. Holden, New York. (With Figures 1–4, Plate I. II., and Figure c, Plate III.) 263

10. Detachment of the Choroid. By Dr. Anton Elschnig, Gratz. Translated and abridged by Dr. J. A. Spalding, Portland, Me. (With Fig. 5, Plate I. II.) 272

11. A Case of Sarcoma of the Cornea. By Dr. Konrad Rumschewitsch, Kiew. Translated by Dr. Ward A. Holden, New York. (With Figure 6, Plate I. II.) 277

12. On Pigment Striæ with Secondary Changes in the Retina after Hemorrhage. By Dr. O. Plange, Münster. Translated by Dr. Ward A. Holden, New York. (With Figs. a and b, Plate III.) 282

13. On the Formation of Dark Angioid Streaks as an Unusual Metamorphosis of Retinal Hemorrhage. By H. Knapp. (With an ophthalmoscopic drawing) 289

14. On Glaucoma after Discission of Secondary Cataract and its Successful Treatment by Iridectomy. By H. Knapp . . 293

15. An Extreme Cylindrical Effect from a Tilted Spherical Lens. By E. L. Jones, M.D., Florence, Ala. 301

16. Systematic Report on the Progress of Ophthalmology during the Second Quarter of the Year 1891. By St. Bernheimer, Heidelberg; C. Horstmann and P. Silex, Berlin. With the co-operation of S. M. Burnett, Washington; Dantone, Rome; Hirschmann, Charkow; E. Marckwort, Antwerp; P. v. Mittelstädt, Metz;

PAGE

L. Werner, Dublin; C. H. A. Westhoff, Amsterdam; Schiötz and Ole Bull, Christiania, and Deus, Berlin. Translated by Dr. F. E. D'Oench, New York 316

A.—Dr. St. Bernheimer. Text-books, monographs, treatises on general, bibliographical, and historical subjects, 303; General pathology, diagnosis, and therapeutics, 304; Instruments and remedies, 305; Anatomy, 307; Physiology, 308.

B.—Dr. C. Horstmann. Anomalies of refraction and accommodation, 309; Lids, 311; Lachrymal apparatus, 313; Muscles and nerves, 314; Orbit and neighboring cavities, 317; Conjunctiva, cornea, sclera, anterior chamber, 317.

C.—Dr. P. Silex. Iris, 320; Choroid, 320; Glaucoma, 322; Sympathetic ophthalmia, 323; Vitreous, 323; Lens, 324. (Concluded in next number.)

17. Book Review 326

Festschrift zur Feier des Siebenzigsten Geburtstages von Hermann von Helmholtz. Stuttgart, 1891. Published by the German Ophthalmological Society. Reviewed by Dr. S. M. Burnett.

18. Obituary 330

I. Sir Wm. Bowman, Bart., F.R.S.
II. Hasner von Artha.

NUMBER 3.

1. Does Javal's Ophthalmometer Render the Use of Atropine Unnecessary. By G. Melville Black, M.D., Denver, Colo. . . 333

2. Optic Nerve Atrophy in a Child, following a Fall on the Head, with Severe Cerebral Symptoms. By S. Kohn, M.D., New York, 339

3. On Synergetic Ocular Movements. By Dr. O. Bull, Christiania, Norway 342

4. The Removal of a Tumor of the Optic Nerve with Preservation of the Eye. By the late Dr. Geo. S. Norton. Reported by A. B. Norton, M.D., New York. (With one woodcut) . . . 354

5. Unusual Family History in Two Cases of Glaucoma. By W. B. Pusey, M.D., Louisville, Ky. 358

6. Another Case of Synchronous Movements of the Upper Lid and Lower Jaw. By Dr. O. Bull, Christiania, Norway . . . 360

7. Attempt to Remove a Chip of Steel from the Background of the Eye Unsuccessful through an Accident which might have been Avoided. By H. Knapp 362

8. A Case of Reflex Micropsia upon Posterior Hypertrophy of the Inferior Turbinates. By John Dunn, M.D., Richmond, Va. . 365

9. A Valuable Experiment Bearing upon Sympathetic Ophthalmia with a Critical Review of the Subject. By Robert L. Randolph, M.D., 367

10. On the Pathology of Circumbulbar Dermoid Cysts. By Dr. J. Mitvalsky. Translated by Dr. Ward A. Holden. (With plates iv., v., vi., and vii., of vol. xxiii. German edition.) . . . 376

PAGE

11. Fifty-four Cases of Cataract Extraction. By J. H. Woodward, M.D., Burlington, Vt. 398

12. Systematic Report on the Progress of Ophthalmology during the Second Quarter (conclusion), and during the Third and Fourth Quarters of the Year 1891. By P. Silex, Berlin; St. Bernheimer, Heidelberg; and C. Horstmann, Berlin. With the Co-operation of S. M. Burnett, Washington; Dantone, Rome; Deus, Berlin; Hirschmann, Charkow; E. Marckwort, Antwerp; P. v. Mittelstädt, Metz; L. Werner, Dublin; C. H. A. Westhoff, Amsterdam; Schiötz and Ole Bull, Christiania. Translated by Dr. Jas. A. Spalding, Portland, Me. 407

C.—Dr. P. Silex. Retina and functional disturbances, 407; Optic nerve, 410; Injuries, foreign bodies (parasites), 412; Affections of the eye in general diseases, 414.

A.—Dr. St. Bernheimer. General ophthalmological literature, 417; General pathology, diagnosis, and therapeutics, 418; Instruments and remedies, 419; Anatomy, 424; Physiology, 426.

B.—Dr. C. Horstmann. Anomalies of refraction and accommodation, 430; Lids, 434; Lachrymal apparatus, 435; Muscles and nerves, 438; Orbit and neighboring cavities, 441; Conjunctiva, cornea, sclera, anterior chamber, 444.

13. Book Reviews 453

Diseases of the Eye. A Handbook of Ophthalmic Practice for Students and Practitioners. By G. E. De Schweinitz, M.D.
The Diagnosis of Diseases of the Nervous System. By C. A. Herter, M.D.,

14. Miscellaneous Notes 455

NUMBER 4.

1. Penetrating Wounds of the Eyeball—Histological and Bacteriological Researches and Considerations Regarding the Pathogenesis of Sympathetic Ophthalmia. By C. E. Finlay, M.D., Habana, Cuba. (With six drawings, two in the text, and four on a plate at the end of the paper.) 457

2. Embolism of Arteria Centralis Retinæ. By Jno. M. Foster. (With two figures in the text.) 497

3. Microscopic Examination of a Case of Typical Inferior Coloboma of the Iris. By Ward A. Holden, M.D., New York. (With six figures—one in the text, and five on the accompanying plate.) . 499

4. A Remarkable Case of Pseudo-Trachoma. By Dr. Richard Greeff. Translated by Dr. Charles Zimmerman, Milwaukee. (With plate i., of vol. xxiv., Germ. ed.) 505

5. Sharp-Cut Ectasia at the Posterior Pole in High-Grade Myopia. By Dr. Leopold Weiss, Heidelberg. Translated by Dr. B. Alex. Randall, Philadelphia. (With five figures on plate viii. of vol. xxiii., Germ. ed., and one in the text.) 511

6. Remarks on Immature Cataract and the Best Method of Hastening Maturity. By Joseph A. White, A.M., M.D. 516

PAGE

7. A Case of Sarcoma of the Choroid and Ciliary Body. Clinical History, by David Webster, M.D.; Microscopical Examination, by Ward A. Holden, M.D. (With a figure in the text.) . . 528

8. A Case of Homonymous Superior Hemianopsia. By Dr. F. Boé, Paris 533

9. Five Cases of Kerato-Conus Treated with Galvano-Cautery. By H. Knapp. (With a drawing.) 540

10. Systematic Report on the Progress of Ophthalmology during the Third and Fourth Quarters of the Year 1891. By Dr. St. Bernheimer, Vienna; Prof. Dr. Horstmann, Berlin, and Dr. Silex, Berlin. With the co-operation of Dr. S. M. Burnett, Washington; Dr. Dantone, Rome; Prof. Dr. Hirschmann, Charkow; Dr. E. Marckwort, Antwerp; Dr. P. von Mittelstädt, Metz; Dr. Werner, Dublin; Dr. C. H. A. Westhoff, Amsterdam; Dr. Schiötz and Dr. Ole Bull, Christiania; and Dr. Deus, Berlin. Translated by Dr. Jas. A. Spalding, Portland, Me. 548

C.—Dr. P. Silex. Iris, 548; Choroid, 550; Glaucoma, 552; Sympathetic ophthalmia, 554; Vitreous, 556; Lens, 557; Retina and functional disturbances, 563; Optic nerve, 567; Injuries, foreign bodies (parasites), 570; Ocular disturbances in constitutional affections, 571.

11. Miscellaneous Notes 578

Obituary.
Errata.

12. Index 579

General Index 595

CONTENTS OF VOLUME XXI., NUMBER 1.

PAGE

1. Observations on the Macula Lutea. By G. Lindsay Johnson, M.A., M.D., B.S., Cantab., F.R.C.S., London. (With 16 figures on the colored plates A–D.) 1
2. The Etiology of Inflammation of the Eye after Injury with Foreign Bodies. By Dr. Stanislawa Poplawska, Warsaw, Poland. Translated by Dr. Ward A. Holden, New York. (With plates vi., vii., and viii., figs. 1–10, of vol. xxii. German edition.) . . . 22
3. Anatomical Contribution to the Knowledge of the Development of Myopia. By Dr. Alexander Krotoschin, Berlin. Translated by J. H. Claiborne, M.D., New York. (With plate ix. of vol. xxii. German edition.) 33
4. Profound Affection of the Eyes in a Case of Pernicious Anæmia. By Elizabeth Sargent, M.D., San Francisco 39
5. Jequirity a Perfectly Safe Remedy. By Chas. E. Michel, M.D., St. Louis, Mo. 48
6. A Statistical Review of the Proportion and Cause of Blindness in Thirty-two Thousand Eyes Consecutively Treated in the Jefferson College Hospital. By Howard F. Hansell, M.D., and James H. Bell, M.D., Philadelphia 51
7. Objective Strabismometry. By Ernest E. Maddox, M.D., Edinburgh 56
8. Traumatic Panophthalmitis; Enucleation; Uncontrollable Hemorrhage; Death. By J. H. Thompson, M.D., Kansas City, Mo., 63
9. The Correlation of Cranial and Oculo-Bulbar Conformations. By C. M. Culver, M.A., M.D., Albany, N. Y. (With one drawing and one plate in the text.) 68
10. Europhen and Cantharidate of Soda in Ophthalmology. By Juan Santos Fernandez, M.D., Havana, Cuba 73
11. A Contribution to the Histology of Some of the Rarer Forms of Tumor of the Choroid. By Ward A. Holden, A.M., M.D., New York. (With five figures in the text.) 76
12. Two Cases of Papilloma of the Conjunctiva Encroaching upon the Cornea. By Dr. F. H. Sims, of Mobile, Ala. 91

PAGE

13. Optic Neuritis after Measles and Intermittent Fever. By Hiram Woods, M.D., Baltimore, Md. 95

14. Report of a Case in Which there is Binocular Absence of the Choroid, Showing a Rich Plexus of Cilio-Retinal Vessels Supplying the Region of the Yellow Spot in Both Eyes. By Warwick M. Cowgill, M.D., Paducah, Ky. (With two drawings.) . 105

15. Temporary Hypermetropic Astigmatism Following an Attack of Measles. By F. W. Marlow, M.D., M.R.C.S., New York . 107

16. Living Larvæ in the Conjunctival Sac. By R. J. Phillips, M.D., Philadelphia. (With a drawing.) 110

17. How shall We Treat Trachoma To-day? By Dr. E. Jaesche, Dorpat. Translated by Dr. Ward A. Holden, New York . . . 113

18. Remarks on the Treatment of Trachoma by the Expression of the Morbid Substance with a Roller Forceps, based on a Series of 114 Successive Cases. By H. Knapp. (With one wood-cut.) . . 119

19. Systematic Report on the Progress of Ophthalmology during the First Quarter of the Year 1891. By St. Bernheimer, Heidelberg; C. Horstmann, and P. Silex, Berlin. With the Co-operation of S. M. Burnett, Washington; Dantone, Rome; Hirschmann, Charkow; E. Marckwort, Antwerp; P. v. Mittelstädt, Metz; L. Werner, Dublin; C. H. A. Westhoff, Amsterdam; Schiötz and Ole Bull, Christiania, and Deus, Berlin. Translated by Dr. F. E. D'Oench, New York 128

A.—Dr. St. Bernheimer. Text-books, monographs, treatises on general, bibliographical, and historical subjects, 128; General pathology, diagnosis, and therapeutics, 130; Anatomy, 131; Physiology, 134.

B.—Dr. Horstmann. Anomalies of refraction and accommodation, 135; Lids, 137; Lachrymal apparatus, 140; Muscles and nerves, 142; Orbit and neighboring cavities, 144; Conjunctiva, cornea, sclera, anterior chamber, 148.

C.—Dr. P. Silex. Iris, 153; Choroid, 154; Glaucoma, 155; Sympathetic ophthalmia, 155; Vitreous, 155; Lens, 156; Retina and functional disturbances, 157; Optic nerve, 161; Injuries, foreign bodies (parasites), 161; Ocular affections in constitutional diseases, 162.

20. Miscellaneous Notes 166

A.—Reviews.
B.—News.—A New Eye and Ear Hospital (With a plate in the text) . . 168

VOL. XXI. No. 1.

ARCHIVES OF OPHTHALMOLOGY.

OBSERVATIONS ON THE MACULA LUTEA.

By G. LINDSAY JOHNSON, M.A., M.D., B.S., Cantab., F.R.C.S. London.

OPHTHALMIC SURGEON WEST-END HOSPITAL FOR NERVOUS DISEASES, AND OPHTHALMIC SURGEON WESTERN GENERAL DISPENSARY, LONDON.

(*With 16 figures on the colored plates A–D.*)

A.—THE MACULA REFLEX.

OPHTHALMOSCOPIC APPEARANCES OF THE HEALTHY MACULA.

According to the text-books and the references in the ophthalmological archives and journals, the macula lutea in the normal eye is generally represented as a patch of somewhat darker red than the surrounding fundus, containing in its centre the fovea centralis as a bright red spot.

In a few instances a narrow bright halo surrounding the macula region has been described and depicted. In all these pictures the halo (if shown at all) is represented as an oval with a long axis horizontal or slightly oblique (from 10°–15° to the horizon). All text-books state that it is difficult to see the macula at all, and some of those works which refer to the halo state that it can only be observed in children, and that only when the pupil is undilated by a mydriatic, under which condition, as above stated, it appears as an oval ring.

It is remarkable that, in spite of the most diligent search, I cannot find a single author in the whole range of ophthalmological literature who mentions the macula as appearing round when observed ophthalmoscopically. It is true Schmidt-Rimpler describes the macula, examined anatomically, in enucleated eyes, as being usually circular, but when

referring to its ophthalmoscopic appearances, he describes it and its surrounding ring as a transversely placed oval (queroval), and thus he figures it in his well-known text book[1]; but he remarks, with his characteristic love of accuracy, that this appearance is not in harmony with his anatomical observations.[2]

The appearance of the macula floor and ring appears to have first been definitely laid down by Richard Liebreich in Graefe's *Archives* for the year 1858.[3] Since that time the description of the obliquely oval appearance of the macula ring has been repeated in words almost identical to those of Liebreich in every text-book on ophthalmology and physiology in which any description of it is given.

In addition to this, I notice that it is invariably stated that this ring round the macula can *never* be seen by the direct examination, *i. e.*, by the upright image,[4] and that, if it could be seen, the magnification is so great that only a portion could come into view at one time; moreover, it is repeatedly affirmed that this ring can only be seen in dark children, and it is maintained that dilatation of the pupil with atropine causes it at once to disappear.[5]

On consulting the various atlases of the eye I find the pictures of the macula ring all having the same oval shape and axial direction, but beyond this they have few points in common. Thus Galezowski figures the typical macula region in his atlas as an oval ring brick-red in color, with a red fovea centralis on an orange-red base.[6]

Schmidt-Rimpler draws it as a canary-yellow oval, with an orange-centre on a walnut-brown base.[7]

---

[1] See colored plate opposite page 321, 2d edition, 1888.

[2] Die Macula lutea anatomisch u. opthalmoscopisch, *A. f. O.*, xxi., 3, p. 17.

[3] Histologisch-ophthalmoscopische Notizen, *A. f. O.*, iv., 2, p. 301.

[4] "Auffallend ist es, dass der Lichtring im aufrechten Bilde fehlt."—Schmidt-Rimpler: "Handbook," p. 231. 2d ed.

See also *A. f. O.*, xxi., 3, p. 27.

Loring: *Transactions of the American Ophthalmological Society*, July, 1891, p. 29.

Mauthner: "Lectures on the Opthalmoscope."

[5] Panas: "Leçons sur les Rétinites," 1878, and Giraud-Teulon: "La Vision et ses Anomalies," p. 355, ed. 1881. Schmidt-Rimpler: *A. f. O.*, xxi., 3, p. 28, etc., etc.

[6] "Traité Inconographique d'Ophthalmoscopie," pl. 1, fig. 2.

[7] "Augenheilkunde," p. 321, 3d edition, 1888.

Panas and Mauthner both describe it as a brilliantly silvered ring.[1] Power speaks of it as "a soft whitish line," which he ascribes to the reflection of the rim of the mirror.[2] Landolt describes it as "a bright oval line, sometimes glistening with a red floor and intensely red, almost black, centre, the dark point in the centre being hardly ever absent."[3]

Helmholtz says: "The retina appears at the yellow spot much darker, of a grayish-yellow color, without any mixture of red,"[4]—a statement which Coecius says he cannot agree with. On the contrary, he says the floor of the macula is dim and of a much deeper red than the fundus generally; in some instances it is even brown or deep gray.[5] Schirmer poetically compares the ring (or Heiligenschein, as he calls it) to the small, finely branched, sparkling ice-flowers on a frosted window-pane.[6] Finally, Merkel[7] describes it as a citron-yellow patch with a round black spot in its centre, which corresponds to the fovea centralis.

By comparing the above description of the typical macula with its ring and centre, we find that no two writers agree as to the appearance and color.

As in many points my observations have led me to conclusions entirely different from those arrived at by the distinguished ophthalmologists above mentioned, I have ventured, though not without some hesitation, to lay the results before the readers of these ARCHIVES.

The conclusions which I have arrived at are:

I.—*That when observed in a certain way the macula ring in its entire circumference can be seen in every person under thirty-five years of age, and frequently, though with diminishing frequency, over that age.* The only cases in which I find an exception are in high myopes (*i. e.*, over 7 D or 8 D), in very fair people in whom the pigment is entirely or largely absent, and in cases in which the pigment is irregularly dis-

[1] "Leçons sur les Rétinitis," 1878.
[2] "Illustrations of the Principal Diseases of the Eye," p. 393.
[3] "Examination of the Eyes," p. 202.
[4] "Beschreibung eines Augenspiegels," p. 35.
[5] Criticism on the above.
[6] Ueber das oph. Bild der Macula lutea, *A. f. O.*, vol. x., Abth. 1, p. 149.
[7] Graefe-Saemisch "Handbuch," Bd. I., Th. 1, p. 34.

tributed and disturbed.[1] All such cases taken together do not nearly amount to five per cent. of the population. The observation of the macula ring is by no means easy in many cases, and it has necessitated repeated trials to determine the amount and direction of the light, and the direction and axis of the patient's eye, so as to produce the clearest image.

The reflection of light from the fundus is so strong that the feeble reflection of the macula ring is entirely overpowered, and no trace of it is to be seen. But I discovered that *if the source of illumination be gradually lowered, the reflection from the fundus decreases more rapidly than that from the margin of the macula, so that a time is arrived at when more light is reflected from the latter than from the general fundus, and at that moment the ring appears.*

There are cases in which the reflection from the macula circumference is so strong that no amount of reflection from the fundus can eclipse it; in such cases of course the ring may be observed by the full flame and even by the indirect method, but it is owing to the rarity of such cases that the appearance of the ring at all has become to be regarded as a phenomenon worthy of note. Moreover, in the direct observation the mirror should be held close to the pupil, in order to see the ring in its entirety, as otherwise the amount of the fundus seen at one time is too small to include it. In most cases, moreover, the macula ring can, even with reduced illumination, only be seen by placing the mirror and the patient's eye so as to observe the macula obliquely to the cone of reflected light proceeding from the macula itself, otherwise this cone of light produces so much dazzle and flare that the details cannot be clearly and satisfactorily made out.

In some cases in which at first no ring can be discerned, I have usually been able to see it quite clearly by moving the ophthalmoscope either laterally or vertically across the field, close to the cornea, until the retinal shadow just

[1] I have reason to believe the halo is often absent or at least less distinctly marked in so-called "neglected eyes," which have been disused from birth, but I have not yet been able to see a sufficient number of cases to state this definitely.

reaches the edge of the macula, when the whole ring instantly comes into view with great distinctness as soon as the illumination is sufficiently reduced. The cone of rays in undilated pupils can only be avoided by oblique observation by the direct method, which is to be preferred in every respect, and particularly because the magnification is not only greater than by the indirect, but, as Dr. Landolt first pointed out, it is invariably the same if certain conditions be observed.[1] He demonstrated that, provided the mirror with its correcting lens be held at the anterior principal focus of the patient's eye, the amplification of the image is exactly 20 diameters.[2] Now the anterior principal focus is situated 13.7 *mm* from the anterior surface of the cornea, a very convenient distance for observation. Moreover, if the correcting glass in the ophthalmoscope be at this distance, the magnification is dependent on the refraction of the patient's eye; whereas, with the indirect method, the magnification varies between wide limits (2 and 7 diameters) according to the focal length of the lens, the refraction of the patient's eye, and the position of the lens employed.

Lastly, it is especially important that the mirror used for the upright image should be of a suitable curvature to get the best result. With the indirect method it matters very little what focal length be used, owing to the interposed lens, but by the direct method it becomes a matter of considerable moment. In order to clear up this point practically, I had a series of concave mirrors made of focal lengths varying from 1.5 to 10 inches. I then, by means of cobbler's wax, stuck the mirror to be tested in its normal position in my ophthalmoscope, and made repeated trials with it, the wax holding sufficiently for observation but allowing of the mirrors being rapidly changed. In this way I found that the best average results at 14 *mm* distance were obtained with a mirror of 2¼ in. solar focus; mirrors of shorter focal

---

[1] On the Enlargement of Ophthalmoscopic Images.—E. Landolt, *Brit. Med. Jour.*, March 1, 1880.

[2] Of course the correcting lens must be at the anterior focus of both the observer's and the patient's eyes that this should be mathematically correct, but if the observer has normal refraction he can hold his eye as close as he likes to the ophthalmoscope without any practical error.

length gave too diffuse an illumination; those over 3 in. began to show, as a rule, a distinct image of the flame, while those with a focus over 5 or 6 in. gave rise to flare rings and Heuse's phantom circles.[1]

Having thus arrived at the best practical focal length for the mirror, I got a series of them made of $2\frac{1}{4}$ inch focus, but with apertures varying from a pin's point to 4 *mm.* I found that very small apertures (under 2 *mm*) allowed too small a pencil of rays to reach the observer's eye, and thus the fundus appeared imperfectly illuminated, while apertures exceeding 3 *mm* caused a slight round shadow to fall on the fundus which increases in intensity with the size of the aperture. I found 2.25 *mm* and 2.5 *mm* to give the best results.

It is very necessary to remove all traces of reflection from the edges of the sight-holes and from the rims of the correcting lenses, which, though not always troublesome in ordinary fundus examination, may become so when observing the macula region, since the slightest reflection from the margin of the sight-hole, owing to its close approximation to the observer's eye, forms an indistinct but magnified image of itself in the shape of a semicircular flare or haze which occupies a considerable part of the usual field and greatly detracts from the clearness of the macula image.[2]

By observing, then, in the way above recommended, I find it best, as soon as I can see the macula at all, to turn down the gas flame rapidly to as low a point as possible consistent with good vision, and then the halo (or halos), if not previously seen, invariably (of course with the exceptions above named) come into view.

---

[1] Ein Lichtreflex der Retina, *A. f. O.*, i., 1884, p. 155.

[2] Couper, in his "magazine" ophthalmoscope, by the invention of the chain-movement, by which a practically indefinite number of lenses can be rotated behind the aperture of the mirror without increasing the thickness or breadth of the instrument, has greatly facilitated the examination of the upright image; for Mr. Couper maintains (and I am quite of his opinion) that the *best* results can only be obtained by single lenses for each focal length, and not by the superposition of one lens on the other, as is the case in nearly all ophthalmoscopes in which the lenses are rotated by discs. For the examination of other parts of the fundus it does not matter so much which form be used, since the addition of two more reflecting surfaces will not interfere perceptibly with the clearness of the image, but in the examination of the macula it is essential that the number of reflecting surfaces should be reduced to a minimum, and for this reason alone the direct method is superior to the indirect one.

All the drawings accompanying this paper represent the ring as seen by the direct method, and therefore all appear circular. With the indirect method, however, I find it difficult to see the halo at all unless well pronounced, because the indirect method does not admit of the fundus being seen at all with the decreased illumination necessary to observe the halo with the direct method, the distance at which the mirror is held, together with the intervention of the lens, increases the reflection and renders the oblique observation of the macula extremely difficult.

In observing the halo by the direct method I find the use of atropine makes no difference, excepting to render the image clearer and more free from flare, and the only explanation that I can give why authors state that the use of atropine causes the ring to disappear, is that they have doubtless used the indirect method, by which the illumination is of necessity very great, and the reflection from the choroid considerably increased by the enlargement of the pupil, so much so as to mask the ring, which, as I have already stated, can only be seen by reducing the illumination in order to, so to say, darken the background. As, moreover, the intensity of illumination varies inversely as the square of linear magnification, the illumination by the indirect method must, *cæteris paribus*, be much greater than by the direct, and even that, as I have pointed out, is in most cases too strong when the usual amount of light is employed.

II.—*The macula is invariably circular, and probably corresponds to the extreme limit of the macular region.* When viewed by the direct method the ring always appears circular. If authors have until now seen the ring as an oval, as mentioned above, it is no doubt due to the use of the indirect method, and I find that in cases in which the ring is sufficiently intense to be seen by this method, it appears as horizontally or slightly obliquely oval.

Schmidt-Rimpler, in trying to account for the oval ophthalmoscopic appearance of what his anatomical observations showed to be a circle,[1] thinks it due to the fact that the curvature of the cornea is greater in the vertical than in

[1] Schmidt-Rimpler: *A. f. O.*, xxi., Abth. 3, p. 26.

the horizontal meridian, and consequently the circle appears horizontally oval. But the difference in curvature between the two meridians is obviously an insufficient explanation. The vast majority of persons possess a corneal astigmatism of less than 0.75 D, and the addition of a cylinder of this amount will only increase the apparent diameter of the ring by 0.14 *mm*, *i. e.*, less than its thirty-fourth part, an increase quite imperceptible. Moreover, if the curvature of the cornea were the cause, observation with the direct method should show the ring as a vertical oval, which is very rarely if ever the case. The explanation will, I think, be found in *the distortion produced by the lens and mirror.* If the light be placed at the side of the patient's face, the slight obliquity of the condensing lens is quite sufficient to distort the circle into a horizontal oval. In order to test this I selected a patient who had an unusually distinct ring, normal refraction, and less than 0.25 D of astigmatism, and atropinized his eye in order to avoid all error due to accommodation. On placing the light at the side of his face, when examining by the indirect method, I saw the horizontal oval ring. On directing the assistant to slowly move the light through a quarter circle to just above the patient's head, I noticed the macula ring change from a horizontal to a vertical oval and back again to a horizontal oval as the light was moved to a corresponding position on the other side of his face. Of course I had to tilt the lens in accordance with the shifting of the light, in order to bring the rays on to the macula, and it was this tilting of the lens which produced the change in the shape of the macula ring. Had the ring been a definite structural mark on the retina or choroid and not a mere reflex, it would of course have remained unaltered, but the fact that the ring is due to a reflection allows a slight amount of shifting, and it is this slight movement which causes the ring to appear drawn out into an oval, so to speak, when the light is at the side of the patient's face and the lens and mirror are imperceptibly tilted in consequence.

When the direct method is used the distortion (due to the tilting of the lens) is avoided and the ring appears circular.

All the microscopical and entoptical observations, as far as I have been able to find, show that the macula is circular. Schmidt-Rimpler, as above stated, draws special attention to the circular form of the macula in his anatomical preparations.

Meyerhausen,[1] Ewald,[2] and others have frequently figured and described Clerk Maxwell's entoptic figure as a bluish, star-shaped, circular patch.

Lastly, Purkinje's candle experiment shows the macula to be quite circular.

As this experiment helps us to become better acquainted with the shape of the macula than any other I know of, and as I am not aware that the detailed description of the appearance of the macula by this method has ever been given, I trust it will not be deemed out of place to describe it here.[3]

By moving the candle up and down or sideways about 10° to the outer side of the visual axis, while gazing at a black surface in a dark room, the following points may be noticed by a practised observer.

First, the retinal vessels appear raised and of a chocolate color on a dull gray-brown background. Suddenly, in the axis of vision, the macula comes into view as a brilliant, dark brick-red, *perfectly circular* patch, standing alone on the background. The edge of the macula appears raised, casting a shadow into its cup-shaped interior, as the candle is moved. On the edge of the macula nearest to the candle (*i. e.*, the inner side) a brightish reflex may be seen, reminding one of the ophthalmoscopic macula reflex, excepting that it only occupies a portion of the circle at a time—*i. e.*, the part directed to the light. Of course, this bright reflex may be seen to travel round the edge of the macula if the light is made to revolve in a circle round the optic axis. The macula appears about half the diameter of that seen by

---

[1] *A. f. O.*, vol. xxvii., p. 2.

[2] "Researches Heidelberg Institute," vol. ii., 2, p. 241.

[3] A detailed description of these experiments, with an excellent drawing, was published in 1882 in these ARCHIVES, vol. xi., p. 476, etc., by Wm. C. Ayres, under the title, "The Blood Circulation in the Region of the Yellow Spot."
H. K.

the direct method with the ophthalmoscope. The macula region appears quite homogeneous and free from vessels except at its margin, where they curl over and are lost to view. Frequently the vessels are seen to divide dichotomously just before reaching the macula.

It takes some moments before the other eye, when experimented on after being closed, can perceive the vessels; moreover, the macula does not appear red for some moments, but its redness soon becomes markedly in contrast with the rest of the dull-brown ground.

When examining the macula ring with the ophthalmoscope, I invariably see the retinal vessels curling over the ring into the macula depression, exactly corresponding to what I see in Purkinje's experiment mentioned above. These vessels pass into the macula in children as well as in adults,[1] and frequently divide dichotomously just over the ring, becoming rapidly so fine that they can no longer be traced any farther. I have only met with two cases in healthy eyes in which I could trace a retinal vessel up to the fovea itself. One was in a native boy from the Upper Congo (Fig. 11), who had marvellously acute vision, and in whom I could trace two minute arterial twigs right up to the fovea centralis. The other was in a patient with a healthy fundus and normal refraction and vision.

As the raised edge of the macula seen by Purkinje's method occurs just inside the point where the vessels divide dichotomously, and as it is just there that I see the ring with the ophthalmoscope, I have reason to believe that the ring corresponds to the extreme limit of the macula region. This view has been further confirmed by some experiments I have made, and which, when completed, I hope to be able to describe in a future number.

III.—*The ring is no doubt due to the cup-shaped dip of the macula.* It has been generally recognized that the surface of the retina presents a depression at the macula, commencing at its circumference and increasing rapidly towards the fovea, where the dip is often very considerable; so much so,

[1] See Leber's reply to Johannides, Graefe's *A. f. O.*, vol. xxvi., Abth. 2, p. 127.

that the older writers considered it as a foramen. Max Schultze described it minutely and figured it in his two celebrated diagrams, which have been copied all the world over. Although it is quite impossible to recognize any alteration in level of the macula with the ordinary ophthalmoscope, there are many other ways of assuring one's self of this fact. The most obvious method that suggests itself, is to make axial sections through the macula region of a removed eye with a razor, and to examine the cut surface under a low power. But there are many difficulties in the way. It is exceedingly difficult to get perfectly fresh and healthy human retinæ, and, when obtained, they must be examined immediately, as degeneration of the retinal elements sets in very rapidly, and especially where it is most to be avoided, viz., at the macula. If the eye be opened and thrown into water, the cells rapidly imbibe the fluid, and swell up, so that any attempt to ascertain the difference in level is seen at once to be hopeless. After some time the surface of the retina gets sodden and raised in the form of minute papillæ, an appearance which becomes very striking round the macula if examined with a low magnifier. It is exceedingly difficult to prevent the retina becoming detached when manipulated after removal. The only way to accomplish this with certainty is to freeze the eye immediately it is excised, and then to make the section behind the equator, and afterwards through the macula itself. The vitreous need only be slightly frozen. The position of the macula is much more readily found by marking the top of the eye before removal, by which its exact position can be determined.

I have experimented with Giraud-Teulon's binocular ophthalmoscope, which has shown to me very clearly the alteration in the level of the vessels as they curl over the edge of the macula.

I think Purkinje's candle phantom, as described above, gives a very reliable and good representation of the cupping of the macula, as the relative depth and slope of various parts of the circumference can be judged by the length and blackness of the shadow cast by its side, but unfortunately one's observations are confined to one's own eyes.

Many years ago, Loring made some interesting experiments to ascertain whether the reflex ring could be produced artificially.[1] He made a small hole in a piece of smooth tinfoil (the $\frac{1}{8400}''$ in thickness), which he squeezed over a disc of plain glass and carefully squeezed a second piece of foil over the first, thus making a uniformly smooth surface with a circular depression of less than the $\frac{1}{8400}$ of an inch in depth.[2] This, being placed in the plane of the posterior pole in an artificial eye, showed a glittering ring with the ophthalmoscope very similar to that seen in the human eye. I have made similar experiments myself both with goldbeater's-skin and with tinfoil, and obtained identical results with those of Loring, nor can I see how they could be otherwise. It therefore occurred to me that the retinal arteries might produce a reflex in the same way by slightly raising the level of the tissue above them. I therefore cut a hair from the head into short pieces and laid them on a cover-slip moistened with equal parts of egg albumen and glycerine. This I dried slightly over a flame and squeezed a piece of tinfoil over the top. The minute ridges thus produced formed the best substitute I could make for the retinal arterioles. . On measuring the height of the ridges I found them to vary between the $\frac{1}{1500}$ of an inch and the $\frac{1}{3000}$ of an inch. I then placed it at the retinal plane of my artificial eye (Landolt's) and examined it with the ophthalmoscope. The ridges gave all the appearance of the glistening sheen which one observes playing over the arteries. So far the analogy appeared to hold good, but it fails to explain the reason why this shot-silk sheen disappears with age, unless it is that in later years the surface of the retina reflects less light.[3]

IV.—*I observe three forms of rings.* Of these the most common is a bright scintillating reflex resembling shot-silk

---

[1] *Transactions of the American Ophthalmological Society*, July, 1871, p. 77.

[2] Dr. Loring does not say how he arrives at his figures, but I have repeated his experiments most carefully, and I find his figures are much too high. I never found the difference in level less than $\frac{1}{2000}$ of an inch (0.0125 *mm*), nor can I discover where tinfoil so thin as the $\frac{1}{8400}$ of an inch (0.003 *mm*) is to be obtained.

[3] Brecht, *A. f. O.*, xxi., Abth. 2, p. 1, describes a similar experiment to that of Loring, and gives a colored diagram of the ring he saw in the artificial eye.

similar in appearance to that noticed skirting the blood-vessels and over the greater part of the fundus in darkly pigmented eyes (Figs. 2, 4, 9, 11, and 12). In some cases it only exists as a circle round the macula, rapidly fading away and losing itself as it reaches the floor, but spreading out for some considerable distance on the farther side of the macula, the distance varying to some extent with the position of the mirror, so that the breadth of the ring cannot be even approximately measured, although the inner margin is much more sharply defined, and varies within very narrow limits, as the mirror is moved or tilted. This form of ring can usually only be seen when the gas is turned down as low as is consistent with good vision. In such cases, if the ring is well marked, the shot-silk appearance will appear following the vessels, now over them, and now as silvery flames extending here and there along their sides, appearing and disappearing in various places as the mirror is shifted and tilted. The distinctness of this shot-silk sheen is always very marked in dark eyes, becoming less evident as the pigment decreases, until in very fair eyes, in which the choroidal vessels begin to shine through, it is hardly visible, although with patience and careful adjustment of the position and amount of the light traces of it can generally be seen. But still it is worthy of note that the macula circle is always the last to disappear, and the fundus must have very little pigment indeed if it cannot be made out at all.

I believe that this ring is partly due to a reflection from the fibres of Müller, where they expand into the membrana limitans interna, but this cannot be the only cause, as the reflex along the sides and over the vessels is always more conspicuous than anywhere else, and I can offer as an hypothesis that the fibrous sheaths of the vessels contribute largely to the cause, by slightly raising the portions of the retina immediately overlying them.

The sheen is nearly absent in the immediate vicinity of the disc, and is entirely absent inside the macula region, excepting a narrow variable band just within its boundary. I searched carefully for this reflex within the macula in the case of the Congo boy, in whom I traced the retinal vessels

to the fovea itself, but did not observe any sheen along them, although abundantly present along the vessels elsewhere, and even along the smallest twigs. Whether the slope of the macula floor or the scanty development of Müller's fibres at this point was the reason for the absence of reflex, I will not venture to surmise.

The second form consists of a radiating ring of a grayish-white lustre round the macula (Figs. 2 and 3). The radii are all directed towards the fovea; although losing their outline at the edge of the macula, they may be traced for a variable distance (usually about $\frac{1}{2}$ PD) away from the macula. At the same time the fibres may be traced radiating for some considerable distance from the margin of the disc. They bear a striking resemblance to nerve fibres, and I am of opinion that they are due to their partial translucency, although I am aware that Professor Schweigger, who has given great attention to this subject, considers the similar appearance round the disc due to a peculiar arrangement of the connective-tissue fibres and not to the nerve fibres. To test this I compared several of these cases side by side with cases of undoubted opaque nerve fibres, and fortunately I found a patient in whom varying degrees of opacity of the nerve sheaths were present, and in parts where the fibres were merely translucent the appearance was identical with the striæ above mentioned.

The third form is so conspicuous that it may be seen even with the brightest illumination as a well marked whitish or golden ring of metallic lustre of the well known oval shape when examined with the inverted image, but quite circular with the direct method (Figs. 1 and 12). It is much narrower than the other two, and is sharply limited just inside the macula circumference, and becoming rapidly lost on its outside.

In these cases, which occur for the most part in children, the macula can be seen to be raised or to have a thickened border, and I think that the shape of the macula border is the cause of its prominence.

In the foregoing pages I have stated:

That the ring around the macula can always, with a few

exceptions, be seen in persons under thirty-five years, and with diminishing frequency in older subjects.

That the macula ring is invariably circular and probably corresponds to the extreme limit of the macula region.

That the ring is undoubtedly due to the cup-shaped dip of the macula region; and that I observe three distinct forms of macula rings; and I have also tried to account for these various appearances.

I would now like to add some further conclusions which my observations and experiments have led me to consider probable.

One reason why the ring is most marked in children (so much so, in fact, that it can frequently be observed with full illumination and by the indirect method) seems to be that in early age the circumference of the macula is formed by a rounded ridge which stands above the general level of the retina. I have been led to this conclusion by the examination of the eye of a youth, which I excised for a deep corneal wound a few weeks ago, and in which I could distinctly see the ridge with the naked eye immediately after excision, and before I placed the divided bulb in a preserving fluid. Inside this ridge the retina sloped more or less gradually towards the fovea. An ophthalmoscopic examination of the remaining eye showed a reflex ring of the third form above described.

I have reason to believe that as a person advances in years this ridge flattens down, but whether the general slope of the macula becomes actually less or not, I cannot say. One thing is certain—the shot-silk reflection of the retina is most conspicuous in childhood. It appears to become less and less with advancing years, and towards middle life it insensibly disappears, and with it the reflection of the macula ring.

I must still point out that occasionally another ring inside of the macula may be observed, which seems to correspond to some further change of level in the floor of the macula between the edge of the macula region and the fovea centralis (see Fig. 1).

Seeing the ring in almost every person, and being thereby able

to determine the limit of the macula region, it may prove of practical value in diagnosing whether a lesion or defect is situated within or without the region of acute vision.

B.—THE FOVEAL REFLEX.

At the centre of the macula ring a very small ring is frequently seen at the edge of the dip of the fovea centralis.

As regards this ring, from anatomical considerations alone, I think no other conclusion is possible than that it is due entirely to a reflection from the edge of the fovea; and I have not the slightest doubt that all the other kinds of reflexes to be met with at the fovea are due to the direction and shape of the sloping sides of the pit. The foveal reflex assumes a large number of shapes. It is generally very bright, like burnished gold, being sometimes a minute but perfect circle (Fig. 9), but more often shaped like a "C" (Fig. 6), the gap in the circle moving with the mirror and position of the light. Occasionally one sees a central spot of reflection (Fig. 4) which varies in different eyes, from a mere point of light to a long flare spot or comet (Figs. 7 and 8), with the apex at the fovea and the base of the "tail" at or near the circumference of the macula. This flare spot is very striking and very characteristic, but it is undoubtedly due to the same cause as the foveal ring, since I have traced every stage of its development.

We see it in its simplest form as a spot of light (Fig. 4), then as a small ring (Fig. 5), then again as a series of dots (Fig. 3), then a horse-shoe form or a portion of a ring (Fig. 6). This in other cases appears with its centre filled and spread out like a bat's-wing or fish-tail gas-jet (Fig. 13). In other cases again it looks like a short comet (Fig. 7), and sometimes as a long comet with a tail extending as far as the edge of the macula (Fig. 8). I have even seen it appear as a glistening horizontal line reaching from a central bright dot to the limit of the macula. These are some of the forms which occur, but the appearance of the foveal reflex is exceedingly varied. The foveal reflex, like that round

the macula, becomes less visible with age and beyond middle life often disappears altogether, but it may frequently be seen as a tiny bright speck in the centre of the slightly darker red background when all traces of the macula ring have vanished.

Several authors, especially Helmholtz, Loring, and Brecht, point to the similarity between these reflexes and the appearance of the depression seen in the tympanic membrane below the end of the handle of the malleus.

I may still refer to the fact that I find some authors in doubt as to the fovea reflex being always in the centre of the macula ring (being placed by many a little above the centre). My observations invariably show the foveal reflex to be at the centre, when in the shape of a ring or a dot, and in other shapes the apex of the reflex is always at the centre likewise. If it does not appear in the centre it is due to the fact that the fovea being a deep depression, the reflex remains stationary, whilst the macula ring can by the tilting of the mirror or lens be made to move within narrow limits, and thus be made apparently to cause the fovea to appear eccentric.

I have stated above that the fovea reflex seems unquestionably due to the reflection of the edge of the fovea, and I fully believe that the varying appearances can all be accounted for by the fact that the foveal pit varies in shape as Schmidt-Rimpler and others have shown.

C.—THE COLOR OF THE MACULA.

I do not think it will be necessary to say a great deal on this head, as it is difficult to amplify with words that which has been so carefully depicted in the accompanying drawings. I would, however, remark that I do not observe any noticeable change in the color of the macula when varying the degree of illumination. I have taken great pains to get the color to appear right when seen by daylight, although as the drawings were made by gaslight the color is more correct when seen under the same conditions.

In many cases, especially in persons over thirty-five, there

is very little difference in color between the macula and the rest of the fundus, and I find the same holds good in high myopes.

I believe that it may be taken as a general rule that in normal eyes of Europeans the inner portion of the macula appears of a more intense or brighter red than the fundus generally, the color deepening as it approaches the fovea centralis, where it is almost always masked by the bright foveal reflex varying in shape and intensity.

Of course exceptions do occur, and the intensity of the red varies considerably in different individuals, there being naturally an ascending scale from very fair to very dark-haired people. I have never met with a black or brown appearance of the fovea centralis, such as has been depicted by several writers as mentioned in the introduction, although on one or two occasions I have seen a deep shadow which was no doubt due to the foveal pit being unusually deep and narrow, and which has given rise to the mistaken idea of a black or dark-colored fovea centralis.

I have noticed that the macula region is devoid of that faintly granular appearance which can almost invariably be seen over the rest of the fundus by carefully focussing with the direct method of observation.

I have frequently observed in the macula area, and especially near the fovea, one or more minute yellowish dots somewhat resembling fatty particles; in some cases they appear dull, in others glistening. I am not sure whether they ought to be considered as pathological or not. At any rate they are exceedingly common in the macula area, though they are by no means confined to that region.

In concluding this article I am fully aware that I have by no means exhausted the subject, and that it will no doubt be possible to find exceptions to the rules I have tried to establish. But I cannot help feeling impressed with the importance, not to say the necessity, of arriving at such a definition of the ophthalmoscopic appearances of the healthy macula as will enable us to distinguish the slightest trace of a pathological condition in this the most essential portion of the retina.

Explanation of the Colored Drawings.

All the drawings represent the macula in perfectly healthy eyes, and comprise characteristic and carefully selected specimens of the chief varieties which have come under my notice.

FIG. 1.—Shows a very well marked macula ring, with a foveal, and also an intermediate or secondary ring. The macula ring is characteristic of the third type as mentioned in the text.

From an English youth, æt. eleven, with brown irides. H = 2 D. V = $\frac{6}{6}$.

FIG. 2.—A good example of the first or ordinary type of macula rings (*vide* text). The fovea appears a dull red circular spot. Five glistening "crick" dots surround it. They appear like polished specks of metal, but the lustre can naturally not be rendered in the drawing. The floor of the macula was very little darker than the surrounding fundus. From an English youth, æt. 18. V = $\frac{6}{6}$; Em.

FIG. 3.—A macula halo of an intermediate form between the two described above. The foveal ring presents a peculiar circle of small yellowish dots arranged with great regularity. From an English boy, æt. eleven. H = 1 D. V = $\frac{6}{6}$.

FIG. 4.—A common form of macula halo. This halo is peculiar in that it occupies nearly the entire macula region. The fovea appears as a small yellow spot. From an Englishman, æt. twenty-five, V = $\frac{6}{6}$; Em.

FIG. 5.—Shows a characteristic fovea often seen in adults. It is quite round and of a buff color like a fat-cell. The macula ring was barely visible, but consisted of a number of faint radiating lines which can be traced nearly to the fovea. From a man, æt. twenty-seven, light-brown hair. V = $\frac{6}{6}$; Em.

FIG. 6.—A characteristic horseshoe form of the foveal reflex. The gap in the small circle can be made to assume almost any position by varying the position of the mirror and light. This macula reflex is an example of the second class. From an English boy, æt. eighteen. V = $\frac{6}{6}$; Em.

FIG. 7.—Exhibits a short "comet flare" with the apex at the fovea. The macula region is not homogeneous, but the arrangement of the pigment layer in lighter and darker spaces shows a radiating appearance, the light streaks tending towards the fovea. From an English girl, æt. eighteen. V = $\frac{6}{6}$. H = 1 D.

FIG. 8.—A long "comet flare," from a boy with light flaxen hair, æt. eight. V = $\frac{6}{6}$; Em. The direction of the tail is towards

a point just above the disc. *I have found that comets are invariably either in this direction (or more rarely) directly inwards.* The sight in this and the foregoing case was perfect, and the eye in the latter emmetropic. This is noteworthy, as these "comet flares" are supposed by Marcus Gunn to be confined to amblyopic myopes. (*Trans. Oph. Soc.*, vol. viii., p. 173.)

Fig. 9.—A very pronounced example of the 1st class of macula rings. The foveal ring is quite circular,—the fovea itself being bright scarlet. From a very dark-olive-complexioned Spanish girl with black hair and dark-brown irides. V = $\frac{6}{6}$. H = 1 D.

Fig. 10.—The macula of a Siamese boy, æt. twelve, born in India. The radiating macula ring of class 2 can be faintly discerned. The floor of the macula is dark, which makes the fovea look redder by comparison than it actually is. The boy had a dark-yellow complexion with dark-brown irides and brown-black hair. V = $\frac{6}{6}$. H = 1 D.

Fig. 11.—The macula region of a native African boy, æt. sixteen, of the flat-nosed prognathous negro type, from Vidi, Lower Congo region. The reflex from the whole fundus is very pronounced, but the general color of the fundus, as indeed in all the natives of Equatorial Africa, is much lighter than in the case of half-casts from the same region, of American and West Indian negroes, and even gypsies. Two distinct macula halos, one lying over the other, can be made out quite clearly. Both halos are quite circular, the superficial one extending further over the floor of the macula than the deeper one. By shifting the mirror the superficial one could be seen to glide slightly over the deeper, thus showing that they were due to different causes and to different layers in the retina.

Two retinal vessels, one arterial and one venous, could be traced to the fovea, which appeared as a dark cherry-red circular patch. Three bright crick dots are to be seen on its upper border. The two yellowish streaks, beneath the horizontal superior temporal artery, are due to a ruptured choroid of long standing from a severe blow in the eye, but this in no way affected his vision, which is quite phenomenal, the eye being absolutely healthy. V = $\frac{6}{1.5}$ and J = 1 at 6 feet. H (manifest) = 0.75 D.

Fig. 12.—The macula region of a native boy from Stanley Pool, Equatorial Africa. This boy belongs to a distinct and superior race to the former, having a well developed nose, and thinner, less prominent lips. The general reflex along the

blood-vessels of the fundus is less marked than in the former case, but the macula ring is very prominent, and appears to be distinctly raised above the general level. Quite a number of small twigs from the superior and inferior temporal arteries pass under the ring to disappear on the floor of the macula after bifurcation.

The fovea is reddish, with a bright round central reflex spot. His vision exceeded anything I have ever noticed before or since. $V = \frac{6}{1.2}$ and $J = \frac{2}{3}$ at 6 feet. H (manifest) = 0.75 D. Astigmatism nil.

Fig. 13.—The macula region of a negro from the Barbadoes, æt. thirty.

The color of the fundus is several shades darker than that of the Congo natives. The macula ring is very feeble; it is only seen as a faint shimmer, after the gas had been lowered. The macula region is darker towards the fovea. The foveal reflex is somewhat in the shape of a bat's-wing burner, being brightest at the centre of the fovea. $V = \frac{6}{6}$; Em.

Fig. 14.—The macula of an English boy, æt. thirteen, with black hair and dark-brown irides; sallow complexion. The choroidal vessels are exceptionally prominent, the interstices being filled with pigment. The curious radiating lines along the floor of the macula reaching to the foveal pit are most striking.

Compare Figs. 7 and 15. $V = \frac{6}{6}$; Emmetropic.

Fig. 15.—The macula of an Albino, pale complexion, blue irides, and white hair.

The choroidal vessels are just as prominent as in the last case, but all pigment is absent; the macula is filled with fine capillary vessels, but they are too small to be clearly defined. The fovea itself appears as an ill-defined reddish spot. From a woman, æt. twenty-one.

Fig. 16.—The macula region of a woman, æt. thirty-six, with brown hair, gray eyes, fair complexion.

The whole fundus is stippled over with black irregular-shaped specks like grains of pepper. The floor of the macula is filled with innumerable black specks, which are much finer and closer together than elsewhere. No halo could be discerned. $V = \frac{6}{6}$ nearly. I have classified this case with the healthy maculæ, although exaggerated cases may perhaps have to be considered as pathological.

THE ETIOLOGY OF INFLAMMATION OF THE EYE AFTER INJURY WITH FOREIGN BODIES.[1]

By Dr. STANISLAWA POPLAWSKA, Warsaw, Poland.

Translated by Dr. Ward A. Holden, New York.

(*With Plates VI., VII., and VIII., Figs. 1–10, of vol. xxii., German edition.*)

ALTHOUGH no one to-day doubts the parasitic origin of panophthalmitis, our knowledge of the microbes which cause this inflammation, and of their biological properties, in the widest sense of the word, is still deficient. We lack detailed reports of the examination of pus in eyes with panophthalmitis, of the results of pure cultures and inoculations, and of the conditions of the microbes in question in the tissues of the eye.

The purpose of the present paper is to fill up some of these gaps in our knowledge. It contains the results of the microscopic examination of twelve eyes enucleated by Prof. Haab for panophthalmitis after injury with a foreign body.

The eyeballs immediately after the enucleation were put into absolute alcohol and left to harden in close-stoppered bottles. Later they were imbedded in celloidin and cut, and the sections stained in the following manner: (1) with hæmatoxylin and eosin for the purpose of studying the condition of the cornea, iris, retina, and choroid, and the exudations in the anterior chamber and the vitreous; (2) for studying the microbes, according to Gram's method: (1) anilin water gentian violet, three minutes, (2) washing with

[1] From the university eye clinic of Prof. Haab, Zürich.

water, (3) sol'n of potas. iod. three minutes, (4) washing in 90 % alcohol, (5) absolute alcohol, (6) oil of bergamot, (7) xylol, (8) Canada balsam; Löffler: (1) methylen blue, ten minutes, (2) washing in 5 % acetic acid, (3) washing in water, (4) 96 % alcohol, (5) oil of bergamot, (6) xylol, (7) Canada balsam; Weigert[1]: (1) saturated sol'n of gentian violet in anilin water, fifteen minutes, (2) washing in water, (3) sol'n of potas. iod. seven minutes, (4) anilin oil until decolorized, (5) clearing with anilin oil, (6) xylol, (7) Canada balsam.

I shall now describe each case in detail.

CASE I.—J. S., æt. forty-five, had a small stone perforate right eye, Oct. 20, 1886. There was pain for a short time. Vision decreased from the following day. Oct. 26th, panothalmitis; enucleated. Patient discharged cured Nov. 8th.

Microscopic Examination.—Globe scarcely shrunken. Large exudation in anterior chamber. Lens in position. The entire vitreous chamber filled with a yellowish-white creamy exudation. An exudation in the posterior portion of the ball between retina and hyaloid membrane, causing a detachment of the vitreous. The foreign body—a small splinter of iron—lay in the centre of the vitreous.

Microscopic Examination.—Cornea normal. Exudation in anterior chamber fibrino-purulent. Iris slightly œdematous, with trace of small-celled infiltration.

The exudation in vitreous chiefly pus. In the centre of the vitreous about the foreign body the small-celled infiltration is denser, and here is seen a well-marked crescentic colony of bacilli, consisting of long chains and isolated slender bacilli, many of which contain spore-like formations bordered by darkly stained protoplasm. The closely packed leucocytes form a sort of wall about the colony, but it is impossible to say whether the bacilli lie in the substance of the cells (Plates VI., Figs. 1, 2; Plate VIII., Fig. 10).

The bacilli do not stain well with Gram's method, their contours remaining blurred, and their structure indistinct; with Weigert's method they stain readily.

---

[1] *Fortschr. der Medicin*, 1887, p. 228.

When the stained preparation is held to the light the colony of bacilli is seen macroscopically as a darkly stained crescentic line. The choroid shows no particular changes.

CASE 2.—M. R., æt. twenty-eight, received March 28, 1888. Right eye and face injured in a powder blast. R. corneal wound, traumatic cataract. Vitreous protruded from the wound and was cut off.

April 9th.—Iris discolored, pupillary margin adherent to the cataract at several points.

April 10th.—Enucleation.

April 15th.—Discharged cured.

Macroscopic Examination.—Suppuration of the vitreous which contains grains of powder and bits of stone. Yellowish-white exudation in anterior chamber. Lens in position.

Microscopic Examination.—The cornea shows a marked small-celled infiltration. Fibrinous exudation in anterior chamber. Iris moderately infiltrated, vessels dilated. Lens cataractous. The vitreous is filled with a fibrino-purulent exudation containing small short bacilli with flattened ends, having a great number of spore-like formations, and being arranged in irregular groups. These groups are few in number, and stain well with Weigert's method, but not with Gram's (Plate VI., Fig. 3).

CASE 3.—S. L. æt. thirty-one, right eye perforated by a bit of steel from a hammer, May 2, 1888.

May 3d.—A corneal wound running obliquely inward from the centre of the cornea. Anterior chamber shallow. Cornea diffusely opaque. Pupil small. Traumatic cataract. Poor projection inward and downward. Atropine, ice.

May 4th.—Small hypopyon.

May 8th.—Pupil small in spite of eight drops of atropine ; no pain.

May 18th.—Continued irritation.

May 19th.—Enucleation.

May 23d.—Discharged cured.

Macroscopic Examination.—Lens in position. Considerable yellowish-white exudation of creamy consistence in the vitreous. No foreign body found.

Microscopic Examination.—The exudation in the vitreous is entirely purulent. In the anterior portion there is a colony of bacilli of crescentic form. The bacilli are small and slender, and form dense round groups. In the neighborhood of the colony the vitreus contains many leucocytes. Under a high power the bacilli are seen to be in the interior of the white blood corpuscles. Many leucocytes are completely filled with bacilli, others contain a smaller number, and some are entirely free from bacilli and contain only products of their degeneration in the form of round or oval bodies which stain darkly. The white blood corpuscles which contain bacilli have lost their nucleus. Comparison of these preparations with those stained with hæmatoxylin and according to Weigert shows that it is not a simple capsule surrounding a colony of bacilli (Plate VI., Fig. 4).

The bacilli do not stain with Gram's method, but stain darkly with Weigert's. They are decolorized with difficulty, and it requires frequent changing of the anilin oil, producing a marked decolorization, and the use of very high powers to study them well.

Case 4.—S. C., left eye perforated with a foreign body while standing near a stone which was struck with a hammer, May 27, 1889.

May 28th.—Arched corneal wound, 2 *mm* from outer margin. The iris is pushed forward at this point; small hypopyon; chemosis. Inflammation increased, and eye was enucleated June 4th.

June 10th.—Discharged cured.

Macroscopic Examination.—Eyeball but slightly shrunken. Moderate amount of exudation in anterior chamber. The entire vitreous chamber is filled with exudation, transparent in the anterior superior portion of the ball, elsewhere yellowish-white and opaque. In the centre of the vitreous is a splinter of iron 3 *mm* long and 1.5 *mm* thick, the exudation about it being stained brown.

Microscopic Examination.—The exudation in the anterior chamber is fibrinous. The iris is œdematous and infiltrated with small cells.

The exudation in the vitreous is fibrino-purulent. At one point in the vitreous, in the neighborhood of the splinter, there is a clearer portion (visible macroscopically), surrounded with a purulent zone. In the clearer portion, which is fibrinous, bacilli are found. They are fairly slender, long, arranged in chains and nests, and have flattened ends. The nearer the long chains of bacilli approach the purulent zone the more they lose their regular form and their staining quality; they show a beginning degeneration in the formation of large round bodies of various size, and the chains stain faintly, but still show occasional spore-like formations. Many chains consist of stained and unstained bacilli at fairly regular intervals. Many nests of bacilli are formed exclusively of those which contain spores (Plate VII., Figs. 6, 7, 8).

The bacilli stain only with Weigert's method. Where round cells and bacilli lie near together, the nuclei of the former stain darker and appear degenerated.

Case 5.—R. R., æt. twenty-nine. Splinter flew into left eye while working vines, June 4, 1888, and produced panophthalmitis.

June 13th.—Enucleation.

June 18th.—Discharged cured.

Macroscopic Examination.—Ball scarcely shrunken. Considerable exudation in anterior chamber. The exudation in the vitreous yellow and creamy. Shrinking and detachment of the vitreous.

Microscopic Examination.—Cornea markedly infiltrated with small cells. Anterior chamber contains a dense fibrino-purulent exudation. The iris is moderately infiltrated. The lens is cataractous, and contains a quantity of bacilli, partly in bundles, partly disseminate. Considerable pus in the vitreous, and between the pus cells numerous straight bacilli with somewhat swollen flattened ends. Many of the bacilli are contracted at points, and show in their interior unstained portions, surrounded with a darkly stained protoplasm; many stain only at the ends. The bacilli break up into flat discs; they stain readily with Weigert's method but not with Gram's (Plate VII., Fig 5).

CASE 6.—R. L., æt. forty-eight. A foreign body flew into the right eye while the patient was at work in the vineyard. Three days later, chemosis and injection of bulbar conjunctiva, hypopyon, and pupillary exudation. Toward the caruncle a small white cicatrix. Visual field imperfect. Atropine did not act. The chemosis and injection increased, and the eye was enucleated ten days after the injury.

Macroscopic Examination.—Ball considerably shrunken; slightly yellowish-white exudation in anterior chamber, more in vitreous. No foreign body discovered.

Microscopic Examination.—The exudation in the anterior chamber principally fibrinous, containing blood in its lower portion. The fine fibrine threads stained with Weigert's method form nests and groups which might be mistaken for colonies of bacilli, but under a higher power this is not possible. The vitreous shows a marked round-celled and fibrinous infiltration containing many slender bacilli. The latter are found in all stages of development: spore-formation and degeneration into bodies of various size and different staining quality. The bacilli stain poorly with Gram's method; with Weigert's method they stain well; and only when stained with this method are the finer details of structure seen (Pl. VIII., Fig. 9).

CASE. 7.—K. B., æt. fifty-six, eye perforated by a bit of iron. Beginning panophthalmitis two days later. The following day enucleation.

Macroscopic Examination.—Ball not shrunken; in the anterior chamber a yellowish-white exudation. The entire vitreous chamber filled with a yellowish-white exudation. The small piece of iron was found in the vitreous.

Microscopic Examination.—Cornea slightly infiltrated; anterior chamber contains fibrinous exudation with a few leucocytes; iris œdematous.

Vitreous shows purulent infiltration. The exudation is denser about the spot where the foreign body lay, and contains short, slender, sporing bacilli with flattened ends.

The microscopic picture similar to that seen in Case 1. It was more difficult to find the bacilli in this case than in the

others, since they lay only in the neighborhood of the splinter, and one hundred sections were mounted before the foreign body was found and the bacilli about it discovered. The bacilli did not stain well, and it was difficult to study the finer details even with a Zeiss immersion $\frac{1}{12}$.

CASE 8. M. V. A small splinter of iron flew into the right eye. Two days later cornea opaque, 2 *mm* high hypopyon, 1 *mm* broad ring abscess in the cornea, beginning panophthalmitis; enucleation three days later.

Vitreous contains yellowish-brown exudation and a small splinter of iron near the ciliary body.

Microscopic Examination.—Cornea markedly infiltrated, particularly downward; anterior chamber deep, and containing fibrino-purulent exudation mixed with blood. Ciliary body shows a hemorrhage; iris infiltrated; vessels dilated.

The vitreous is infiltrated with round cells, and contains blood. The exudation is principally purulent. In the anterior section of the ball, near the ciliary body, on both sides, are short slender bacilli arranged in groups in the sanguino-purulent exudation. They are found within a limited area only. Most of them show contractions, and some stain only at the ends. The ends are pointed and round. The bacilli stain well with Weigert's method, but not with Gram's. The retina is totally destroyed.

The choroid is greatly thickened, and its vessels dilated, their walls thickened and of homogeneous appearance. The vessel walls, having apparently undergone hyaline degeneration, stain unusually well with eosin.

In these eight cases microbes were positively found; in four other cases I was unable to discover microbes, in spite of careful searching and the use of all three methods of staining.

The *results* of my studies may be *summed up* as follows:

Eight of the twelve eyeballs examined showed microbes. These were without exception bacilli; and each case showed but a single variety, so that there was never a mixed infection. The bacilli lay always in the medium which con-

tained the foreign body, viz., the vitreous, and in spite of careful searching were never found in the anterior chamber, iris, retina, or choroid. In the vitreous they were confined to a small locality, almost always immediately surrounding the foreign body. The only exception was in Case 8, where the lens also contained bacilli; but since in this case the lens capsule was ruptured, aud the bacilli lay also near the posterior surface of the lens, it is possible that they were carried into the lens with the pus in a purely mechanical manner, and there proliferated.

The important question now arises: In what way do the bacilli get into the interior of the eye?

There are only two possible explanations. Either the bacilli enter the eye with the unclean splinter, and there develop and multiply, and by their biological processes cause panophthalmitis; or the bacilli, present in the conjunctival sac, pass into the eye through the canal formed by the foreign body, and there produce the fibrino-purulent inflammation which has been described.

Opposed to the first of these explanations are the reports of Sattler,[1] who, by Weidmann's[2] statement that splinters from the hoes used in the fields and vineyards were specially pernicious, was led to examine the earth of the vineyards for micro-organisms; he found a great number of bacilli, but none with pathogenic properties. Supported by his examinations, and by the absence of any account of pus-producing bacteria being found in the earth, Sattler rejects the first explanation entirely, and declares the second to be the only explanation tenable from a practical standpoint.

Since, among the microbes normally found in the conjunctival sac, bacilli are present in considerable number,[3] the simplest explanation for my eight cases would be the second.

---

[1] Sattler, Die Bedeutung der Bacteriologie für die Augenheilkunde. Seventh Internat, Congr., Heidelberg, 1888.

[2] Weidmann, Ueber die Verletzungen des Auges durch Fremdkörper. Inaug. Dissert., Zürich, 1888.

[3] Eugen Fick, Ueber Mikro-organismen im Conjunctival-Sack, Wiesbaden, 1887.

Although the absolute proof is wanting, I would however doubt the correctness of such an explanation. Both the fact that bacilli were in no case found in the anterior chamber, and the location and the grouping of the bacilli in the vitreous, are against it. The bacilli do not spread from the path of the foreign body into the interior of the vitreous, but develop uniformly around the foreign body. The objection may be made that the absence of bacilli in the anterior chamber might be explained by the difference in the nutrient medium, since they might be unable to develop here; yet it is questionable whether this point is of importance, and it must have been occasionally possible to discover the bacilli in their passage from the conjunctival sac into the anterior chamber.

Although bacilli were found in all eight cases, and we are accustomed to consider cocci alone as pus-producers, I have considered it self-evident that the bacilli found in the vitreous were the cause of the panophthalmitis, *i. e.*, the producers of the suppuration. It seems superfluous to attempt further to prove the correctness of this opinion, since, although we have little information concerning pus-producing bacilli, my observations are not altogether isolated ones.

Koch in his paper, Examination of Pathogenic Organisms,[1] gives a drawing of an ulcerated spot in the cornea with bacilli heaped up in it, and says: "It is also probable that the ulceration is caused by the immigration of the bacilli." In Sattler's paper already quoted, he reports that he was able to obtain pure cultures of two sorts of bacilli, which inoculated into the cornea produced purulent infiltration and hypopyon. In the same paper he states that Scimemi[2] cultivated a small bacillus which possessed marked pyogenic properties, and was not identical with that discovered by Sattler. Passet's bacillus pyogenes putridus, and Rosenbach's bacillus of putrid suppuration should not be forgotten.

---

[1] Koch, Mittheilungen aus der kaiserlichen Gesundheitsamt, vol. i.
[2] Scimemi, Ricerche batteriologiche sull'ulcera corneale con ipopio, 1887.

Whether the bacilli that I have found are of a single variety, and where they belong in the system of micro-organisms, can only be settled by making pure cultures and inoculations. My examinations show that there were but two sorts of bacilli which caused panophthalmitis in the eight cases: (1) a small slender form with no disposition to chain formation; (2) a large long form. Both forms stain with difficulty with Gram's method, which may partly explain the fact that beyond a short note in Weidmann's[1] paper no reports exist concerning the finding of bacilli in panophthalmitis. A second point is the fact that usually enucleation is not made in panophthalmitis. That the enucleation at this stage, if the wound cavity be thoroughly disinfected as is the custom in the Zürich clinic, is not a dangerous procedure is shown by the results of my examinations, which also explain the reason why it is not dangerous. The mycosis is ordinarily limited; the distant action of the bacilli, through the poisonous substances which they produce, being however very great. This is shown by the development of the hypopyon, and by the affection of the iris and retina. The destruction of the latter by the poisonous products of the bacilli is certainly in many cases of injury by foreign bodies the cause of the quickly appearing amblyopia or amaurosis.

Since eyes injured by foreign bodies very frequently lead to sympathetic ophthalmia, we may conclude that these bacilli in many cases are concerned in this process.

I have not given the measurements of single bacilli, but instead of these I give ten photographs, all of which are magnified four or five hundred diameters, except in Case 2. where the magnification is one thousand. Only after pure cultures have been made can accurate measurement be taken, and an accurate description of the forms be given. These eyeballs lay for a varied length of time in alcohol, and were examined after being stained with different methods, and, besides this, many of the cut sections were kept in alcohol until stained, all of which make valuable

[1] Weidmann, *l. c.*, p. 77. The finding of bacilli in the vitreous by Prof. Haab in a case of panophthalmitis from a foreign body.

measurements impossible. Nor did the comparison of these bacilli with others seem to be advisable. Their relation to the white blood corpuscles, as shown in Figs. 1 and 4, Pl. VI., furnishes the best idea of their dimensions.

The photographs, from which the plates were made, were excellently done by O. Müller, photographer, Zürich.

Explanation of the Figures.

Plate VI.

FIG. 1, CASE 1.—Bacilli lying in the white blood corpuscles. ×500.

FIG. 2, CASE 1.—Bacilli lying free in the exudation, grown to larger form than in the previous preparation. ×500.

FIG. 3, CASE 2.—Very small bacilli (found only in this case) containing granules (spores?). ×1000.

FIG. 4. CASE 3.—Bacilli lying in white corpuscles as in Case 1., and of similiar size. ×500.

Plate VII.

FIG. 5, CASE 5.—×500.
FIG. 6, CASE 4.—×500.
FIG. 7, CASE 4.—×500.
FIG. 8, CASE 4.—×500.

Plate VIII.

FIG. 9, CASE 6.—Bacilli in irregular groups, not lying in the white corpuscles. ×400.

FIG. 10, CASE 1.—Bacilli forming a close network. ×400.

ANATOMICAL CONTRIBUTION TO THE KNOWLEDGE OF THE DEVELOPMENT OF MYOPIA.

By Dr. ALEXANDER KROTOSCHIN, Berlin.

Translated by J. H. Claiborne, M.D., New York.

(With Plate IX. of vol. xxii. of German edition.)

STATISTICAL investigations into the spread of myopia show with great clearness its preponderance in educated circles (Cohn and his following). Above all things, schools are the nests for myopia, and justly so, since the statistics show a continuous increase of myopia among schools, from the lower to the higher classes.

Cohn found in his investigations only 0.4 % of myopia among 10,060 scholars in the first year; in the last, 63.6 %.

Moreover it may be regarded as proved that the number of myopic scholars increase with the increased grade of a school.

In village schools Cohn found 1.4 %, in middle-class schools 10.3 %, in colleges 26.2 % of myopia.

In fact more accurate statistical investigations prove that it is mostly the lower grades of myopia which prevail in educated circles and which become stationary at the end of the period of growth, while the severer forms of myopia, the constantly progressive myopia with complications of eye diseases, such as choroiditis, fluidity of the vitreous humor, and so forth, occur at least just as frequently in uneducated circles and among country people (Tscherning, Weissbach, Leininberg, and others).

Horner and Stilling several years ago almost simultaneously called attention to the fact that it is frequently badly

nourished anæmic people that are affected with excessive myopia, and that cases sometimes occur in practice which clearly show the origin of progressive myopia to lie in severe constitutional illness.

None of the many theories offered for the origin of myopia are satisfactory for all cases. Against each theory there are weighty objections.

The question of the origin of myopia has again been brought into prominence through accurate anatomical examinations of normal as well as myopic eyes, through examinations into the mechanism of the ocular muscles and into the structure of the orbit.

Tscherning was led by his statistical researches to divide those conditions of the eye included under the term myopia, according to symptoms as follows:

1. Physiological myopia due to too great a curvature of the cornea.
2. Acquired myopia due to near work.
3. Progressive myopia depending on hereditary causes.

Stilling's ophthalmometric measurements show that physiological myopia occurs only in rare cases. For even in the lowest grades of myopia a radius of curvature of the cornea is usually found which is greater than that in emmetropes. The few exceptions to this rule rest upon an inherited anomaly of development.

Transitions between both forms of myopia, the acquired myopia and the hydrophthalmia, such as Cohn cites, for example, do not occur. Transitions between a slight deformity caused by outward pressure and an hydropic degeneration of the eye are impossible. That this is so follows from the anatomical examination of eyes of both forms.

In the first group the eyes are sound, showing only one deformity, and that corresponds to the course of the superior oblique muscle.

In the second group a real pathological process is dealt with: the signs of an aqueous degeneration of the eye, a hydrophthalmia, excessive stretching, widening of the anterior chamber, separation of the inner from the outer nerve sheath, enlargement and spreading of the papilla are

found. Retina, choroid, and sclera are pressed fast upon each other in consequence of the increase in intraocular pressure; the choroid exhibits a pressure atrophy, for no inflammatory changes can be shown in the vessels. The macroscopic and microscopic appearances of myopic eyes which has just been described I was able to verify in three cases in possession of Professor Stilling, which I have examined under his supervision.

A myopic eye of high degree, the description of which I shall next take up, was enucleated on account of the lens being spontaneously dislocated into the anterior chamber. It offered the following macroscopic appearances:

Longitudinal diameter . .	33 *mm.*
Cross diameter . . .	27 *mm.*
Vertical diameter . . .	27 *mm.*

The oblique tendon is broad, and runs quite far toward the temple. In cutting through the bulb horizontally, considerable fluid ran out. The vitreous is almost completely degenerated as far as the front part, where there is a clear layer. The outer part of the zonula is torn; the lens is luxated into the anterior chamber.

The sclera is very thin everywhere, the choroid atrophic throughout, the pigment gone.

Microscopic Appearances.—The optic papilla is at least twice the natural size; the scleral canal is wide-stretched, and presents the appearance of a flat dish. The intervaginal space is very much widened toward the temporal side.

The choroid is reduced to a thin skin. The ciliary muscle shows a stretching of its fibres, which extend far backwards. (Table ix., Fig. 1.)

In contrast with this, the two other myopic eyes, taken from an elderly practising physician who died of progressive paralysis, presented a perfectly normal appearance. A myopia of about 6 D had been found during life.

Professor Stilling had the opportunity of examining the orbital section in this case, the record of which he has permitted me to publish.

The orbit was very high on both sides, on the one side

the index amounted to about 100; on the other even more than 100. Likewise the trochlea lay quite high on both sides, and the tendon of the superior oblique came down steep to the ball. Arrived there it wound itself around the ball far towards the temple.

By the contraction of the superior oblique there appeared on either side a plain furrow.

The measurements of the eye were:

LEFT EYE.

Antero-posterior diameter,		25.0 *mm.*
Horizontal	"	24.3 *mm.*
Vertical	"	24.3 *mm.*

The diameters of this eye scarcely departed from those of the normal. 25.0 is a high figure for the antero-posterior diameter, yet it is not an excessive one, since it is sufficiently often found in the cadaver.

RIGHT EYE.

Antero-posterior diameter,		25.5 *mm.*
Horizontal	"	24.3 *mm.*
Vertical	"	24.3 *mm.*

These eyes were hardened in Müller's fluid and in alcohol, and the section was made in the horizontal diameter; the left was imbedded in celloidin, and sections were made from the under half with the microtome.

In the section the eyes did not show the faintest change of color in the hinder part.

The left eye was divided into halves by a horizontal section. The vitreous is of perfectly normal consistence; the sclera of normal thickness, is gradually thickened toward the optic nerve, as in normal eyes, and attains the considerable thickness of 1.3 *mm* at the optic nerve. Not the slightest sign of atrophy of the choroid is to be observed on examination with a magnifying glass. The sclerotic canal and the optic papilla show no striking distortion; the intervaginal space is quite narrow; the outer sheath of the nerve at its insertion only a little weaker than the sclera. The anterior chamber is a little deep, even a trifle narrow.

The lens is in its normal position. The ciliary muscle appears hypertrophic and has the myopic form. The vitreous is perfectly normal in consistence and in the arrangement of its layers.

The temporal half of the ball is clearly widened toward the nose. In the orbital section a slight stretching of the optic nerve was visible on the contraction of the superior oblique.

Examination with the magnifying glass showed that the temporal side of the optic papilla was somewhat steeper than the nasal; also the attachment of the choroid on the nasal side seemed to be drawn a little more pointedly toward the temporal side, and seemed to be on a higher level than the attachment on the temporal side. Exactly the same conditions were found in the right eye. The sclera was 1.0 *mm* thick at the optic nerve.

Microscopic Examination of the Left Eye.—The optic papilla and its surroundings are absolutely normal; the pigment epithelium of the retina comes close up to the optic nerve on both sides; is not piled up; the papilla is not distorted. Only for a very small distance towards the temple the pigment is atrophic.

The ciliary muscle shows with striking plainness the obtuse triangular shape.

The only change, consequently, which is to be pointed out is the very small change in the pigment epithelium towards the temple, a change which is occasionally found more strongly pronounced in eyes that are not myopic. By a more powerful magnifying glass the atrophic change in the pigment epithelium was found in a very small degree towards the nose.

The wall of the scleral canal appears to be a little steeper towards the temple, towards the nose less strikingly so. (Table ix. Fig. 2.)

The right eye was not examined microscopically, since it showed the same appearances macroscopically and under the magnifying glass as the left eye.

As the macroscopic and microscopic examinations evidently show in the first case we have to do with a really diseased eye, in the last two cases with a perfectly sound one,

so that the sharp demarcation between the two forms of myopia already spoken of above is perfectly borne out by these observations.

The clinical course also demands a sharp separation of the acquired myopia from the hydrophthalmia. The former begins at the time of greatest growth and remains stationary at its termination ; the latter is found even amongst children, reaches a high degree in youth, and ends in many cases with the complications of excessive enlargement mentioned above.

Both forms have in common :

(1) The kind of refraction ; in the one form the main thing, in the other a complication of secondary importance.

(2) Hypertrophy of Brücke's fibres in the ciliary muscle.

(3) The sickle-form at the conus ; this has in high-graded myopic eyes another significance in so far as an enlargement, stretching, and spreading of the papilla is added.

[The remainder of the paper is a plea for Stilling's hypothesis. It is based on one hundred new measurements of orbits of dead bodies and the presence or absence of compression of the globe by the tendon of the superior oblique. See the full presentation of this subject in the paper of O. Cohen in vol. xviii., p. 251, etc., of these ARCHIVES.]

Explanation of the Drawings.

Plate IX., Fig. 1.

Highly myopic eye.

R = Retina.
Ch = Chorioidea.
Sc = Sclera.
Lc = Lamina cribrosa.
Spi = Stretched intervaginal space.
Vo = Optic nerve sheath.

Fig. 2.

Eye with myopia of 6.0 D.

R = Retina.
P = Pigment epithelium.
C = Choroid.
Sc = Sclera.
Lc = Lamina cribrosa.

PROFOUND AFFECTION OF THE EYES IN A CASE OF PERNICIOUS ANÆMIA.

By ELIZABETH SARGENT, M.D.,

OCULIST AND AURIST TO THE CHILDREN'S HOSPITAL, SAN FRANCISCO.

THE late Prof. Horner, of Zürich, added much to the knowledge of the clinical changes of the eye in pernicious anæmia, he having examined thirty cases ophthalmoscopically. He found almost always very extensive retinal hemorrhages, and dilated, tortuous veins. He also noticed the marked whiteness of the papilla, in contrast with the rest of the background.[1] But I do not find anywhere in the scanty special literature on the subject, a case in which the eye symptoms were so severe as in the one to be described; hence the detailed account of the general condition of the body, as well as that of the eye.

Josephine C., aged fourteen years, of Irish parentage, was admitted to the Children's Hospital, Nov. 16, 1889, with the following history:

She was the youngest of eight children; her father died of consumption, and one sister died at fourteen years of "heart disease." The mother is intemperate. Of children's diseases she had had whooping-cough and measles. Menstruation began when she was twelve years old, and at first was free and regular, although sometimes painful; it had been very irregular for some months past.

The patient imagined that she had been strong and healthy until a few weeks previous to her admission to the hospital, at which time she lost her appetite, and began to feel tired and dizzy, sometimes falling down unconscious. Upon close inquiry, it was

[1] "Handbuch der gesammt. Augenheilkunde," Graefe and Saemisch, p. 604.

found that for three years she had probably been insufficiently nourished, as during that time she never felt as if she had had enough to eat; however, this feeling may have been due to malassimilation, rather than to insufficient food.

Stat. Præs.: Skin waxy-white, lips and mucous membranes colorless, adipose tissue well-developed, bowels irregular, urine normal. No test for urobilin was made. Blood drawn from a finger looked watery and of a very pale color; very few blood corpuscles were seen in the microscopical field, but there did not appear to be any abnormal disproportion between the red and white corpuscles; no exact measurements were made. The red corpuscles did not form into rouleaux, and many of them were unusually small, and irregular in outline.

Physical Examination: Apex beat of the heart in the fifth intercostal space in line with the nipple; roughness with the first sound, and murmurs, probably anæmic, heard all over the chest. Dulness over the whole left lung; on the right side the respiratory murmur normal. Breathing shallow, and easier in recumbency. Liver and spleen dulness normal, and no tenderness over either. No enlargement of the subcutaneous lymphatic glands. The history of the case mentions no examination of the bones as to tenderness to pressure. Frequent bleeding from the gums. The patient was examined by me for the first time on Nov. 26th, at the request of Dr. Agnes Lowry, under whose charge she was. Both eyes were affected to a similar degree:

The palpebral conjunctiva pale, the ocular conjunctiva and the sclera strikingly white; cornea clear. The pupil is dilated, but not ad maximum, and reacts sluggishly; reflex from the fundus very pale red; the refractive media clear. The optic papilla remarkably prominent, with undefined outlines, and no vessels visible upon it; the retina of an opaque, bluish-white color, with knuckles of tortuous veins to be seen here and there; also numerous hemorrhages, some quite large. She could read large print only (Snellen, 1.5) at a short distance, but did not remember when vision first began to be defective.

December 10th: The patient complained of headache, and pain in the right side of the abdomen. The condition of the eyes was about the same.

December 22d: Having said that she did not see any more, it was discovered that vision was actually limited to distinguishing between light and darkness. Upon examination with the opthal-

moscope, it was impossible to see the fundi. By transmitted light, there was no reflex at all,—the interiors of the eyes having the appearance of a chamber filled with impenetrable darkness. Copious hemorrhage into each eye was suspected, but oblique illumination failed to verify this supposition.

December 28th: Paralysis and other symptoms resembling those of pressure on the brain appeared. There were also profuse hemorrhages from the mucous surfaces.

The patient died on Dec. 30th, and twenty-four hours after death the autopsy was performed by Dr. D. W. Montgomery, at that time Pathologist to the Children's Hospital. His report was as follows :

On the left side of the neck, below the angle of the jaw, over the sterno-cleido-mastoid muscle, there is a brown patch. The skin is also irregularly pigmented to the right of the thyroid cartilage, extending to the s.-c.-m. muscle. On the right side of the neck, extending up to the hair-line, is a patch of leukoderma, and over the right occipital region loss of hair pigment. The skeleton is well-formed. On the right leg and arm there are ecchymoses.

Over the abdomen the adipose tissue is two inches thick ; no fluid in the abdominal cavity ; the stomach prominent.

A small quantity of fluid is present in the pleural cavity. There are no adhesions on the right side, but the left pleura is adherent throughout. The pericardium contains about one ounce of fluid ; ecchymoses over the visceral pericardium. The right side of the heart is filled with fluid blood, a large, tough clot being also present in the right ventricle ; the valves of both sides are competent ; ecchymoses in the tricuspid. There are hemorrhages into the pleura, and also into the pulmonary tissues. The left lung is one third normal size, and is collapsed and solidified ; the right lung is normal. No cavities are present.

The mucous membrane of the stomach shows a few ecchymoses ; no atrophy. The spleen is normal in size ; there are two accessory ones the size of a pea and of a chickpea, respectively. The suprarenal capsules are normal. Both kidneys are pale ; their capsules not adherent. The pancreas is normal. The liver looks very pale and bloodless ; bile duct pervious. The bladder presents nothing abnormal. Ecchymoses are present in the right ovary ; uterus normal.

The convolutions of the brain are normal. There are small

hemorrhages into the pia mater, one two inches behind the fissure of Rolando; also hemorrhages into the lower surface of the left temporal lobe. In the anterior perforated space there is a small clot. The optic thalami are pale. The right eye removed for examination by Dr. Sargent.

The enucleated eye was hardened in Mueller's fluid, divided horizontally into halves, and imbedded in celloidin. The first thing noticeable *macroscopically*, besides the total retinal detachment, was the size of a hemorrhage into the retina, situated five millimetres from the ora serrata, and which was found to measure four millimetres in length, and one millimetre in width at the middle, gradually tapering off at each end. Microscopical examination shows the following condition of the various structures:

In three of the specimens a hemorrhage is to be seen in the posterior layers of the cornea near the sclero-corneal junction; otherwise the cornea is normal. The vessels of the sclera are markedly empty. The anterior chamber is filled with an amorphous, granular substance, probably serous exudation; the angle of the anterior chamber is roomy and Schlemm's canal patent. The lens, with the exception of a few vacuoles in the posterior part, is healthy. The uveal tract, including iris, is entirely free from signs of inflammation; the vessels are empty. On one side the retina, although completely detached, lies near the choroid; on the other side, where the most copious hemorrhages took place into the substance of the retina, the distance between choroid and retina amounts macroscopically to eight millimetres; this whole space is filled by a homogeneous, granular substance, similar to the exudation in the anterior chamber, and contains no cells or formed elements. The large hemorrhage is present in fourteen consecutive sections of one millimetre thickness, of greatest size in six of them, while the immense detachment extends from top to bottom of the eye on that (the outer) side. Numerous small extravasations are to be seen throughout the whole extent of the retina, some of recent date. At the sites of the largest hemorrhages the layers of this membrane (see page 45) are separated and disorganized, the retina being stretched in places to four

times its ordinary width. In some parts there are diffuse-looking masses of dark yellowish-brown pigment, evidently the remains of old extravasations, in which no definite granules or cells are to be made out. In addition, large, bright-yellow, granular lumps of pigment, oblong or irregular in shape, are arranged in large and small groups, or scattered singly through the retina. These accumulations are sometimes in the neighborhood of a small vessel, but seem, in general, to originate at the sites of old extravasations. In some of the capillaries there are a few blood corpuscles, and numbers of the bright-yellow granules; but the vessels are, in the main, empty. Finally, there are small, round, yellow, highly refracting bodies, which may be either pigment granules or fat globules. They are probably not the latter, since they have not been dissolved by the ether and alcohol.

Moissey Mühlmann[1] believes that a combination of stagnation of blood, with inflammation of the capillary wall, is necessary for the production of hematogenic pigment metamorphosis. In the case in question one element, at least, existed during life for the production of the pigment, *i. e.*, stagnation of the blood in the vessels; but after repeated careful inspection of the capillaries and larger vessels I have been unable to detect any changes in the vascular walls. In only a few specimens is there an artery, in the midst of an extravasation, which is occluded by a hyaline mass of a yellow color. The staining material used was alum-carmine. Mühlmann's experiments were made upon the capillaries of fresh specimens of the arachnoid of the brain, in which the evidences of inflammation could be seen. The pigment granules passed through the walls by diapedesis upon slight pressure of the cover glass, and ranged themselves along the capillaries externally, thus indicating the presence of a sticky exudation. The limits of this paper prevent my going more deeply into this part of the subject.

Hyperplasia of the connective-tissue elements is present, projecting as wave-like eminences into the vitreous space.

[1] Zur Pigmentmetamorphose der rothen Blutkörperchen, Virchow's *Archiv*, Bd. 126, 1891.

In parts of the retina near the equator, corresponding to the inner granular layer, and encroaching upon the nervous layer, Mueller's fibres are pushed apart so as to form large cavities, some containing serous exudation, others hemorrhages. In the immediate neighborhood of the papilla the granular layers have been stretched by the œdema into a reticular tissue. The granular layers are, however, fairly well preserved in many places. Cystic degeneration is also present in the ora serrata. The nervous layer is atrophic.

The layer of rods and cones has undergone cystic degeneration throughout. This layer is bounded externally by a highly refracting substance, ranging in color from yellow to yellowish-brown, which is perfectly homogeneous, except in a few places where it passes into a row of large, shining, opaque, nucleated cells, some of these cells being visible as far along as the optic-nerve entrance. The hyaline degeneration is confined to the middle section of the eye, gradually disappearing above and below the level of the papilla. The pigment layer is detached and lies against the choroid in the middle section, in which situation is seen a hyaline degeneration resembling the "Drusen" described by German writers. Specimens taken from beyond the middle zone show this layer lying free and the cells in a good state of preservation. The optic disc is greatly swollen, being two millimetres high (macroscopically) where it goes over into the retina. A small V-shaped depression, filled with delicate connective tissue, in which are visible a few leucocytes containing nuclei, and minute capillaries, can be seen in all of the specimens of the nerve. Some of the vessels in the optic nerve and swollen peripapillar portion of the retina, although themselves empty, are surrounded by lymphoid cells, but this was observed in four specimens only. The main trunk of the opthalmic artery in one specimen contains granular debris, a few blood corpuscles, and the yellow, highly refracting globules mentioned as occurring in the stroma of the retina. The nerve fibres beyond the scleral ring are compact and very little, if at all, changed. Where the nerve passes over into the retina, on each side, there are some cysti-like openings.

The vitreous is quite well preserved, and presents a fibrillated, wavy appearance, free from inflammatory products, except at the posterior pole, where it is infiltrated by some nucleated leucocytes; and at one place in the periphery where there is a small group of leucocytes and yellow pigment granules.

In teased-out specimens the blood corpuscles composing the large retinal hemorrhage, above mentioned, floated about in the field of vision, and, although most of them were normal in shape, many were noticeably irregular in outline, some having the shape of a kidney bean, just as was remarked in the blood examined during life. Very large red blood corpuscles, as well as minute bi-concave discs and small globules (the microcytes of various authors), were also to be seen.

The changes in the eyes seem to have been due in great part to the œdema and extravasation caused by the general lowered vitality of the vascular system, the inflammation being secondary and circumscribed. The final extinction of vision previous to death was probably caused by copious serous exudation and fresh extravasations.

Judging from the condition of the child when admitted to the hospital, and the extreme retinal changes, one would be led to think that the disease must have been in progress for a long time before she was made aware of it by the occurrence of symptoms of final dissolution.

Dr. Montgomery kindly placed at my disposal for microscopical examination portions of the consolidated lung, the heart, the liver, and the kidney. The changes in the lung tissue—œdema, and dilatation of the alveoli; some of the alveoli contain hyaline globules resembling those found in the lens and choroid in degenerative changes. Portions of each ventricle, and one of the columnæ carneæ of the right side, were examined, and show no abnormality. The kidney is perfectly normal, except for œdema. The uriniferous tubules are filled by a serous exudation, but there is no fatty degeneration of the epithelium. The sections of the liver show that organ to have been in a healthy condition. The blood-vessels, great and small, are empty, in correspondence with the extreme pallor noticed at the autopsy. No fat

granules are to be seen, even under high powers. The absence of fatty degeneration of the various organs, as usually observed in pernicious anæmia, seems singular. (Pepper,[1] Eichhorst,[2] Klebs[3]) Dr. J. West Roosevelt,[4] of New York, reports three cases in which the organs were found to be normal.

Bearing upon the subject in hand, there recently came to my notice a paper upon "The Pathology of Pernicious Anemia," by Drs. J. P. Crozer Griffith and Charles W. Burr, of Philadelphia, read at the meeting of the Association of American Physicians in Washington, D. C., September 24, 1891.[5]

Drs. Griffith and Burr examined the viscera of patients dying of various diseases, particularly those connected with forms of anæmia. The results of their observations agree perfectly with those of Hunter, and show that although small quantities of iron, without special arrangement, occur in the liver in other forms of anæmia, pernicious anæmia is distinguished by the presence of enormous quantities of iron deposited in the hepatic cells in a characteristic manner.

Following one of the methods they had employed, I tried the effect of solutions of potassium ferro-cyanide and hydrochloric acid upon sections of the liver, kidney, and the eye, from the case I had been studying. The specimens were taken out of alcohol, well washed in water, placed in a strong solution of potassium ferro-cyanide for fifteen minutes, then left in a 2-per-cent. solution of hydrochloric acid the same length of time, after which they were dehydrated and mounted in balsam in the usual way. Sections of liver treated in this way exhibit the Prussian-blue reaction, and, when examined microscopically, show the presence of blue granules in the *outer and middle zones* of the hepatic cells, the inner zone remaining free—in unison with the verification of Hunter's observations by Drs. Griffith and Burr. Sections of the kidney show scanty deposits of iron here and

---

[1] Progressive Pernicious Anæmia, *Am. Jour. Med. Sciences*, Oct., 1875.
[2] "Handbuch der spec. Pathologie und Therapie," 1885.
[3] "Algem. path. Morphologie," 1889.
[4] *Medical Record*, April 14, 1888.
[5] *Medical News*, Oct. 17, 1891.

there in the tissue of the kidney, not in the tubules; but the greater portion is entirely free from coloration. In contrast to the reaction mentioned above, sections of the liver from a patient of Drs. Montgomery and H. M. Sherman, of this city, who died of carcinoma of the duodenum associated with extreme anæmia, show no Prussian-blue reaction when tested with the above reagents. Microscopically, the cells around the central veins are found to be occupied by a dark-brown pigment, while only a few blue granules are seen scattered about, without definite arrangement. As regards the sections of the eye in my case, it was noticed that after subjecting them to the reagents, a strip of the retina two millimetres long, just beyond the large hemorrhage, was intensely colored, the rest of the retina up to the opposite end being more faintly stained here and there. The other parts of the eye were free from coloration. Microscopically, the deeply stained strip shows the retina in that situation of a diffuse blue hue, with intensely blue granules of large size, corresponding to the large yellow pigment granules found in the same place in sections stained with alum-carmine. Scattered about sparsely through the rest of the retina are the same blue, previously yellow, granules, proving them to be deposits of iron. Within the bounds of the large hemorrhage there is no staining at all; this fact, together with the good state of preservation of the blood corpuscles, would go to prove this hemorrhage of very recent date. Finally, there was also no staining of the diffuse masses of dark, yellowish-brown pigment.

JEQUIRITY A PERFECTLY SAFE REMEDY.

By CHAS. E. MICHEL, M.D.,
PROF. OF OPHTHALMOLOGY, MO. MED. COL., ST. LOUIS, MO.

IT being our duty to give to the profession, for the good of all, whatever knowledge or experience may appear to us worthy of note, that others may test and pass upon its merits, I am induced to record my experience in the use of the jequirity bean. At one time the current literature teemed with articles *pro* and *con*, and when the heat of discussion had subsided, there were some points upon which the majority had not yet agreed, more especially the degree of danger attending its application to the conjunctiva. Are we to conclude that, appreciating its value, and having become expert in its employment, the drug has gradually passed into the list of standard remedies of the ophthalmologist; or is there a tendency on the part of the majority, because of its apparently irregular action, and supposed danger, to use it seldom and with apprehension, thus allowing it to pass into disuse? The writer fears that this last is the case; many no doubt prefer to have recourse to other apparently safer means to obtain what this invaluable agent can and will do expeditiously and with perfect safety, provided it be properly used. My experience with jequirity commenced soon after its introduction to the profession. I saw it used in De Wecker's clinic in the summer of 1884, and immediately upon my return in the fall, commenced its employment, impressed both by its wonderful curative effects in certain cases, and also by the terrible accidents which occurred in the practice of some able men. I determined to test the remedy for myself, and adopted a *modus operandi*

which proved so satisfactory, that I have had no occasion to modify it in any way. I have used the remedy freely in two very large public clinics, and in my private practice; my assistants, Drs. Wolfner and Lebeau, have also done the same, and yet we have not had a *single* accident to record, nor seen an eye impaired in any way. Very rarely did the reaction cause any anxiety, it being always under good control. Only ordinary precautions have been taken to exclude notoriously inappropriate cases. I have come to regard the application of jequirity infusion to the eye as devoid of danger, and am firmly convinced that where accidents have occurred, they have been due chiefly, if not entirely, to an over-dose of the remedy. Of course there may be danger if grossly misused, or if idiosyncrasy exists. I can recollect not more than two or three cases where I deemed it prudent to attempt to reduce the jequirity inflammation, and in none of them was it continued longer than twenty-four hours. Cold medicated applications were used.

Have made by a careful druggist a four per cent. maceration of the bean in cold water, allow it to stand twenty-four hours in a cold place, then decant until a semi-milky fluid is obtained. If kept in a cool place the infusion will exert its full effect as long as its fresh acrid flavor persists—four to six days. After that a taint of decomposition sets in which renders it unfit for use. There is no hurry needed in cases where jequirity is indicated; they are chronic. Why not then use this potent remedy with the same precautions that we observe in the hypodermic injection of strychnia, for instance? With that remedy, for patent reasons, we commenced with apparently unnecessarily small doses, as applied to the vast majority of cases, and moreover dose and inject it ourselves, after taking note of the effects obtained; but patients have too often been given the jequirity infusion to drop in the eye a given number of times until seen again, when too late it is discovered that an overdose has been used. I hold that it is to the injudicious application, and too frequent repetition of perhaps unnecessarily strong infusions, that the majority of accidents have been due, for I have repeatedly seen, twenty-four hours after the instillation of a single drop of a four per cent. infusion, the fullest

jequirity inflammation. A more free use of it in these cases would no doubt have been followed by those accidents so commonly reported as caused by the remedy, whereas an overdose would truly have been the source of trouble. To neither patient nor friends can the application of jequirity, or the hypodermic injection of strychnia be entrusted; only the skilled ophthalmologist, or the skilled assistant, should attend to this delicate procedure, and I speak advisedly, for several serious mistakes can be made, as will be seen. Shake the bottle, then seizing the eyelashes of the upper eyelid, pull the lid away from the globe, and instil a single drop of the infusion, allowing it to flow freely over the globe to the superior cul-de-sac, and then to the inferior one for about thirty seconds, after which the patient must not rub the eyes. The case is seen twenty-four hours later, and in about five per cent. of the cases a characteristic jequirity action is obtained, with indications of commencing formation of the so-called false membrane; generally, however, there is only free lachrymation, and a reddened conjunctiva, as in commencing cases of mild conjunctivitis; if this be marked, another similar instillation is made, but if the reaction is deemed insufficient, two drops are instilled, and the lids gently rubbed for a few moments over the globe, and the patient seen twenty-four hours later. This suffices in a large number of cases. A third application of the same kind is made if somewhat more action be needed, but if only a slight effect has been produced, we feel secure that no intolerance of the remedy exists, and proceed to regular inoculation, which never fails, unless it be in some cases that have been recently subjected to the jequirity treatment. Wrap a piece of cloth over the tip of the forefinger, and dip it freely into the infusion, then turn the lids and rub the indolent conjunctival surfaces more or less forcibly, so as to remove some of the epithelium. In very chronic cases, rub also as much of the globe as can be reached; a few quick brushes of the finger will be borne well enough without cocaine, which may be previously applied. Jequirity is too valuable a remedy to be neglected by even a small proportion of ophthalmologists, and if the above precautions be observed none need fear accidents from it.

A STATISTICAL REVIEW OF THE PROPORTION AND CAUSE OF BLINDNESS IN THIRTY-TWO THOUSAND EYES CONSECUTIVELY TREATED IN THE JEFFERSON COLLEGE HOSPITAL.

By HOWARD F. HANSELL, M.D., and JAMES H. BELL, M.D., Philadelphia.

THE object of this paper is to place before the reader, in brief space, the proportion and cause of blindness occurring in a hospital unusually rich in the abundance and variety of the material presented, and to notice certain features of peculiar and distinctive interest to the profession of this country. We say peculiar and distinctive interest, because statistics of a like character gathered from European clinics, which have hitherto published in large measure the estimates upon which our conclusions have been based, are not reliable guides in the study of disease as it is manifested on this side of the Atlantic.

Our traditional dependence on European clinics for statistics is due in part to habit and an indefinite sort of policy of acceptance, and in part to the fact that we have been until recently unable to furnish any adequate substitute for their authority. It is easier, and in every way more agreeable, to approve and appropriate the tedious and mechanical arrangement of supposed permanent and universal relations bearing upon the subject which happens to be under discussion, than to make such work original and possibly disturb the repose of accepted so-called facts.

These declarations are not meant in any way to deny the value and sufficiency of European statistics for the purposes of European medicine, of which they form a just and vital

part, but rather to direct attention to the fact, too often disregarded by American writers, that an *unqualified* acceptance and application of such statistics to American medicine have the practical effect of ignoring the considerable difference in *type* and *relative frequency* of disease which are the results of widely diverging climatic and social conditions.

The data herein given were obtained from reliable records of cases recently treated in the Jefferson College Hospital under Prof. Wm. Thomson. In presenting them to the reader we have purposely avoided reference to pre-existing statistics upon the same subject, not with a view to saving ourselves the small labor of reviewing easily accessible material, but in order that we might not even unconsciously make results conform to accepted standards, and thus destroy any value the paper might otherwise possess.

TABLE I.

The proportion of blind to the whole number of eyes examined, and the proportion of blind in one and both eyes to the whole number of blind eyes:

Total number of eyes examined	32,000
" " " blind eyes	586
" " " patients blind in one or both eyes	505
" " " patients blind in one eye	424
" " " " " " both eyes	81

It will be seen from this table that the proportion of blind eyes to the whole number of eyes examined is 1.08 per cent., and that of the total number of blind eyes, nearly 84 (83.96 + %) per cent., involved one, and about 16 (16.03 — %) per cent. both eyes of patients. That is to say, that in 16,000 patients treated, only 81 were blind in both eyes.

TABLE II.

The proportion of blind eyes in males as compared with females, the ratio in which the two great classes of causes, surgical and medical, stand to one another, and the proportion of blindness in right and left eyes without division of sexes:

Total number of blind eyes in males	410 = 69.96 %
" " " " " " females	176 = 30.03 %
" " " eyes blind in males from surgical causes	205 = 34.98 %
" " " " " " " " medical "	182 = 31.06 %
" " " " " " females " surgical "	55 = 9.38 %
" " " " " " " " medical "	128 = 20.82 %
" " " right eyes blind	286 = 45.73 %
" " " left " "	318 = 54.26 %

TABLE III.

The relation of age to the liability to blindness:

1st decade,	males 19,	females 32,	total	51 =	8.89 %
2d "	" 54,	" 25,	"	79 =	13.48 %
3d "	" 109,	" 27,	"	136 =	23.20 %
4th "	" 70,	" 25,	"	95 =	16.21 %
5th "	" 60,	" 15,	"	75 =	12.79 %
6th "	" 40,	" 27,	"	67 =	11.43 %
7th "	" 49,	" 18,	"	67 =	11.43 %
8th "	" 6,	" 5,	"	11 =	1.89 %
9th "	" 3,	" 2,	"	5 =	.85 %

TABLE IV.

The specific causes, irrespective of age, sex, or other relation, in the order of their frequency. Under traumatism are included all causes of injury not otherwise specified:

Per cent. of	Traumatism	to whole No. of blind eyes, 22.18
" " "	Glaucoma	" " " " " " 11.43
" " "	Phthisis bulbi	" " " " " " 6.58
" " "	Atrophy optic n. from unknown cause	" " " " " " 4.94
" " "	Atrophy optic n. (specific)	" " " " " " 4.77
" " "	Panophthalmitis	" " " " " " 4.26
" " "	Infective diseases	" " " " " " 3.92
" " "	Atrophy optic n. (non-specific)	" " " " " " 3.65
" " "	Leucoma adherens	" " " " " " 3.58
" " "	Gunshot wound	" " " " " " 2.90
" " "	Unsuccessful cataract operation	" " " " " " 2.73
" " "	Chronic iritis	" " " " " " 2.56
" " "	Anterior staphyloma	" " " " " " 2.38
" " "	Detachment of the retina	" " " " " " 2.21
" " "	Malignant myopia	" " " " " " 1.70
" " "	Tumor of ball	" " " " " " 1.36
" " "	Congenital defects	" " " " " " 1.21
" " "	Gonorrhœal ophthalmia	" " " " " " 1.21
" " "	Atrophy optic n. from spinal disease	" " " " " " 1.02
" " "	Chorio-retinitis	" " " " " " 1.02
" " "	Foreign body in eye	" " " " " " .85
" " "	Alcohol and tobacco amblyopia	" " " " " " .85
" " "	Dislocated lens	" " " " " " .85
" " "	Optic neuritis (post ocular)	" " " " " " .69
" " "	Atrophy optic n. from choked disc	" " " " " " .69

Per cent. of Sympathetic ophthalmia	to whole No. of blind eyes,	.69
" " " Atrophy optic n. from dysentery and diarrhœa	" " " " " "	.69
" " " Tumor of orbit	" " " " " "	.51
" " " Necrosis of cornea	" " " " " "	.51
" " " Albuminuric retinitis	" " " " " "	.34
" " " Embolism central retinal artery	" " " " " "	.34
" " " Retinal hemorrhage	" " " " " "	.34
" " " Retinitis pigmentosa	" " " " " "	.017

TABLE V.

Causes which have resulted in binocular blindness, with the number of cases as compared with the whole number affected from each cause respectively in the order of their frequency:

Atrophy optic nerve	Whole No.	72	Binocular 21
Glaucoma	" "	67	" 12
Traumatism	" "	123	" 7
Phthisis bulbi	" "	38	" 6
Leucoma adherens	" "	21	" 4
Gunshot wounds	" "	14	" 3
Chronic iritis	" "	15	" 3
Atrophy optic n. (spinal disease)	" "	6	" 3
Atrophy optic n. (choked disc)	" "	4	" 2
Toxic amblyopia	" "	5	" 2
Congenital defects	" "	7	" 2
Unsuccessful cataract operation	" "	16	" 1
Optic neuritis (post ocular)	" "	4	" 1
Malignant myopia	" "	10	" 1
Panophthalmitis	" "	25	" 1
Chorio-retinitis	" "	6	" 1
Anterior staphyloma	" "	14	" 1
Necrosis cornea	" "	3	" 1
Atrophy optic n. following dys. and diar.	" "	4	" 1
No history	" "	16	" 1

EXPLANATORY.

We have considered an eye as blind when the vision was reduced to counting fingers at two feet, light perception or absolute darkness conforming to the usual acceptation of the meaning of the word.

All the cases here recorded as blind were incurable. Not one has been included in these tables which offered the slightest prospect of alleviation by glasses, by medical treat-

ment, or by surgical interference. The reader might justly infer from scanning the list of causes that improvement of vision were possible in some; for example, "malignant myopia," and "chronic iritis." In the former, deterioration of the retina and choroid through gross anatomical changes precluded the possibility of increased visual acuteness through a correction of the refraction. In the latter, the anterior section of the ball was so changed from the normal condition by exudation, atrophy of iris and ciliary body, capsular and lenticular cataract, or secondary glaucoma, that the cases were regarded as hopeless. Moreover, eyes which showed a chance, however slight, of regaining in the future, however distant, any portion of sight, were excluded from the above enumeration.

The most noteworthy features exhibited by these tables are:

1. The extremely low proportion of blind eyes to the aggregate of eyes examined. It must be remembered, in explanation, that a hospital is not an institution for the hopelessly blind, but the curably blind.

2. That the liability to blindness in males is 100 per cent. greater than in females.

3. That the per cent. of males blinded from surgical causes is but slightly higher (3 per cent.) than from medical causes, but that in females eyes blinded from medical causes are greatly in excess.

4. That the left eye is 10 per cent. more frequently the seat of fatal disease than the right.

5. That the third decade (20–30 years) of human life far exceeds all others in furnishing subjects of disease or injury fatal to sight.

6. That traumatism, including unsuccessful cataract operation, gunshot wound, foreign body in the ball, and dislocated lens, was responsible for nearly 30 per cent. of the total number of the cases of blindness.

OBJECTIVE STRABISMOMETRY.

By ERNEST E. MADDOX, M.D., Edinburgh.

WHEN diplopia exists, or can be easily elicited, the measurement of squint is a simple matter, for the calculation can be made at once from the distance between the two images. Perhaps the easiest way of making the observation is to use the test I have elsewhere described,[1] which sometimes elicits diplopia when other means fail. It consists of a short piece of glass rod, mounted against a slit in a circular piece of metal, of such a size as to fit into an ordinary trial frame. A candle placed opposite the centre of a scale on the wall is then looked at from a distance of five metres, with the glass rod held horizontally before one eye. A vertical line of light is seen, crossing that figure on the scale which measures the duration.[2]

In the great majority of long-standing squints, however, diplopia cannot be elicited, owing either to monocular amblyopia, or to physiological suppression of the image in one eye. Objective tests are therefore on these cases the only ones possible; and even where diplopia exists, it is well to confirm the subjective test by a rapid objective one, to guard against the occasional fallacy of a false projection of one of the images. But, fallacies apart, objective tests are not to be compared for *accuracy* with subjective ones.

The old "linear" tests, such as marking the deviation

---

[1] Dr. Berry was kind enough to exhibit the test for me at the Berlin Congress. An account of it will also be found in the *Ophthalmic Review* for May, 1890.

[2] This scale can be obtained from Curry and Paxton, 195 Gt. Portland St., London. They also supply the rod-test for half a crown.

with ink on the lower eyelid, or the use of Laurence's strabismometer and its numerous allies, have quite gone out of favor, not being so sound in principle as "angular" measurements. Of these latter, the perimeter method is almost as old as the perimeter itself. It is, I believe, still, the most accurate of the objective tests, though sometimes difficult, especially with young children, and far too slow in execution to meet clinical requirements, since it needs careful adjustment of the patient's chair and chin. For the measurement of so common a thing as squint, rapidity is a *sine qua non.* For these reasons, the perimeter, though admirable in theory, is not in frequent use. To measure a squint by it, the squinting eye should be placed in the centre of the arc, which lies horizontally on that side towards which the squinting eye looks. The fixing eye should look over the arc at a distant object in the direction of a line passing from the centre of the squinting eye above the pivot of the arc. A candle or lighted taper is then made to traverse the arc till its image on the cornea, as seen by the observer's eye just behind the candle, occupies the same position that it does when the fixing eye is correct and the squinting eye is made to look at the candle. Generally, however, the centre of the cornea is taken as giving sufficient accuracy, or this measurement is first made and then that for the angle α which is added or subtracted as the case may be.

A very simple method of guessing approximately the degree of a squint was introduced by Hirschberg in 1886, though it does not appear to have been taken up by others, at least in this country. He seeks to measure the squint at a glance by holding a lighted taper in front of the patient in the median plane, about twelve degrees off, and in this way divided squints into five groups or grades, according to the position apparently occupied by the corneal image, in reference to the iris and cornea of the squinting eye, supposing the pupil to be of medium size (35 *mm*). In his first grade the image of the flame lies nearer the centre of the pupil than its margin. In the second grade, on the margin or near it. In the third, about half way between the margin of the pupil and that of the cornea. In the fourth, on the margin

of the cornea; and in the fifth, on the sclerotic. He also made rules for the operative treatment of the different grades, but this of course is not desirable, for the accommodative element is thus left out of account. A high squint does not necessarily need a strong operation, or even one at all, if the accommodative element is large, and the desire for single vision not abrogated. Moreover he did not in his paper take account of the occasional difference in the angle α in the two eyes, a difference sometimes great enough to come under his first grade of squint. The pupil too is not a very reliable index, being subject to physiological anomalies of position: it may be eccentric in any direction, though it is generally so inwards. Still, Hirschberg's method is, I find, of great service with babies, and when it is the only available mode of measuring. He attached a definite angular value to each of his five grades, but the fallacies are too great to attempt such refinement. The broad generalization given by his assistant, Cl. Dubois-Reymond, will be found quite sufficient, viz., that if the image appear within the area of a medium pupil the squint is from 0° to 20°. If it appear over the iris, from 20° to 45°. If on the sclerotic, more than 45°.

A difference in the amount of the angle α in the two eyes is generally associated with a difference in refraction, but it may exist independently of this, as in a case where the refraction was equal in the two eyes, yet I roughly measured 4° for the angle α in one eye, and 7° in the other. Any fallacy on this score may easily be guarded against by covering first one eye, and then the other, to note whether the corneal image in each occupies the same relative position. The flame should, for this purpose, be held, as nearly as possible, in the line between the observing and the observed eye.

Quite an advance in strabismometry was made by the introduction of Mr. Priestley Smith's method in 1888. He uses two tapes, each one metre long, joined by a ring, which the surgeon holds by his forefinger or the handle of his ophthalmoscope, when the patient is seated as for retinoscopy. The patient is instructed to hold the farther end

of one of the tapes against his temple, while the other tape with a small weight at its extremity runs between the fingers of the surgeon's free hand which forms the fixation-object. The light is now thrown by the ophthalmoscope upon the undeviating eye to note the physiological eccentricity of the corneal image upon the cornea, while the patient fixes the mirror. The patient is then told to look steadily at the surgeon's free hand, and it is moved to the right or left with the tape running through it, till the corneal image on the squinting eye occupies a position corresponding to that formerly noted on the other. This method is far quicker than the perimeter, and, though not quite so precise, much more useful. I am indebted to Mr. Berry for suggesting how by dividing the length of the tape or string used by the interocular distance we get a fair idea of the squint in metre-angles; and also for suggesting the importance of testing for concomitancy by repeating the test with the patient's head 30° to the right and left successively. He pointed out that Priestley Smith's method presupposes concomitancy, and therefore is not suitable in testing the operative effect after squint operations, since concomitancy does not then exist. This difficulty, however, is easily overcome by telling the patient to keep following the surgeon's hand with his face as well as his eye. Since Priestley Smith's method only needs an ordinary tape measure, in addition to the ever-present ophthalmoscope, it possesses advantages over any method which requires apparatus.

For hospital and consulting-room work the following method will, I think, be found useful, since to some extent it combines the accuracy of the perimeter with the speed of Priestley Smith's method.

On the wall is a horizontal board with a candle in the centre, and marked to the right and left therefrom in metre angles, or degrees, or both, for a distance of one metre. The figures to the right are black, and those to the left red. A string one metre long is fixed by one end to the centre of the board. The patient is placed opposite the candle at the distance of one metre, the string being raised to meas-

ure the distance, and then being allowed to drop. Children are made to stand upon a chair. First, while the patient is told to look at the candle, the observer places his own head a little lower than the imaginary line from the candle to the patient's squinting eye, but in the same vertical plane with it, so as to look into the said eye from the distance of about a foot. At once the amount of squint is roughly guessed by the position the neglected image of the candle occupies on the cornea, by Hirschberg's principle. The sound eye is then covered to let the squinting one look at the candle; while it does this the position of the corneal image is carefully noted. Now the best eye is again uncovered and the patient is told to look at the number on the board which we have guessed at as probably being the measure of the squint. If the guess be right the corneal image will now occupy the same position on the squinting eye that it did when the best eye was covered, and the squinting eye was fixing the flame; should the guess be short of the mark, he is told to look at the next figure, or the next still, or should it be over the mark, he is directed to a figure less. The figure settled on gives at once the measure of the squint in its primary deviation. Should it be desired to measure the secondary deviation, it is easily done by covering the fixed eye with the hand, so as to turn the squinting eye into a fixing one. The patient is now told to look at the same number, but on the opposite side of the candle, as that which measured the primary deviation. On momentarily uncovering the covered eye the corneal image will be seen in its "fixation position,"[1] if the secondary squint is equal to the primary. If the squint be of sufficiently high degree, the hand can be so held as to screen the best eye from the figure which is fixed, while not interposing between it and the candle. Either way, the figure which measures the secondary deviation is soon found in the same way as the primary. Of course some eyes have no central fixation, and then the secondary

[1] By this I mean the position it occupies on the cornea when the eye is fixing the candle. It is nearly always a little (more or less) to the inner side of the centre of the cornea.

deviation cannot be measured. For children too young to read and who must therefore stand on a chair, a relative can hold a match-box or other article over each figure that is named.

To test for *concomitancy*, the patient's head should be rotated 20° or 30° to the right, and then to the left, and the squint be measured in each of these positions. The effect of correcting the refraction can also be ascertained. If binocular vision be not restored by the correction, it suffices to place a lens before the fixing eye in a trial frame, and watch the corneal image on the naked squinting eye. To ensure that the lens, if strong, exerts no prismatic effect, it should be well centred, and the patient's head, as well as the eye, be directed to the figure indicated on the board as the measure of the squint. Indeed in every case, except in tests for concomitancy, the head, as well as the eye, should be directed to this figure; the patient will often do so instinctively, but if not he should be told to, for it is better to measure the squint in its usual position with the fixing eye looking straight forwards. The angle can be measured by this method, though with not quite so great accuracy as by the perimeter, from the difficulty of ensuring that the observing eye is in exactly the right position. The string already mentioned as attached to the centre of the board should be stretched to the patient's eyebrow, to give an idea of the right plane; and if greater accuracy is required, a thin wire can be suspended from it, bearing a small weight. The observer's eye can then be held just behind the wire. One eye should be covered by the patient's own hand, while the other looks at that figure which allows the corneal image to appear in the exact centre of the cornea.

As the "board method" of strabismometry was in the first place suggested by Priestley Smith's, it remains only to describe the intermediate method by which it was arrived at. Finding the red reflex from the choroid in his test rather embarrassing, I changed places with the patient and used the flame directly instead of the ophthalmoscope, still drawing out the tape-measure as before. For this plan a

light room was found to serve as well as a dark one, and the observation of the corneal image was found to be much facilitated by placing the observer's head between the light and the observed eye. To gain this advantage, however, two operators are necessary, whereas it is gained in the board method by one. I am indebted to Dr. Berry for much assistance, and to him, and Dr. Argyll Robertson also, for a great number of squint cases on which to test these methods.

TRAUMATIC PANOPHTHALMITIS; ENUCLEATION; UNCONTROLLABLE HEMORRHAGE; DEATH.

By J. H. THOMPSON, M.D., Kansas City, Mo.

IN a thesis on enucleation of the eyeball, by A. Fage, Paris, 1891, we read the following sentence: "So far as serious hemorrhage is concerned, this is rare, and we are always able to control it." [1]

This may, in a measure, be true, and it is doubtful if many operators have experienced more than ordinary bleeding after simple enucleation. I, for one, am prepared to publish an exception to the statement of M. Fage; for not many months ago I removed an eye, from the effect of which the patient died, on the seventh day, of hemorrhage. This is a dreadful admission, but it is a fact nevertheless, and although the circumstances are painful to relate, they may be interesting to many.

John W., a truck gardener, aged thirty-two years, a large, seemingly healthy man, was wounded in the face by an accidental discharge of a gun, twenty to twenty-five yards distant.

His companions said that at the time they could see the blood spout from his face, and that when they reached him he was bleeding profusely. This bleeding stopped in a short time, when he rode a mile or so home. He found that he was shot in the right eye. The family physician was called, but did nothing other than order cold applications to the face. Five days after the injury I saw the patient. The swelling from the many shot wounds in the face was decreasing, but the right eye was in a con-

[1] *Recueil d'Ophtalmologie*, Sept., 1891, p. 537.

dition of panophthalmitis, a single shot having entered it at the upper edge of the cornea. The wound was quite large, and in it the prolapsed iris. The anterior chamber was full of pus, and the conjunctiva chemosed.

I explained to him his condition: told him that the sight of that eye was hopelessly gone, that he was then suffering from an acute inflammation of the entire eyeball, and that enucleation was the best that could be done for him. That he refused. I then ordered hot poultices and sufficient morphine to relieve the pain.

I saw him again in a few days; the eye was then badly inflamed, but under morphine he was comparatively comfortable. Again enucleation was strongly advised, but declined. I did not see him again for a month, but heard in the interim that with the help of morphine and whiskey he was doing nicely; in fact, he was about well. At this time he came to my office. He complained that the pain was returning, and was then willing that the eye should be removed.

I did not examine the eye, but saw that the collapsed ball was more inflamed than is usual at that stage of the disease.

That afternoon, under chloroform, I removed the eye, and on examining it, I found that the shot had passed completely through it, leaving the eye at the disc, where there was a large mass of inflammatory tissue surrounding the nerve. The hemorrhage did not appear excessive. The wound was dressed with bichloride gauze and a bandage applied. After the patient came to from the anæsthetic, and I was about to leave, I noticed that the bandage was bloody. It was removed and another carefully applied. This again was soaked through in a short time. When I removed it, inserted a speculum, and sought the bleeding vessel, I could not find it; the blood simply welled up from the depth of the orbit, arterial in character, but without pulsation.

In hunting for the artery I noticed that there was quite a large cavity behind the capsule. This I tamponed. The pain from the tampon and bandage was excessive, but was somewhat mitigated by morphine. The bleeding now stopped. At midnight I saw the patient and found him covered with blood. I then placed him under chloroform, opened up the orbit, and tried for an hour to secure the bleeding vessel with artery forceps; in vain; still the blood came from the deep, but not as free as before. While under the anæsthetic, the orbit was carefully tamponed and the

whole compressed tightly under a bandage. The pain was almost unendurable, but the hemorrhage was apparently under control. This dressing remained in place twenty-four hours, when the bleeding returned; the blood forcing its way through the bandage.

For some time I feared that in removing the eye I had opened into a traumatic aneurism, and holding in mind the course of the shot, I thought that there was a wound of the ophthalmic artery in the canal. It was also noticed that when a hypodermic injection of morphine was given, the spot was afterwards marked by a large ecchymosis; often the puncture bled considerably.

The patient had been a hard drinker for several years; he lived in a very malarious river bottom, and had drank a large quantity of whiskey during his illness. For these reasons it appeared that in addition to a trauma of a deep artery, we had also a hemorrhagic tendency to contend with. Therefore, iron and ergot were given in large doses. When the bleeding returned, I called in the help of a surgeon, Dr. J. D. Griffith. We then dissected the entire contents of the orbit from its walls, and included them in a stout ligature as near the foramen as possible; the remains of the tissues were removed. The bleeding ceased; the wound was left open for an hour, and it remained dry. Then was the orbit tamponed with iodoform gauze, and the patient, for the first time in weeks, made comfortable. This was done in the early morning. At midnight I was summoned again, and found him bleeding as badly as before. He was then removed to the hospital, and preparations were made to tie the common carotid artery. Instead of doing this, the orbit was carefully cleaned out, and the tissue about the fissure and optic canal caught up in broad compression forceps. Apparently there was nothing left to bleed. The wound was left open until it glazed over, when it was tamponed with iodoform gauze soaked in Monsell's solution, the forceps (3 pair) remaining in place.

It was now thought that this would be sufficient, and that it was unnecessary to tie the artery. The patient was comfortable. The next day I found a little bleeding. In emptying the orbit, it was found necessary to slit the external canthus about one quarter of an inch. The blood came from this wound. One drop of Monsell's solution stopped it. In the evening, although there had been no bleeding, still there was a marked swelling around the canthus. The tumor contained clotted blood. This was

pressed out, and the cavity washed with a bichloride solution. Slight compression seemed to hold the hemorrhage in check. At midnight, this blood cavity was as large as a hickory nut; by morning, twice as large. It was filled with a hard blood clot, which, when it was removed, exposed an irregular cavity bleeding from every spot. Nothing would control this oozing; hour by hour this cavity grew larger, until it undermined the skin of the forehead, side of the face, and cheek. The walls then broke down, leaving an open wound, dissecting up the soft parts in all directions. The blood ran in a little stream over the cheek. The pulse now became fast and irregular. Maniacal delirium now came on, and the patient died at midnight, bleeding to the very last. There was no bleeding from the orbit after the last operation.

From time to time we are cautioned not to remove an eye during panophthalmitis, since there is danger of secondary inflammation of the brain, and death. That this accident can be attributed to septic invasion is the opinion of many authorities, but I have never yet seen a warning of hemorrhage.

In the case reported, the man died from hemorrhage following a simple enucleation. Whether there was a traumatic aneurism in the orbit, I am unable to say. The fact that the shot had passed completely through the eye, the course it took, and the large cavity in the depth of the orbit rather tended to that belief.

I can hardly think that that could have been responsible for the fatal bleeding. The tamponing would have controlled such a hemorrhage, even if it came from a wound in the ophthalmic artery in the canal.

The patient was what might be called a bad subject for operation. He had for years been a steady drinker, and during six weeks previous to the operation had made himself comfortable with morphine and whiskey. It will be remembered that at no time did the blood fail to clot; indeed, the tendency was to the formation of hard clots, for we found in the so-called blood abscess a remarkably hard coagulum, which seemed to destroy the surrounding tissues by pressure.

When, after the final operation, the bleeding started from the small wound at the canthus, it was seen that it came from every capillary. The tissues seemed to melt away, exposing a larger surface every moment, until the oozing collected into a running stream.

Therefore, I am inclined to the opinion that the fault was not in the character of the blood, but was in the walls of the arterioles, which melted away, as did the connective tissue which supported them. Whether this condition was the result of alcoholism, I am unable to say, but think it very probable.

THE CORRELATION OF CRANIAL AND OCULO-BULBAR CONFORMATIONS.

C. M. CULVER, M.A., M.D., ALBANY, N. Y.

(*With two wood-cuts.*)

THIS correlation has been somewhat discussed. No definite law concerning it has, to my knowledge, been formulated. If there were a uniform similarity between the shape of a cranium and of the eyeballs it contains, it seems as if the most natural one would be between the ratios of the transverse and longitudinal (or antero-posterior) diameters of the spheroids in question. If such a correlation existed it might be practically utilized. The static, refractive power of an eyeball is conditioned by the ratio of its transverse and longitudinal diameters. If the long eye were usually in a long skull, the oculist might find it of aid to him to use a pair of outside calipers, primarily, with them making measurements of the patient's head; and then, applying the law, know something about the kind and degree of ametropia to be found in that case. On page 299, of Landolt's work on "Refraction and Accommodation," the author gives a figure, which is here reproduced, representing the cranial conformation of O—— S——, the left side of whose skull was undeveloped, while the other half was like that of the average adult. As affecting the making of a rule, of the kind above suggested, this figure seems to me to have a double significance, its parts being somewhat contradictory. O—— S—— had the face and cranium of an infant, on one side, while face and cranium were developed so as to be in correspondence with his adult

age, on the other side. A myopic eye is longer, antero-posteriorly, relatively to its transverse diameter, than a hyperopic or emmetropic eye. This preponderance of length over width was characteristic of the left half of the cranium of O—— S——. But myopia was not at all present in the horizontal meridian of the left eye in that skull, and there was but one dioptry of myopia in its vertical meridian. Hence the relation seems to have been lacking in this case. But it has been assumed that hyperopia is comparable with the optical condition of an eye which is incompletely devel-

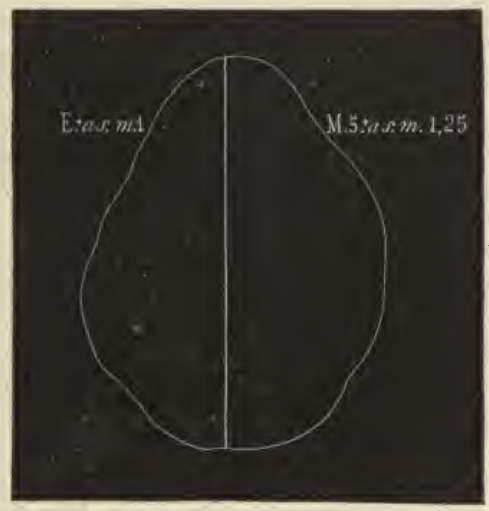

oped. O—— S—— was not hyperopic in either eye; but his left eye was less affected by myopia, and the left side of his cranium was the one presenting imperfect development. Hence, whatever similarity may be expected to exist between a non-myopic eye and the corresponding lack of development of the side of the cranium containing it, is to be found in the case under consideration.

With a view to investigating this matter, to determine, if possible, if a uniform correlation of the ratios in question exists, I bought what hatters term a *conformateur* (mine being of the kind make by Allié, of Paris). With it the crania of some hundreds of my patients were measured.

From appropriate experiments I adopted 0.79 as the ratio of the transverse to the antero-posterior diameter of the average skull. From the classical works of Merkel[1] and Noyes,[2] 0.97 was adopted as the ratio of the similar diameters of the emmetropic eye. Then, in the case of each patient whose skull was measured, the diameters of the eyeballs were estimated according to the *data* to be found on pages 58 and 62 of the first edition of Dr. Noyes' work, just cited. After having arranged several pages of figures in columns, I thought that such a presentation of the ratios would not be striking. Hence they were reduced to the graphic form shown in the annexed plate. Only one hundred cases were used, at first, from which to estimate ratios, because of the facility of calculating percentages from that number. Accordingly, the plate shows only one hundred cases. Many more records are preserved, making their use possible should it be demanded by interest in the topic. In these cases there seems to be no correspondence between the degrees of variation, of the tracings, from the normals.

Among the measurements not represented in those herewith presented, are those of two successive cases, in one of which the patient's myopia amounted to twenty-eight dioptries, while the other's hyperopia was of six dioptries. The length of the myope's head, from before backward, was one millimetre less than that of the hyperope, while the transverse diameter of the myope's skull was by one millimetre greater than the corresponding diameter of the hyperope's, the ratios being, therefore, directly opposite to what might be expected, if a myope were to have a specially long, and a hyperope a specially wide, skull. In corresponding with Landolt concerning these cases, he writes that the cases are worthy of note, adding: "But you will find still more marked differences, and those in the same sense. Hence I say, in my work, that the rule requiring that the larger eye shall be in the larger half of the cranium, is subject to many exceptions, and that the influence exercised by the

[1] Merkel, "Handbuch der Topographischen Anatomie," page 282.

[2] Noyes, "Diseases of the Eye," pages 2, 58, and 62, first edition; pages 2, 89, and 90, 1890 edition.

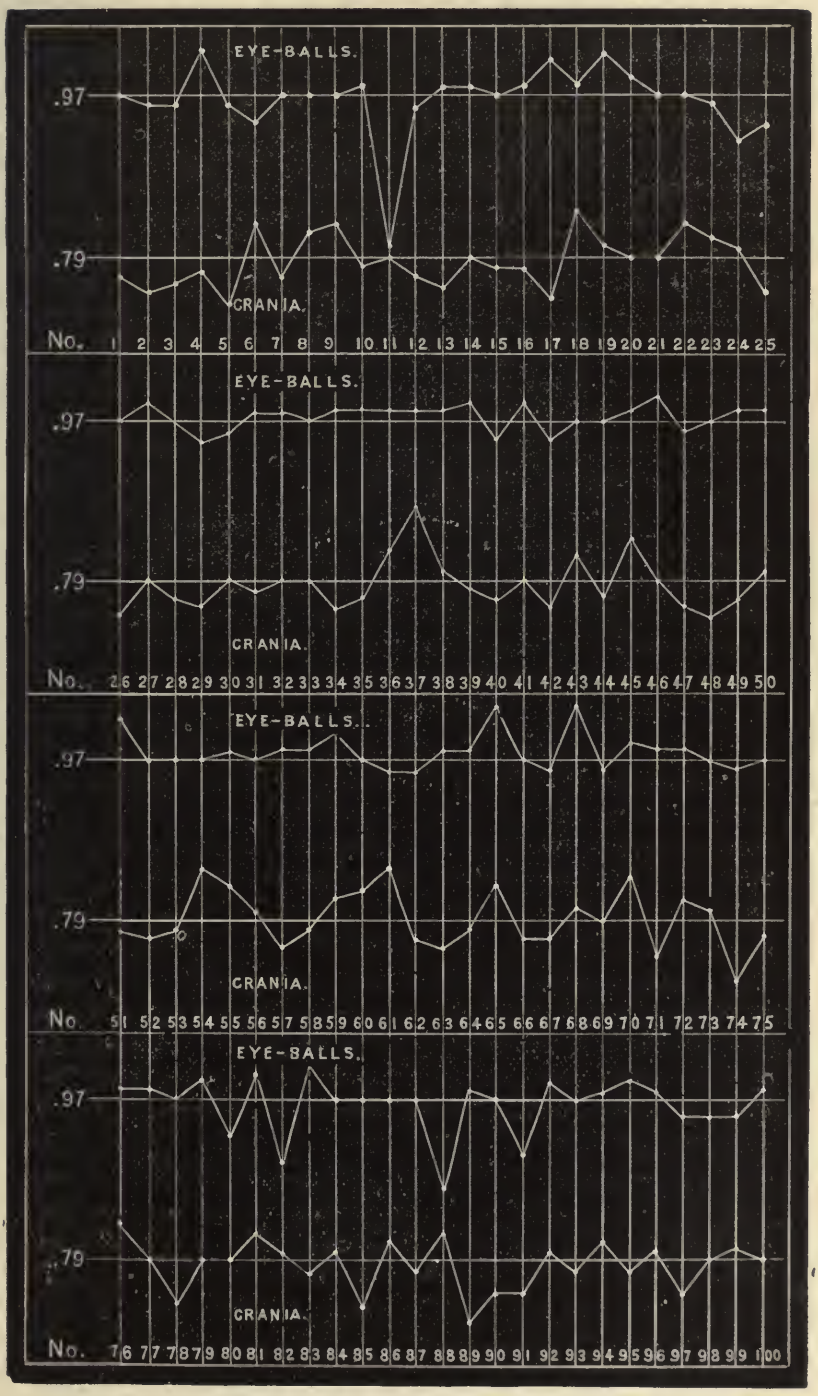
EYE-BALLS.
.97
.79
CRANIA.
No. 1 2 3 4 5 6 7 8 9 10 11 12 13 14 15 16 17 18 19 20 21 22 23 24 25
EYE-BALLS.
.97
.79
CRANIA.
No. 26 27 28 29 30 31 32 33 34 35 36 37 38 39 40 41 42 43 44 45 46 47 48 49 50
EYE-BALLS.
.97
.79
CRANIA.
No. 51 52 53 54 55 56 57 58 59 60 61 62 63 64 65 66 67 68 69 70 71 72 73 74 75
EYE-BALLS.
.97
.79
CRANIA.
No. 76 77 78 79 80 81 82 83 84 85 86 87 88 89 90 91 92 93 94 95 96 97 98 99 100

skeleton on the development of the eye, is not immediate, but rather indirect."

However, it seems that any relation between cranial and oculo-bulbar conformations (especially any that is to be of sufficient utility to make us care to be acquainted with it) ought to be most readily susceptible of expression in terms of ratios of the transverse and longitudinal diameters.

Professor Ripton, of Union College, has earned my gratitude, which I wish now to express, by reviewing the figures, from which the accompanying diagram was made. He pronounced them correct.

My conclusion, from this investigation, is that, if there exist any correlation between the ratios of the transverse and longitudinal axes of a cranium and the eyeballs it contains, it is not direct or practically useful.

EUROPHEN AND CANTHARIDATE OF SODA IN OPHTHALMOLOGY.

By JUAN SANTOS FERNANDEZ, M.D., Havana, Cuba.

WHEN I came back from Europe, in August, 1891, I brought with me some europhen, which had been just produced in Germany. It is obtained from the action of iodine on isobuthylorthocresol in alkaline solution. Antiseptic properties were claimed for this substance, and I have been informed that those claims have been recently confirmed, and that the antiseptic value of europhen has been found to be very much like that of iodoform. The bacteriological testing has been carried forth by Dr. N. Liebel and the dermatological by Dr. Eichhoff of Elberfeld.[1] Dr. Liebel has found it completely destitute of toxicity; Dr. Eichhoff has tried it in gonorrhœa, in the form of an emulsion with olive oil, tragacanth gum, and water; the strength of this topic has been from 0.30 to 1.50 per cent.; this dose has always produced irritation of the mucous membrane and micturition was painful.

Europhen has been employed with success in some non-syphilitic diseases, such as varicose sores, ulcerated lupus, etc.; also in burns; it has been useless in eczema and psoriasis.

The same as iodoform and aristol, europhen is active only when applied to moist surfaces, which are able to withdraw from the remedy a certain amount of iodine in a free state. A salve with 5 to 10 per cent. has proved to be irritant enough to produce eczema; for this reason a dose under 2 per cent. is recommended. Our experience with

[1] Sem. Mèd. n. 37. 1891.

europhen very nearly confirms the opinion of the authors named. We have only tried it on the conjunctiva and cornea while inflamed. We have used very small doses (as we always do with unknown substances), of 0.5 and 1.00 per cent. in a salve with vaseline. The application of this salve has never been followed with pain. The same is not the case with iodol; when we tried it we certainly obtained some improvement in keratitis, but we were obliged to give up its use on account of excessive pain, although employed in the same doses as europhen. We can divide our cases into conjunctivitis, keratitis, accidental and surgical traumatisms.

CASE 1.—Y. W., Chinese, æt. sixty-two, sub-acute glaucoma with cataract. Iridectomy was performed on Sept. 12, 1891; after the operation europhen (1 per cent.) was applied. The wound of the cornea was healed and in eight days he was released without trace of inflammation.

CASE 2.—S. P., a negro, was taken in Sept. 16, 1891. Eight days before a small quantity of moist lime had fallen into his eye, which accident was followed with much pain, and compelled him to abandon his work; the europhen salve was exclusively employed, with good result, the epithelial sore being now under healing process.

CASE 3.—I. A., yellow man; he was received in my clinic on May 12, 1891; diagnosis, kerato-conjunctivitis; he has been sick for six months before consulting an ophthalmologist; while I was in Europe, Dr. Madan tried, without success, antiseptic washes, boric acid and bichloride of mercury, salol, and petroleum; europhen was then applied, and in fifteen days great improvement was noticed.

CASE 4.—A. P., negro, æt. twenty; marginal keratitis of L. E.; is very much better since europhen was employed.

CASE 5.—R. C.; has been operated on for pupilla cicatricialis on Sept. 16, 1891; since the second day europhen is applied and the healing goes on very rapidly.

CASE 6.—L. M., single woman, æt forty; partial enucleation was performed; eight days after operation, the wound not having healed by *prima intentio*, notwithstanding very complete antisepsis, europhen was applied; after the first application the suppuration ceased; boric acid and bichloride had had no success.

CASE 7.—V. A., of Navarra, Spain; engineer; was wounded

in the right cornea with an iron bar; plumb. acet. was applied by an accidental assistant; two corneal opacities were detected; one of them was linear, near the periphery, and was due to incipient hypopyon; the other was central, about five millimetres long and two wide; it was thus ellipsoid. The central opacity was due to a layer of lead; pain and injection persisted, after removal of the metal, until europhen was applied, in a dose of 1.5 per cent.; after the first application the pain disappeared and the injection gradually diminished. Although the dose was 0.5 per cent. higher, no pain was present.

CASE 8.—A young man, æt. thirty; beer-maker; received a drop of liquid ammonia in L. E. on July 24, 1891; subsequent intense inflammation, lasting five days; suppuration takes place, with severe pain; Sept. 22d he is examined by me for the first time, after having been treated by other doctors; the conjunctiva appears œdematous, and mucous irritant secretion is detected in both culs-de-sac; the cornea was completely infiltrated; the iris partly projected. He was treated by boric-acid applications twice a day, and europhen salve. Success was promptly obtained, the pain has subsided and the cornea is rapidly assuming its normal aspect.

We are aware that the cases which we present, and many others which have not been recorded, are not sufficient to claim europhen as having better antiseptic properties than other remedies, but, the eye being such a delicate organ, we have endeavored, before doing anything else, to be sure of its innocence; this, and that europhen is useful in some, not serious, diseases of the eye, where other antiseptics are also efficient, is all that we can, as yet, affirm. After having done this, we shall try it in those diseases in which no treatment has ever been successful.

I have promised the readers of the ARCHIVES to inform them of the ultimate result in those patients in which I tried the cantharidate of soda in granular eyelids. The treatment was pursued in six patients, who at first moderately improved, but remained after as they were before. As the treatment is painful, and sometimes indurations were observed in the injection places, the doctors who were in charge of my clinic during my trip in Europe deemed it necessary to suspend its use.

A CONTRIBUTION TO THE HISTOLOGY OF SOME OF THE RARER FORMS OF TUMOR OF THE CHOROID.*

By WARD A. HOLDEN, A.M., M.D., New York.

(*With five figures in the text.*)

CASE I.—METASTATIC CARCINOMA OF CHOROID AND SCLERA.

CASES of metastatic carcinoma of the choroid have been observed by Perls, Hirschberg, Schöler-Uhthoff, Hirschberg-Birnbacher, Manz, Schapringer, Mitvalsky (2), Elschnig, Schultze, Ewing, and Wadsworth—twelve cases in all, in nine of which a microscopic examination was made.[1] The case to be anatomically described here is of interest as showing clearly the genesis of these tumors.

The eyeball, after being hardened in Müller's fluid, was divided horizontally, and one half cut in total microscopic sections.

Anatomical Description.—The retina is detached on the temporal side from the papilla to the ora serrata, and the subretinal space is filled with a homogeneous coagulated mass (Fig. 1). Beneath this detachment the choroid is diffusely thickened to 1.5 *mm* by the presence of epithelial tubules and new-formed fibrous tissue. In the outer layers of the sclera and the episcleral tissue, at a point corresponding to the middle of the choroidal growth, there is a small tumor consisting of narrow epithelial tubules. This

* From the laboratory of the New York Ophth. and Aural Institute.

[1] References and notes of these cases, together with such general conclusions as could be drawn from a consideration of the first eight cases, are contained in the paper by Mitvalsky, these Archives, No. 2, 1891.

second carcinomatous focus seems to stand in no direct connection with that in the choroid, from which it is separated by two thirds the thickness of the unchanged sclera ; 4 *mm* to the nasal side of the papilla, a few carcinoma tubules have developed in the choroid without causing a thickening perceptible to the naked eye.

There are thus three distinct carcinomatous foci, varying in extent and degree of development. Posterior to the two choroidal foci the vessels of the choroid are dilated and distended with blood. Anterior to the foci the choroid is normal, excepting for some hemorrhages into the suprachoroidal space. The retina shows no changes except in the layer of rods and cones in that

FIG. I.

portion which is detached. The remaining parts of the eyeball are normal. The filtration angles are widely open, and there is no anatomical indication of increased intraocular tension.

The histological aspects of the three carcinomatous foci differ, and each will be spoken of in turn. The larger choroidal focus is 12 *mm* in lateral extent, beginning at a point 3 *mm* to the temporal side of the papilla. In its internal portion corresponding to the layer of large vessels, there are large tubules composed of a varying number of concentric layers of epithelioid cells arranged more or less regularly, the interior ones often degenerated and not taking the stain. These tubules are surrounded with bundles of coarse-fibred connective-tissue, containing spindle-shaped nuclei, pigmented cells, free pigment, and small blood-vessels. Internal to these and corresponding

in position to Sattler's layer of small vessels—tubules, groups, and tracts of epithelioid cells are crowded together, separated only by fine connective-tissue fibres containing pigment-cells. A small number of carcinoma cells are found within the capillaries of the chorio-capillaris. At some points there is a continuous line of cells from the capillary layer to a group in the stroma of the choroid. Within a few of the larger veins, distinct groups of carcinoma cells are seen, unconnected with the vessel wall.

There is a round-celled infiltration about the choroidal vessels and nerves where they pass through the sclera on the temporal side. The outer layers of the sclera for a distance corresponding to the middle two fourths of the larger choroidal tumor, show a great number of congested vessels, mostly very little larger than capillaries, and about these a diffuse round-celled infiltration. At a point opposite the middle of the choroidal tumor, there is the small scleral focus consisting of epithelial tubules of from one to three layers of cells. No direct connection was found between the tubules and the vessels.

The smaller choroidal focus consists of a plugging of the chorio-capillaris with carcinoma cells for a distance of 2 *mm*, and of a few groups of carcinoma cells in the stroma of the choroid, some directly continuous with the cells in the capillaries. Besides this some of the veins contain groups of carcinoma cells which can often be traced back to the capillaries.

Although the clinical history of this case has been unfortunately misplaced, the presence of three distinct carcinomatous foci in the eye, two of them in a part in which primary carcinoma does not occur, leaves no doubt but that these are of metastatic origin, and this is confirmed by their position with reference to the arteries. For the smaller choroidal focus appears in that portion of the choroid to which the short ciliary arteries of the nasal side run, the middle portion of the larger choroidal focus is in that part of the choroid where the greater number of short ciliary arteries enter, and the location of the scleral focus is that of one of the small twigs which, after being given off by the short ciliary arteries, run near the surface of the sclera.

No plugging of a ciliary artery was found here, as in Schultze's case, but in each choroidal focus the capillaries of the chorio-capillaris were found plugged with carcinoma

cells. These cells proliferated at some points, and in some preparations they are seen to have broken through the capillary walls and to be directly continuous with groups in the stroma of the choroid. The impression is thus gained that wandering epithelioid cells have been caught in the chorio-capillaris, and proliferating have formed groups in the stroma of the choroid, and groups passing back into the veins.

The scleral focus, the smaller choroidal focus, and the external portion of the larger choroidal focus are of the type of carcinoma simplex, *i. e.*, they consist of a framework of dense connective-tissue, in the alveoli of which lie groups of epithelioid cells. In the internal portion of the larger choroidal focus the cells predominate over the connective tissue, approximating the type of carcinoma medullare or molle. In the cases previously reported these growths were of the type of carcinoma simplex or scirrhosum.

While the detachment of the retina occurring in cases of choroidal tumor has been attributed to interference with the choroidal circulation and consequent exudation (Graefe, Fuchs), or to direct secretion from the tumor itself (Leber), Iwanoff, Brailey, and Nordensen have found shrinking and detachment of the vitreous as well in these cases as in spontaneous detachment of the retina.

In our case the peripheral portion of the detached retina shows in many preparations a marked fold, whose configuration plainly suggests traction at a particular point from the side of the vitreous. And at this point in the uncut half of the eye a tuft of vitreous was seen securely attached to the retina, while on either side it was detached. Over the adjacent surfaces of the retina and vitreous, which later has of course shrunk more in the hardening, traces of coagulated matter are seen in this region in the sections, indicating that in life a layer of fluid separated the vitreous from the retina. The vitreous is markedly fibrillar in its peripheral portion, and especially so near the ora serrata. The retina shows no rupture, but it is safe to say that there was shrinking and detachment of the vitreous in life, and that the dragging

of the portions still adherent to the retina regulated the form which the detached portion of the retina assumed if it did not alone produce the detachment.

These cases of carcinoma of the choroid have now been observed so often that a word as to diagnosis may be admissible. As for the ophthalmoscopic picture of carcinoma before detachment of the retina takes place, its usual position corresponding to the entrance of the short ciliary arteries, and its usual diffuse form, would point toward the diagnosis in contradistinction to sarcoma, which may appear at any point in the uveal tract, and is rarely diffuse but almost always elevated. The diagnosis is confirmed by the discovery of the primary carcinoma, which in every case but one has been located in the breast. Furthermore, the diagnosis is not unimportant as regards treatment. For in cases of primary malignant disease of the eye, epithelioma or sarcoma of the outer coat, sarcoma of the middle, and glioma of the inner coat, if enucleation be made before metastases take place in distant organs, or contiguous parts become involved, the disease is permanently cured in a certain percentage of the cases; but the presence of a carcinomatous tumor in the choroid implies the existence of a primary growth elsewhere in the body, and the probability of metastatic tumors having already developed in other parts or being likely soon to develop, so that the enucleation of the eye can neither prevent nor even delay the lethal termination.

CASE 2.—TELANGIECTATIC SARCOMA OF THE CHOROID.

John G., æt. forty-two, complained of failing vision and pain in his left eye. Examination showed extensive detachment of the retina and increased tension. A diagnosis of choroidal tumor was made and the eye enucleated by Dr. H. Knapp, Sept. 10, 1883. When the ball was opened after the enucleation, a tumor of the choroid the size of a small hazel-nut was seen near the papilla. On being cut the tumor showed a smooth surface and soft consistence. After being hardened in Müller's fluid the ball was divided horizontally and one half cut in microscopic sections.

Anatomical Description.—From the posterior segment of the choroid springs a smooth fungus-shaped tumor, with slightly con-

stricted base, extending from the papilla nearly to the equator of the ball on the temporal side, measuring 15 *mm* in its greatest transverse diameter and rising 8 *mm* above the plane of the choroid. Its cut surface is of a uniform gray color.

The internal layers of the choroid are reflected at the base of the tumor and continue over it as an adherent thick capsule. From the papilla to the ora serrata the retina is completely detached, leaving the pigment epithelium in position on the lamina vitrea of the choroid.

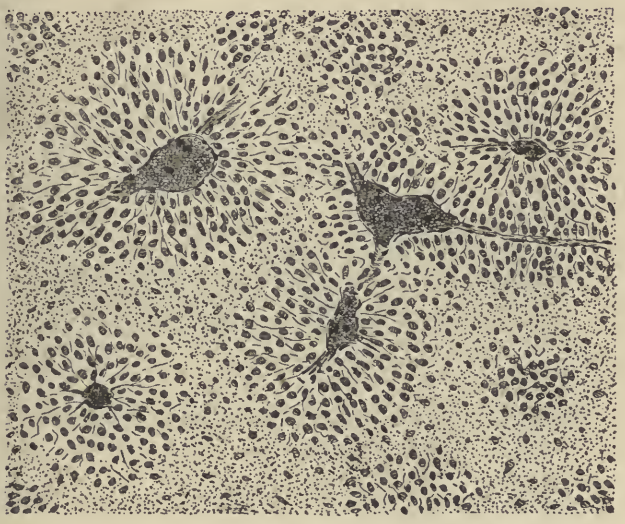

FIG. 2.

The tumor has developed in the tunica vasculosa, and large vessels of this layer are found both in the portion of the choroid next the sclera and in that covering the surface of the tumor.

The bulk of the tumor is composed of tubules, cut transversely and longitudinally, with little intervening tissue. Slightly magnified it gives the impression of being a tubular adenoma. With a higher power each tubule is seen to consist of a delicate homogeneous tubular membrane, with spindle-shaped nuclei, *i. e.*, a capillary vessel wall, surrounded with concentric layers of short spindle cells (Fig. 2). The arrangement of the cells is that of superimposed layers of epithelial cells. These layers, which are not distinct since the cells are not polygonal but spindle-shaped, vary in

number from three to seven in the different tubules. For the most part they are about five in number and give the tumor a very uniform appearance.

In the central portion of the tumor the vessel walls lie for the most part in opposition, or the very narrow lumen contains a few scattered blood corpuscles. Nearer the periphery of the tumor the lumen is often larger and filled with blood corpuscles (Fig. 2). Near the capsule a vessel here and there is dilated into a broad sinus. In none of these new-formed vessels, however, can be seen more of a wall than the delicate elastic membrane with its spindle-shaped nuclei.

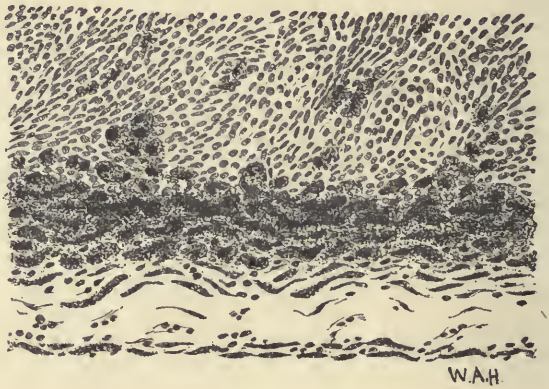

FIG. 3.

The cells about the vessels are packed closely together, allowing no intercellular substance to be seen. The portions of the tumor between the separate tubular systems have scattered round and spindle cells similar to those about the vessels, and contain extravasations of blood. The specimens being friable do not tease well, and it is impossible to get a clear picture of the ground substance between the tubules, the interstitial tissue of the tumor. It would seem, however, to be finely granular.

The cells are of the size usually found in small-celled sarcomata, the nucleus being a little larger than that of a white blood corpuscle, staining less dark with hematoxylin, and not being especially granular.

Besides the characteristic arrangement of the cells, there is a small portion of the tumor at the periphery toward the equator of

the ball, which contains closely packed round and short spindle cells in irregular groups (Fig. 3) with few vessels—a common type of small spindle-celled sarcoma of the choroid. This arrangement of the cells begins in the choroid and passes gradually over into the tubular arrangement described above.

The proper choroidal vessels are almost altogether wanting in the portion of the choroid next to the sclera. They are comparatively few in number in the portion on the surface of the tumor. In the capsule at the neck of the tumor there are a number of

FIG. 4.

large vessels and a very considerable increase of pigment. This is most marked on the side next the papilla, and here there have been large hemorrhages into the base of the tumor, separating it from its capsule.

Fig. 4 shows in its lower portion the choroid *(A)*, and to the left a hemorrhage *(B)*. The inner layers of the choroidal capsule are infiltrated with sarcoma cells, and the pigment cells are increased in number. Many of the pigment cells of a long spindle form show traces of membrane, and above and to the left in the draw-

ing are seen to form distinct capillary walls, cut longitudinally, surrounded by layers of sarcoma cells. Excepting a few mostly round pigment cells near the capsule, all the cells in the tumor which contain pigment lie in the vessel walls. The proper sarcoma cells are not pigmented. These longitudinally-cut tubules containing here no blood corpuscles, often dividing and rejoining, continue in parallel rows of from three to five over the extent of the hemorrhage and some distance beyond it, just within the capsule, in all through about one fourth of the periphery of the tumor. In other parts of the tumor these peripheral longitudinally-cut tubules are less regularly parallel and have a considerable lumen.

Above and to the right of the field shown in Fig. 4 the transversely-cut tubules begin. The blood-vessel *(D)* is one of a number just within the capsule, and bearing more resemblance to a choroidal vessel than to one of the tubules of the tumor. Some of these vessels have quite thick walls, and running from them can be seen twigs which become tubules of the tumor.

The nuclei of the most external cells in some of the tubules stain faintly, and the central portion of the tumor consists of cells which retain their form and whose body stains normally; but the nuclei stain faintly or not at all, indicating a beginning degeneration of the cells.

The Remainder of the Eyeball.—The intervaginal space about the optic nerve is large. The retina is slightly infiltrated with leucocytes in the region of the tumor. The anterior portion of the periphery of the cornea shows a round-celled infiltration and the interlamellar spaces are enlarged. The region of the canal of Schlemm is slightly infiltrated with leucocytes. The iris in its whole extent lies on the cornea, to which it is firmly adherent at its periphery. The retina, completely detached, folds on itself at the ora serrata, and continues forward over the ciliary body and the posterior surface of the lens. The ciliary processes are flattened against the ciliary body and the ciliary body is compressed.

The globe shows signs of increased intraocular tension, and the disease is therefore in its second stage, the stadium glaucomatosum.

The most important characteristic of the tumor being the vessel formations, and these being of a capillary type, it is to be called, following Virchow's classification, a telangiec-

tatic sarcoma, the predominating cells being small spindle-cells.

The modern idea of the development of sarcoma is that the tumor is formed by the proliferation of the adventitial cells of new-formed capillaries. In the slow-growing sarcomata these new cells become more or less spindle-shaped, the capillary degenerates, and each group of cells forms a fascicle separated from its neighboring fascicles by a lymph-space lined with endothelial cells.[1]

In this case the bulk of the tumor has not undergone the usual changes, but still exhibits the capillary vessels with their sheaths of sarcoma cells. A small portion of the tumor has developed further, and distinct fascicles have been formed, each showing in its central portion the indistinct remains of a pre-existing capillary.

The degeneration of the external cells in some of the peripheric tubules and the complete degeneration of the tubules in the centre of the growth, is very similar to that seen in degenerating glioma, where each capillary is surrounded with a sheath of normal cells, and those further from the blood-supply degenerate and do not take the hematoxylin stain.

The causes of degeneration in sarcoma are the insufficient blood-supply in rapid-growing tumors and the compression exercised by other parts. The cells nearest the vessel wall are the active ones. In our case the capillaries of the central portion of the tumor mostly show no lumen at all or are plugged with degenerated masses, indicating a deficient blood-supply; and lymph-spaces between the fascicles which might carry nutrition to the peripheric cells of a fascicle are also wanting here.

Some of the capillaries are seen to be given off by large vessels of the capsule of the tumor. At a little distance from the capsule the capillaries lose their pigment. This partial pigmentation of the endothelium of the capillaries is often found in both melano-sarcoma and leuco-sarcoma.

Cases of angio-sarcoma and cavernous sarcoma of the

[1] Ackermann: "Die Histogenese und Histologie der Sarcome," Volkmann's *Samml. klin. Vorträge, Chirurgie*, 1883.

choroid have been reported by Leber, Hirschberg, Fuchs, Nordensen, and others. Schiess-Gemuseus[1] has reported a case of benign cavernous angioma having no sarcomatous formation.

Two cases have been reported which bear some resemblance to the case under consideration. The first is Knapp's 14th case.[2] It differs from the case in question in that many of the vessels showed the usual three coats, and the capillary twigs were encircled by separate groups of mostly round cells, so that in general appearance the tumor resembled an alveolar carcinoma.

A second case described by Schüppel[3] showed a number of thin-walled vessels, with from one to three concentric layers of cells about them, resembling the endothelial cells of Descemet's membrane. Among them were large darkly pigmented cells, and the spaces left were filled with small branched cells slightly pigmented. No fibrous structure existed. This was called by Sleich an endothelial sarcoma.

The tumor which has been described is interesting as being a peculiar example of a type rarely found in the choroid, which in its rapid growth has remained in that immature stage through which all sarcomata may be supposed to pass in the course of their development.

CASE 3.—ANGIO-SARCOMA OF CHOROID.

This tumor, like that last described, is composed in part of vessels surrounded with sheaths of sarcoma cells, which join to make up a compact mass. It, however, presents the remarkable peculiarity of vessels springing out, independent and unconnected, from the substance of the tumor, and almost completely blocking the vitreous chamber.

C. H., æt. twenty-two, came to the clinic October 9, 1888, complaining of loss of sight and pain in the right eye.

Examination showed perikeratic injection, and a number of dark patches in the ciliary region; anterior chamber shallow;

---

[1] Graefe's *Archiv*, vol. xxxiv., 3, p. 240.
[2] Die intraocularen Geschwülste, p. 134.
[3] Cited by Fuchs: Das Sarcom des Uvealtractus, p. 139.

signs of old iritis ; no view of fundus as the vitreous chamber contained blood ; tension + 2.

The eye was enucleated by Dr. H. Knapp as suspicious of containing a tumor.

The enucleated ball was much enlarged. Besides the dark patches in the ciliary region, another similar patch was seen in the sclera to the upper inner side of the optic nerve.

When opened the vitreous chamber was seen to be filled with a mass, a portion of which was black, the rest mottled brown. The darker portion proved to be blood, and this having been washed out the mottled brown portion was seen to consist of minute branched tubules, matted together, but for the most part distinct, springing from an elevated tumor which extended on the temporal side from the disc to a point somewhat anterior to the equator of the ball.

The ultimate elements of the tumor are, first, small round cells with a large pale nucleus and distinct nucleolus, making up the greater portion of the tumor; and secondly, cells of the same size and larger, darkly pigmented, and present in less number.

Histologically the growth may be grossly divided into three parts. The middle part is composed of small unpigmented cells and contains a few small thin-walled vessels. To the temporal side and partly surrounding this unpigmented part is a second smaller part strongly pigmented throughout and containing many fair-sized vessels. The surface of the tumor is not marked by a distinct capsule, as is usually the case; and from this portion larger and smaller, mostly well-pigmented vessels, at first connected by sarcomatous tissue and farther out unconnected, run forward into the vitreous chamber.

To the nasal side of the middle part and separated from it by a pigmented layer, is the third part, which is but slightly pigmented and presents the typical picture of angiosarcoma. The short ciliary arteries pass through the sclera and break up into a great number of large tortuous vessels which, running close together, are united by sarcoma cells. These vessels in their turn give off larger and smaller vessels

which pass out free into the vitreous chamber and together with the pigmented vessels from the temporal part of the tumor, nearly fill it (Fig. 5).

The middle unpigmented part is partly surrounded by the darkly pigmented part. A recent writer[1] on this subject says: "It is a well-known fact that melano-sarcoma often presents a mottled appearance; but a sarcoma showing a

FIG. 5.

smaller portion slightly pigmented and a larger portion darkly pigmented (as in the case he reported) seems not to have been previously described."

This condition cannot be so exceedingly rare. I have another case besides this, in which the middle third of the tumor in the section shows scarcely a trace of pigment, while the other two thirds are very dark.

[1] Weinbaum, Graefe's *Archiv*, xxxvii., 1.

The pigmented part in the case under discussion contains many large vessels, as is usually the case in the more darkly pigmented peripheral or capsular portion of a sarcoma of the choroid.

The angiomatous part near the disc would seem to be a more recent development outside the pigmented zone which may here represent the usual capsule.

The condition of the remaining parts of the ball are as follows:

No layers of the choroid can be distinguished in the tumor. The choroid elsewhere, the ciliary body, and particularly the iris, are degenerated and sclerosed. The iris in almost its entire extent is adherent to the lens capsule. The filtration angle is occluded. Just external to the sclero-corneal junction there are a number of accumulations of pigmented sarcoma cells in the ciliary body and the thinned sclera. Upon the lamina vitrea of the choroid are colloid excrescences and there has been an excessive development of pigment epithelium. The sclera near the nerve shows a pigmented sarcomatous patch similar to those in the ciliary region. The nerve is atrophic. The retina, completely detached and degenerated, can be recognized in part as a connective-tissue band just behind the unchanged lens.

Under a high power most of the vessels are seen to consist of homogeneous, elastic tubules having round cells grouped irregularly about them, these being most densely packed near the membrane. Some of the vessels have, external to the elastic membrane, a sheath of fusiform cells running circularly and longitudinally, but never in a radiating manner as in the case previously described.

The vessels in which this sheath is well marked are very similar to normal choroidal arteries and are, like the others, surrounded with irregularly arranged round cells.

The vessels free in the vitreous chamber vary in the thickness of their sarcomatous sheath from a single broken layer of round cells to an accumulation a dozen cells deep. All the vessels contained blood.

Angio-sarcoma of the choroid, even of the ordinary type, is not common, but I have found no case described which showed this peculiar extra-capsular development of vessels.

Explanation of the Figures.

FIG. 1. Total section of the ball with carcinoma of the choroid (Case 1).

FIG. 2. A portion of the sarcoma (Case 2) some distance from the centre, showing vessels with a considerable lumen, some transversely, others longitudinally cut, surrounded with concentric layers of spindle cells. The portions between the groups of cells show old extravasations of blood. Hematoxylin-eosin. × 200.

FIG. 3. A portion of the sarcoma (Case 2) near the equator of the ball, showing spindle and round cells arranged after the usual type. Hematox.-eosin. × 200.

FIG. 4. The choroid *A* (Case 2) is seen to be infiltrated with sarcoma cells. To the left is a hemorrhage *B*. Running in layers over this are seen the long spindle and fusiform pigmented cells which to the left form capillary walls around which the sarcoma cells arrange themselves. To the right is the thin-walled vessel *D*. Hematox.-eosin. × 200.

FIG. 5. Eccentric horizontal section of posterior segment of ball (Case 3), showing the nasal unpigmented part of the sarcoma with its angiomatous structure, and the free vessels springing from it. Hematox.-eosin. × circa 12.

TWO CASES OF PAPILLOMA OF THE CONJUNCTIVA ENCROACHING UPON THE CORNEA.

By Dr. F. H. SIMS, of Mobile, Ala.

FROM THE EYE CLINIC OF PROFESSOR FUCHS, IN VIENNA.

THE rarity of papillomatous growth on the conjunctiva has induced me to report two cases recently operated upon in Professor Fuchs' clinic.

Interest in these cases is increased by the fact that in both instances the growths encroached upon the cornea, so far in one case as to materially disturb vision in the eye upon dilatation of the pupil.

A careful search into the literature of the subject reveals the fact that only ten cases of well-marked papillomatous growth of the conjunctiva have been reported. Most of these had their origin from the caruncle, semilunar fold, or from the palpebral conjunctiva, usually near the margin of the lid. In four instances, however, the bulbar conjunctiva was involved, either primarily or by extension of the growth from the palpebral portion. In none of these cases was the limbus or cornea involved, which is the more remarkable, as mentioned by Professor Fuchs, when we consider that the limbus is the only portion of the conjunctiva where papillæ are sometimes to be found.

Mackenzie[1] states in a general way that he has seen "warty granulations" springing from the cornea, and Mr. Bowman[2] removed a "warty opacity" from the same situa-

[1] Mackenzie on "Diseases of the Eye," London, 1854.

[2] "Lectures on the Parts Concerned in the Operations on the Eye," London, 1849.

tion. As neither of these cases seems to have been submitted to histological examination, we are left in doubt as to whether the growths were of papillomatous character

In most of the reported cases there was marked tendency toward recurrence, though in every instance complete extirpation of the growth together with the attached conjunctiva resulted in permanent recovery.

I will now report briefly the two cases referred to above:

CASE 1.—Michael Brunner, farmer, æt. fifty-five, was admitted to the hospital April 28, 1891. He first noticed about six months ago a small tumor about the size of a pin-head which, from his statement, was situated on the outer portion of the bulbar conjunctiva, some distance from the limbus. The tumor increased rapidly in size, and at the same time approached the limbus upon which it began to encroach after about two months. The eye was a little irritable, but he suffered no pain. Upon admission the growth was found to measure 1 *cm* in the horizontal by 8 *mm* in the vertical direction. It was attached to the conjunctiva external to the limbus as well as to the limbus itself, and for a short distance to the cornea. Its margins were free from attachment, allowing the passage of a probe entirely round under the overhanging edges of the growth.

This freedom from attachment was especially marked internally where the tumor extended across the cornea to the outer margin of the pupil. This portion could be raised from the cornea which was found to be clear, and of healthy appearance. The growth was of a reddish-gray color and presented an irregular mulberry surface which, when examined with a magnifying glass, was seen to consist of numerous papillæ, and to be covered by a thin grayish epithelial membrane.

Numerous fine blood-vessels were to be seen in the papillæ, and at two points small capillary hemorrhages.

The growth was removed, together with some portion of the conjunctiva around the attachment, and the edges of the wound brought together by means of fine sutures.

CASE 2.—Rudolfine Hausner, æt. twenty, was sent to the clinic June 9, 1891, from Professor Kaposi's wards, where she had been under treatment at intervals since 1885 for xeroderma pigmentosum. A growth about 9 *mm* in the vertical by 7 *mm* in the horizontal direction was found to be situated on the outer sclero-

corneal junction of the left eye. The principal points of attachment were the limbus, and the conjunctiva immediately external. The margins of the tumor were, like the above-described growth, free from attachment, movable, and overlapping the cornea internally about 2½ *mm.* The gross appearance was also that of a typical papilloma. The history of the case showed that the growth had been developing gradually since February, at which time it was first noticed, as a small whitish swelling situated on the conjunctiva external to the limbus. Frequent cauterization seemed to have but little effect upon its progress.

This case is more interesting from the undoubted connection existing between the papillomatous growth and the rare and interesting form of skin disease for which the patient has been under treatment for the past few years. This disease was described by Kaposi,[1] in 1870, under the name of xeroderma pigmentosum, and is thought by him to consist primarily of disease of the vessels and structures of the papillary layer of the skin. The disease, according to Kaposi, begins in early childhood, and is evidently of hereditary origin, as of the comparatively few cases described many have occurred in members of the same family. The disease is usually confined to the upper portion of the body, and presents quite characteristic appearances. The skin over the affected part is covered with brownish-white pigment spots, between which depressed scars, much resembling those of small-pox, appear. The epidermis is at first smooth, but afterwards becomes thrown into rolls from atrophy of the skin tissue beneath. Sarcomatous and carcinomatous nodes are of frequent occurrence, the result, as Kaposi points out, of the inherent disturbance of nutrition in the stratum papillare. The patient under consideration was operated upon by Billroth in July, 1889, for carcinomatous growth involving the nose; and numerous small growths removed from time to time by Kaposi have proved to be of a similar character.

According to Elsenberg,[2] fifty-two cases of xeroderma pigmentosum had been reported up to date—1890. The

[1] "Encyclopädie der gesammten Heilkunde."
[2] *Archiv für Dermatologie und Syphilis*, 1890.

conjunctiva was involved in one of Elsenberg's cases, the growth proving upon examination to be sarcoma. Professor Kaposi is of the opinion that the papillomatous growth under consideration would have assumed a malignant character if allowed to reach its full development. He has seen no other case of xeroderma pigmentosum in which the conjunctiva was involved.

MICROSCOPIC APPEARANCE.

The two tumors were found to be identical in structure, consisting of numerous papillæ, each containing a loop of blood-vessels surrounded by layers of epithelial cells. Little connective tissue was to be seen, except a thin sheath round the vessels, and the line of demarcation between this tissue and the internal layer of epithelium was found to be well marked throughout. The epithelial layer was increased to about three times its normal thickness, the cells presenting the characteristics of those of the bulbar conjunctiva.

I beg leave here to acknowledge my indebtedness to Professor Kaposi for kind assistance while investigating the subject of xeroderma pigmentosum.

I am also much indebted to his assistant, Dr. Lukasiewicz, for sections of the tumor from the latter case.

OPTIC NEURITIS AFTER MEASLES AND INTERMITTENT FEVER.

By HIRAM WOODS, M.D., Baltimore, Md.

Case 1.—In the spring of 1888, Mrs. B. brought her four-year-old boy to the Presbyterian Eye, Ear, and Throat Hospital. She stated that the child had had measles two or three months before her visit, and that his sight had become poor while he was recovering. The child looked robust, but his vision was reduced to ability to see large objects when very near them. A more accurate test of vision could not be made. The pupils were moderately dilated but reacted to light. The ophthalmoscope revealed double optic neuritis. There were no retinal hemorrhages. Urine normal. Both nerves become atrophic. Dr. Caleb Winslow, who attended the boy when he was ill with measles, tells me that this child and his brother were sick at the same time. There was never the least reason for anxiety in either case. Both attacks were light and apparently uncomplicated, until the sight of this boy began to deteriorate during convalescence. Barring his blindness, the boy has had excellent health since his illness.

Case 2.—Jimmy M., ten years old, came under my care in February, 1891. His mother, an intelligent woman, gave me the following history: She has five children. In December, 1890, three of them were taken, one after another, with measles. The family physician, Dr. Charles L. Buddenholm, was called in and attended the children through their illness. At no time were they very sick, and the first intimation of trouble was ten days or so after the children were running about, when this boy seemed to see poorly. For a month after this was noticed, sight steadily became worse. Dr. Buddenholm confirms this history. At the time of the visit to me vision was so poor that the boy would not trust himself to walk alone. He had $\frac{6}{200}$ V in each eye.

Pupils were moderately dilated, but responded to light. The ophthalmoscope revealed : R. E., slight optic neuritis, apparently subsiding. The line of separation between nerve and retina on the nasal side was blurred, while the outer half of the papilla was pallid, but not white. The vessels were unaffected. L. E., a more active inflammatory process was found in this eye. The papilla was considerably swollen, while the fundus—especially from the papilla to the fovea—was hazy. There was no special engorgement of the retinal vessels. An actual test of the visual field could not be made, but it was evidently contracted. The child was put on strychnia, beginning with $\frac{1}{30}$ gr. of the sulphate three times daily. The dose was increased in ten days to $\frac{1}{15}$ gr. t. d. At this time there were slight muscular twitchings, but they soon passed off. He remained under my care for three weeks. The only change in the ophthalmoscopic appearance during this period was the gradual subsidence of the left neuritis. The first week in April he had $\frac{20}{100}$ V both eyes. I did not see him again till October 31st last. His sight is about $\frac{10}{100}$, a falling off since April. The discs are somewhat pale, but one would not call them atrophied unless he knew sight was poor, and was familiar with the history.

Case 3.—A boy of five years of age, was brought to me at Easton, Talbot Co., in June, 1888. His father, a farmer, told me the boy had had "chills" in the fall of 1887. Quinine had been given according to the method in vogue among the farmers in that region of Maryland—as much of the salt, in powder, as is necessary to stop the ague. The chills yielded to the drug, but there were several relapses till cold weather set in. The attack extended over a period of three or four months. The defect in vision was noticed early in the winter. Examination of the eyes showed pupils moderately dilated, and responding feebly to light. Objects held to the left were faintly seen, but central vision was gone. The ophthalmoscope showed double nerve atrophy and retinal hemorrhages—some new, others old. Neither the heart nor urine showed anything abnormal. I saw the child again in the spring of 1890 at the Presbyterian Eye and Ear Hospital. He is absolutely blind.

So far as I have been able to discover, optic neuritis after measles has been explained in three ways: (1) coincidence; (2) disease of the visual centre in the occipital lobe with

consecutive changes in the optic tracts and nerves; (3) basal meningitis. Cases are not numerous, and autopsies less so, hence explanations are little more than hypotheses.

Undoubtedly there is such a disease as idiopathic optic neuritis, and it could as easily occur during convalescence from measles as at any other time. Noyes ("Diseases of the Eye") expresses the opinion that "in theoretical statements too little stress has been laid upon this kind of idiopathic affection." It would, however, be almost entirely negatived as an explanation of such cases as those narrated, (*a*) if optic neuritis occurred frequently enough after measles to demonstrate that the latter had a causative influence, even if this influence could not be identified, or (*b*) if such conditions as are known causes of neuritis existed with measles and were caused by it. As regards (*a*), most authors mention optic neuritis as an occasional sequela of measles. While not undertaking an explanation of its production, they evidently do not think it merely a coincidence. Proposition (*b*) must be accepted or rejected according to the evidence which can be produced in favor of the second or third explanations given above, or, possibly, of some other not here mentioned.

At a meeting of the Société d'Ophtalmologie de Paris, November 6, 1888, M. Despagnet presented the candidature thesis of M. Boucher, entitled "Rongeole: amblyopie d'origine cérébrale" (*Recueil d'Ophtalmologie*, Dec., 1888). The paper was based upon the case of a soldier, twenty-five years old, who had measles complicated only by a diarrhœa, appearing on the sixteenth day, and lasting two days. Ten days later, while sleeping, he became restless, and "rose from his bed in a state of somnambulism." He soon fell into a deep sleep which lasted thirty-six hours. There was no paralysis, as evidenced by his drawing away his foot when pricked. When he awoke he presented a normal appearance and felt well, but found he could not see. Examination showed V $\frac{1}{100}$ each eye. Pupils were of normal size and responded to light. The ophthalmoscope revealed nothing abnormal. Associated symptoms were uncertainty in walk, feebleness of legs, hesitation in touching rapidly designated

points on the face. There was no diminution of sensibility. The urine was normal. After three days another eye examination revealed a concentrically contracted field. Red was quickly recognized, and all other colors confounded. Fundal appearance normal. In two weeks from their first appearance all the symptoms had disappeared except those connected with the eyes. There was now "over the entire fundus of the eye a very light gray transparent cloud, specially marked toward the inside of and above the papilla." A month later he had V R. E. $\frac{7}{200}$, L. E. $\frac{3}{200}$. Six weeks later there was practically the same V, while "each papilla was pale, but not enough so to call it atrophied." Some months after this the condition was the same, and the man was lost sight of. Boucher quotes a case of Calmeil's as follows: A child, at the end of an attack of measles, had coma, and became deaf, dumb, and blind. Speech returned after a year, but he remained blind, became epileptic, right hemiplegic and imbecile. Death after "some years." The most important thing revealed by the autopsy was atrophy and sclerosis of both occipital lobes, and atrophy of the optic nerves. The opinion is expressed that the original lesion was in the hemisphere, and the atrophy was secondary. Without following Boucher's explanation of the associated nervous symptoms in his case, he attributes the visual disturbances to lesions of the occipital lobes with *secondary* nerve and retinal disease appearing at a late period. He thus connects the central lesions with measles: "Amblyopia may result from an intoxication acting upon the nervous system through the blood. The poison may be a morbid product accumulated by . . . an infectious fever." Despagnet added a case of his own, in which a sudden and incomplete blindness had come on twenty-eight days after measles, unaccompanied by other symptoms. V was $\frac{1}{100}$, soon improving to R. E. $\frac{1}{28}$, L. E. $\frac{1}{50}$, where it remained. The ophthalmoscopic appearances were the same as in Boucher's case, and the same explanation is given of the blindness. The cerebral lesion is thought to be a hemorrhage. As examples of vascular lesions after fevers (a not uncommon occurrence according to the writer), he cites

embolisms and thromboses of the retina, orbit, and brain after typhoid fever," and gangrene sometimes seen after measles. In the further discussion of the case, Abadie thought the amblyopia came "from a vascular lesion which might have been produced by a microbic infection." Channel thought the blindness a mere coincidence with the measles, and Galezowski, agreeing with Channel, added that he "had seen hundreds of patients with measles and scarlet fever, and he could not say he had ever met amblyopia indisputably due to these affections."

The essential features of these cases seem to be (1) the suddenness of the attack and the marked degree of blindness; (2) the absence of eye lesions early in the attack and their appearance later; (3) the similarity of the visual disturbances in the cases reported and the one quoted (Calmeil's), and the pretty close correspondence between the post-mortem appearances in the latter and the physiology of the occipital lobe. So far, the hypothesis of central lesion and secondary atrophy seems tenable. To connect the central lesion with the measles of nearly a month previous is a more difficult matter. If there be such a connection, it must act, as Boucher says, "through the blood." Such vascular lesions as purpura are now and then seen after infectious fevers—less often after measles than others. What causes the degeneration of the vessels is, so far as I can find out, unknown. It may be, as Abadie says, a microbic infection, which may act by producing its own specific result upon certain tissues, or else by producing some poisonous principle in the blood. The "gangrene of measles" is usually cancrum oris, and is practically confined to asylums and badly nourished children (J. Lewis Smith). In a recent conversation, Dr. Wm. H. Welch, of the Johns Hopkins Hospital, expressed to me the opinion that cancrum oris after measles is due to an infection entirely distinct from measles. In such a part as the cheek, gangrene from purely vascular disturbances would be almost impossible on account of the abundant blood supply and free anastomosis. The influence of the measles is, probably, effecting such alterations in the tissues

(possibly from stomatitis) as to render them incapable of resisting the organisms of decomposition. Thus the cancrum oris might furnish a clue to the explanation of deeper disturbances. Given a system with its powers of resistance lowered by measles (or anything else), and a secondary infection, the latter might as easily manifest itself in the nervous system as elsewhere. In two features, at least, my own cases differ from those cited above: (1) the failure of sight was gradual and came on during convalescence; (2) there was abundant explanation of the blindness found in the fundus of the eye. This makes the theory of central lesion and consecutive atrophy very improbable. In one of three cases reported by Dr. O. F. Wadsworth in the *Boston Medical and Surgical Journal* (Dec. 30, 1880), the same was true. The patient recovered. In the other two the relation is not so clear. Three cases reported by Dr. Coggin, of Salem, Mass., in the *American Journal of Ophthalmology* (January, 1890), manifested blindness very early after measles. In two there was neuritis with subsequent atrophy, while the third showed no lesion of the eye and ultimately recovered. All these patients manifested other symptoms which were referred to a supposed meningitis. In a few lines given to the subject, Gowers (*Medical Ophthalmoscopy*) attributes troubles in vision after measles to meningitis. The same opinion is expressed by Dr. de Schweinitz, in his excellent article on diseases of the eye, in Keating's "Encyclopædia of Diseases of Children."

As already stated, if there were any meningeal symptoms in my cases, they escaped the notice of either the parents or attending physicians. Can a meningitis exist of sufficient gravity to cause optic neuritis and atrophy, and manifest itself in no other way? In this connection, I am granted by my friend, Dr. H. J. Berkley, of this city, the privilege of using an observation of his before its publication in a coming number of the *Hopkins Bulletin*. In the recent report of a case entitled "Acute Ataxia, Following Diarrhœa," he advances the theory of auto-infection from the intestinal canal, and subsequent inflammation of the nervous system. He adds: "The strongest support that this

hypothesis has is the peculiar neuritis of the chiasma of the optic nerves. In persons who have died of infectious diseases, notably typhoid fever, I have noticed in the meninges around the sides and interior portion of the optic chiasm, a rather intense degree of inflammation, with much small-cell infiltration, and implication of the vessels, especially the veins. . . . This condition, in different degrees, was almost constant . . . causing a positive increase in the nuclei between the fibres of the optic nerve." He states that he has not noticed "distinct degeneration of the nerve fibres," nor did the specimen (taken from Müller's fluid) yield bacilli. He adds: "It is just at this point (chiasm) that a most excellent focus is to be found for the deposit and growth of pathogenic organisms, and a room for the action of the toxical material engendered by them; . . . the protuberance in the loose and folded character of the meninges, and the number of blood-vessels in its meshes affording great facilities for an exudation and stasis of the blood." The fact that Dr. Berkley did not find positive nerve degeneration means very little. Given a meningitis about the chiasm with subsequent neuritis at this point, the question of recovery or nerve atrophy becomes one of degree of the inflammation and length of life.

Cases of blindness after measles seem, then, to be of two kinds: (1) those showing no eye lesions until late in the history of the case; (2) those with marked neuritis from the beginning. The former are apparently due to cerebral lesion—probably vascular—with consecutive nerve disease; the latter to basal meningitis and neuritis. The most natural explanation of their connection with measles seems to be that this disease lowers, so to speak, the powers of resistance of the tissues, and renders secondary infection easy. Whether the evidence of this secondary infection will be vascular changes in the brain, intestines, or elsewhere, inflammation of tissues in the thorax or cranium, or gangrene of the cheek, will depend upon the nature of the infection and the seat of its operations.

As regards the case of neuro-retinitis after intermittent fever, it may be asked—was the blindness merely a coinci-

dence, was it caused by the fever, or by the indefinite, but certainly large, amount of quinine the patient took? The first is, of course, possible. There is no proving it one way or the other. As to the rest, Gruening (Noyes, *loc. cit.*) states that quinine amaurosis comes on suddenly and is complete, is associated with great deafness, passes off completely in a few days, weeks, or months, so far as central vision is concerned, while peripheral vision may remain permanently impaired. "The ophthalmoscope reveals ischæmia of the retinal arteries and veins, without any inflammatory changes." In the case here narrated, blindness came on gradually—if the history is reliable,—was unaccompanied by deafness, central vision was lost while a little peripheral vision remained, and the loss of sight was complete and permanent. The ophthalmoscope revealed marked inflammatory changes. Neuro-retinal lesions after malarial fever are frequently seen in countries where the fever is of a severer type than prevails here. According to Gowers (*loc. cit.*) retinal hemorrhages, neuro-retinitis, and nerve atrophy are the changes observed. Macnamara, who had an immense experience in India, narrates, in his "Diseases of the Eye," a case which he states "is an example of a class of cases by no means of uncommon occurrence among the natives of India." A girl of thirteen, who had had previous attacks, had quotidian malaria for a week. At the end of this time "a numbness and inability to move the right leg came on." Soon both were affected, and she could not walk. With these symptoms sight began to fail, and, when admitted to the eye hospital two months after the beginning of the attack, motion of the right arm had been lost, the pupils were "dilated and insensible to light," while the ophthalmoscope revealed double optic neuritis and nothing else. She ultimately made a complete recovery. Macnamara thought this class of cases depended "upon miasmatic influences affecting alterations in the blood, and thereby inducing local hyperæmia and serous effusion into various organs." He attributed the transient paralysis "to a serous effusion into the optic thalami and corpora striata . . . the pressure thus caused on these

important nerve-centres interfering with the volition of the patient over the affected limbs." He thought the blindness due to "serous effusion into the optic papilla and nervous matter of the retina."

This case is given in detail because an almost identical one has recently been reported in the *Proceedings of the New York State Medical Society for* 1891, by Dr. Frank W. Ring, of New York, and, further, because it bears out, in a measure, a hypothetical explanation which has been given of malarial amaurosis.

In 1877 Dr. C. S. Bull, of New York, reported in the *American Journal of Medical Sciences*, two cases of nerve atrophy occurring in victims of chronic malarial poisoning. He argues that in the congestive types of malaria, when sight is affected, amblyopia is probably the result of increased intracranial pressure from increased blood-supply. He says: "If one such attack may bring on a disturbance, which at first is purely functional, may not a repeated number of such attacks produce a permanent organic change in the fibres of the optic nerve or tract, or in the nuclei of origin, by long-continued and repeated pressure?" Finally, reference should be made to a paper presented by Dr. Morton Prince, of Boston, to the American Neurological Society in 1889, an abstract of which appeared in the New York *Medical Record* of July 27, 1889. The subject was, "Malaria as a Cause of Degenerative Diseases of the Spinal Cord." Cases are cited to show the co-existence of malaria with tabes dorsalis and disseminated sclerosis. The author thinks there may be a causative relation between chronic malarial poisoning and connective-tissue formation in the nervous system.

The cases quoted from Macnamara and Ring are practically the same—temporary blindness with swelling of each papilla, associated with symptoms indicating cerebral disease, the whole train of symptoms disappearing, and recovery being complete. Bull's cases and my own are alike in two particulars at least—the blindness was permanent from nerve atrophy, and there seems to have been no other nervous disturbance. When Macnamara wrote,

the theory that optic neuritis was due to distension of the dorsal sheath from the arachnoid cavity was generally believed; hence he accepted intracranial and perineural pressure as sufficient explanation of all the symptoms. This theory is now generally abandoned for one holding an inflammation of the nerve fibres as the original pathological factor, and the effusion into the sheath and papilla as secondary to this inflammation. Considering the five cases together, the questions would arise: (1) Can malaria effect such changes in the blood as to cause an inflammation of the optic-nerve fibres and consecutive atrophy; and (2) is it true, after all, that increased intracranial pressure can so affect the optic nerve through the dural sheath, as to cause papillitis and subsequent atrophy? As regards (1) I do not know that such a result of malaria is generally recognized. Concerning (2), the formation of connective tissue in various organs of the body, as the result of repeated hyperæmia and serous infiltration, is a well-recognized consequence of chronic malarial poisoning. Reasoning upon the analogy thus furnished, serous infiltration and subsequent connective-tissue growth would seem to me the most natural explanation of *malarial* optic neuritis and atrophy.

REPORT OF A CASE IN WHICH THERE IS BINOCULAR ABSENCE OF THE CHOROID, SHOWING A RICH PLEXUS OF CILIO-RETINAL VESSELS SUPPLYING THE REGION OF THE YELLOW SPOT IN BOTH EYES.

By WARWICK M. COWGILL, M.D., Paducah, Ky.

(*With two drawings.*)

August 25, 1886, George K., æt. seventeen, was brought to me by his mother, who said that her son's eyesight had been very poor all his life. The external appearance of his eyes is normal; refractive media clear. A high degree of myopia in both eyes

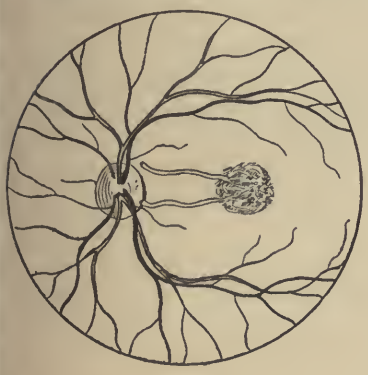

L.

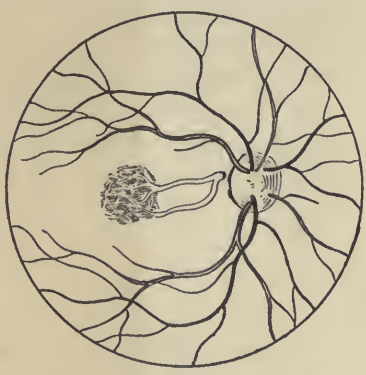

R.

(R E — 13 D; L E — 16 D). V R E = $\frac{10}{200}$ w — 8.D; V L E = $\frac{8}{200}$ w — 8.D. There is no evidence of choroid, on examination with the ophthalmoscope, in either eye. There is an entire absence of choroidal pigment and blood-vessels. The whole background of the eyes, as far forward as can be seen when the pupils are dilated

ad maximum, is of scleral whiteness. The central retinal vessels are normal in their number, distribution, and size. Arising near the border of the O D in the R E at the temporal side is a large cilio-retinal vessel, which gives off a large branch just as it emerges from the sclera. These vessels pass directly, without branching, to the region of the yellow spot, where they form a rich circumscribed plexus, about the diameter of the Od.

In the left eye the conditions are practically the same, only the two vessels arise separately, one above the upper, and one from the lower outer edge of the O D. These vessels have a decidedly different appearance from the central retinal vessels. They are larger—the larger one in each eye being about twice, and the smaller one about once, the diameter of the largest central retinal arteries. They seem to be compressed antero-posteriorly, which gives them a ribbon-like appearance. There is no blood cylinder reflex from them. Their color is somewhat brighter than that of the central retinal arteries.

We have here two eyes in which there has been an arrest of development. The choroid is entirely absent in both eyes, at least in so far as the elements of this structure can be made out with the ophthalmoscope. The retina, which appears to be normal in each eye, lies directly upon the white reflecting surface, which is undoubtedly the sclera. The absence of choroidal tissue has left the normal retina and its vascular system pictured clearly against the sclera, which brings out clearly the cilio-retinal system of vessels that go to supply the retina in the region of the yellow spot.

TEMPORARY HYPERMETROPIC ASTIGMATISM FOLLOWING AN ATTACK OF MEASLES.

By F. W. MARLOW, M.D., M.R.C.S.,

PROFESSOR OF OPHTHALMOLOGY IN THE MEDICAL DEPARTMENT OF THE UNIVERSITY OF SYRACUSE, N. Y.

Mr. S. C. H., aged twenty-five, a student of Syracuse University, consulted me on December 28, 1889, on account of asthenopic symptoms, which had been increasing during the preceding twelve months.

An examination resulted as follows:

V= $\frac{6}{9}$ in each eye separately, but + 0.25 D cyl. axis 90° definitely increases sharpness of vision, the patient being very particular as to the direction of the axis. As he objected at this time to the use of a mydriatic, the above glasses were ordered. They gave him the desired relief, enabling him to do as much reading as his university course required.

On April 23, 1890, I saw him again. He then stated that he had had a rather severe attack of measles in February; that this was preceded for a day or two by some weakness and watering of the right eye, and that since his convalescence the sight of this eye has been much less distinct than formerly. Has done no work since, and is wearing smoked glasses.

Examination showed R V = $\frac{6}{12}$; $\left.\begin{array}{r} + 0.5 \text{ D sph.} \\ + 1.25 \text{ D cyl. } 170^\circ \end{array}\right\} = \frac{6}{6}$

L V = $\frac{6}{6}$ faulty; + 0.25 D cyl. 90° = $\frac{6}{6}$.

After all range of accommodation had been abolished by the repeated instillation of homatropia, the refraction was again tested.

R with $\left.\begin{array}{r} + 1 \text{ D sph.} \\ + 1 \text{ D cyl. } 170^\circ \end{array}\right\}$ V = $\frac{6}{6}$.

L with + 0.5 D sph.
+ 0.25 D cyl. 90° } V = $\frac{6}{6}$.

The amount of astigmatic change in the right eye is not fully represented by the above figures. The original direction of the axis of the cylinder having been nearly at right angles to the changed direction, it is necessary to add the original to the acquired astigmatism to obtain the full degree of astigmatic change, which would therefore amount to at least 1.25 D.

He was ordered for constant wear:

For the right eye + 0.75 D sph.
+ 1 D cyl. 170° }
For the left + 0.25 D sph.
+ 0.25 D cyl. 90° }

His next visit was on June 4, 1890, when he stated that the glasses did very well for a few days, and then the eye changed again, and he had been getting on well without any.

Examination showed the refraction to be precisely as at the first visit, *the only glass accepted by either eye being* + 0.25 *D cyl., axis exactly at* 90°.

The fundus and pupils were normal throughout.

On November 20, 1891, Mr. H. kindly permitted me to completely paralyze the accommodation of the right eye with homatropia, in order to again examine the static refraction, which proved to be as follows:

R V = $\frac{6}{18}$; + 0.5 D or 0.75 D sph.
+ 0.25 D cyl. 90° } $\frac{6}{6}$

Fundus normal.

This temporary change in refraction must have been due to meridional change of curvature in the cornea or crystalline lens. Its seat in the former structure is improbable on account of the rapidity of its onset and disappearance, the completeness of its disappearance, and the absence of any evident corneal disturbance. An ophthalmometric examination would of course have settled the point. The error was doubtless located in the crystalline lens. Had the refractive change been in the direction of myopia, an

obvious and easily accepted explanation could exist in a local or astigmatic contraction of the ciliary muscle. But the change being in the direction of hypermetropia, of diminished refractive power, the ciliary muscle would have to be locally relaxed in order to produce the effect. This hypothesis is rendered untenable by the fact that complete paralysis of the accommodation results similarly in the two eyes, adding 0.5 D of Hy. to the previous error. If the accommodation had been already partially relaxed in the right eye, less effect would have been produced in this eye than in the left, in which accommodation still retained its full power.

It is presumably true that the lens (unless pathological changes take place within it) does not change its shape, without change in the tension of the anterior capsule and suspensory ligament. The existence of a localized swelling of the ciliary processes near the vertical meridian pressing upon and causing increased tension of the suspensory ligament, and consequently diminution of curvature of the anterior surface of the lens near the vertical meridian, affords a possible explanation of the phenomenon. The meridional flattening would be accompanied by a slight flattening of the whole anterior surface, and a corresponding amount of general Hy. added.

Patients not infrequently date their asthenopic symptoms from an attack of measles, or some other exanthem. The explanation, I believe, is usually deemed to be that the acute illness simply determines the time of onset of symptoms due to pre-existing errors; and presumably this is true of the majority of such cases. The above-recorded case, however, is suggestive of the possibility of refractive error originating during an attack of measles, and there is no evident reason why such refractive error should not persist for a considerable period of time, or even become permanent.

LIVING LARVÆ IN THE CONJUNCTIVAL SAC.

By R. J. PHILLIPS, M.D.,

OPHTHALMIC SURGEON TO THE PRESBYTERIAN HOSPITAL, PHILADELPHIA; INSTRUCTOR IN DISEASES OF THE EYE, PHILADELPHIA POLYCLINIC.

The patient, C. H., a bright, cleanly boy of thirteen years, employed as a jeweller's errand boy, presented himself at the eye clinic of the Presbyterian Hospital, August 27, 1891, with the following story: Five hours before, while burning some rubbish in the back yard of the store, he felt something which he took to be an insect enter the right eye. He rubbed the eye, but the irritation not disappearing, he went to his employer, who, using a lens, discovered a small, white body just within the outer canthus. On endeavoring to remove this body it separated into a number of small "worms," which scattered themselves over the conjunctiva.

At the hospital the conjunctiva was found to be injected, especially that of the lids. There was considerable discharge of mucus. Five parasites were counted crawling about on the globe and lids. Their motions were rapid, serving to carry them across the cornea in two or three seconds. They seemed perfectly at home in the tears, and were observed to come to the margin of the lids but not to cross it. Two of the creatures were removed and placed in water, where they lived for forty-eight hours. Of the others, one was removed on the second, and the remaining two on the third, day after their discovery in the sac. Of these last, one had attached itself to the ocular conjunctiva about 3 millimetres from the cornea, and remained there during its residence in the sac. Meanwhile, the irritation and discharge had rather diminished than increased, and in fact were insignificant.

The parasites are one and a third millimetres long, and to the naked eye appear as white, spindle-shaped worms, in

which few anatomical details can be made out. Under the microscope, each one is seen to be, as represented in the figure, divided into twelve segments, *s s*, by rings of short hairs *r r*. The anterior segment, or "head," though not itself differing from the others in texture or color, is armed with a pair of stout black hooks, *h h*, with which are connected two dark prolongations, *p p*, extending one sixth of the length of the insect, which I take to be muscles for moving the hooks, or possibly organs performing the function of jaws. The alimentary canal can be seen as a broad, shaded band extending from the mouth, *m*, to the anus, *a*.

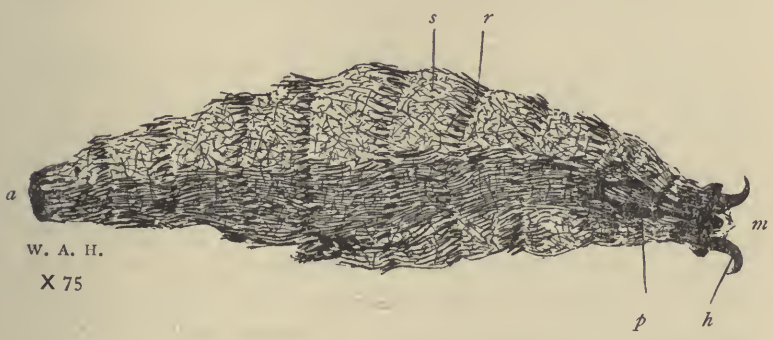

W. A. H.
X 75

These little animals are pronounced by several entomologists to whom I have shown them to be readily recognizable as the larvæ of some of the smaller dipterous insects, probably of a small fly or midge. As the number of North American species in the order *Diptera* is estimated at 10,000, of which only 2,500 have been studied, or at least described, while the knowledge of the larvæ of these insects is in a still more imperfect state, the strict identification of the fly from the few specimens of the larva in my possession will be seen to be impossible. However, the case shows that it is possible for the maggots of a small fly to be deposited in the conjunctival sac, for them to live and thrive there, and that without causing much inconvenience. Indeed, the conditions found in the conjunctiva accord very well with those commonly sought by many genera of the *Muscidæ* for depositing their eggs, while to the closely allied family, the *Œstridæ*, belong the horse-bot, whose

larvæ inhabit the stomach of the horse, and the sheep-bot, whose larvæ I have myself found in the frontal sinuses of the sheep.

The maggots of various flies have been found parasitic in man, not only in wounds and foul discharges, where they are frequently seen, but in the alimentary canal (Dr. J. Leidy, *Proceedings of the Phila. Academy of Natural Sciences*, 1859), in the skin and nostrils (F. Smith, *Transactions of the Entomological Society of London*, 1868, and others), and in some four reported cases in the urine, with which they were supposed to have been passed from the bladder; but this was in no case quite proven, and seems improbable.

As regards the case in hand, and the interesting question of how the larvæ were deposited in the conjunctival sac, the statement made by Packard ("Guide to the Study of Insects," p. 358), that many flies are viviparous, is important. According to this authority, the vagina of many *Muscidæ* "has a seminal receptacle, a spacious and sometimes two-lobed reservoir, in which the fecundated eggs are accumulated in great numbers, and remain until sufficiently developed to be hatched, so that these animals are viviparous."

The *Diptera* in this latitude have, as a rule, no true ovipositor, and content themselves with placing their eggs in cracks or upon the surface of the substance which is to form the food of the larvæ, nor is it probable that eggs could have been deposited beneath the conjunctiva and the larvæ have come to maturity there without producing great inflammation. Equally improbable is it that the eggs could have been deposited on the conjunctiva during sleep, or have entered the eye while bathing, and remained long enough to hatch, without either causing irritation or being washed away by the tears, so that the history of something, thought to be an insect, entering the eye only a few minutes before the living larvæ were discovered, makes it probable that the latter were already hatched in the body of a mature insect, from which they were very likely forced by the vigorous rubbing which the eye received.

HOW SHALL WE TREAT TRACHOMA TO-DAY?

By Dr. E. JAESCHE, Dorpat.

Translated by Dr. Ward A. Holden, New York.

THIS is a question which may seem superfluous, as we have now a method of treatment that is sufficient for all stages of trachoma. But since new procedures are being presented the question is still justifiable. In vol. xxii. of these ARCHIVES, J. Lindsay Johnson recommends "A New Method of Treating Chronic Trachoma"; and in the *Centralbl. f. prakt. Augenheilk.*, February and August, 1890, Noiszewski describes "The Treatment of Trachoma by Transplantation of Conjunctiva." Both of these procedures are, however, so complicated that scarcely any one who had much to do with trachoma cases would think of employing them. These facts lead me to repeat that the simplest and safest procedure is the pressing out of the trachoma follicles. It may not be out of place at this point to glance over the more important means that have been devised for the treatment of trachoma.

Since time immemorial, two sorts of treatment have been used, a *medicamentous* and a *mechanical*. We shall refer to the medicamentous means later. He who has seen many trachoma patients who have been treated for years with sulphate of copper and other agents, and where the swollen conjunctiva still shows follicles, although, perhaps, somewhat flattened, will be eager to adopt a mechanical means that promises a quick result. Thus we see that in early times various rough substances, mineral and vegetable, were rubbed over the granular surface of the conjunctiva. In

this manner, without doubt, a certain amount of destruction of the granulations and hemorrhage was obtained. This method has been lately revived. Fadda (*Gazz. clin. dello spedale civico di Palermo. Berliner klin. Wochenschrift*, p. 221. These ARCHIVES, vol. xvi., p. 17) passes a metallic plate provided with very fine teeth several times over the diseased conjunctiva. Th. v. Schroeder, in St. Petersburg, scratches each follicle out with a sharp-pointed instrument. The galvano-cautery has also been used in trachoma. Korn passes a glowing platinum plate over the conjunctiva. Fröhlich advises the destruction with the galvano-cautery of the individual granules in the tarsal portion of the conjunctiva, and energetic linear cauterization of the retro-tarsal folds. In cases of excessive pannus he makes a similar linear cauterization, a sort of periotomy, partial or total, near the margin of the cornea. G. Lindsay Johnson has a three-bladed knife with which he incises the affected conjunctiva repeatedly from the margin of the lid to the fornix. These incisions are then cauterized with a double galvano-cautery plate. This method is certainly efficacious, but requires special apparatus and great care in its application, as the author states. Every one will agree with his remark that we should endeavor to get rid of the follicles quickly.

Convinced of this fact, some oculists have advised the opening of each follicle with a cataract needle, and as this is very tedious, others have advocated a simpler and more energetic means, the scissors. Pilz ("Textbook of Ophth.") recommends cutting out the follicles deeply, but only two or three at a sitting. In this way, however, the treatment is unduly prolonged. Besides this, Pilz thinks it necessary, in cases of marked infiltration and gelatinous degeneration of the bulbar conjunctiva, to make incisions through the entire thickness of the conjunctiva, allowing the escape of the yellowish contents. The consecutive hemorrhage is encouraged for a time. Some oculists, among them Jacobson of Koenigsberg, go still further, and believe that the disease can be radically cured only by the excision of the entire trachomatous retro-tarsal fold. This is a procedure which is rightly objected to, since it causes a permanent interference

with the motility of the globe, which is scarcely less than that occasioned by the atrophy of the conjunctiva, in which the untreated cases of trachoma usually end. Cutting out the trachomatous conjunctiva and replacing it with mucous membrane from the lip, as Noiszewski recommends, is a procedure which none will be eager to adopt while we possess another which is exceedingly simple, and at the same time sufficient for all cases that occur.

It is very well to experiment in the clinics with different methods of treatment, in order to demonstrate their efficacy to the students, but when a physician has much to do with trachoma cases, he will adopt the simplest and the safest method and continue to practise it. Only since I began to treat cases in the manner to be presently described have I taken any pleasure in the treatment of trachoma.

We shall always be thankful to Dr. Hotz for suggesting the treatment by pressing out the follicles, and if this treatment has not been generally adopted, it is because he advised the use of the thumb nail, at least in the upper lid. For the lower lid he uses a long-curved untoothed forceps, between the branches of which the conjunctiva is grasped and squeezed, and thus freed of its follicles. Since the expression of the follicles should never be omitted, I will indicate the simplest and most efficacious method of performing it.

An instrument well adapted for this purpose is Himly's well-known fenestrated forceps. The conjunctiva of the upper and the lower lid can be seized between its branches with equal certainty, and the entire breadth of the lid squeezed out with a few strokes. Ordinarily we require no other instrument, although for children it is a little broad, and for these cases I have a similar instrument with branches only one fourth so wide as those of Himly's instrument. With this, the conjunctiva in quite young children can be seized even at the outer commissure. Although the operation is so simple, I wish to make a few remarks about it,—points that the experience of the past year has given me.

The *three* chief forms or stages of trachoma require certain variations in the method of treatment. If we have a *fresh*

case with prominent lymph follicles and moderate swelling of the conjunctiva, it is sufficient, after having everted the lid, to seize the conjunctiva in such manner that one branch of the forceps lies in the retro-tarsal fold and the other at the margin of the lid. The forceps are then closed with some force and drawn over the conjunctiva in such a way that not only the follicles are pressed out, but the entire swollen portion of the conjunctiva with the hypertrophied papillæ and the new-formed vessels is thoroughly crushed. In the beginning, I hesitated about doing this so thoroughly, but only after seeing how well the conjunctiva bore the manipulation, did the great value of this method become evident. It does not suffice to apply the forceps a single time. Even in the middle of the lid they must be applied several times, and later the conjunctiva near the commissures seized. When both lids are affected, the lower is treated first, and then the upper, but often the follicles are confined for the most part to the upper.

This manipulation causes severe pain that is but slightly relieved by the previous instillation of cocaine. In the lower lid, only the conjunctiva is squeezed, but in the upper the cartilage is also subjected to the pressure. The operation is quickly performed, however, and finished at one sitting, unless it be preferred to do but one eye at a time. Feeble persons sometimes become faint in the course of the operation, for which reason it is better that children and delicate individuals be chloroformed in order that the operation may be done with sufficient care.

Even at this stage of the process there is often a considerable formation of folds in the conjunctiva of the culs-de-sac. They are more frequent below where they sometimes appear in a double row; in the upper, they are often only to be seen after aversion of the lid. These folds are usually infiltrated and richly covered with granulations, and should be separately seized and pressed out. It is also recommended to excise the most prominent ones with the scissors, otherwise they may persist for a long time, hindering the mobility of the eyes, and increasing the danger of recurrence of the follicles. The hemorrhage which follows the expression and

the excision is not uniform, yet in most cases severe, and it is well to keep it up for a time by moving the lids and washing them with warm water.

In the *second* stage the process is further advanced. *The conjunctiva is markedly swollen, infiltrated, and bleeds readily; the papillæ are greatly hypertrophied, the follicles changed, mostly not so prominent, and partly degenerated, and between them are prominent indurated swellings.* The upper lid is usually the more affected, and the cornea is also involved, showing pannous vascularization, infiltrations, ulcers, or trachomatous growths. The upper lids are swollen, there is photophobia, larchrymation, pain, and muco-purulent secretion. When the disease is so far advanced, *repeated and energetic crushing of the conjunctiva is required*, and this is entirely safe. On the following day the conjunctiva is somewhat more swollen, bleeding, and at points covered with a superficial coating of pale degenerated tissue. This affects, however, only the hypertrophic papillæ, and soon disappears. Some days later the inflammatory swelling decreases, and the improvement begins. In this stage it is admissible to use the scissors after the squeezing, even if the formation of folds is not especially marked. A few strips of the hypertrophic tissue are removed; there is more hemorrhage, and quicker recovery, and there need be no fear of deleterious cicatrization. The latter occurs only in old neglected cases, and is best prevented by an early and thorough squeezing of the conjunctiva. When there is a considerable degree of pannus, the treatment is facilitated by making at the same time a peritomy, partial or total, according to circumstances.

The best results are obtained in the first two stages of trachoma, and especially in the first stage. But an unexpected result is often obtained even in the *third* stage. The conjunctiva here shows *a fairly smooth, atrophic, bloodless surface, and the underlying tissue is infiltrated, thickened, and sclerosed.* There are usually also hard indurated prominences on the conjunctiva of the upper lid, and there is pannus or ulceration of the cornea. If the forceps are used in such cases, half degenerated follicles escape from the

depth of the conjunctiva in unexpected quantity. If all the roughness of the conjunctiva is removed, and a proper after-treatment employed, the worst cases rapidly improve.

The *medicinal* treatment after the operation may be very simple. The first day it is well to make frequent cold applications, later twice a day is sufficient.

Besides this, a wash of sublimate or boric acid may be used. After the second day I begin the instillation of 2 % solution of nitrate of silver, which is used once daily. If the swelling of the papillæ decreases too slowly, the crystal of sulphate of copper may be employed. There are cases in which the *single operation is not sufficient, and a gentler second operation should be made.* A few remaining follicles may be cut off with the scissors.

Fresh cases may be quickly cured in the manner indicated, and even bad cases greatly improved in five or six weeks. The treatment is much longer when the cartilage has been affected, or there is distichiasis, or deep infiltrations and ulcers of the cornea. When there has been an opacity of the cornea for a length of time, I am accustomed to drop a solution of potas. iodid. 0.007–0.015, glycerin. 2.0, aq. dest. 4.0, into the eye once or twice a day, and then massage it.

REMARKS ON THE TREATMENT OF TRACHOMA BY THE EXPRESSION OF THE MORBID SUBSTANCE WITH A ROLLER FORCEPS, BASED ON A SERIES OF 114 SUCCESSIVE CASES.

By H. KNAPP.

(*With one wood-cut.*)

WHEN I was a student, our great teacher, A. v. Graefe, impressively told us "that no remedy—sulphate of copper crystal, the mitigated nitrate of silver stick, etc.—should destroy the granulations by cauterization, but should produce so much irritation—congestion, swelling, and sero-mucous secretion—as to bring about their absorption by increased nutritive tissue changes." This principle ought to be upheld in the modern mechanical methods of treating trachoma as well as in the topical application of antiseptic, astringent, and caustic remedies. The natural termination of the trachomatous process is not exclusively more or less atrophy of the conjunctiva and its consequences, but also—oftener, I think, than we are aware of—absorption of the morbid material with virtually, if not actually, a healthy conjunctiva. Such recoveries—the full restoration of the healthy state—I have frequently seen, both in the follicular catarrh (vesicular or miliary granulations) and in the true follicular trachoma. Without remedies or with weak astringents or the most superficial touchings with blue-stone the granules disappeared and the conjunctiva, in aspect and function, was perfectly normal and remained so. This, the ideal cure of trachoma, can, I think, be obtained even by the sulphate of copper treatment in most cases—even with

very dense granular infiltration of the upper as well as the lower retro-tarsal folds—when atrophy is not yet present and the patients do not interrupt the treatment. The results in private were not so favorable as when the patients were admitted to the hospital and stayed till they were cured. The time in advanced granular infiltration varied from three to six months. The results obtained in dispensary practice were, as a rule, unsatisfactory.

Unfortunately the majority of cases come under our observation when more or less atrophy has taken place. In these as in all cases the object of our treatment must be to arrest the progress of the disease at once and to eliminate the morbid material with as little destruction of healthy tissue as possible. Excision of the infiltrated part of the conjunctiva does least fulfil this end; galvano-cautery does not rank much higher; electrolysis also is liable, it seems, to sacrifice more healthy tissue than is necessary; "brossage" and "grattage"—in plain English brushing and scratching—also seem needlessly violent procedures. Darier ("Traitement chirurgical de la conjonctivite granuleuse," Paris, June 15, 1891, p. 7) says: "The brushing must be energetic to remove the whole contents of the granulations, without tearing off the conjunctival shreds ('languettes') the sparing of which is important." Abadie, in the discussion on this subject before the Ophthalmol. Soc. of Paris, July 7, 1891, says: "By this scrubbing the mucous membrane unweaves and looks somewhat like picked lint (la mugueuse s'effile, prend un peu l'aspect de la charpie)."[1]

Curetting, *i. e.*, ripping the granulations with a needle and scooping out their contents singly with a small sharp spoon, if it can be done without scraping off healthy tissue, seems a tedious procedure.

There remain the different modes of pressing out the granulations. This method, old in its beginning, has been practised recently by a number of oculists, among whom I may mention Mandelstamm,[2] Hotz,[3] E. Sargent,[4] Noyes.[5]

---

[1] *Rec. d'ophtal.*, 1891, p. 485.
[2] *Graefe's Arch.*, year 1883, No. 1, p. 100.
[3] These ARCHIVES, vol. xv., p. 147, 1886.
[4] "Transact. Cal. State Med. Soc. for 1890," p. 238.
[5] "Textbook on the Diseases of the Eye," 1890, p. 321.

Hotz and Noyes are the two authors who most emphatically recommend this method. Hotz pressed the granulations of the upper lid out with his finger-nails, those of the lower lid with the curved branches of a pair of toothless forceps. Noyes uses two pairs of forceps whose handles end in two grooved plates, placed at right angles to the branches. Between these the conjunctiva is stripped of its granular deposits, the four lids in one sitting. I had the good fortune of seeing Dr. Noyes perform one of these operations in a marked case of follicular trachoma, March, 1891. It impressed me more favorably than any of the other procedures with which I had become acquainted either by reading or as an eye-witness, and I was determined to give this method a fair trial. I used Dr. Noyes' forceps and also the ring-forceps with which Dr. Prince, of Springfield, Ill., had presented me two years previously. Both answered the purpose, but thinking that they tore the tissue, in particular stripped off the epithelium, more than was needful, I had a roller-forceps made by Geo. Tiemann & Co., with which I have done all my trachoma operations ever since.



The instrument is made according to the principle of the mangle. The branches of ordinary, rather strong, forceps divide at their ends like a horse-shoe, the free space of which is closed by a creased steel cylinder which rolls on pivots in sockets. The ends of the forceps thus resemble a stirrup. (See accompanying drawing, which presents an older pattern. The newer instruments have conical pivots which dip into corresponding depressions. Tiemann & Co. proposed also to make an instrument with longer limbs of the stirrup and a set screw to remove and cleanse the pivots and sockets. At my suggestion they made the branches a little longer and somewhat elastic, so that the cylinder can be removed and reinserted.) The rolling cylinder (the foot-plate of the stirrup) is 20 to 25 *mm* long and 1 to 1.5 *mm* thick. It is made of steel, and can be taken apart to be

cleansed, if need be, but the ordinary cleansing with soap and water and sterilizing in boiling water are sufficient to keep it aseptic. I had a pair made of platinum which could be sterilized in a spirit flame, but found this an unnecessary precaution. I am sorry to say that the workmanship of the instrument is not always as perfect as it should be. Bending of the pivots, uneven bore of the socket, too tight a fit, and other imperfections diminish the ease with which the cylinders should turn. Blood-clots and débris of tissue adhering to the joints also interfere with the turning and should be removed as often as they collect. It is advisable always to have on hand two pairs of forceps so that during the progress of the operation they may be changed and cleansed in an antiseptic fluid. If well made and kept clean they turn very readily. Of course the less pressure used the less is the resistance—instead of turning they slide over the tissue. Practically this is of very little importance, for at the beginning of the operation when the folds held between the cylinders are thick or hard, the pressure and resistance being great, the cylinders turn easily, and later when the trachomatous substance is squeezed out the folds are thin, smooth, and even, so that only little pressure from the forceps is required, and the mucous membrane will not be torn or the epithelium stripped off, even when the rods do not roll but simply slide.

The *mode of application* is as follows: The patient is etherized, except in mild cases of superficial granular deposition, in which cocaine anæsthesia penetrates deeply enough to perform the operation without pain. The upper lid is everted, seized at the convex border of the tarsus with ordinary fixing forceps and drawn off the eye so as to expose the whole palpebro-bulbar conjunctiva. The infiltrated part is then—or is not—superficially scarified with the three-bladed "sillonneur" of Johnson.[1] One blade of the forceps is pushed deeply between the ocular and the palpebral conjunctiva, the other applied to the everted surface of the tarsus; the forceps are compressed with more or less force, drawn forward, and the infiltrated soft substances squeezed

[1] See his paper in these ARCHIVES, vol. xix., p. 268, 1890.

out as the cylinders roll over the surfaces of the fold held between them. This manœuvre is repeated all over the conjunctiva until the granules and the juice are completely pressed out of the tissue. The forceps pass two or three times over the same place, until the absence of resistance proves that all foreign tissue substance is removed.

The lower lid is treated in the same way, only it is not necessary to use fixing forceps. An assistant everts the lid by drawing it down.

If the tarsal conjunctiva contain granules, which is quite frequent, one blade of the forceps is applied to the skin, the other to the conjunctiva, and the instrument drawn across several times until all the granules have disappeared. The tarsal surface then looks finely striated from the impression of the ridges of the grooved cylinders rolling over it, whereas the skin shows no action of the instrument at all. It is necessary to squeeze the conjunctiva near both commissures with particular care, and not omit the caruncle if it is affected. In handling the forceps the traction ought to be straight in the direction of the handle, not sideways, which would interfere with the easy turning of the rods. This and similar details in the handling of the instrument every one will soon find out.

There is, in most cases, moderate bleeding during the operation. When, during and after the operation, the blood is wiped off with absorbent cotton or a fine sponge, the conjunctiva is swollen but perfectly even, free from granules or diffuse infiltration, and without any laceration. In cases of follicular trachoma the empty nests of the granules are indicated by points of dark blood.

In a well marked case, where the four lids are studded with granulations, the operation, done thoroughly and without haste, takes about ten minutes.

The mucous membrane is washed with ordinary water, or a mild antiseptic, boric acid, 2 per cent., or bicloride of mercury, 1:5000. No bandage is applied. The patient, as soon as he comes to, opens his eyes, feels no pain, and goes home as if nothing had been done. Neither a bandage, nor cold applications, nor anything else is required. He washes his

eyes several times a day, and in a few days attends to his business again.

The lids not infrequently swell somewhat, rarely much. The conjunctiva is swollen for several days, even in some cases for one or several weeks. It is not rare to see the retro-tarsal folds coated with a layer of coagulated lymph, which disappears in a few days.

In the great majority of cases the recovery is rapid and free from irritation. In some cases, however, there is considerable reaction; the conjunctiva is swollen, the pannus denser, *i. e.*, more vascular, the sight dimmer, and there may be one or two small white patches in the cornea—in short, the condition of a spontaneous acute exacerbation of trachoma. These aggravations should be treated with cold applications, antiseptic collyria, and rest. They soon disappear.

In other cases, of long duration, diffuse infiltration, and cicatrices, the operation is followed by increased congestion, so-called papillary swelling of the conjunctiva. The mucous membrane shows the same aspect as in the final stage of purulent ophthalmia, and should be treated like this, namely, a one or two per cent. solution of nitrate of silver brushed over the swollen parts daily or every other day. If the conjunctiva shows less papillary unevenness, but is swollen, and the tarsus infiltrated, after-treatment with the sulphate of copper crystal should follow the operation, in the same way as we treat trachoma when in its natural course it has reached its final stage.

In a few cases—I remember two, in young men—the operation is followed by increased swelling of the conjunctiva, and apparently a fresh infiltration of miliary granulations. They disappear rapidly by brushings with nitrate of silver solution and touchings with blue-stone.

From March 21, 1891, until December 16, 1891, I have treated in this way 114 cases of trachoma, and kept notes of them all as carefully as it could be done with out-patients. I will consider them under five heads:

1. *Follicular catarrh*—16 cases. Fifteen were cured. Some had been treated very long, with collyria and blue-stone.

One had a fresh outbreak of granulations soon after the squeezing. It is being treated with blue-stone and rapidly improves.

2. *Follicular trachoma*—64 cases. The spawn-like granules were characteristically developed, scattered over upper and lower conjunctivæ, mostly without irritative symptoms or affection of the cornea, not rarely one eye being intact. **In this form the expression method triumphs.** One sitting almost always suffices permanently to cure both eyes, restoring a virtually healthy conjunctiva.

Of the 64 *cases*, 54 were cured, and the records of most of them go over longer periods, from three to nine months. Of 8, no records of the recovery were made, but there is little doubt that they were cured. One case was "squeezed" a second time, as some granules had been left at the outer canthus. Another was reported by one of our colleagues (Dr. Weeks) at the N. Y. Eye and Ear Infirmary as having had some granulations left in the tarsal conjunctiva (for which "grattage" was used), none in the retro-tarsal folds. Another did well for months, but lately—six months after the operation—he presented himself again with a crop of miliary granulations, for which he should be operated on again.

A child of two and one half years had both eyelids of each eye excessively swollen, and studded all over with miliary granulations. Her brother, two months old when brought to me, had had blennorrhœa neonatorum, for which I had treated him. I ordered antiseptics, and cold applications to the eyes for a week or two, and when the swelling had somewhat subsided, I squeezed the four lids at the same sitting, but rather cautiously. The reaction was not great, but the papillary roughness remained marked, and I had to treat the child with a one per cent. solution of nitrate of silver, two months, before the swelling and granular infiltration disappeared. Bolder pressing might have produced a quicker recovery, but I wanted to be extremely careful in these therapeutic studies of trachoma, in order not to have my conscience loaded with a case of blindness, as it happened when jequirity was represented to be so innocent.

3. *Diffuse trachoma*—22 cases. Seventeen cured; three

not reported after the operation; one had a relapse and was "squeezed" a second time; another, six months later, had an acute attack of conjunctivitis, but without granulations.

4. *Cicatricial trachoma*—10 cases. Seven were cured, as far as these cases can be cured, *i. e.*, with smooth, more or less shrunken conjunctivæ, and frequently corneal opacities, but no more irritative symptoms. Of two, there is no record after the operation. One, an old and bad case, was squeezed a second time. No trachomatous substance came out. Left off treatment for four months. Now (Dec.) one eye cured, the other had again glassy infiltrations between the cicatrices, which were pressed out successfully.

5. *Horny summer granulations*—2 cases. One mild, cured; one old and severe, much improved the first week, then hot weather set in and the eye was greatly irritated. Later on, considerable improvement, no recovery as yet. These cases, over which we have so little control, end in recovery, but it takes years.

The results of this series of cases have certainly been satisfactory. In the majority no after-treatment has been required; in others a sulphate of copper crystal or a nitrate of silver solution was used for weeks or even longer. Yet the treatment, also in these cases, was materially abridged by the operation. It is too short a time to judge of the final value of this mode of treatment. Relapses may occur in other than the few cases in which they have come to my notice. One thing I can say: I am not aware that in this whole series one eye was made worse, for the two eyes with a crop of miliary granulations are yielding fast under nitrate of silver treatment. In two cases of cicatricial trachoma, one eye was operated on by expression, the other by grattage, according to Abadie-Darier, by my former pupil Dr. Marple. In the first, both eyes showed about the same reaction, and both did well; in the other case, the reaction from the grattage was rather severe. The patient has been lost sight of.

In conclusion I may be allowed to say a few words of a theoretical bearing. Most authors—Sattler, Abadie, Darier, Weeks, and others—lay great stress on the infusion of a

strong antiseptic, corrosive sublimate 1:500, etc., into the depth of the infiltrated lids. I want to say that in most cases I used no antiseptic at all, and never a stronger one than bichloride of mercury 1:5000. Nevertheless the cases recovered as well as those reported by the above authors, and, yet, I believe in the infectiousness of trachoma, not only of the diffuse and cicatricial forms, but of the follicular without irritation, and even the follicular catarrh. The infectiousness, I think, is clinically proven by the indisputable contagiousness of the disease, though the bacteriological evidence is not yet convincingly established. If I am asked, why I did not use germicides, though believing in the infectious nature of trachoma, I answer that any infectious disease may be recovered from without antiseptics. In the clinical study under consideration, I wanted to subject each factor of the problem to the test of experimentation as singly as we can make it. One truth has come to light: Antiseptics are not a condition *sine qua non* in the cure of trachoma. This truth was established before, not only by spontaneous recoveries, but by numerous observations of the fact that portions of trachomatous conjunctiva, left after partial excision, do not as a rule spread the infection over the unaffected parts, but disappear, and the eye is totally and permanently cured. The same observation is made in other modes of treatment of trachoma. Neither galvano-cautery, nor electrolysis, curetting, expression, nor even grattage, with copious infusion of bichloride, can be supposed to destroy all the germs that are in a conjunctiva. It seems that it is sufficient to remove the greater part of them. The restorative properties of the organism will then be strong enough to counterbalance the effects of a small quantity of microbes, or rather of their secretions. The elimination of bacteria, by all of the mechanical modes of treatment, will, I think, also be aided by the blood and lymph streams from the depth to the surface of the wounds, acting as drains on the diseased tissues.

SYSTEMATIC REPORT ON THE PROGRESS OF OPHTHALMOLOGY DURING THE FIRST QUARTER OF THE YEAR 1891.

By ST. BERNHEIMER, Heidelberg; C. HORSTMANN and P. SILEX, Berlin.

WITH THE CO-OPERATION OF

S. M. Burnett, Washington; Dantone, Rome; Hirschmann, Charkow; E. Marckwort, Antwerp; P. v. Mittelstädt, Metz; L. Werner, Dublin; C. H. A. Westhoff, Amsterdam; Schiötz and Ole Bull, Christiania, and Deus, Berlin.

Translated by Dr. F. E. D'Oench, New York.

Sections I.–IV. Reviewed by Dr. ST. BERNHEIMER.

I.—GENERAL OPHTHALMOLOGICAL LITERATURE.

TEXT-BOOKS, MONOGRAPHS, TREATISES ON GENERAL, BIBLIOGRAPHICAL, AND HISTORICAL SUBJECTS.

1. Brooklyn Eye and Ear Hospital. Twenty-second annual report, 1890.

2. Illinois Charitable Eye and Ear Infirmary. Seventeenth biennial report, 1890.

3. Maine Eye and Ear Infirmary. Fifth annual report, 1890, E. E. Holt.

4. Massachusetts Charitable Eye and Ear Infirmary. Sixty-fifth annual report, 1890.

5. Presbyterian Eye, Ear, and Throat Charity Hospital, Baltimore, 1890. Thirteenth annual report.

6. Howe, Lucien. Legislation for the prevention of blindness. *Trans. Amer. Ophth. Soc.*, 1890.

7. BULLETIN DE LA CLINIQUE NATIONALE OPHTALMOLOGIQUE DE L'HOSPICE DES QUINZE-VINGTS PAR LES DOCTEURS A. TROUSSEAU ET A. CHEVALLEREAU, MEDECINS TITULAIRES, LES DOCTEURS VALUDE ET KALT, MEDICINS ADJOINTS. Paris, 1891 (1890–1891).

8. MAGNUS. Report of his Ophthalmic Hospital at Breslau from April 1, 1889, to Dec. 31, 1890.

8a. E. LOPEZ. Ophthalmological service of the "Mercedes" Hospital. Operations in 1890: 3 peritomies, 2 pterygia, 2 iridectomies, 2 enucleations, 13 cataracts. Of the latter there were 10 good results, 2 moderate, 1 unknown.

The report of Drs. Mathewson, Prout, and Rushmore, of the BROOKLYN EYE AND EAR HOSPITAL (1) for 1890, gives a total of 5,822 eye patients. Ten extractions with iridectomy, three without, and one in the capsule. BURNETT.

The seventeenth biennial report of the ILLINOIS EYE AND EAR INFIRMARY (2) (Drs. Holmes, Hotz, Montgomery, Ware, and Gardiner) shows 4,888 eye cases for the two years, with 721 operations, including the minor ones. 101 of these were for cataract. BURNETT.

In HOLT'S INFIRMARY (3) there were 871 new eye patients registered in 1890 and 273 operations, of which 38 were extractions of cataract, 11 without iridectomy. BURNETT.

The sixty-fifth annual report of the MASSACHUSETTS EYE AND EAR INFIRMARY (4) (Drs. Derby, Shaw, Jeffries, Willard, Bradford, and Chandler) shows 676 resident eye patients and 10,931 ambulatory. There were 144 extractions, which are carefully tabulated by F. P. Sprague. Of these 92 were after the method of Graefe; only 3 were simple. There were 10 suctions. There was total loss in 1, panophthalmitis in 3, light perception in 4. BURNETT.

The thirteenth report of DR. CHISOLM'S HOSPITAL (5) shows 6,464 eye cases, 93 extractions without iridectomy, 20 with iridectomy, 8 in the capsule. BURNETT.

HOWE'S (6) paper is a plea for legislation for the prevention of blindness especially by ophthalmia neonatorum. Good work in this line has already been done in the State of New York, and we quote the law which has gone into effect in that State during the last year: "(1) Should any midwife or nurse, having charge of an infant in this State, notice that one or both eyes of such infant are inflamed or reddened at any time within two weeks after its

birth, it shall be the duty of such midwife or nurse so having charge of such infant, to report the fact in writing within six hours to the health officer or some legally qualified practitioner of medicine of the city, town, or district in which the parents of the infant reside. (2) Any failure to comply with the provisions of the act shall be punishable by a fine not to exceed one hundred dollars, or imprisonment not to exceed six months, or both. (3) This act shall take effect on the 1st of September, 1890."

The annual report of the HOSPICE DES QUINZE-VINGTS (7) for 1890 shows an attendance of 14,050 new patients, of whom 1,469 were admitted. The physicians in charge, Drs. Trousseau, Chevallereau, Valude, and Kalt, deliver a lecture once a week on a certain chapter of ophthalmology ; once a week patients are presented, followed by a discussion of the cases by the physicians of the hospital. Among the operations the extractions of cataract occupy the most prominent place. All the physicians operate without iridectomy, and are very well satisfied with the results. The patients usually leave the hospital at the end of nine days unless prolapse of iris or other complications have taken place ; the former occur in about six per cent. of all cases, and are either replaced, abscised, or cauterized. Trousseau operates with the knife alone without the aid of any other instruments, as he believes that they increase the danger of infection and prolapse of iris and injure the eye unnecessarily. His colleagues use the customary instruments (with the exception of Valude, who opens the capsule with the knife) and remove the speculum and fixation-forceps after the corneal section. One operator recommends eserine, the other considers it useless, likewise the washing out of the anterior chamber, which, however, is done only with sterilized distilled water. The bandage is not changed if possible until the fourth day. For the prevention of sympathetic ophthalmia resection of the optic nerve is practised besides enucleation, the former being the operation which they think should be resorted to if possible. Intraocular injections in such cases as well as in detachment of the retina proved useless.

V. MITTELSTÄDT.

II.—GENERAL PATHOLOGY, DIAGNOSIS, AND THERAPEUTICS.

9. TORNATOLA. Infezione purulenta secondaria dell'occhio. Ricerche sperimentali di batteriologia. *Ann. di Ottalm.*, vol. xix., 5–6, p. 480.

TORNATOLA (9) has made some very interesting investigations on so-called secondary infection in three series of twelve rabbits each, and found the following important facts : (1) In the twelve animals, under whose skin or into one of whose joints a pure culture of staphylococcus pyogenes albus had been injected (in bouillon), a severe local inflammation set in, a few of them died ; but a corneal wound produced aseptically at the same time, healed in a normal manner even when the iris was injured. (2) The same result was obtained in the second series of experiments, in which panophthalmitis was produced in one eye by the injection of the culture, while the other eye had been subjected to an aseptic operation. (3) In the twelve rabbits, however, in which the operation was performed with the same precautions, but the infectious solution was injected into the veins of the animal's ear, panophthalmitis developed in seven cases, resulting in destruction of the eye. In considering the indications for an operation, foci of suppuration which may be present in any part of the body should be taken into serious consideration, so that infection of the wound in the eye may not take place in consequence of purulent destruction of venous thrombi. DANTONE.

III.—ANATOMY.

10. DARKSCHEWITSCH, L. On decussation of the fibres of the optic nerve. *Graefe's Arch. f. Ophth.*, vol. xxxvii., 1, p. 1.

11. LANGER, F. Is it justifiable to consider the perichoroidal and Tenon's space a lymph-space ? Vienna, 1891.

12. NICATI, W. La glande de l'humeur aqueuse, glande des procès ciliaires ou glande uvée (Suite). *Arch. d'opht.*, vol. xi., 1, 2.

13. RIEKE, A. On the forms and development of the pigment-cells of the choroid. *Graefe's Arch. f. Ophth.*, vol. xxxvii., 1, p. 62.

14. TOPOLANSKI, A. The structure of the zonula and its surroundings, with remarks on the albino eye. *Graefe's Arch. f. Ophth.*, vol. xxxvii., 1, p. 28.

DARKSCHEWITSCH (10) has considered it necessary to disprove once more Michel's assertion of the total decussation of the optic nerves of the higher mammals and man. He succeeds, as could now be expected, by dividing a tractus : both optic nerves showed

partial atrophy of their fibres. He operated on a new-born cat. He found the left divided tractus completely atrophic, the right somewhat smaller than in a healthy animal of the same litter. Both optic nerves were preserved and consisted of normal fibres, but they were somewhat smaller than those of a healthy animal, the right being somewhat thinner than the left.

According to the investigations of LANGER (11) neither the meshes between the choroid and sclera, nor the spaces between the latter and the muscles of the eyeball can be considered lymph-spaces. Tenon's space exists as such only between the tendons of the ocular muscles and the sclera; beyond that, the more the posterior pole of the globe is approached, the more tissue of increasing density is found, which passes into the sclera without forming a space with the latter. There is no perivascular space around the vortex veins. HORSTMANN.

In the second part of NICATI'S (12) very interesting paper, he discusses the physiological changes in the secretion of the aqueous humor and by numerous experiments, the details of which cannot be given in a review, seeks to determine the locality of its secretion, its dependence upon the blood-pressure and the intra-ocular pressure, and upon nervous influence. The essential points are as follows: the aqueous humor is secreted by the glandular epithelium which covers the ciliary processes from the ora serrata to the origin of the iris. This epithelium does not permit the salts injected into the blood to pass through, only when great quantities are injected does diffusion take place, which is favored by division of the cervical sympathetic nerve. In occlusion of the pupil a small quantity of aqueous is also discharged by the anterior surface of the iris. The aqueous humor first obtained by puncture does not coagulate, and remains colorless when fluorescin is injected subcutaneously. The aqueous subsequently discharged, coagulates, and is colored. This coagulable variety of the aqueous, which fills the anterior chamber three minutes after the first puncture, comes from the spaces between the epithelium. This secretion is the result of a disturbance of equilibrium between the intra-ocular and the blood pressure, and does not take place in a purely mechanical manner, but by reflex action through the nerves of secretion. After various experiments in dividing the fifth nerve at different parts of its course (corneal nerves, ciliary nerves, in front of and behind Gasser's ganglion) and also the medulla oblongata, the author comes to the conclusion that the

ciliary ganglion is the centre of secretion. This centre is in constant action which is opposed by the fifth nerve, Gasser's ganglion, and the medulla oblongata after dividing which or also the deep ciliary nerves (which form the peripheral source of the reflex) the discharge takes place in much less than the usual time of three minutes. Division of the cervical sympathetic nerve of the opposite side of the cervical spinal cord, and iridectomy, retard the reflex.

In the third part Nicati discusses the changes due to retention or increased secretion of aqueous humor: glaucoma. In accordance with the results of physiological experiments, iridectomy must be considered the real operation for glaucoma, while the effect of anterior and posterior sclerotomy is confined to narrow limits and therefore only temporary. Detachment of the retina he explains by saying that when the aqueous flows backward in suddenly diminished tension (especially in stooping, in rising in the morning after prolonged rest on the back), the hyaloid and with it the ora serrata of the retina are detached (experimental detachment by injection of water from the anterior chamber). Parencentesis, iridectomy, injection of liquid (vitreous) into the vitreous are indicated from the author's experiments and, in view of the poor prognosis, permissible. v. MITTELSTÄDT.

RIEKE (13) examined the shape of the choroidal pigment cells in various mammals, and found that all of the pigment is formed within the cells and varies from an almost round to a highly ramified shape. The cells are generally arranged along both sides of the blood-vessels. The aggregations of pigment may perhaps be offsets which have remained adherent, or remnants of disintegrated cells. The diffuse distribution of the granules of pigment he ascribes to the destruction of former pigment-cells. The pigmentation of the human choroid begins in about the seventh month of pregnancy.—In the third part of his paper the author discusses the development of the pigment in the pigment-cells. He thinks that for normal conditions the formation of pigment from blood has not been proven. He supposes that it develops in the fixed connective-tissue cells, and that the pigment is not brought to them by the wandering cells. The pigment free from iron he considers autochthonous, due to metabolic action of the cells.

TOPOLANSKI (14) favors Czermak's view, that the zonula is composed of fibres, namely, 1 orbiculo- and cilio-capsular, 2 orbiculo-ciliary, and 3 inter- and intra-ciliary fibres.

IV. PHYSIOLOGY.

15. FISCHER, R. Estimates of size in the visual field. *Graefe's Arch. f. Ophth.*, vol. xxxvii., 1, p. 97.

16. GREEN, JOHN. An elementary discussion of some cases of centrical refraction through tipped spectacle lenses. *Trans. Amer. Ophth. Soc.*, 1890.

17. HARLAN, G. C. Transient pulsation of retinal arteries induced by application of homatropine. *Trans. Amer. Ophth. Soc.*, 1890.

18. HELMHOLTZ. Attempt at an extended application of Fechner's law to the system of colors. *Zeitschr., f. Psych. u. Physiol. d. Sinne*, vol. ii.

19. LIPPINCOTT, J. A. New tests for binocular vision. *Trans. Amer. Ophth. Soc.*, 1890.

20. ROMANO. Sulla funzione delle radici del nervo oculomotore e sui movimenti riflessi dell'iride. *Ann. di Ottalm.*, vol. xix., 5–6, p. 501.

21. SNELLEN. Opennigsrede van het derde Nederlandsch Natur en Geneeskundig Congres. *Nederlandsch Tijdschrift voor Geneeskunde*, 1891, 1, p. 431.

GREEN'S (16) consideration of the optical properties of tipped lenses, which is very lengthy, adds nothing to what is already known, except perhaps in the matter of toric lenses. BURNETT.

HARLAN (17) found a marked pulsation of the retinal arteries produced by homatropine in a man of sixty-six. The phenomenon was observed at three successive instillations. No signs of glaucoma were present. BURNETT.

LIPPINCOTT (19) employs in his test for stereoscopic vision the fact that metamorphosia is produced by the use of a cylinder before one eye, when there is binocular vision. The method he uses is to place a 2 D cylinder before one eye, say axis vertical, and holding a rectangular card or book before the patient, ask if the one side or the other is higher. If it is, then binocular vision exists. Changes can be rung to minus cylinders, and axis vertical or horizontal. BURNETT.

By numerous experiments on dogs, ROMANO (20) has discovered the special centres governing the muscles supplied by the oculomotor nerve, and has determined their position and extent along the aquæductus Sylvii, from the corpora quadrigemina.

DANTONE.

SNELLEN (21) discusses the wave theory of Huyghens and the emission theory of Newton, and gives great praise to the researches of Thomas Young and Fresnel. He therefore ascribes the progress of science not to accident, or to intuition, but to the continuous combined labor of many. WESTHOFF.

Sections V.–X. Reviewed by PROF. HORSTMANN.

V.—ANOMALIES OF REFRACTION AND ACCOMMODATION.

22. JACKSON, E. Progressive hyperopic astigmatism. *Trans. Amer. Ophth. Soc.*, 1890.

23. JACKSON, E. Tests for visual acuteness. *Journ. Amer. Med. Assoc.*, Jan. 31, 1891.

24. NUEL, J. P. D'une apparence ophtalmoscopique de l'œil myope. Contribution à la connaissance de la prédisposition héréditaire à la myopie. *Arch. d'opth.*, vol. xi., 1, p. 56.

25. OTT, F. On high degrees of myopia. *Inaug. Diss.*, Strassburg, 1891.

26. PEDRAZZOLI. Un "ottodinamometro." *Ann. di Ottalm.*, vol. xix., 5–6, p. 423.

27. PUKALA, V. On the injurious influence of the accommodation upon the increase of myopia of the highest degrees. *Amer. Journ. Ophth.*, March, 1891.

28. RANDALL, B. A. Can hypermetropia be healthfully outgrown? *Trans. Amer. Ophth. Soc.*, 1890.

29. RANDALL, B. A. Some disputed points in the correction of refraction errors. *Journ. Amer. Med. Assoc.*, Jan. 10, 1891.

30. ROOSA, D. B. ST. JOHN. Constitutional conditions combined with ametropia the cause of asthenopia. *N. Y. Med. Journ.*, March 28, 1891.

31. SECONDI, G. Valore di A. nel campo di sguardo. *Ann. di Ottalm.*, vol. xix., 5–6, p. 510.

32. SIMON, R. Contributions to the knowledge of astigmatism, especially in regard to visual acuteness. *Inaug. Diss.*, Strassburg, 1891.

33. WEISS, L. On the occurrence of sharply defined ectasias at the posterior pole in high degrees of myopia. *Arch. f. Augenhk.*, vol. xxiii., p. 194.

JACKSON (22) reports seventeen cases in which the hyperopic astigmatism had increased in eyes which had been examined under a mydriatic. In none is it recorded that an ophthalmometric measurement of the cornea was made. He thinks the change due to some pathological change taking place in the anterior part of the eyeball. BURNETT.

JACKSON (23) points out the defects of our ordinary Snellen types and uses one like the block letter E, which Snellen also recommended for the illiterate. This, however, only subtends an angle of four minutes. He prefers and uses an artificial illumination. BURNETT.

NUEL (24) describes a hitherto scarcely described arrangement of the retinal blood-vessels in highly myopic eyes; they ramify more or less immediately after their exit from the papilla, instead of passing upward and downward, and pass obliquely upon the papilla towards the temporal side, in a straighter line than usual, those going from the temporal half of the papilla towards the macula taking an especially straight course. At the same time there is a large physiological excavation with a large atrophic crescent towards the temporal side. The author never found this arrangement of the blood-vessels in emmetropic or hypermetropic, and but rarely in slightly myopic eyes. He saw it, however, in a temporal coloboma of the optic nerve, and ascribes it in high degrees of myopia to a shifting of the retina, due to the stretching of the posterior pole in the temporal direction. He believes that this arrangement of the blood-vessels or the condition favoring its development is congenital, and is an important symptom in recognizing the development of a high degree of myopia, the cause of which is also congenital, and perhaps attributable to imperfect closure of the posterior pole of the eye. V. MITTELSTÄDT.

OTT (25) found among 24,036 patients of the Strassburg eye clinic 489 cases of high degrees of myopia, partly binocular, but in many confined to one eye. The female sex predominated. Myopia of more than 8 D only was considered. Normal sight was found in only 50 eyes (5.9 %), affections of the macula lutea were observed in 155 eyes, opacities of the lens in 61, of the vitreous in 88, detachment of the retina in 21, the latter always confined to one eye. Strabismus was found in 30 patients, 23 of divergent and 7 of convergent strabismus.

PUKALA (27) is of the opinion that the use of the accommodation has a pernicious effect upon myopia of high degrees, and that

the myope loses nothing, but on the contrary gains by becoming aphakic. BURNETT.

RANDALL (28), from a study of all the statistics at his command as well as from his own observations, has reached the conclusion that it is extremely doubtful if hypermetropia ever decreases except under pathological conditions. BURNETT.

RANDALL (29) thinks emmetropia a rare condition, but only in a portion of cases does the ametropia require correction. He prefers hyoscyamine as a mydriatic, and thinks a full correction, except in some particular instances, should be worn. He speaks well of skiascopy as a test for refraction. BURNETT.

ROOSA (30) reiterates his views that refractive errors are at the foundation of all asthenopias, and his disbelief in an independent asthenopic muscular insufficiency. He believes that ametropia exists in 90 % of the human race. BURNETT.

SIMON (32) presents the result of his examination of 200 astigmatic eyes in 119 persons, 74 males and 45 females. He confirms the view of Donders, that the maximum of curvature corresponds about to the vertical meridian. Simple hyperopic astigmatism occurred most frequently. The symmetrical or asymmetrical position of the axes of the principal meridians must not be overlooked, especially in estimating vision in binocular astigmatism. Sight in cases of astigmatism against the rule was better than in those of astigmatism according to rule.

According to WEISS (33) the so-called posterior staphyloma, so frequently seen in myopia, is not a true staphyloma, as the blood-vessels crossing its edge take a straight course, so that there can be no difference of level. Genuine posterior staphylomas, however, occur, pouch-like, sharply defined ectasias at the posterior pole, where the retinal blood-vessels pass with a marked break in direction from the bottom of the pit to the surface of the adjacent retina. Weiss saw a number of such ectasias on the nasal side of the papilla, the edge of which sloped away upward and downward and only partly coincided with the margin of the so-called staphyloma. There was a high degree of myopia in all of the eyes.

VI.—LIDS.

34. BENSON, A. Blepharocheiloplastic operations. *Brit. Med. Journ.*, Feb., 1891, p. 281.

35. DEUTSCHMANN, A. The pathology of chalazion. *Beiträge zur Augenhk.*, 1891, No. 2, p. 109.

36. FRÄNKEL. Unilateral involuntary movement of the lids in chewing. *Zeh. klin. Monatsbl. f. Augenhk.*, vol. xxix., p. 93.

37. FUKALA. Two methods of operating for the cure of senile ectropium and ectropium following blepharitis. *Berliner klin. Wochenschr.*, 1891, No. 11.

38. HARLAN, G. C. A new operation for symblepharon. *Trans. Amer. Ophth. Soc.*, 1890.

39. HEISRATH. Operation for ptosis. *Berliner klin. Wochenschr.*, 1891, No. 3.

40. KNAUER, F. On ptosis and its treatment, with special reference to Pagenstecher's thread-operation. *Inaug. Diss.*, Weisbaden, 1891.

41. MITVALSKY. The pathology of circumbulbar dermoid cysts. *Arch. f. Augenhk.*, vol. xxiii., p. 109.

42. POOLEY, T. R. Operation for ectropion of the lower lid by the sliding flap method. *Trans. Amer. Ophth. Soc.*, 1890.

43. PROSKAUER, THEO. Congenital ptosis and associated movements of the paralyzed lid. *Centralbl. f. prakt. Augenhk.*, 1891, p. 97.

44. RAEHLMANN, E. Therapeutic experiences in operations on the edge of the lids, and in transplantation of skin and mucous membrane to the eye. *Deutsche med. Wochenschr.*, 1891, No. 1.

45. WICHERKIEWICZ, B. A new blepharoplastic method for covering the loss of substance after removal of a tumor involving the whole lid. *Zehn. klin. Monatsbl. f. Augenhk.*, vol. xxix., p. 20.

BENSON'S (34) blepharocheiloplastic operation is a modification of that of van Millingen. Mucous membrane from the upper lip is transplanted into the intermarginal incision of the lid and attached with sutures. The result was a permanently good one.

WERNER.

According to DEUTSCHMANN (35) the pathological change in chalazion begins in the follicles of Meibom's glands, and consists in a steady proliferation of the epithelium of the acini. This proliferation fills the latter either completely, or a broken-up mass of sebum, enclosed by the cells, is found in the centre. Meanwhile round and epithelioid cells begin to accumulate around the acini, especially around the capillary blood-vessels, soon filling the

entire tissue and coming partly from the blood-vessels, partly from the fixed tissue cells. The cellular infiltration of the surroundings of the gland increases to such an extent that the affection of the latter is almost lost sight of. The tarsus also becomes similarly affected, and finally the whole is converted into a mass of tissue filled with cells. Sometimes so-called giant cells are found in it, which develop from the proliferated epithelium of the follicles. The pathological change in chalazion, therefore, is a chronic inflammation of a Meibomian gland attended with proliferation of the epithelium of the glands and subsequent chronic inflammation of the surrounding connective tissue. In opposition to Tangl's view it is not the result of a tuberculous inflammation, the results of inoculation being negative in every case.

FRÄNKEL (36) observed in a child unilateral involuntary lifting of the lid in chewing. When it masticates while looking down, or if it opens the mouth wide, the upper lid of the left eye is raised with a jerk, exposing a large part of the sclera.

FUKALA (37) operates for senile and sarcomatous ectropium by excising the whole ectropionized portion and then uniting the skin at the edge of the lid with the conjunctiva. In ectropium of marginal blepharitis he detaches the skin of the lid from the tarsus in its whole length. The two ends of the thread are tied upon the skin.

In a case of extensive symblepharon of the lower lid HARLAN (38) dissected the lid from the ball fully, and then cut the lid from the outer to the inner canthus at the orbital margin, thus detaching it completely except at the canthus. Through this opening he passed a flap of skin, dissected from the cheek below, and attached it, with its epithelial side towards the ball, to the margin of the lid. The case has done well to date. BURNETT.

For the cure of ptosis HEISRATH (39) recommends excision of a broad strip of tarsus with the conjunctiva from the whole breadth of the lid. After ectropionizing the upper lid an incision is made parallel to the free margin at a greater or less distance from it, according to the amount of effect desired; the tarsus is detached from the tissue beneath and abscised at the boundary of the fornix. The edges of the wound are united with three or four sutures.

KNAUER (40) recommends Pagenstecher's thread-operation in ptosis, as no other method yields better results or equals it in simplicity.

Pooley's (42) case was a woman of forty-eight, from whose lower lid an epithelioma had been removed, leaving an extensive ectropion. The edge of the lid, which was intact, was dissected along with the conjunctiva from their attachment to the malar bone and the lid stitched to the upper lid. The defect thus caused was filled in by a flap from the temple. The upper incision was 10 *cm* and the lower 8.7 *cm* in length. It was drawn forward and attached to the edges of the opening by twenty-four sutures. The healing was perfect. Burnett.

In a patient with a high degree of left-sided congenital ptosis and paresis of the superior rectus Proskauer (43) saw the palpebral fissure expand to the height of 6 *mm* by considerable effort and with the aid of the corrugator muscle. When the patient, however, opens his mouth the left upper lid rises without any twitching and without the aid of any other muscle.

In changes of position of the edge of the lid Raehlmann (44) performed transplantation of skin in seventy-four cases. He took the flap if possible from the upper lid, otherwise from the temple, making it larger than the defect to be covered. After detaching it he placed it with its outer surface upon a slightly warm porcelain dish and removed every trace of bloody tissue. The flap was then inserted into the intermarginal space and fixed there.

Wicherkiewicz (45) covered a total defect of the upper lid, due to the removal of a tumor, with a flap composed of skin, muscles, cartilage, and conjunctiva, which he took from the lower lid.

VII.—LACHRYMAL APPARATUS.

46. Bock. Tuberculosis of the lachrymal sac. *Wiener med. Wochenschr.*, 1891, No. 18.

47. Schirmer, O. On adenomas of the region of the caruncle. *v. Graefe's Arch. f. Ophth.*, vol. xxxvii., 1, p. 216.

48. Sgrosso. Reperto anatomo-patologico di un caso di dacrioadenite acuta. *Ann. di Ottalm.*, vol. xix., 5–6, p. 533.

49. Silex, P. Contribution to the treatment of chronic affections of the lachrymal sac. *Deutsche med. Wochenschr.*, 1891, 4.

50. Vossius, A. Contribution to the congenital affections of the lachrymal passages. *Beiträge zur Augenhk.*, 1891, vol. ii., p. 1.

Bock (46) removed a tumor almost the size of a hazel-nut from the region of the right lachrymal sac in a seamstress aged twenty-seven, who was suffering with a tuberculous affection of the elbow-joint. It proved to be a granulation-tumor, composed of a number of larger and smaller tubercles and completely filling the lachrymal sac, while its wall had partly been merged into the tumor, partly destroyed. Bock thinks that the patient introduced pus containing tubercle bacilli with her finger into the right eye, thus leading to the development of this rare form of tumor in the lachrymal sac.

Schirmer (47) examined under the microscope a hairless tumor resembling a button, movable upon the sclera of the left eye, situated at the insertion of the internal rectus muscle and extending as far as the plica semilunaris. It proved to be an adenoma. He believes it had its origin in a Krause gland, which in rare cases are found in small numbers in the inner part of the semilunar fold and neighboring bulbar conjunctiva.

Sgrosso (48) reports on a third case of acute dacryoadenitis. The tumor was of the size of a large oval hazel-nut, caused slight exophthalmus, and totally prevented movement of the eyeball upward and outward. Microscopic examination of the excised gland revealed extensive granular infiltration, which forced the acini and the ducts apart and compressed them. In the centre there was beginning necrotic destruction, in the blood-vessels various changes in all parts of the walls. Dantone.

In chronic dacryocystitis, with ectasia of the walls of the sac and impassable strictures and formation of fistulas, Silex (49) recommends extirpation of the sac. The result has been satisfactory in every case.

In a boy aged seventeen Vossius (50) observed a congenital fistula of the lachrymal sac with congenital occlusion of the lower end of the naso-lachrymal duct. The latter was pierced with Stilling's knife, and then a probe of medium size was passed from the fistula through the nasal cavity. These probings, with syringing with permanganate of potassium, were repeated every day. Afterwards Vossius introduced a lead-wire from the fistula through the lachrymal duct into the nose and left it in position for two weeks. After slitting the upper canaliculus he then introduced the lead-wire from this point through the lachrymal duct into the nose, circumcised the edge of the fistula, and closed the wound with sutures. The cure has been a permanent one.

VIII.—MUSCLES AND NERVES.

51. GUTTMANN, G. A case of bilateral acute ophthalmoplegia exterior after meat-poisoning. *Berliner klin. Wochenschr.*, 1891, No. 8.

52. JONES, W. M. Miners' nystagmus. *Brit. Med. Jour.*, March, 1891, p. 519.

53. MILLIKIN, B. L. Complete paralysis of the lateral movements of both eyes, ability to converge remaining intact. *Trans. Amer. Ophth. Soc.*, 1890.

54. NOYES, H. D. The therapeutic effect of prisms in ophthalmic practice; a study of 100 cases in which they were prescribed. *Trans. Amer. Ophth. Soc.*, 1890.

55. SNELL. Miners' nystagmus. *The Lancet*, Jan. 1, 1891.

56. STRAUB, M. Een gevaal van verlamming van het convergentie-vermogen. *Nederlandsch Tijdschrift voor Geneeskunde*, 1891, vol. i., p. 219.

57. WOODWARD, J. H. Muscular asthenopia. *New York Med. Jour.*, Feb. 7, 1891.

GUTTMANN (51) saw almost complete paralysis of all exterior eye muscles, besides ptosis, follow the eating of a spoiled goose.

JONES (52) gives reasons for believing that nystagmus in miners is due to faulty illumination, and not to the position of the worker. Nystagmus, he says, is common to all underground workers; less than half lie down during work. It is very liable to come on men who have previously worked with naked lights. It is much commoner in winter. He believes it is a clonus of the ocular muscles, due to fatigue following their tonic contraction. WERNER.

In MILLIKIN'S (53) case, a man of thirty-three years had noted at times for 12 or 13 years that he saw double. After the grippe he had another attack, and Millikin saw him for the first time. There was absolute inability to turn either eye outward, but convergence was good. No other paralysis. No history of syphilis. Iodide of potassium was prescribed for him, but he took only a few doses. In about fifteen days spontaneous cure took place, the right beginning first. BURNETT.

NOYES (54) precedes his tabulation with a general consideration of the subject of muscular insufficiencies, and his methods of testing for the same. His success has been encouraging, cure or marked relief following the use of the prisms in something more

than 75 % of the cases. His general conclusions are as follows: (1) Tests for muscular asthenopia at the punctum remotum have greater value than those for the punctum proximum or punctum agendi (average 13″); (2) the equilibrium test is valuable, but not decisive, and should not be the measure of error; (3) weakness of abduction is a far more fruitful cause of muscular asthenopia than a weakness of adduction—the preponderance is not far from 3 to 1; (4) adduction, at 18′ less than 5°, accompanied by headache or eye-strain, justifies a trial of weak adductive prisms which should be worn continuously. They may become permanently necessary, and can in many cases be superseded by tenotomy. They may be only a temporary necessity, and the symptoms disappear. In those cases we do not always find the abduction to have increased; in other cases all the muscles show gain in power or disappearance of spasm. Prisms, after having been worn with benefit, sometimes lose their good influence, and in most cases tenotomy will give relief; (5) refractive errors must always be corrected, but when of low degree, search must always be made for muscular faults, and if detected, prisms are indicated in conjunction with optical correction; (6) many neurotic symptoms, such as headache, vertigo, nausea, mental disturbance, and remote neuralgic conditions may be relieved by prisms.

BURNETT.

STRAUB (56) observed a case in which "accommodative convergence" was very much diminished. A man of thirty-nine had diplopia a year ago on account of paralysis of the oculomotor nerve. There was improvement after the use of mercury and iodide of potassium. When he fixes a point farther away than 2 *m*, he sees single. When a near object is looked at, the eyes remain in the same state, but crossed double images are seen. The pupils react to light and consensually, and contract on convergence (accommodation). The nearest point of accommodation of the left eye lies at 12½ *cm*, of the right at 17 *cm*. In the right eye there is H 2 D1 Dc ax. vert, V = ⅙; in the left E, V = 1. The visual line of the left eye can shift 50° to the right or left; the right accomplishes the same, but with greater effort. In fixing a distant object, the other eye being covered, the latter deviates a few degrees outward. In fixing a nearer point, the right eye deviates 13°, the left 10°. Adduction 6°, abduction 12°. Slight paresis of accommodation and marked paresis of convergence, therefore, remained after the paralysis of the oculomotor

nerve; a unilateral affection was therefore followed by a disturbance of an associated movement. Covering the glass before the right caused disappearance of the diplopia, dizziness, and headache. He discusses the cases described by Parinaud and A. Graefe. WESTHOFF.

WOODWARD (57) gives in detail the histories of five cases of muscular asthenopia, maintaining, in opposition to the statement of Roosa (that no such thing as muscular asthenopia exists), that there is an asthenopia due to disturbance of the muscular equilibrium of the eyes, and that it is correctable by prisms or tenotomy. BURNETT.

IX.—ORBIT AND NEIGHBORING CAVITIES.

58. BORTHEN, LYDER. Circumscribed orbital abscess complicating influenza. *Zeh. klin. Monatsbl. f. Augenhk.*, vol. xxix., p. 83.

59. DUNN, J. A case of malignant fibroid of the orbit. *Amer. Jour. Ophth.*, 1890, No. 12.

60. GUILLEMAIN, A. Étude sur les abscès des sinus frontaux considérés principalement dans leur complications orbitaires, leur diagnostic et leur traitement. *Arch. d'opht.*, vol. xi., pp. 1 and 111.

61. HIGGINS, C. Foreign body lodged in the orbit for forty-six years; removal. *The Lancet*, 1891, p. 82.

62. HULKE, J. W. Five cases of disorders of the frontal sinus. *The Lancet*, 1891, p. 589.

63. NORRIS, W. J. Foreign bodies in the orbit. *Trans. Amer. Ophth. Soc.*, 1890.

64. POOLEY, T. R. Removal of a large exostosis of the orbit with preservation of the eye. *Trans. Amer. Ophth. Soc.*, 1890.

65. TORNATOLA. Fibroma missomatode dell' orbita. *Ann. di Ottalm.*, vol. xix., 5–6, p. 491.

65A. SANTOS FERNANDEZ. Loss of vision from bullet-wounds in the peri-orbital region. *Crónica Médico-Quirúrgica de la Habana*, April, 1891.

LYDER BORTHEN (58) reports that in a girl of fourteen, on the sixth day after the beginning of influenza, a swelling of the lids of the right eye developed, which disappeared in a few days. There was protrusion, the eyeball diverged, and its mobility was limited. A fluctuating tumor gradually developed in the region

of the lig. palpebrale internum. After incision pus escaped, and the normal state was soon re-established. The case was probably one of metastasis of the orbit, which may also develop in other infectious diseases.

DUNN'S (59) case was that of a negro of nineteen years, who had a growth protruding from between the lids of the left eye, which had been noticed during the last eighteen months. The eyeball was not involved. It grew rather rapidly, and it and the eye were finally removed. It measured 32 by 25 by 15 *mm.* Its lower two thirds were uncapsulated. It was nowhere adherent to the eyeball, and appeared to have sprung from the tissues of the orbit. No sarcoma cells were found, but there was abundant fibrous tissue. BURNETT.

GUILLEMAIN (60) first discusses the anatomical conditions of the frontal sinuses, and calls attention to their not infrequently large extent, and the occasional great thinness of the walls separating them from the cranial and orbital cavities. Abscess or better empyema of the frontal sinus is not a very rare occurrence, except in children, where there is no such cavity, and mainly occurs in men, in whom the sinuses and the canals (infundibulum) connecting them with the anterior ethmoid cells and nasal cavity, respectively, are wider than in women. The left sinus is more frequently affected than the right. Syphilis and tuberculosis are causes only in form of an extension of the affection of the bones. Erysipelas (two cases of his own), typhoid and scarlet fever, favor its development. Injuries, foreign bodies, and affections of the nasal cavity may also be the cause (two observations of his own after ozæna and coryza). Occlusion of the infundibulum (by swelling of the mucous membrane) is necessary for the development of the affection. When the cause is an infectious one, suppuration follows, otherwise dropsy of the cavities. The discharge is yellow, greenish, or chocolate-colored, liquid or gelatinous. The mucous membrane shows marked inflammatory swelling. The result of an examination for micro-organisms was negative in one case, in a second the discharge was lost. Perforation takes place either outward through the skin, frequently not until after the lapse of months, or through the dividing wall into the other sinus, and thence into the nose, generally into the orbit, very seldom into the cranial cavity, and then always with fatal result. Sequestra are rare, and generally come from the wall of the orbit, forming a concavo-convex plate. The author then discusses at

length the symptoms of perforation into the orbit, in which the ophthalmoscopic appearance of the fundus generally remained unchanged. The pulsations observed after opening of the sinus seem to be due to transmission of the pulsations of the blood-vessels in the orbit. In rare cases abscesses form in the neighbourhood, after opening which there is, however, no improvement, as they are not connected with the sinus. In such cases the frontal sinus must be trephined, when rapid improvement takes place. In half of the cases a fistula remains behind. Abscess of the sinus begins acutely with symptoms of fever, redness, and swelling of the inner portion of the upper lid, or chronically with the formation of a tumor at the inner canthus, or with symptoms of restriction of space in the orbit, the patients in the latter instance being people who have suffered for years with a purulent discharge from the nose. As to the diagnosis, Panas has mentioned the points in the *Arch. d'opht.*, vol. x., No. 3, May and June, 1891, p. 231 (*cfr.* ARCH. OF OPHTH., vol. xx., Rev. No. 99). The severe supra-orbital pain, which is always present, though frequently intermittent as in malaria, is especially worthy of notice; it resists anti-syphilitic and every other form of treatment, and only ceases after perforation. It is not difficult to distinguish it from orbital phlegmon, tenonitis, and dacryocystitis. In caries of the orbital margin (usually the lower), the differently shaped sequestra and the probe, which in abscess of the sinus often penetrates very far, aid in the diagnosis. Treatment consists in trephining and draining the cavity either from the orbit or from the brow at the orbital margin; in the latter case with the introduction of a drainage-tube into the nose, to provide a natural discharge for the secretion. As a result of his examinations on the dead, Panas has constructed an elastic catheter, which can be readily introduced through a wide opening made by trephining of the brow, through the sinus into the nose, making the introduction of a drainage-tube possible. In every kind of drainage antiseptic injections are necessary. Naso-frontal drainage seems best, but even then recovery is protracted for months, and a permanent fistula may result. In conclusion, the author reports five observations of his own, and twenty-one of others, with a bibliography. V. MITTLESTÄDT.

In HIGGINS' (61) case, a portion of the blade of a knife almost an inch long was removed from the orbit of a man æt. fifty-two, who had fallen on a knife when a child of six. WERNER.

HULKE (62) records two cases of frontal mucocele and three cases of polypi of the sinus. WERNER.

NORRIS'S (63) first case was that of an injury to the left eye from the explosion of a torpedo on a railroad. The eye was removed, but the stump remained very sensitive and fistulous. Under ether a large piece of metal (weighing 123 grains) of which a photograph is given was extracted with the bone forceps from the orbit. The orbital walls were not fractured. The second case was that of a piece of nail embedded in the lower inner part of the left orbit. There was some blood on the anterior chamber, but the cornea was clear; eye slightly prominent. The nail was removed. The eye has still defective vision and is rather soft. BURNETT.

POOLEY'S (64) case was that of a young woman who had for several years noticed an increasing swelling at the upper inner corner of the right orbit. Vision was somewhat impaired and there was a myopic astigmatism of 1 D. Inflammatory symptoms associated with some brain symptoms setting in, an operation was submitted to. An incision was made in the integument just at the edge of the orbit, embracing nearly two thirds of its circumference. The tumor was easily defined. It was attacked at its base with a chisel and the tissues were found to be so soft that a mallet need not be used, the pressure of the hand being sufficient to detach it from its base. Connection with any of the neighboring cavities could not be made out. Some reaction followed and there was some homonymous diplopia in the lower field for some time, but the ultimate recovery was satisfactory, and the slight neuritis which was present at one time and the astigmatism wholly disappeared. The tumor weighed 26 grammes, and its longest diameter was 39 *mm*, its next 30 and its least 28 *mm*. BURNETT.

TORNATOLA (65) reports the successful removal of a large orbital tumor, which had existed for sixteen years and had forced the eyeball completely out of the orbit. After removal of the capsulated neoplasm the eyeball could be replaced and the recovery was normal. Vision, which at the time of the operation was equal to counting of fingers at 5 *mm*, with a contracted visual field, was preserved unchanged. Microscopic examination proved the tumor to be a myxo-fibroma. The author states that thus far no case of myxo-fibroma of the orbit has been reported. DANTONE.

FERNANDEZ (65a), after describing several cases, comes to the following conclusions: (1) Bullets do not always produce ocular or encephalic lesions. (2) They may only injure the deep-seated portion of the ocular apparatus. (3) They may injure the optic nerve or the retina. (4) In the nerve these lesions are degenerative or neuritides. (5) The retinal detachment is brought about by contusion or by a choroiditis. E. LOPEZ.

X.—CONJUNCTIVA, CORNEA, SCLERA, ANTERIOR CHAMBER.

66. ANTONELLI. Cisti sotto-congiuntivali aventi origine delle glandole acino-tubulari. *Ann. di Ottalm.*, vol. xix., 5–6, p. 467.

67. DEUTSCHMANN. R. On pemphigus and essential xerosis of the conjunctiva. *Beiträge zur Augenhk.*, 1891, 2, p. 39.

68. FRAENKEL. A piece of wood for 12 years in the conjunctiva. *Zeh. Klin. Monatsbl. f. Augenhk.*, vol. xxix., p. 94.

69. GUAITA. Due casi di linfoma diffuso della congiuntiva. *Ann di Ottalm.*, vol. xix., 5–6, p. 513.

70. HOLMES, C. R. Boracic acid and massage in pannus. *Journ. Amer. Med. Assoc.*, Jan. 17, 1891.

71. KAZAUROW. The question of the treatment of trachoma. *Wratsch*, 1891, No. 5.

72. KOLLOCK, C. W. A form of xerosis. *Trans. Amer. Ophth. Soc.*, 1890.

73. KOPFSTEIN, W. The conjunctivitis of the new-born. *Wiener Wochenschr.*, 1891, Nos. 6, 7, and 8.

74. KRUG. An epidemic of follicular conjunctivitis in the schools of Dresden. *Zeitschr. f. Gesundheitspflege*, 1891, No. 2.

75. MOAURO. Congiuntivite follicolare e tracoma, contribuzione all anatomia patologica. *Ann. di Ottalm.*, vol., xix., 5–6 p. 377.

76. PETERS. Infectious eye diseases in the schools of the district of Bromberg. *Zeitschr. f. Gesundheitspflege*, 1891, No. 5.

77. RAEHLMANN, E. The pathology of trachoma. *Wiener med. Wochenschr.*, 1891, Nos. 19, 20.

78. SATTLER, H. The treatment of trachoma formerly and now. Berlin, 1891.

79. DE SCHWEINITZ, G. E. The indications for some of the applications commonly used in the treatment of chronic granular lids. *Med. News*, Feb. 7, 1891.

80. TAYLOR. Ricerche anatomiche su cinque casi di ipertrofia del limbus per cartarro primaverile. *Ann. di Ottalm.*, vol. xix., 5–6, p. 524.

81. VESZELY, C. Excision of the fornix in the treatment of trachoma. *Wiener klin. Wochenschr.*, 1891, Nos. 22–24.

ANTONELLI (66) has made a careful histological examination of one of the small, more or less transparent cysts found by various authors at the fornix of the conjunctiva, and found that it is a dilatation of one of the small Krause glands. DANTONE.

DEUTSCHMANN (67) observed essential xerosis of the conjunctiva for two years in a lady of seventy-one, without being able to find the cause, but finally pemphigus of the hard palate was discovered and also a temporary formation of vesicles on the conjunctiva. Microscopic examination and cultures revealed a small streptococcus, the pathogenic powers of which were confirmed by experiments on animals.

In two poorly nourished, anæmic persons GUAITA (69) observed an enormous swelling of both lids of both eyes, so that they could not be opened at all. The cause was a marked thickening of the otherwise seemingly normal conjunctiva, extending from the fornix to the margin of the lids. Microscopic examination of a few small excised pieces of the swelling revealed an extensive collection of lymphoid cells in the meshes of the conjunctival and sub-conjunctival connective issue, but not a trace of amyloid substance or amyloid degeneration. Massage of the lids had an excellent effect in both patients. DANTONE.

HOLMES (70) has had satisfactory results in treating the pannus of trachoma with instillations of boracic acid conjoined with massage. BURNETT.

KAZAUROW (71) prefers the bluestone and nitrate of silver solution to all other remedies recommended for trachoma. Even in corneal ulcers cauterizations with a 5 % solution of nitrate of silver (in the usual manner) produce the best results. Scraping out with the sharp spoon or with the wire brush leads to the formation of scars. Better results (but not as brilliant as those of Costomiris) he obtained by massage of the conjunctiva with boracic acid powder. In atonic cases the conjunctiva is thereby stimulated and made more receptive for the action of the bluestone and nitrate of silver. In pannus, as well as in other corneal opacities, Kazaurow saw good results follow the insufflations of antipyrine powder. In diffuse trachoma he brushes the con-

junctiva with hygroscopic cotton soaked in a 1 % solution of sublimate, watches the reaction, and does not repeat the application until the eschar has completely disappeared. (For out-door patients he prescribes drops composed of one part sublimate, ten of alcohol, and 240 of water.) In marked xerophthalmus he has used a 1 to 2 % emulsion of creoline with good result.

HIRSCHMANN.

KOLLOCK (72) describes a peculiar condition of the conjunctiva found in negro children from one to nine years of age, in Charleston, S. C. The conjunctiva is dry and scaly, and falls into folds, and is more or less pigmented. The edge of the cornea is frequently ulcerated, but may have a ridge of grayish material surrounding it, and the surface of the cornea has a greenish sheen which is due to change in the epithelium. There is no pain or photophobia. It is seen only in the badly nourished negro children. General treatment seems the most effective, and locally mild antisepsis is used. BURNETT.

KOPFSTEIN (73) distinguishes two kinds of ophthalmic blennorrhœa of the new-born and older nurslings. The one, due to infection with genital or ophthalmic secretion containing gonococci, deserves the name ophthalmic blennorrhœa ; the other includes severe suppurations of the conjunctiva, which, however, can only be considered cases of very virulent conjunctivitis.

KRUG (74) reports that in the schools of Dresden 4,653 children among 9,320 were attacked with follicular conjunctivitis. Dryness of the atmosphere favors the spread of the disease on account of the pulverization of the dry discharge. It is not identical with trachoma. Genuine trachoma was found in only three children. They were chronic cases not dependent upon the epidemic.

MOAURO (75) endeavored to obtain an insight into the nature of follicular and trachomatous conjunctivitis by careful microscopic examinations, and came to the following conclusions : The two diseases differ ; the former is characterized by nodules, the structure of which is identical with that of the lymph-follicles found under normal conditions ; the latter is distinguished by the trachoma nodules, which histologically must be classed among the true granulation tissue and which are produced by proliferation of the fixed connective tissue cells and of the walls of the blood-vessels. DANTONE.

According to the examinations of PETERS (76), among 4,000 school-children in the district of Bromberg, 950 suffered with eye

diseases, 100 of these with genuine trachoma, 300 with follicular conjunctivitis, and 550 with simple conjunctivitis.

RAEHLMANN (77) distinguishes two totally different types of granulation tissue, the follicular and blennorrhoic. The clinical course of follicular inflammation is much more changeable than the even course of chronic blennorrhœa. Trachoma may be defined as a follicular inflammation of the conjunctiva, the clinical course and result of which are dependent upon the quantity, size, and location of the newly formed follicles, and upon the changes which these formations undergo. A few follicles in the conjunctiva are harmless; when numerous they destroy the mucous membrane. The clinical course of trachoma may be divided into three stages. The *first stage* is that of formation of the follicles. It progresses under inflammatory symptoms when they develop in large numbers; when they come slowly the course is a more or less indolent one. Mild cases of trachoma may be cured without leaving a trace. Follicular conjunctivitis belongs here, which, according to Raehlmann, is nothing but a mild trachoma in its first stage, and not a disease *sui generis*. In the *second stage* changes in the tissue take place in the form of necrosis, ulceration, hypertrophy, and sclerosis of the mucous membrane. They lead directly to the *third stage*, the cicatricial trachoma. Keratitis pannosa is frequently observed during the second stage. Trachoma is unquestionably contagious. Acute trachoma is the most contagious, then the chronic form in the second stage.

In discussing the treatment of trachoma in former times and now SATTLER (78) recommends opening the follicle with a cataract needle and evacuating the contents with a delicate sharp spoon. The upper fornix is seized with a forceps constructed by Herrnheiser. He removes everything at one sitting, and disinfects with a solution of sublimate (1.1000). When the upper lids are hypertrophied, lax, the conjunctiva covered with red, partly nodular granulations, and the fornix so swollen that the follicles are scarcely recognizable, he brushes them, before resorting to an operation, with a two-per-cent. solution of silver nitrate alternately with sublimate (1:500). If the granulations then become distinct, an operative procedure is indicated. The after-treatment consists in instillations of sublimate (1:1000), touchings with blue-stone or alum, finally dusting of tannin. The yellow precipitate salve he recommends in old cicatricial trachoma. The length of treatment is very much shortened by scooping out the granulations, there

is no increase in the formation of cicatricial tissue, the eyelashes do not assume an abnormal shape, and the tarsus is not deformed. Relapses are rare; complicating corneal affections are favorably influenced. In very acute cases of trachoma operative treatment should be avoided, cold applications and bathing the eyes with a boracic acid or weak sublimate solution are indicated, followed by applications of a one-half-per-cent. solution of acetate of lead or nitrate of silver, and afterwards sublimate (1:500).

In the first stages—acute—of granular lids DE SCHWEINITZ (79) uses nitrate of silver, or weak bichloride solutions; in the second the copper stick, and in the third the boroglyceride. He has also found hyposulphide of sodium useful in the second stage.

BURNETT.

According to TAYLOR (80) the swelling at the corneal margin so frequently observed in vernal catarrh is a sort of neoplasia. Proliferation of the epithelial cells not only causes thickening of the epithelium itself, but offsets extend into the connective tissue lying beneath, causing a marked reaction of the latter.

VESZELY (81) has excised the retro-tarsal fold in sixty cases of trachoma. The infiltration and hypertrophy of the mucous membrane disappeared much more rapidly than after medicamentous treatment. Deformities of the lids and relapses are much less frequent. Shortening of the conjunctival sac, limitation of mobility of the globe, ptosis, and entropium were never observed after the operation.

81a. DR. LOPEZ. Granular ophthalmia in the negro race. LOPEZ presents to the "Sociedad de Estudios Clinicos" the debated question of the existence or non-existence of this affection in the African race, with the object of inquiring into the truth among the observers in Cuba. After an animated discussion Drs. Montalvo and Santos Fernandez agreed with Dr. Lopez in the rarity of the disease; and according to the statistics of the two last it is found in the ratio of 1 : 2400 and 1 : 2200. (Session of April 17, 1891.)

82. HAGNAUER, G. The misinterpretation of herpes corneæ febrilis. *Inaug. Diss.*, Zürich, 1891.

83. v. HIPPEL, A. A case of successful transplantation of the cornea. *Berliner klin. Wochenschr.*, 1891, No. 19.

84. WERNDLY, L. U. H. C. Keratitis diffusa en Hutchinson'sche tanden. *Proefschrift*, Leiden, 1891.

According to HAGNAUER (82) the corneal affections described by Hansen-Grut, Emmert, and others as keratitis dendritica are identical with those to which Horner has given the name of herpes corneæ febrilis.

From a patient, who had a central opacity of the cornea 3 *mm* in diameter and a cataractous lens, HIPPEL (83) extracted the latter, so that vision rose to one fifth. He then circumcised the opaque part of the cornea with a trephine down to the membrana Descemetii, extracted this disc, and implanted a piece of rabbit's cornea into the opening. The latter healed in and remained transparent, so that vision rose to one third.

According to WERNDLY (84) keratitis profunda occurs in $\frac{1}{3}$ % of all eye patients. In 75 % both eyes are affected. The most frequent complication is that of the uvea, about 40 %. The characteristic defects of the teeth were observed in 40 %. In 55 % of all cases there was hereditary syphilis beyond a doubt. Werndly proposes the name "uveokeratitis specifica." WESTHOFF.

Sections XI.–XX. Reviewed by DR. P. SILEX.

XI.—IRIS.

85. REBOUD. Vaste déchirure de l'iris, décollement complet de l'hyaloide avec retraction de tout le corps vitré sans décollement rétinien ; acuité visuelle très-satisfaisante. *Arch. d'opht.*, vol. xi., No. 1, Jan.–Feb., 1891, p. 15.

86. RISLEY, S. D., and RANDALL, B. A. Cyst of the iris, following a penetrating wound which had caused sympathetic neuroretinitis. *Trans. Amer. Ophth. Soc.*, 1890.

87. STEWART, TH. Foreign body in the iris. *Journ. Ophth., Otol., and Laryng.*, Jan., 1891.

87a. DR. ACOSTA. On the frequency of specific iritis. *Revista de las Ciencias Médicas*, April, 1891. In a total of twenty-one thousand patients from the statistics of Dr. Santos Fernandez he found that the affection constituted four per cent. of the total number of patients and fifty-two per cent. of all the iritides. He does not recognize any characteristic symptom except the gumma in the rare cases in which it is found. E. LOPEZ.

In RISLEY and RANDALL'S (86) case a boy of twelve received an injury which ruptured the sclero-corneal junction at the lower inner quadrant of the left eye. The iris prolapsed and was cut

off. From time to time there was irritation in the right and marked congestion of the nerve-head and retina. A cyst developed near the site of the wound in the left and gradually increased in size in the interval of eight years between the time of the reception of the injury and the enucleation of the eyeball, which was demanded by the condition of the right; there were convulsions at times. The cyst was found to be formed between the layers of the iris. The remainder of the eye appeared to be in a fairly healthy condition. BURNETT.

In STEWART's (87) case the man was struck on the eye with a piece of metal. Part of it lodged in the corneo-scleral junction and was scraped off after a few days. A speck of pus appearing on the iris, an incision was made and the speck grasped with a pair of forceps and removed. A small piece of metal was embedded in this. The case did well. BURNETT.

XII.—CHOROID.

88. FREUDENTHAL. On sarcoma of the uveal tract. *v. Graefe's Arch.*, vol. xxxvii., 1, p. 137.

89. WADSWORTH, O. F. A case of metastatic carcinoma of the choroid. *Trans. Amer. Ophth. Soc.*, 1890.

90. WEINBAUM, S. Contribution to the knowledge of sarcomatous affections of the ocular membranes. *v. Graefe's Arch.*, vol. xxxvii., 1, p. 185.

FREUDENTHAL (88) presents a review of twenty-four cases of sarcoma of the choroid operated on at the Göttingen clinic from 1871 to 1889. The age of the patients varied between twenty-eight and sixty-nine years. In one case the eye was not enucleated until sixteen years after the first observation. In twenty-five per cent. local relapses occurred from eight to ten years after the operation. In only one case metastasis was observed in more distant organs; the majority died of sarcoma of the brain. Metastasis in the liver occurred in twenty per cent. in a space from one to seven years. He regards thirty-seven per cent. as cured (by far too favorable.—H. K.).

WADSWORTH (89) had detected the intraocular growth before he was aware that a carcinomatous breast had been removed sixteen months before. The patient had observed a blur before her eye three weeks before she first consulted him. On removal of the eye the tumor was found to be a carcinoma. BURNETT.

WEINBAUM (90) describes a melanosarcoma of the choroid and two episcleral sarcomas. All the patients died of multiple sarcomatosis.

XIII.—GLAUCOMA.

91. KOLLOCK, C. W. Two cases of glaucoma with unusual features. *Trans. Amer. Ophth. Soc.*, 1890.

92. LOGETSCHNIKOW. Contributions to the prognosis of operations for glaucoma. *Wjestnik Ophth.*, 1891, No. 1.

KOLLOCK'S (91) first case was that of a man in whom he had performed iridectomy for subacute glaucoma. Two days after the operation the eyeball was of stony hardness, though a weak solution of eserine had been used. Under a 4-gr. solution of eserine the hardness instantly disappeared, leaving, however, an irregular astigmatism. Vision improved under the administration of strychnine. The second case was one of glaucoma following hemorrhagic retinitis in a patient subject to albuminuria. Enucleation was finally done. The other eye was unaffected.

BURNETT.

LOGETSCHNIKOW (92) reiterates the assertion, made in 1889, that iridectomy can be indefinitely repeated upon the glaucomatous eye at greater or less intervals, and that the course of the disease can thus be checked, but the disease itself not radically cured. He has never failed to see an advance in the glaucoma, when the patient was sufficiently long under observation, except in one case of simple glaucoma, in which both eyes had been operated upon by v. Graefe twenty years ago, and were still healthy. HIRSCHMANN.

XIV.—SYMPATHETIC OPHTHALMIA.

93. LIMBURG and LEVY. Investigations on sympathetic ophthalmia. *Arch. f. experim. Path. u. Pharmak.*, vol. xxviii., Nos. 1 and 2.

As a result of their experiments LIMBURG and LEVY (93) consider the staphylococcus and streptococcus which they found both in the injured and the sympathizing eye, only an occasional, but not specific cause of sympathetic ophthalmia. They never succeeded in producing the disease by inoculation.

XV.—VITREOUS.

94. SCHULTER. Formation of new blood-vessels in the vitreous. *Centralbl. f. prakt. Augenhk.*, vol. xv., p. 45.

XVI.—LENS.

95. BULL, C. S. Extraction of lenses dislocated into the vitreous chamber. *Trans. Amer. Ophth. Soc.*, 1890.

96. BULL, C. S. Simple extraction of cataract without iridectomy. *Trans. Amer. Ophth. Soc.*, 1890.

97. DERBY, HASKET. Eight cases of rudimentary zonular cataract among the members of the same family. *Trans. Amer. Ophth. Soc.*, 1890.

98. GREEN, J. Notes of 21 cases of cataract occurring in a single family. *Trans. Amer. Ophth. Soc.*, 1890.

99. LAQUEUR. The present state of our knowledge of cataract extraction. *Wiener klin. Wochenschr.*, 1891, No. 1, p. 11.

100. THOMAS, C. M. A report of 50 cases of cataract extraction. *Jour. Ophth., Otol., and Laryng.*, Jan., 1891.

100a. SANTOS FERNANDEZ. Cataract. *Crónica Médico-Quirúrgica de la Habana*, February, 1891.

BULL (95) gives in detail the histories of 13 cases where by manipulation he extracted lenses dislocated into the vitreous. He does not consider the bident a desirable instrument. His plan is to make a rather large incision lying wholly in the cornea. The wire speculum is then removed, and while the upper lid is held up by an assistant, pressure directly backwards is made below, on the eyeball. The lens then gradually presents itself in the pupillary space and is readily expelled. BURNETT.

BULL'S (96) further experience since the report of his first 100 simple extractions has tended to confirm his favorable opinion of it. He makes a small flap, not a linear cut, the whole incision falling within the cornea, using a narrow Graefe knife. The lids are held open with a speculum until the lens is to be expelled, when it is removed. A T-shaped incision is made in the capsule, and sometimes a square piece is cut out. The delivery of the lens is made by pressure above the incision and at the lower part of the cornea. The conjunctiva before, during, and after the operation is washed with a warm, saturated solution of boracic acid. The anterior chamber is sometimes washed out with the same. He counsels against using bichloride solutions for this. After the iris is returned he puts in a drop of a ½-gr. solution of eserine. He bandages both eyes, having found the plaster strips unsatisfactory. He inspects the lids after forty-eight hours,

and sometimes opens the eye, if all does not seem to be doing well. If everything is satisfactory he takes off the bandage and substitutes a shade during the day after the fourth or fifth day.

BURNETT.

In none of DERBY'S (97) cases were convulsions noted. He argues from these cases that such faults of development are more apt to be transmitted through the female than the male, and more perfectly to the females than the males. BURNETT.

GREEN (98) gives a table of 70 known descendants of one woman where there were 21 cases of cataract. BURNETT.

THOMAS (100) always does a preliminary iridectomy, small and very peripheral. As a dressing he has tried the plaster strips, and finds them more uncomfortable than the bandage. His results are: Good, 44 cases; moderate, 4 cases; bad, 1; unknown, 1. Artificial maturation was done seven times. No complications in healing, and no loss in the last 106 extractions in his practice. BURNETT.

FERNANDEZ SANTOS (100a), considers both the artificial ripening and extraction of immature cataracts as dangerous. He accepts the occlusive bandage which he had formerly condemned, as the most adapted to antiseptic principles. He believes that the principal cause of the delirium after extractions lies in the use of atropine and in the occlusion. He condemns the extraction of the lens in its capsule, as it does not even protect against secondary cataract. He referred to a late form, where the opacity is in the hyaloid membrane.

With regard to anæsthesia, he considers the local one obtained with cocaine insufficient. He states that it does not always render the conjunctiva insensible. He stands by the view which he has often expressed of the usefulness in many cases of a general anæsthesia. E. LOPEZ.

XVII.—RETINA AND FUNCTIONAL DISTURBANCES.

101. AYRES, S. C. Traumatic hemorrhage in the region of the macula lutea. *Amer. Jour. Ophth.*, Feb., 1891.

102. CARMALT, W. H. Contributions to ocular tumors. *Trans. Amer. Ophth. Soc.*, 1890.

103. CHIARI. Demonstration of a globe completely substituted by glioma. *Wiener med. Presse*, 1891, p. 312.

104. EMERSON, J. B. A contribution to the study of the

treatment of retinal detachment. *N. Y. Med. Jour.*, March 21, 1891.

105. GURWITSCH, M. S. The histological changes in the retina and choroid in Bright's disease. *Ophth. Section of the 4th Pirogoff Meeting of Russian Physicians*, 1890.

106. HIRSCHBERG, J. On diabetic affections of the visual organ. *Deutsch. med. Wochenschr.*, 1891, p. 467.

107. JACOBY, G. W. Transient blindness in whooping-cough. *N. Y. Med. Jour.*, 1891, No. 2.

108. MAKROCKI. A case of spontaneously cured detachment of the retina in a horse suffering with iridochoroiditis, so-called moon-blindness. *Zeitschr. f. vergl. Augenhk.*, vol. vii., 1, p. 51.

109. MARTINET. A case of retinitis proliferans. *Deutsche med. Wochenschr.*, 1891, p. 329. (A case and bibliography.)

110. MICHAELSEN. A case of pulsation of the retinal arteries in glaucoma, insufficiency and aneurism of the aorta, with an autopsy of the internal organs. *Centralbl. f. prakt. Augenhk.*, vol. xv., p. 33.

111. MITTENDORF, W. F. Embolism of the upper branch of the retinal artery with normal vision. *Trans. Amer. Ophth. Soc.*, 1890.

112. NORTON, G. A case of retinitis diabetica. *Jour. Ophth., Otol., and Laryng.*, Jan., 1891.

113. SCHWEIGGER, C. On diabetic retinitis. *Deutsche med. Wochenschr.*, 1890, p. 260.

114. THEOBALD, S. Report of a case of recurrent irido-chorio-retinitis. *Trans. Amer. Ophth. Soc.*, 1890.

115. WADSWORTH, O. F. Thrombosis of the arteria centralis retinæ—large retino-ciliary artery—central vision unimpaired. *Trans. Amer. Ophth. Soc.*, 1890.

116. WEBSTER, D. Nine cases of detachment of the retina treated by operation. *N. Y. Med. Jour.*, March 21, 1891.

AYRES' (101) cases are as follows: 1. Injury of the eye by a ball; intraocular hemorrhage and hemorrhage in macula lutea; metamorphopsia; changes in the refraction of the eyes. 2. Injury of the eye by a rubber sling-shot; extensive intraocular hemorrhage, and hemorrhage in the region of the macula, with œdema of the retina; recovery. 3. Hemorrhage in the region of the macula while stooping to drink out of a stream; œdema of the retina; central scotoma; recovery. BURNETT.

CARMALT'S (102) four cases are as follows : 1. Round-celled sarcoma of the conjunctiva ; extirpation ; recurrence ; death. 2. Glio-sarcoma of the retina (?) ; enucleation ; recurrence ; metastases to brain ; death. 3. Double glio-sarcoma in an infant ; both eyes enucleated ; apparent recovery, one year after report. 4. Sarcoma of the conjunctiva ; removal ; recurrence ; second removal ; no recurrence after six months. BURNETT.

In CHIARI'S (103) patient, a child, aged three and a half years, the eyeball was abnormally large, even at birth. A tumor soon afterwards growing from it in a short time reached the size of a hen's egg. After removal of the whole mass no traces of the eyeball could be found.

EMERSON (104) gives the histories of 21 cases of retinal detachment treated by himself and Roosa. None were operated on. The treatment was by rest with bandaging, by pilocarpine and salicylate of sodium. Nine were improved, and in one the condition became worse. In 8 the retina was re-attached with useful vision. In the majority the re-attachment seemed to be permanent (? Ed.). BURNETT.

According to GURWITSCH (105) the changes are similar to those found in other organs in kidney disease. The blood-vessels of the choroid first become affected, show hyaline degeneration, become brittle, obstructed, permit extravasation. The same changes take place afterwards in the blood-vessels of the retina.

MARCKWORT.

In this reply to Schweigger, HIRSCHBERG (106) calls attention to the characteristics of diabetic retinitis and diabetic cataract. At least ten per cent of his extractions are for diabetic cataract. He then reviews all the changes which diabetes may cause in the visual organ. Beginning with the margin of the lids, there is no part of the eye, with the exception of the conjunctiva of the lids, the affection of which he could not frequently trace to diabetes.

MICHAELSEN'S (110) case is remarkable, because the arterial pulse was noticeable at the same time in all the parts of the papilla, and extended several diameters beyond it, though less marked. The veins also showed decided pulsations.

MITTENDORF'S (111) patient was a woman of thirty-five, who had some rheumatism and a cardiac complication. There was a sudden loss of the lower half of the visual field of the right eye, but central vision was good. Examination showed an embolism

of the upper branch of the central retinal artery with the usual appearances, except that the macula was nearly normal. This was explained by the fact that a branch of the lower division of the artery curved upward and ran above the macula, thus giving it a blood-supply. BURNETT.

The late Dr. NORTON (112) reports and gives a colored drawing of a case of retinitis diabetica. The white placques were very large, resembling those found in Bright's retinitis, but there were numerous small white spots and capillary hemorrhages. BURNETT.

SCHWEIGGER (113) declares in opposition to Hirschberg, that there are only a few characteristic diabetic affections of the eyes. Not all the diseases which may occur in the eye in the course of diabetes are attributable to that cause.

THEOBALD'S (114) case was that of a young woman of twenty-five who had lost the left eye from what was apparently an irido-choroiditis. The other eye being attacked with iritis, the eye was removed. Nevertheless, and in spite of mercurial and iodide treatment, there were recurrent attacks of iritis, choroiditis, and retinitis, followed finally by high tension, for which a sclerotomy was made. The condition gradually went from bad to worse, and vision was lost in this also. Theobald thinks from certain points in the history that a disturbed state of the sympathetic nervous system was at the bottom of the trouble. BURNETT.

WADSWORTH'S (115) patient was a woman of twenty-four years, who suddenly after headache had diminution of vision in the left eye. Central vision in both was $\frac{16}{12}$, but in the left there was great haziness of the retina except at the macula and a triangular space uniting it with the disc. The vessels seemed but little reduced in size. A large retino-ciliary artery ran from the edge of the disc above the macula, which seemed normal. The central vision in the left extended to about 20°. In the course of a few days the retina began to clear, but the patient passed from observation before the end was reached. Wadsworth thinks the lesion a thrombus rather than an embolus. BURNETT.

WEBSTER (116) made all his operations by exposing the sclera and then making a puncture with a Graefe knife, turning it upon its axis to facilitate the exit of the fluid. Sometimes an attempt was made to puncture the retina also. The results were: one cured; four greatly improved; apparently permanently; six relapsed. None were made worse. BURNETT.

XVIII.—OPTIC NERVE.

117. BULL, C. S. Papillitis, or inflammation of the intraocular end of the optic nerve. Its etiology and connection with intracranial disease. *N. Y. Med. Jour.*, Feb. 21, 1891.

118. FOWLER, W. P. Atrophy of the optic nerves following spinal injury. *Jour. Ophth., Otol., and Laryng.*, Jan., 1891.

119. FOX, L. W. Resection of the optic nerve. *Med. and Surg. Rep.*, Feb. 7, 1891.

BULL (117) gives a general consideration of the subject in all its relations, with a *résumé* of our existing knowledge on the subject. It is too extensive to abstract satisfactorily. No new points are brought out. BURNETT.

In FOWLER'S (118) case a man was thrown from a caisson during the war and run over, the wheel passing over the lower portion of the dorsal region. The lower extremities were paralyzed for a few months. His back remained weak. He perspires freely and his face flushes easily. No suspicion of syphilis. Sight failing gradually from optic atrophy for some years, and was finally lost altogether. BURNETT.

FOX (119) recommends resection of the nerve in many cases now submitted to enucleation, and considers it a protection from sympathetic ophthalmia. He describes his method of doing it. BURNETT.

XIX.—INJURIES, FOREIGN BODIES (PARASITES).

120. BOYNTON, F. H., and CRIPPEN, H. H. Injury to the bulbus causing transverse rupture of the iris and of the zonula. *Jour. Ophth., Otol., and Laryngol.*, Jan., 1891.

121. MAJOCCHI. Nota preventiva sul demodex folliculorum nelle glandole Meibomiane e nei follicoli cigliari. *Ann. di Ottalm.*, vol. xix., 5–6, p. 546.

122. WILSON, F. M. Specimens of filaria oculi humani. *Trans. Amer. Ophth. Soc.*, 1891.

123. WILSON, HAROLD. Blindness from a penetrating wound of the temple and orbit. *Jour. Ophth., Otol., and Laryng.*, Jan., 1891.

BOYNTON and CRIPPIN'S (120) case was that of an injury to the eye from a bullet, in which the iris was ruptured horizontally from the pupillary margin to the periphery, leaving the sphincter intact.

The zonula was also ruptured and the lens tilted. There were radiating opacities on the posterior surface of the lens. BURNETT.

MAJOCCHI (121), who was enabled to examine demodex folliculorum once in a removed chalazion and once directly on the lid of a corpse, considers this parasite as having an indifferent effect upon the follicles of the hairs of the lids and the eyelashes, but a very great one upon the Meibomian glands. It produces marked reaction when it gets into the efferent duct or the body of the gland. The duct becomes horny ; the acini at first yield an increased discharge on account of irritation of their epithelium ; fatty degeneration follows, leading to thickening of the peri-acinous connective tissue with subsequent cystic enlargement of the whole gland.

DANTONE.

WILSON (122) showed a specimen of filaria oculi humani, which had been removed from the skin of the upper lid of a missionary at Benita on the west coast of Africa. He gave some account of other occurrences. BURNETT.

In WILSON'S (123) case a knife was thrust into the temple, and, entering the orbit, must have severed the optic nerve and all the nerves around the optic foramen, since there was only faint perception of light and fixedness of the eyeball. The media were clear, but the disc was pale, arteries small, and the veins large, dark, and irregular. BURNETT.

XX.—OCULAR AFFECTIONS IN CONSTITUTIONAL DISEASES.

124. CALLAN, P. A. Migraine and functional headaches from eye-strain. *Jour. Amer. Med. Assoc.*, March 28, 1891.

125. FRÖLICH, L. On affections of the eye in alopecia areata. *Berliner klin. Wochenschr.*, No. 14, 1891.

126. GALEZOWSKI. Des troubles visuels dans la maladie de Parkinson. *Rec. d'opht.*, Feb., 1891, p. 72.

127. HARLAN, G. C. Transient amblyopia with bitemporal hemianopsia in a case of malarial cachexia. *Trans. Amer. Ophth. Soc.*, 1890.

128. MAZZA. Osservazioni di emianopsia omonima con afasia, emianestesia e sordità del lato opporto. *Ann. di Ottalm.*, vol. xix., 5–6, p. 500.

129. NIEDEN, A. On fear of smallness of surrounding space, agoraphobia, and limitation of the visual field. *Deutsche med. Wochenschr.*, 1891, p. 465.

130. NORRIS, N. Two cases of tumor with interesting eye-symptoms. *Trans. Amer. Ophth. Soc.*, 1890.

131. OLIVER, CH. An analysis of the ocular symptoms found in the third stage of general paralysis of the insane. *Trans. Amer. Ophth. Soc.*, 1890.

132. Report of the committee on the causes and prevention of blindness. *Trans. Amer. Ophth. Soc.*, 1890.

133. STEVENS, G. T. Some conditions of mutual interest to the dentist and the oculist. *Internat. Dent. Journ.*, March, 1891.

134. WEISSENBERG. Contributions to the knowledge of the disturbances of reading on the basis of a case of dyslexia. *Arch. f. Psychiatr.*, vol. xxii., p. 414.

135. WINKLER. Bydraga tot hersenchirurgie. *Nederl. Tijdschrift voor Geneeskunde*, 1891, 1, p. 371.

CALLAN'S (124) conclusion from an extended experience with hundreds of cases is that he regards eye-strain as the cause of seventy-five per cent. of all functional headaches and migraine.

BURNETT.

Both of FRÖLICH'S (125) cases were complicated with iridochoroiditis. Accurate bibliography of the subject.

According to GALEZOWSKI (126) sight generally remains unimpaired in Parkinson's disease (paralysis agitans). The eyes, however, have a fixed look without a tendency to movement. Both upper lids generally droop so much as to cover half the eye. In spite of the immobility of the lids there is always a slight tremulousness. MARCKWORT.

HARLAN'S (127) case was that of a sailor who had lived in a malarious region and was suffering from obscure nervous symptoms. He was suddenly seized with typical symmetrical bitemporal hemianopsia, the central area of vision being 2½ inches at a distance of 12 inches and clearly defined. The next day the blindness was total. A microscopical examination revealed the pigment granules in the blood, and 24 grs. of quinine were given daily, and improvement began at once. The pigment granules began to disappear from the blood, and in ten days he was discharged well. BURNETT.

In NIEDEN'S (129) patient, a strong man of thirty-four years, the disease had reached such a point that even in his room he was seized with the fear that the space was too small for him. During this attack his surroundings became dark and indistinct,

while the objects looked at were clearly visible. By closing his eyes and remaining in the dark he regained his composure.

The first of NORRIS's (130) cases was that of a woman of thirty-two in otherwise good health, whose first symptoms were a narrowing of the visual fields of both eyes—in the left at the upper and outer quadrant, and to a less extent in the upper-inner in the right. She was afterwards taken with symptoms referable to the central nervous system—convulsions, headache, dizziness, etc., and a choked disc showed itself first on the left and then on the right side. There was nausea and vomiting and a marked increase of knee-jerk, particularly on the left side. Later, severer headaches and double vision, paresis of inferior rectus of the right side, pupils sluggish. The patient died, and the autopsy made by Dr. Osler showed the optic commissure prominent, optic nerves a little swollen and white, the commissure intact. Left optic tract normal, right completely involved in a growth which extended from the temporal lobe forward. The third nerve looked normal at its point of emergence, right uncinate gyrus greatly swollen. The tumor extended upward and involved the anterior portion of the corpus callosum and the septum lucidum. Right lateral ventricle a little enlarged and the ependyma soft. The other connections of the tumor were not interesting from the point of view of the ophthalmologist. The tumor was a glioma.

The second case was one of tumor (sarcoma) in the region of the sella turcica, and was in a woman who first complained of deafness in the right ear. Six months afterwards there was severe pain in the right trigeminus, failing vision, and diplopia. Right eye slightly prominent, pupil semidilated and responsive only consensually, paralysis of external rectus, haziness around o. d., with signs of slight choked disc. On the left only a slight contraction of the visual field up and in at first, but in six days vision was wholly lost with but little alteration in the normal ophthalmoscopic appearances. Soon after she died, but a few days before the right eye became very prominent. Only a limited autopsy was allowed. A large tumor was found occupying the sella turcica extending to the wings of the sphenoid on either side; optic chiasm soft and swollen, as well as the nerves and tracts. The second, third, fourth, fifth, sixth, seventh, and eighth nerves on the right side and the second and third on the left were involved. BURNETT.

OLIVER'S (131) observations, which are a continuation of a similar report made last year, are very thorough, but too long to embody in an abstract with justice to the original. BURNETT.

THE REPORT (132) was made by Dr. L. Howe, chairman of the committee. It recounts, first, the apparent fact that blindness in the United States is increasing five times as fast as the population ; secondly, that the increase is greatest in the East and in the South. This increase in the East is probably due to immigration, the law in regard to eye diseases being very lax. The report includes a tabulation of 50 cases of blindness in blind-asylums and alms-houses in the State of New York. From this we learn that 14.51 % are due to ophthalmia neonatorum, and 12 % to diseases of the cornea primary or secondary to conjunctival disease. The report insists on the duty of the profession in making widespread the dangers of ophthalmia neonatorum among all classes of people, and of the necessity of legislation for that purpose, and of the importance of teaching to students of medicine and to midwives the methods of preventing and treating these cases of sore eyes in babies. Immigration laws should also be amended so as to require all contagious sore eyes to be held in quarantine. BURNETT.

The object of STEVENS' (133) paper is to show the connection between the strain from ocular defects and pain in the face often limited to one tooth, leading frequently to a false diagnosis of dental disease. BURNETT.

In a man aged thirty-eight choked disc developed in both eyes with subsequent blindness. Pupillary reaction and movements of the eyes were normal. WINKLER (135) thought that the symptoms indicated a large, slowly growing tumor in or around the left hemisphere of the cerebellum with pressure upon the vermis. After trephining a hard body was felt at a depth of 1½ *cm* after several exploratory punctures with a delicate needle. The operation was discontinued. Much cerebro-spinal liquid escaped, and for a few days the patient could see a little. After ten days, however, there was complete blindness, and death followed two months later. The autopsy revealed a tumor the size of a hen's egg, attached with a long pedicle to the right tentorium cerebelli (endothelioma). In four other cases of cerebral tumor, in which an operation was undertaken, no choked disc was observed.

MISCELLANEOUS NOTES.

A.—Reviews.

Die Schattenprobe (The Shadow Test). By Dr. Eugene Fick, Lecturer at the University of Zurich. Wiesbaden: Bergmann, 1891.

This monograph, of 67 large octavo pages, handsomely gotten up, with three colored plates and several drawings in the text, is, as far as we can judge, the best guide for learning skiascopy that has been published. It gives a full exposition of the subject, theoretical as well as practical, containing all that is useful, omitting what is unessential, superfluous, and erroneous in the extensive discussion of this mode of examination, which during the last decade has sprung into wide-spread favor in France, England, and America. After an introduction of five pages the author treats of the *theory of skiascopy* under the following heads: The essentials of the shadow test; the shape of the shadow; the velocity of its motion; the influence of the mirror; the theory in the case of regular astigmatism. The *application of skiascopy* is described under the heads: The apparatus; the manipulation; the results.

In the conclusion the author discusses the value of skiascopy, comparing it with the other tests. His judgment is altogether favorable, though not the expression of a one-sided enthusiast. "In accuracy," he says, "the shadow test equals the determination of refraction by the upright image, in higher degrees of ametropia it even surpasses it." Fick's monograph will be welcome to all who want to inform themselves thoroughly and without inordinate loss of time on the details of this important method of determination of refraction. It will no doubt largely contribute to popularize the method in Germany. H. K.

On the Pathology and Treatment of Glaucoma, being a revised publication, with additions, of the Erasmus Wilson Lectures, delivered at the Royal College of Surgeons of England, in March, 1889, by PRIESTLEY SMITH. London : Churchill, 1891.

Every oculist will like to have this remarkable monograph in his library. In its 198 octavo pages, with very many illustrations, it contains a wealth of original observation and research on a subject which belongs to the most important and, in spite of all labor bestowed on it, the least understood in ophthalmology. A great deal can be learned from this monograph not only as to actual information of things established, but also as to methods how properly to investigate cases and specimens which may come before us. H. K.

Transactions of the Ophthalmological Section of the American Medical Association, at the forty-second meeting, held at Washington, D.C., May 5–8, 1891.

This is a volume of 380 small octavo pages, cleanly printed on good paper, somewhat illustrated, containing the papers read before the meeting and the discussions of them, reprinted from the Journal of the Association. It is a thankworthy enterprise to present these many valuable contributions to ophthalmology in a neat volume to those who take special interest in this branch of medicine. In this way they will be less liable to be overlooked and lost, but more appreciated and made the incentive for new scientific and practical work.

Two of our French contemporaries have taken a new and higher flight. 1. The **Annales d'oculistique** have been converted into a monthly, under the editorship of Drs. VALUDE and SULZER, instead of a bimonthly under the late Dr. WARLOMONT. They are published in Paris, and what has appeared since the death of Warlomont gives a good promise for the future. 2. The **Archives d'ophtalmologie,** edited by PANAS, LANDOLT, GAYET, and BADAL, will likewise be converted to a monthly from a bimonthly, increasing the number of its pages from 576 to 768. Besides the original papers, the *Archives d'opht.* will in future furnish a complete bibliography with abstracts of the more important publications. Drs. NUËL and VAN DUYSE, the former associates of Dr. Warlomont, will be added to the editorial staff, and Dr. PARENT, the "popular secretary of the French Ophthalmological Society," will be the secretary of the journal. "Les Archives présenteront alors de plus en plus l'organe classique des

publications ophtalmologiques en langue française ainsi qu'un recueil bibliographique complet et rationnel."

The Ophthalmic Record, edited and published in Nashville, Tenn., by Dr. G. C. SAVAGE, with a Department for Laryngology, Rhinology, and Otology edited by Dr. GEO. H. PRICE, a lively monthly journal of thirty-two pages each number, has appeared regularly since July, 1891. Its articles are short, varied, and practical. Price $2.00 per annum.

We have just received the first (January) number of another American ophthalmic and aural periodical, the **Annals of Ophthalmology and Otology,** a journal of practical ophthalmology, otology, laryngology, and rhinology. Edited by JAMES P. PARKER, M.D. Published quarterly, Kansas City, Mo., under the auspices of the Corporation of the Kansas City Polyclinic Medical School. Subscription price $2.00 a year; each number to contain about eighty pages.

The present number has seventy-four pages, and contains sixteen original articles, forty pages being devoted to ophthalmology, twenty-five to otology and laryngology, nine to abstracts from literature and a short editorial. From the latter we learn that "hereafter this journal will contain [besides original papers], under the head of Progress, a *complete*, *systematic*, and *early* review of the current ophthalmological, otological, laryngological, and rhinological literature of the world, prepared by the following collaborators: Dr. B. E. Fryer, of Kansas City, Casey A. Wood and T. M. Hardie, of Chicago, and Dr. M. D. Lederman, of New York."

B.—NEWS.

A New Eye and Ear Hospital. September 19, 1891, the corner-stone of the Maine Eye and Ear Infirmary was laid at Portland under impressive ceremonies. The originator and chief promoter of this beautiful institution, of which we give the accompanying illustration, is Dr. E. E. HOLT, who, for five or six years, has conducted the work of the Infirmary in insufficient quarters. It is expected that the structure will be finished by next June at a total cost of about $50,000. The State appropriated $5,000. The imposing building will be arranged according to the newest and most approved hospital architecture. The heating, for instance, will be done by hot water, using a Spence boiler com-

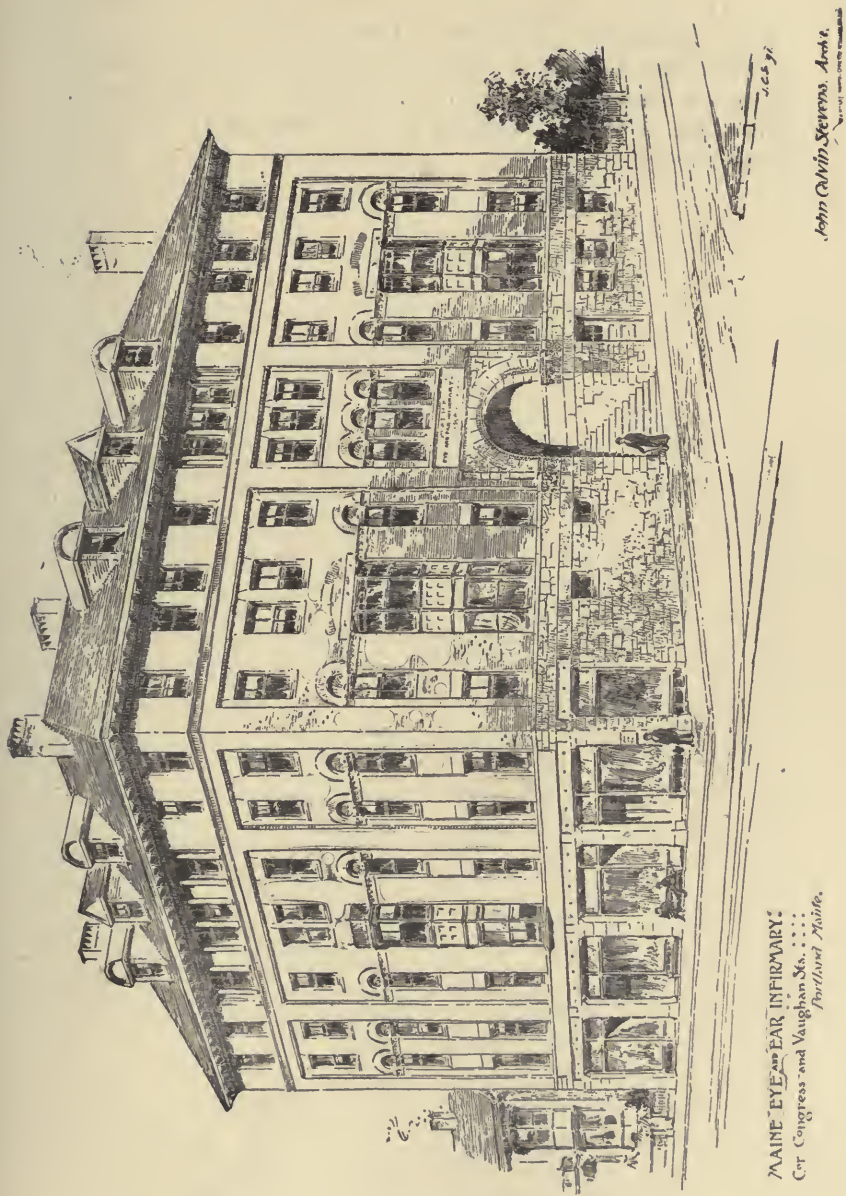
John Calvin Stevens, Archt.
MAINE EYE and EAR INFIRMARY.
Cor Congress and Vaughan Sts.
Portland Maine.

bined with a steam coil, heating air to 80° F., and blowing it in at the rate of 250,000 cubic feet per hour. There was opposition to the erection of a special eye and ear hospital on the part of the General Hospital, but it seems broken, and the new hospital will enjoy the undivided support of all. It promises to be an institution of which Maine, Portland, and in particular Dr. Holt, may well be proud.

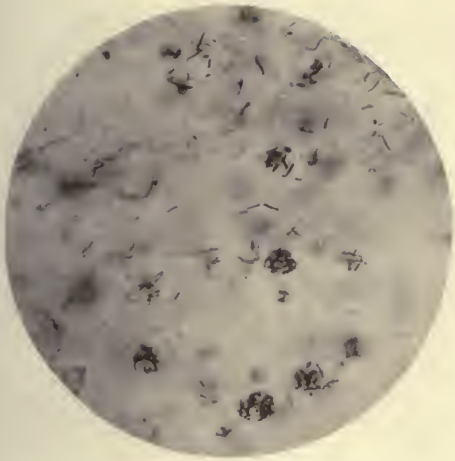

1.



2.

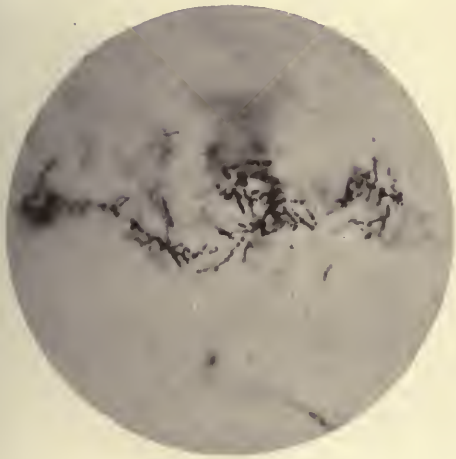

3.

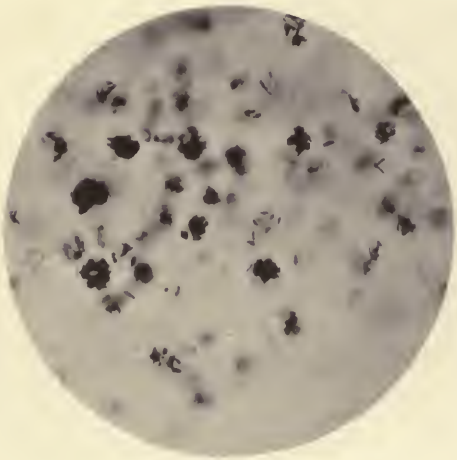

4.

Poplawska, Fremdkörper-Panophthalmie. O. Müller, phot.

Lichtdruck von J. Brunner, Winterthur.

5.

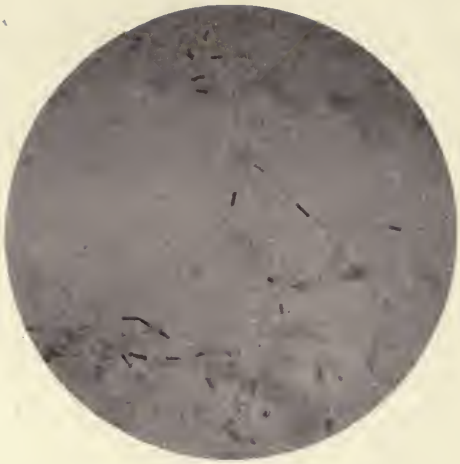

6.

7.

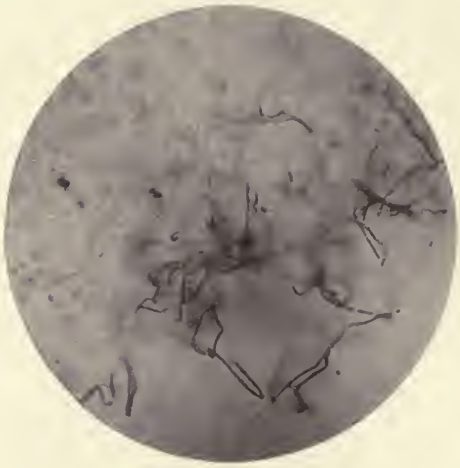

8.

Poplawska, Fremdkörper-Panophthalmie. O. Müller, phot.

Lichtdruck von J. Brunner, Winterthur.

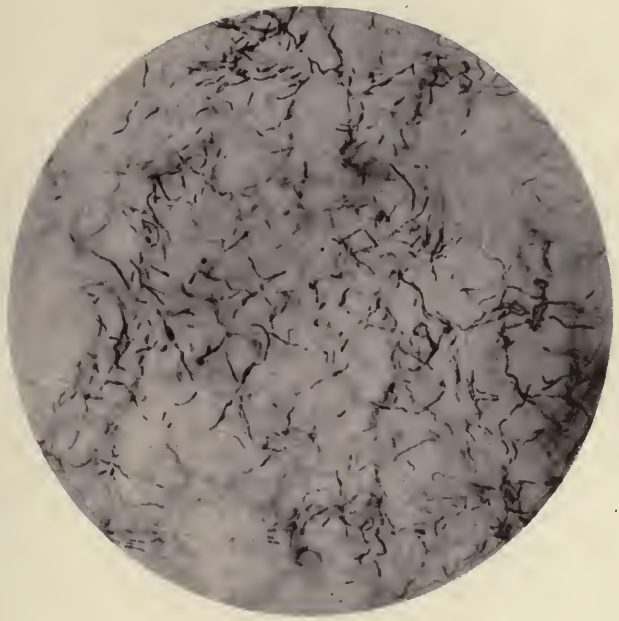

9.

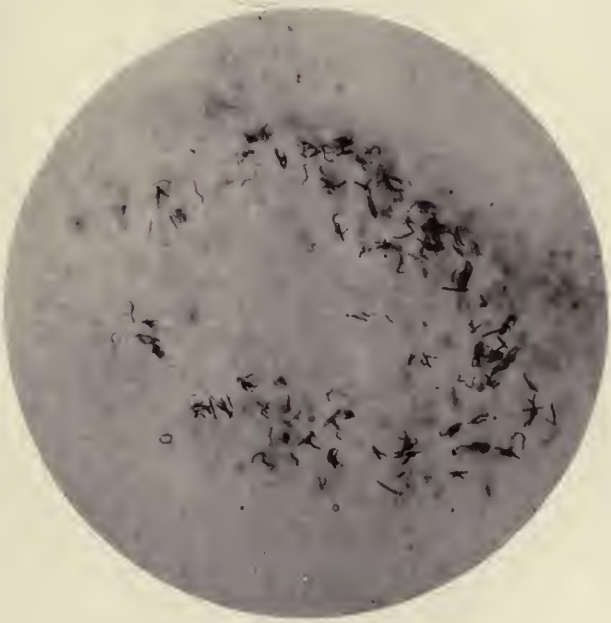

10.

Poplawska, Fremdkörper-Panophthalmie.

O. Müller, phot.

Fig. 1.

Fig. 2.

Tab I

Fig. 3.

A.W. Head, del.

Fig. 4.

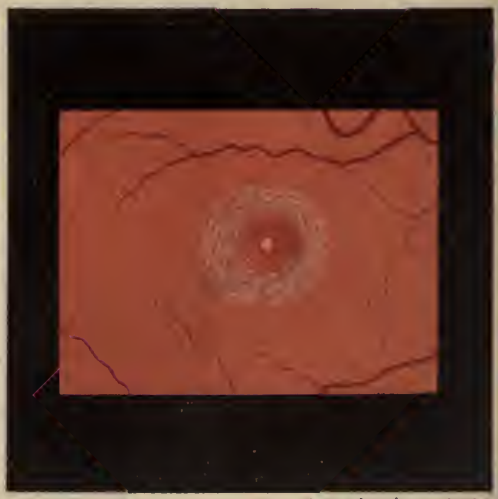

A.J. Abraham, lith.

Fig. 5.

Fig. 6.

Fig. 7.

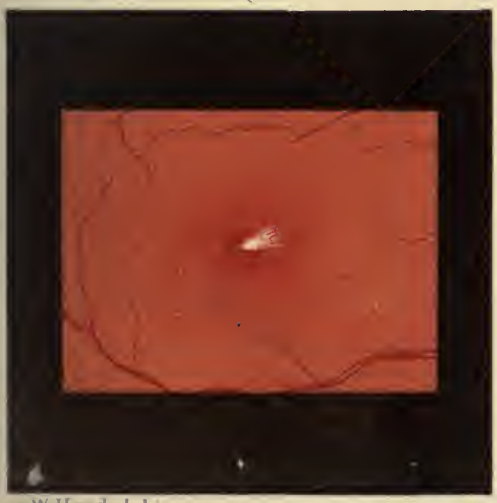

A.W. Head del.

Fig. 8.

A.J. Abraham lith.

Fig. 9.

Fig. 10.

Tab. III.

Fig. 11.

Fig. 12.

G. Lindsay Johnson, del.

A. J. Abraham, lith.

Fig. 13.

Fig. 14.

Tab. IV

Fig. 15.



Fig. 16.

L. W. Head. del.

A. J. Abraham, lith.

CONTENTS OF VOLUME XXI., NUMBER 2.

PAGE

1. Further Experiments on the Lymph-Streams and Lymph-Channels of the Eye. By H. Gifford, Omaha, Neb. (With plate) . . 171

2. Binocular Metamorphopsia Produced by Correcting Glasses. By Harry Friedenwald, A.B., M.D., Baltimore. 204

3. An Iris Shield—A New Cataract Instrument. By Charles W. Dodd, M.D., Cincinnati. (With a woodcut) 213

4. On Vaccine Blepharitis. By Charles Zimmerman, M.D., Milwaukee, Wis. 215

5. Idiopathic Vitreous Hemorrhages. By Dr. James A. Spalding, Portland, Me. 220

6. Retention Cyst of the Conjunctiva of Traumatic Origin. By Dr. Enrique Lopez, Habana. Translated by Dr. C. E. Finlay. . 231

7. Some Squint Statistics. By H. H. Seabrook, M.D., New York. . 234

8. Contributions to Clinical Ophthalmology · being Gleanings from my Case-Books. By Swan M. Burnett, M.D., Ph.D., Washington, D.C. (With eight illustrations) 248

CASE I.—Retro-bulbar neuritis, without discoverable cause; marked shot-silk retina; central scotoma for red; peculiar visual fields. CASE II.—Cyst of the iris. CASE III.—Loss of eye in early life from inflammation (traumatic); sympathetic irido-choroiditis many years after; enucleation of the atrophic ball; relief to the irido-choroiditis; formation of bone in the vitreous or retina, springing from the optic disc. CASE IV.—Total dislocation of the lens under the conjunctiva to the nasal side from a blow; removal; preservation of the eyeball. CASE V.—A case of partial dislocation of the lens under the conjunctiva upward. CASE VI.—Successful extraction of a floating degenerated lens from the vitreous chamber. CASE VII.—Chemosis of the conjunctiva and lid caused by the ingestion of a single grain of quinine. CASE VIII.—Periodic congestion of the conjunctiva from vaso-motor disturbance. CASE IX.—Wrinkling of the cornea.

9. On Congenital Coloboma of the Optic Nerve. By Prof. W. Manz, Freiburg, Baden. Translated by Dr. Ward A. Holden, New York. (With Figures 1–4, Plate I. II., and Figure c, Plate III.) 263

10. Detachment of the Choroid. By Dr. Anton Elschnig, Gratz. Translated and abridged by Dr. J. A. Spalding, Portland, Me. (With Fig. 5, Plate I. II.) 272

PAGE

11. A Case of Sarcoma of the Cornea. By Dr. Konrad Rumschewitsch, Kiew. Translated by Dr. Ward A. Holden, New York. (With Figure 6, Plate I. II.) 277

12. On Pigment Striæ with Secondary Changes in the Retina after Hemorrhage. By Dr. O. Plange, Münster. Translated by Dr. Ward A. Holden, New York. (With Figs. a. and b, Plate III.) 282

13. On the Formation of Dark Angioid Streaks as an Unusual Metamorphosis of Retinal Hemorrhage. By H. Knapp. (With an ophthalmoscopic drawing) 289

14. On Glaucoma after Discission of Secondary Cataract and its Successful Treatment by Iridectomy. By H. Knapp . . 293

15. An Extreme Cylindrical Effect from a Tilted Spherical Lens. By E. L. Jones, M.D., Florence, Ala. 301

16. Systematic Report on the Progress of Ophthalmology during the Second Quarter of the Year 1891. By St. Bernheimer, Heidelberg; C. Horstmann and P. Silex, Berlin. With the co-operation of S. M. Burnett, Washington; Dantone, Rome; Hirschmann, Charkow; E. Marckwort, Antwerp; P. v. Mittelstädt, Metz; L. Werner, Dublin; C. H. A. Westhoff, Amsterdam; Schiötz and Ole Bull, Christiania, and Deus, Berlin. Translated by Dr. F. E. D'Oench, New York 316

A.—Dr. St. Bernheimer. Text-books, monographs, treatises on general, bibliographical, and historical subjects, 303; General pathology, diagnosis, and therapeutics, 304; Instruments and remedies, 305; Anatomy, 307; Physiology, 308.

B.—Dr. C. Horstmann. Anomalies of refraction and accommodation, 309; Lids, 311; Lachrymal apparatus, 313; Muscles and nerves, 314; Orbit and neighboring cavities, 317; Conjunctiva, cornea, sclera, anterior chamber, 317.

C.—Dr. P. Silex. Iris, 320; Choroid, 320; Glaucoma, 322; Sympathetic ophthalmia, 323; Vitreous, 323; Lens, 324. (To be concluded in next number.)

17. Book Review 326

Festschrift zur Feier des Siebenzigsten Geburtstages von Hermann von Helmholtz. Stuttgart, 1891. Published by the German Ophthalmological Society. Reviewed by Dr. S. M. Burnett.

18. Obituary 330

I. Sir Wm. Bowman, Bart., F.R.S.
II. Hasner von Artha.

ARCHIVES OF OPHTHALMOLOGY.

FURTHER EXPERIMENTS ON THE LYMPH-STREAMS AND LYMPH-CHANNELS OF THE EYE.

By H. GIFFORD, Omaha, Neb.

(*With plate.*)

IN this paper it is not proposed to consider the histology of the finer lymph channels, but merely the paths by which the chambers and larger lymph-spaces of the eye communicate with each other and with the parts external to the eye. The literature of the subject is so extensive that to review it at all thoroughly would consume too much valuable space. For *résumés* the reader is referred to the papers of Schick [1] and of Staderini.[2]

My own experiments have been continued, with the interruptions unavoidable in active practice, from 1886 up to the present time. They are not fully completed, but as this completion may have to be indefinitely postponed, I feel justified in publishing such results as have already been obtained.

Methods.

For observing the transportation of pigment granules by the lymph-currents of the living animal, I have injected suspensions of india-ink and of cinnabar in a $\frac{1}{2}$–$\frac{3}{4}$ % sodium chloride solution. The cinnabar has the advantage of being less likely than india-ink to cause marked reaction, but the particles are heavier and less easily transported by the lymph-stream. India-ink, even when thoroughly sterilized, causes, when much is introduced, quite a sharp reaction, but

[1] Schick. *Archiv für Ophthal.*, xxxi., 2.
[2] Staderini. *A. f. O.*, xxx.

it reaches fine channels which I have not found demonstrable with cinnabar. Injections into the vitreous I have made both through a scleral incision and through the puncture of a hypodermic needle alone, with no perceptible difference in the results except that with a free incision the pigment is not carried out of the vitreous so promptly. The scleral incision does away with the theoretical objection that the injection might interfere with natural currents by raising the tension, but, practically, even when the pigment is injected through a hypodermic puncture, so much fluid escapes from the opening immediately on the withdrawal of the needle, that it is evident that this opening is sufficient to draw off any excess of intraocular fluid before the pigment granules can have been influenced perceptibly by the currents of the eye. In injecting pigment into the anterior chamber of the living rabbit, the most satisfactory method is that described by me in 1887.[1] Instead of piercing the cornea an incision is made through the ciliary body into the posterior chamber. Through this the needle or glass canula is passed by way of the pupil into the anterior chamber. By gently lifting the iris, part or all of the aqueous can be evacuated and its place filled with the pigment suspension, which then cannot escape except by the natural outlets; while, if it is injected through a corneal wound, much or nearly all of it escapes at once on the withdrawal of the instrument. In injecting the anterior chamber and its outlets, *post mortem*, I have obtained the most striking results with asphalt chloroform (15 %) and a solution of alkanet in turpentine. In the experiments with ferro-cyanide of potassium and with fluorescein no important departure from the ordinary methods was made. Except where otherwise stated, albino rabbits were used for all experiments.

Experiments on Living Animals with Ferro-Cyanide of Potassium.

As is well known, the method of Memorsky,[2] consisting in the introduction of a solution of potassium ferro-cyanide

[1] GIFFORD. Trans. Internat. Med. Cong., 1887.

[2] MEMORSKY. *A. f. O.*, xi., 2.

into the eye and precipitating it by placing the eye, after enucleation, in a ferric chloride solution, gives in the blue precipitate formed a very delicate test for the presence of the salt in the tissues into which it may have penetrated during life. Knies [1] assuming that, in general, a sharp blue line in an eye thus treated indicated a lymph-stream, used this method for attaining far-reaching conclusions as to the currents in the eye; and his results were largely confirmed and to some extent widened by Weiss [2] and by Ulrich [3]; the latter concluding that the aqueous, in passing from the posterior to the anterior chamber, does not go through the pupil, but traverses the tissues of the iris. Of these experiments, I have made twenty-eight; twenty-four injections of the ferro-cyanide solution into the vitreous; four subcutaneous injections. The results were, in the main, similar to those described by Ulrich; the sharp blue line passing through the iris root, to which he attributes so much importance, was observed in a large proportion of the cases. Why it was not observed or commented upon by Knies and Weiss I cannot understand. I have not, however, found the line to be so constant as one would expect from Ulrich's descriptions. He speaks of obtaining pictures indicating that a part of the stream from the posterior chamber passes through the iris into Fontana's spaces, without entering the anterior chamber at all; meaning by this, I suppose, that he has noticed the blue line taking this course. I have not only seen this, but have seen the line passing from the zonula through the ciliary body into the inner layers of the sclera so far back as not to touch the posterior chamber, nor even the front half of the ciliary body. I have also found the line passing through the iris half-way down toward the pupil. Sometimes there are three or more lines in different parts of the iris, and these, or the single one, may go only part way through the iris either from behind forward, or the reverse; or a line may start from the anterior surface

---

[1] KNIES. *Virchow's Archiv*, lxii. and lxv., and *Archiv für Augen- und Ohrenheilk.*, vii.

[2] WEISS. *A. f. O.*, xxv., 2.

[3] ULRICH. *A. f. O.*, xxvi., 3, and *A. f. Augenheilk.*, xii.

and taking a curved course pass first toward the posterior surface, but turn and, without reaching this, pass out at the anterior surface again. Such variations occur without any easily ascertainable cause. Sometimes, in eyes treated as nearly alike as possible, there will be very decided differences in the lines, and the same is true of the corneal and scleral lines of Knies. In the central canal of the opticus, along the vessels, I have occasionally found a blue coloration extending out into the orbital tissue, but this only exceptionally. In the few experiments in which I have injected the ferro-cyanide solution subcutaneously, the eyes have twice presented the appearance described by Ulrich. The blue line in the iris was nowhere sharp and distinct, but there was a diffuse blueness in the iris root. In many cuts, however, the appearance was not even that of a diffuse line passing clear through the iris, but gave the impression of the solution having been soaked up from the aqueous by the anterior surface, as the blue began at this surface and extended not more than half-way through toward the hind surface, becoming fainter the greater the distance from the fore surface. There was also, after these subcutaneous injections, an occasional blue line farther down in the iris toward the pupil. Regarding the blue in the cornea proper, both after the vitreous and the subcutaneous injections, the evidence was decidedly in favor of the solution having penetrated it, if at all, not directly from the aqueous through Descemet's membrane, but indirectly by way of the tissues of the sclero-corneal junction. When the ferro-cyanide solution was not left long in the eye or circulatory system before the animal's death, the cornea frequently had no blue in it except near the periphery and in the intercellular lines of Descemet's epithelium. The longer the experiment was continued the greater the tendency for the blue to extend clear across the cornea from border to border. I would not assert on the strength of this that none of the ferro-cyanide diffuses through Descemet's membrane from the aqueous into the cornea, but simply that this does not occur, if at all, so rapidly as the diffusion from the periphery.

But although my results in most respects agree with those

of Knies, Weiss and Ulrich, in my interpretation of them I am obliged to differ radically from these writers. In fact my experiments on dead animals have convinced me that the ferro-cyanide method, as used by them, is practically useless in investigating the normal lymph-stream, and for this reason I spare the reader a more minute description of the results obtained by it in the live animal.

Injections of Ferro-Cyanide into the Vitreous of Dead Rabbits.

Stilling[1] mentions a verbal communication from Weiss to the effect that results similar to those obtained by him in living animals had also been obtained in dead eyes. Aside from this, the only reference that I know to such experiments is made by Ulrich in a footnote to his last paper. He here mentions having tried injections of ferro-cyanide into the vitreous of dead pigs' eyes. He speaks of the results as radically different from those obtained in the living animal, but his descriptions would seem to indicate a difference not so radical after all. I have made twelve experiments of the kind. The rabbit having been chloroformed till the last sign of life had been gone for from five to ten minutes, a few drops of the ferro-cyanide solution were injected into the vitreous, either simply by puncturing with a hypodermic needle or through a broad scleral incision, and the whole animal put into an oven, kept at blood heat for an hour, the eyes then being enucleated and hardened in tincture of ferric chloride diluted with alcohol. In six cases Ulrich's and Knies' lines in the iris and cornea were found as well marked as in any case where the injection had been made *ante mortem.* In one case where barely enough ferro-cyanide solution had been injected with a hypodermic to raise the tension of the dead eye to near the normal, and the needle, instead of being withdrawn at once had been pushed through the sclera on the opposite side and left in position till the eye was hardened, the blue lines were brighter and more

---

[1] STILLING. *A. f. Augenheilk.*, xvi.

marked than I have ever obtained them in experiments on a live animal. To meet the objection of Ulrich that even in the dead eye the pressure in the vitreous might force the ferro-cyanide out through the iris root, several eyes were opened so widely by scleral incisions of more than one centimetre in length that the question of pressure could be entirely eliminated. Ferro-cyanide was then injected freely, most of it flowing back as fast as it was introduced. In the majority of these eyes, also, the lines of Knies and of Ulrich were found. In one eye about one third of the vitreous was scooped out through an incision about one *cm* long and replaced by ferro-cyanide solution. This eye also showed a well-marked Ulrich's line. In these eyes the retina and sclera were often blue throughout, except near the corneal border, instead of showing the narrow lines generally seen after injection into the living eye; the central canal of the opticus, also, contained a blue precipitate more often than in the experiments made during life.

My conclusion therefore is that while the blue lines obtained by the ferro-cyanide method are at first sight very striking, and may, to some extent, be influenced by vital processes, there is no evidence to show that they really follow the paths of normal lymph-streams. Aside from the fact that those upon which most stress have been laid occur equally well in the dead eye, their occurrence in the living eye is subject to such variation and is so entirely independent of any histological basis as to throw most serious doubts on their physiological importance. The believers in the value of the method have themselves mentioned this lack of any histological basis for the lines, without having laid sufficient stress upon it. In many parts of the eye these blue lines appear under conditions rendering it manifestly impossible that they indicate the path of the lymph-streams. A line is sometimes seen passing from the vitreous obliquely into the lens and then back into the vitreous again; or from the dural sheath down into the optic nerve and then out again. The scleral line of Knies sometimes leaves the eye and passes obliquely through the recti muscles or orbital tissue, in a sharp straight line which it would be absurd to

suppose a lymph-stream to follow. On the other hand, it is equally unreasonable to suppose that the ferro-cyanide would *diffuse* through the tissues in such sharply defined lines as are often seen, without any histological basis. A completely satisfactory explanation of the origin of all these lines is difficult to give. Sometimes, though only occasionally, they occur in the neighborhood of what other experiments show to be lymph-channels, as, for instance, along the blood-vessels passing through the sclera, sclero-corneal junction, and optic nerve. Whether the ferro-cyanide has reached these channels by simple diffusion or has been carried thither by some current, is impossible to say. *In most cases, however, these lines undoubtedly represent the boundary between the area into which the ferro-cyanide has diffused and that which is still free from it.* Along such a boundary there is an uncommonly strong precipitation of the blue salt, because the instant the solution of ferric chloride into which the eye is put penetrates to such a line, precipitation takes place, thus producing a line of liquid containing less of the salts in solution, and toward such a line the salts from both sides tend to diffuse and be in turn precipitated, the result being the accumulation of the blue precipitate in a more or less distinct line. This can be demonstrated by injecting several drops of a solution of ferro-cyanide into the centre of a piece of liver one or two inches in diameter and, after some minutes, hardening in tincture of ferric chloride diluted with alcohol. On cutting through such a piece, I have found the tissue into which no ferro-cyanide had penetrated marked off from the more internal portions containing it by a sharp blue line precisely like those found in the eye. The rather constant presence of a blue precipitate in the iris root, in many cases where the boundary line seems to fall elsewhere, is probably due to the proximity of this structure to Fontana's spaces, through which all the aqueous has to pass and with which its meshes freely communicate. Diffusible salts also undoubtedly pass into the iris to some extent from the posterior chamber, and where a salt is injected subcutaneously some of it probably diffuses through the walls of the vessels which abound in the iris root.

Experiments with Subcutaneous Injections of Fluorescein.

Convinced by the results just mentioned of the small value of the use of diffusible substances in this work, and in view of the results of Ehrenthal,[1] who has obtained all the characteristic phenomena of Ulrich's line by injecting a weak solution of fluorescein under low pressure into the carotid of the dead rabbit, I have made only five such experiments. My results have corresponded most nearly with those of Ulrich. The fluorescent line which appears in the anterior chamber about ten minutes after injecting 3–5 cc. of a 20 % solution of uranin (soluble ammonia salt of fluorescein), under the skin, unquestionably takes its origin in the upper periphery of the chamber. When the eye is rotated, the line always changes, though sometimes a little slowly, so as to remain vertical; it is not, in other words, bound up with any particular part of the iris periphery. In my first two or three experiments on albino rabbits, I thought I could detect the yellow coloration of the whole iris periphery which Ulrich describes as evidence in favor of his theory of a stream through the iris root; but upon the most careful examination in my last experiment with an albino rabbit, I felt uncertain whether the yellow was really in the iris root, or in the almost transparent edge of the limbus corneæ, which in all experiments is one of the earliest tissues to show a yellow color. Granting, however, that it is in the iris, I see no reason for dismissing so scornfully, as Ulrich does, the explanation of Schick, that the color is due to the fluorescent fluid in the posterior chamber shining through the translucent albino iris. In any event, it is reasonable to suppose that enough fluorescein might diffuse from the posterior chamber through the iris root to appear on the anterior surface, without this constituting any proof that the lymph-stream takes this course. I regard Ehrenthal's explanation of Ulrich's line as the most satisfactory. He considers it due to the force of gravity acting upon the fluorescein which diffuses into the periphery of the anterior chamber from the plexus of blood-vessels in this

[1] EHRENTHAL. *Inaug. Diss.*, Königsberg, 1887.

vicinity; and as he has shown that the line appears equally well whether the animal be dead or alive, few will be inclined to believe that the normal lymph-stream has much to do with it.

Injections of Fluorescein into the Living Vitreous.

In view of the foregoing, I should not have busied myself further with fluorescein but for the statement of Pflüger,[1] partially confirmed by Schoeler and Uthoff,[2] that fluorescein injected into the vitreous does not reappear in the aqueous. This appeared to me very surprising, in view of the readiness with which I had observed ferro-cyanide diffuse from the vitreous into the aqueous. To test the question, therefore, the following experiment was made: September 17, 1890, small black rabbit, 3–4 gtt. of 10 % solution of uranin injected into each vitreous back of and below the centre. On withdrawing the needle about the same quantity of fluid flowed out under the conjunctiva. After $\frac{3}{4}$–1 hour, vitreous strongly fluorescent, but no fluorescence for certain in the aqueous. On slight struggling of the rabbit, however, clouds of fluorescence could be seen to burst into the anterior chamber through the pupil in each eye. After 10–15 mins. these clouds diffused through the aqueous which, even then, could not be distinctly seen to be fluorescent, in the intact eye, but on making a paracentesis, after washing the cornea and conjunctival sac carefully, the escaping aqueous was seen to be strongly fluorescent. After some weeks the same experiment was tried on the same rabbit, with results proving equally clearly the passage (by diffusion or otherwise) of fluorescein from the vitreous to the aqueous.

Introduction of Small Quantities of Pigment into the Chambers of the Eye and into the Cranial Cavity, in Live Rabbits.

Although I am convinced that this method gives the most trustworthy results, as to the paths and directions of the

---

[1] PFLÜGER. *Zehender's Monatsblätter*, xx.

[2] SCHOELER and UTHOFF. *Nagel's Jahresbericht*, xiii.

lymph-currents, continued experience with it has taught me that it has more decided limitations than I at first supposed. At first I was inclined to believe, wherever considerable pigment was carried into lymph-channels, apparently without the aid of leucocytes (*i. e.*, without pigmented leucocytes being present along the track), that it must have been transported by some regular stream. I have found, however, that in some channels, especially in the finer ones, the pigment finds its way equally well in precisely opposite directions. In the lymphatics surrounding the small blood-vessels of the optic nerve, for instance, india-ink passes regularly from the large canal of the retinal vessels toward the periphery of the nerve and into the intervaginal space; but it also passes equally well in the opposite direction, from the intervaginal space through the pial sheath, along the small vessels toward the central canal; and this apparently without the intervention of leucocytes, though in this latter direction I have not observed it to pass more than half-way from the periphery to the centre of the nerve. The same can be observed to some extent in the lymphatics surrounding the venæ vorticosæ; here pigment passes from the perichoroidal space out to the space of Tenon, but also, for a short distance at least, from the latter in toward the choroid. Even in the central canal of the optic nerve, where the evidence of a stream passing out along the vessels is most conclusive, I have observed small quantities of pigment passing from the intervaginal space for a short distance in toward the vitreous, though in nothing like the quantity which at the same time is carried out from the intervaginal space into the orbital tissue outside the nerve. These facts tend to confirm the judgment of Leber as to the caution with which conclusions must be drawn from the presence of pigment in any tissue, as to the method of its transport thither. As I have mentioned in my first paper, the absence of leucocytes is no proof that they have not been instrumental in carrying pigment to any point where it may be found, since, for anything we positively know to the contrary, they might carry the pigment granules for a certain distance, and then give them up, without leaving any

trace of their action. Conversely, of course, pigment might be carried for some distance by a current, and then be taken up by leucocytes, so as to appear to have been transported by them. But while the first of these suppositions may possibly explain the passage of pigment against the stream in the larger channels, in the smaller ones it is more probable that there is either no regular current, or so slight a one that it is liable to be stopped or even reversed by the slight variations of pressure which may accompany the movements of the eyeball; so that pigment finds its way all through these finer channels, as it would through the interstices of a loose sponge, if the latter were gently moved for some time in a fluid containing pigment in suspension. In certain channels, as in those of the central canal of the opticus, so much more pigment is carried in one direction than in the other that we are justified in saying, from this evidence alone, that a stream flows in a certain direction; but even where it does not decide as to the existence or direction of a stream, the pigment method is a valuable supplement to injections under low pressure in the dead animal, as the granules whether carried by leucocytes or not point out the open channels everywhere, without leaving room for the objection to which injections in the dead animal are always open, namely, the possibility of the formation of false passages.

I.

INTRODUCTION OF PIGMENT INTO THE CRANIAL CAVITY.

My latest experiments under this head have developed nothing new as to the passage of pigment from the cranial cavity down to the eye, which almost invariably occurs; but they have led me to modify considerably my views as to the lymph-current between the intervaginal and perichoroidal spaces. Although in my previous experiments,[1] I had not observed pigment pass from the intervaginal to the perichoroidal space, I had seen anthrax bacilli and blood do this to some extent, and had concluded that this was the

[1] GIFFORD. *A. f. Augenheilk.*, xvi., and these ARCHIVES, xv., p. 153.

normal course of the lymph-stream. Deutschmann[1] also subscribes to this view as the result of a single experiment in which the pigment passed from the cranial cavity forward through the perichoroidal space to the venæ vorticosæ and along these vessels out to Tenon's space. My negative results with pigment I explained by assuming that the pigment came down from the cranial cavity in such quantities that the narrow entrance from the intervaginal to the perichoroidal space was blocked by it; but I am now convinced that this explanation is incorrect. I have had the same negative results when the quantity of pigment brought down from the cranial cavity was so small as to preclude the idea of any blocking of the channels; and even in the cases where, from microscopic appearances a blockade might be thought of, I have observed the pigment passing from the main mass along the small vessels into the nerve and through the dural sheath to Tenon's space, but not into the perichoroidal space. Considering then the overwhelming majority of negative results obtained by Quincke,[2] Zellweger,[3] Deutschmann, and myself over the single positive result of Deutschmann and my own three positive results, it must be admitted that while there are evidently open channels between the intervaginal and perichoroidal spaces, the evidence is decidedly against the existence, as a rule, of any stream in them from behind forward; rather, if any, in the contrary direction, when we remember that the pressure in the perichoroidal space is probably very nearly the same as that in the vitreous and hence considerably higher than that in the intracranial and intravaginal spaces.

The main outlet for the pigment in the intervaginal space leads into the orbital tissues around the central retinal vessels. The pigment also penetrates the dural sheath along the smaller blood-vessels, and along the surface of the sheath, passes forward into Tenon's space as far as the equator of the eye. The pigment is taken up by the whole inner sur-

---

[1] DEUTSCHMANN. Ueber d. Ophthalmia Migratoria. Hamburg, 1889, p. 25.

[2] QUINCKE, *Reichert and Dubois-Reymond's Archiv*, 1872.

[3] ZELLWEGER. *Inaug. Diss.*, Zürich, 1887.

face of the dural sheath of the nerve, but except along penetrating vessels, I have not seen it pass clear through the sheath into the supravaginal space. As previously mentioned, the pigment also passes from the intervaginal space through the pial sheath along the small blood-vessels toward the centre of the nerve. Finally, at the point where the central retinal vessels leave the nerve, although there can be no doubt that the main current is out into the orbit, a small amount of pigment finds its way up for some distance around the vessels toward the vitreous, whether through the agency of leucocytes or an occasional reversal of the current, I am unable to say. In the orbital tissue below the nerve, there is no such strong current toward the cranial cavity as I supposed when I wrote my first paper. The pigment passes partly back along the vessels to the end of the orbit, but also to some extent forward and downward. That there is any main current down toward the floor of the orbit as Deutschmann believes, I doubt. My impression is that there is no decided stream, but that through the motions of the eye and the body, the pigment becomes pretty evenly disseminated throughout the loose tissues of the orbit, with, perhaps, some tendency downward from the force of gravity.

II.

INTRODUCTION OF PIGMENT INTO TENON'S SPACE.

Early in the course of these experiments, a number of results seemed to show that in Tenon's space and the subconjunctival tissue generally, there was a decided stream backward; but a continuation of the experiments has shown me that, in the rabbit, there is no proof of a decided stream in either direction, while in man such evidence as is available points rather to a movement of the subconjunctival lymph toward the cornea. India-ink introduced under the rabbit's conjunctiva passes backward and forward with apparently equal facility; while, in man the blood from slight hemorrhages near the retrotarsal folds moves with remarkable regularity toward the cornea, occasionally passing into

the transparent corneal tissue for fully a millimetre from the limbus. Whether the blood would pass equally readily in the opposite direction is a point worth studying, which at present I cannot decide.

III.

INTRODUCTION OF PIGMENT AND OF ANTHRAX BACILLI INTO THE VITREOUS.

Regarding the results of introducing anthrax bacilli into the vitreous, I have little to add to what I have already published. The bacilli pass regularly out through the central canal of the opticus and into the various channels connecting with it, as previously described. I have never seen them pass clear forward around the lens into the posterior chamber, though in one case they were observed more than halfway through the zonula. Where pigment was introduced into the vitreous (as was done in 35 cases), in all cases except one, where an extensive detachment of the retina occurred, part of the pigment was carried out into the orbit through the central canal of the opticus and into the channels connecting with it, as in the case of the anthrax bacilli.[1] In one case, in which the rabbit was killed about thirty days after the injection, an unusually large quantity of india-ink had passed along the small vessels branching off from the central retinal vessels to the choroid, so that the whole perichoroidal space, as far forward as the ciliary processes, was

[1] From Ulrich's last article one would infer that it is impossible to introduce india-ink into the vitreous without causing so much reaction as to arouse the suspicion that this passage through the opticus is due to a partial blocking of the paths leading forward around the lens, rather than to a natural lymph-stream through the opticus. I should judge from this that Ulrich must have had unusually bad luck with his vitreous injections. I have many times injected one or two drops of a sepia suspension into the vitreous with either no perceptible reaction following, or with so slight and so transient a one that it would be hypercritical to consider that it affected the result. In these cases, the ophthalmoscope often showed the pigment beginning to collect upon the papilla several days after every trace of reaction had disappeared, and continuiug to collect for many days thereafter. The microscope, also, often showed the pigment passing through the nerve without any sign of a blocking of the anterior outlets.

full of free pigment. From the perichoroidal space, the pigment also passed along the venæ vorticosæ to the space of Tenon. In two other cases also, in which, after a detachment of the retina, the pigment penetrated directly from the vitreous through the wound into the perichoroidal space, this passage, along the venæ vorticosæ and also along the vessels penetrating the eye at its posterior pole, was observed. In these two cases, the pigment in the perichoroidal space passed forward to the ciliary processes and backward for a short distance into the intervaginal space. In both, the rabbit had been allowed to live four or five weeks after the injection into the vitreous. From the perichoroid and from the lymphatics around the penetrating vessels, the pigment passes everywhere into the neighboring scleral tissue, whether with or without the aid of leucocytes could not be determined with certainty. Though pigmented leucocytes were present here and there in most cases, in the one case where the pigment reached the perichoroid from the vitreous along the small vessels near the opticus, they were entirely absent from the perichoroidal space, and, whether from a mere coincidence or not, little or no penetration from this space, or from the perivascular lymphatics, into the scleral tissue could be observed.

In all cases some pigment was found remaining in the vitreous, mostly in clumps on the surface of the retina, either free or in leucocytes. Where it was free, no tendency to penetrate into the retina was evident; but where any considerable quantity of the pigmented leucocytes were collected, some of them could generally be seen penetrating into the retina. In cases where a thick layer of free pigment rests in the hollows of the ora serrata, the epithelial cells occasionally seem to take up a few granules and pass them through into the underlying tissue. In only two cases has more than a small amount of pigment reached the space between the retina proper and its epithelial layer. In one of these the pigment was carried in by leucocytes through the inner layers of the retina, just at the commencement of the ora serrata, spreading from here in the space outside the rods and cones, a considerable distance laterally, and back-

ward to the equator of the eye, much of it being taken into the substance of the cells of the retinal epithelium. From this intraretinal space pigmented leucocytes penetrated the retina proper at various points, but none at all passed through the epithelium into the choroid. Anteriorly the pigment was everywhere stopped short at the commencement of the *pars ciliaris.* In the other case an optic neurectomy had been performed some time previously, but the eye was otherwise perfectly normal. The pigment passed out through the optic nerve, as in ordinary cases, but along one small vessel, branching off from the main ones in the central canal, a considerable quantity of pigment, probably borne by leucocytes, entered the intraretinal space and spread out as in the preceding case, except that here at one point one or two pigmented cells were found outside of the epithelium in the choroid. It may be that to get there they had followed along some penetrating blood-vessel, but of this I could not be certain. Of the pigment remaining in the vitreous more was always found at the bottom of the chamber, but I could determine no definite relation to the canal of Cloquet.

Regarding the passage of pigment[1] forward around the lens, in quite a number of cases where only one or two drops of the pigment suspension were injected into the vitreous and the animal was killed no later than five or six days thereafter, no pigment could be seen to have passed through the zonula, while the passage through the optic nerve was well marked. But when the animal was left alive for from one to four weeks there was almost invariably a considerable passage of free pigment (with or without pigmented leucocytes, according to the severity of the reaction following the operation), occasionally only part way through the zonula, but generally clear through into the posterior chamber, and from here through the pupil into the anterior chamber, where part of it was taken up by the anterior iris surface, but the greater part found its way into Fontana's spaces, whence it tended to pass out along the paths to be mentioned later in describ-

[1] The passage of solid pigment particles through the zonula in the normal eye was first described in my paper of 1887, Ulrich having previously failed to observe it except in one eye with an anterior synechia.

ing the results of injections into the anterior chamber. There is always more pigment in the zonula and in the posterior and anterior chambers below than above. In the posterior chamber one generally finds much less pigment than in Fontana's spaces. In some cases, where the latter are quite full of pigment, there is hardly a trace left in the posterior chamber beyond a few granules in or on the epithelial cells lining the hollows between the ciliary processes at the bottom of the chamber. Generally, however, there are traces of pigment here and there on the posterior surface of the iris, clear up to the pupillary margin, and often quite a layer of free pigment apparently caked at the bottom of the chamber, with more or less pigmented leucocytes, according to the extent of the reaction which had followed the operation. When quite a clump of these leucocytes occurs at the bottom of the posterior chamber some of them are often found penetrating into the iris root, not, however, in the direction of the angle of the anterior chamber but passing farther back toward the ciliary body. A thin layer of free pigment commonly seems to be taken into the surface of the epithelial cells at the bottom of the posterior chamber, but I have never seen the slightest tendency for it to pass deeper into the iris either at the root or elsewhere on its posterior surface. Ulrich, in his last paper,[1] while admitting that the iris root fills up with pigment equally as well when the latter is put into the anterior chamber as when it is put into the vitreous, still insists that, in the latter case, the pigment found in the iris root and anterior chamber must, in part at least, have passed through the iris from behind. He is convinced of this for the following reasons (*loc. cit.*, p. 297):

"First, it is difficult to understand why the iris is not just as permeable for such suspension fluids from behind as from

---

[1] *Archiv f. Augenheilk.*, xx. In this paper, my first article is referred to as if it were simply a repetition of Ulrich's previous work. One can best decide as to the accuracy of this judgment by reading the few lines of Ulrich's which I there quoted. They contain all that he had then written on the posterior lymph-channels, and he published nothing more on the subject for several years thereafter.

before, especially as it is beyond all doubt that the stream of the aqueous, so far as it can be determined by diffusible coloring matters, passes through the iris from behind; and this stream seems well calculated, when strengthened by the reaction following an operation, to carry pigment particles with it. Second in the majority of experiments the amount of pigment found upon the posterior surface of the iris was in a remarkable disproportion to that in the anterior chamber and the iris root. This disproportion was especially noticeable in the right eye of experiment xi. Macroscopically the posterior surface of the iris appeared entirely free from pigment, while the bridge of pigment running squarely through the iris root was, in cross-section, plainly visible to the naked eye. In experiment ix. the disproportion was of a qualitative nature. While the pigment adhering to the posterior surface of the iris was in general enclosed in cells, the anterior surface was fairly black with free pigment. The pigment in Fontana's spaces was also free. Finally I must refer again to the conditions observed in experiment xv. [In all of these experiments referred to india-ink had been injected into the vitreous.] Only at one point of the circumlental space had the pigment penetrated as far forward as the root of the iris, and only at a corresponding point was any pigment found in the iris root or in Fontana's spaces. This must appear incomprehensible if we admit that the pigment had passed into the anterior chamber through the pupil, to say nothing of the fact that the posterior surface of the iris was free from pigment."

It will be observed that the first of the foregoing reasons takes for granted that the posterior surface of the iris is just as permeable as the anterior, and then begs the question as to the reliability of the results obtained by the ferro-cyanide and fluorescein methods. Now, it is perfectly certain that the anterior surface of the iris is much more permeable for solid particles than the posterior; this is evident from the microscopical character of these surfaces and from the fact that as I have mentioned previously free pigment never passes more deeply, if at all, into the posterior surface of the iris than the most superficial portions of the epithelial

cells, while on the anterior surface, and particularly from Fontana's spaces, it passes much deeper. The disproportion between the different amounts of pigment found upon the posterior and anterior surfaces of the iris, which Ulrich regards as striking enough to constitute his second reason, is easily explained by what has just been stated regarding the permeability of these surfaces. The pigment on its way to the pupil passes over the posterior surface, but this is so comparatively smooth that it is not taken up here in anything like the quantity that it is by the crypts of the anterior surface and the meshes communicating with Fontana's spaces. In Ulrich's experiment xi., where he found the posterior surface of the iris macroscopically free from pigment, the microscope showed that it really was not free. Finally, the fact that Ulrich, in experiment xv., found pigment penetrating from the vitreous to the posterior chamber only at one point and found it in the anterior chamber and iris-root only at a corresponding point, would be more striking if he had assured us that this point was not the lowest point of the eye. After injections of pigment into the vitreous, as I have shortly before mentioned, I have always found more pigment at the lowest part of vitreous, posterior and anterior chambers than elsewhere, and several times I have found it only at this lowest part. This is, of course, simply the result of the force of gravity and until assured that in Ulrich's case a similar simple explanation is not sufficient, one cannot be expected to consider the case of especial significance.

IV.

INTRODUCTION OF PIGMENT INTO THE POSTERIOR CHAMBER.

Although I had made experiments of this kind in 1885, the first published results were those of Ulrich. My results differ in no important particular from those obtained by him. In five albino rabbits I made an incision through the ciliary body into the posterior chamber with a narrow cata-

ract knife; through this incision one or two drops of the india-ink suspension were injected into the lower part of the posterior chamber, where it could be plainly seen through the translucent iris. In some experiments, even before the injection was completed, a black line of pigment could be seen passing over the edge of the pupil into the anterior chamber. In others, especially where eserine had been used before the operation, no pigment was seen in the anterior chamber for a short time after the operation, but it always appeared there within a few hours, and in the course of twenty-four hours no pigment, or only a small clump, could be seen with the naked eye in the posterior chamber. The microscopical examination of five of the eyes thus treated showed that most of the pigment which did not pass forward through the pupil within a short time after the operation was taken up by leucocytes. How large a proportion of these latter pass through the pupil it is difficult to say. Some were always found both before and behind the iris, the greatest number always being clumped together in the lower part of the posterior chamber. Here they sometimes remain for several days at least, and perhaps would remain very much longer, or even indefinitely, if the animal were allowed to live. As has already been mentioned in connection with injections into the vitreous, leucocytes containing pigment sometimes pass from this collection at the inferior cul-de-sac of the posterior chamber into the iris root. They also, I think, pass occasionally in the opposite direction through the zonula into the vitreous, but if they do this at all it is to a very limited extent. In the eyes examined I have always found an occasional isolated pigment-holding leucocyte both in the zonula and in the anterior portion of the vitreous, but as in making the incision for the introduction of the pigment it is difficult to avoid opening the vitreous chamber slightly, I have not felt certain whether these leucocytes came from the posterior chamber or from the path of the incision. Aside from this possibility that a few leucocytes may pass through the zonula in a posterior direction, there is no evidence of any flow from the posterior chamber to the vitreous.

V.

INTRODUCTION OF PIGMENT INTO THE ANTERIOR CHAMBER.

In these experiments (to the number of twenty-five) cinnabar was used three times, while in the others an india-ink suspension was injected, generally through the ciliary incision as previously described under "Methods." The results have been partly described in another paper. In certain particulars they agreed with those obtained by all the other investigators who have made similar experiments. These particulars were: (1) the enclosure of more or less of the pigment in a fibrinous clot (into which leucocytes wander and take up much of the pigment) according as more or less of the aqueous is allowed to escape at the operation[1]; (2) the lodgment of considerable quantities of free pigment in the depressions and superficial layers of the iris, whence leucocytes carry it into the deeper layers also; (3) the accumulation of the main bulk of the pigment, whether free or enclosed in cells, in Fontana's spaces; (4) its passage from these spaces into the iris root, inner layers of the sclera, and the ciliary processes. From this point, the testimony diverges. Calberla[2] and Heisrath[3] claim to have found free pigment in the blood-vessels in the neighborhood of the chamber angle. Brugsch,[4] although he found pigment some distance back in the choroid, concluded that there were no open channels leading from the chamber angle; while Morf[5] describes a system of very large lymphatics permeating the sclero-corneal junction and communicating with the anterior chamber.

---

[1] One can observe the course of pigment in the anterior chamber, with this clot and nearly all the leucocytes eliminated from the experiment, by injecting the pigment into the vitreous and allowing the animal to live for several weeks. The pigment, in such cases, is generally carried forward in small quantities to the anterior chamber; no clot forms there; few or no leucocytes are found in the chamber and no more in the adjacent tissues than are probably normal. Otherwise the final results do not differ essentially from those obtained by bringing the pigment directly into the anterior chamber.

[2] CALBERLA. *Nagel's Jahresbericht*, v.

[3] HEISRATH. *A. f. O.*, xxvi., 1.

[4] BRUGSCH. *A. f. O.*, xxiii., 3.

[5] MORF. *Inaug. Diss.*, Zürich, 1887.

My own conclusions as to the outlets from Fontana's spaces are as follows: Free pigment passes readily into the blood-vessels of the sclero-corneal junction, and from these into the vessels of the choroid and subconjunctival tissue. I have become convinced of this fact almost against my will. From my early experiments on the subject, I was led to believe that while there was a tolerably free outlet through the perivascular lymph-spaces, no pigment penetrated into the blood-vessels proper. Under the influence of this belief I misinterpreted the results of many later experiments. After injections of pigment into the anterior chamber, when the animal has been allowed to live several days, one always finds pigment, not contained in leucocytes, in the tissues surrounding the blood-vessels of the sclero-corneal junction. The pigment which I have found inside the blood-vessels has mostly been deposited on the surface or in the substance of the endothelial cells. Now it is extremely difficult, unless one happens to make a lucky section, to decide with absolute certainty whether a layer of pigment is just within or just outside the thin wall of one of these vessels; so difficult that, seeing that some of the pigment was apparently outside of the vessel wall, I concluded, after much uncertainty, that it all was outside and maintained this belief until a repetition of Heisrath's experiments showed me that the blood-vessels could be injected from the anterior chamber with pigment suspensions under low pressure; and that pigment, which a series of sections showed me to be unquestionably in the lumen of the blood-vessel, looked precisely as it had done in my experiments on living animals, where the pigment had been left to the natural currents. The quantity of pigment found inside the vessels diminishes rather rapidly as the distance from Fontana's spaces increases. I have found small quantities in the walls of the choroidal vessels, just back of the ciliary body and in the subconjunctival vessels for a few *mm* back of the limbus, but not with any certainty farther back; it is possible, however, that some of the pigment which I have found in the perivascular spaces of the venæ vorticosæ and of choroidal vessels as far back as the equator may have come from

within these vessels. Regarding the histology of the communication between the anterior chamber and the blood-vessels, in many sections one sees an apparently solid column of pigment and pigmented leucocytes continuing from Fontana's spaces directly into a blood-vessel, without the slightest sign of an interruption, as if the entire lumen of the blood-vessel were an opening in the wall of these spaces. In other sections vessels are seen running somewhat parallel to these spaces, sending off short diverticula, which communicate with them. Whether or not there are valves to prevent a reflux from the blood-vessels into the chamber I cannot say. Theoretically they are not necessary, as, under normal conditions, the pressure in the chamber is always much higher than that in the veins. The presence of the pigment within the blood-vessels is best demonstrated by injecting into the anterior chamber, through the ciliary incision already described, enough india-ink suspension to fill it one half or three fourths full, the animal being killed twenty-four to forty-eight hours thereafter. The longer the animal is allowed to live the greater the amount of pigment found apparently in the perivascular tissues, and how much of this gets there by passing from Fontana's spaces directly into the perivascular spaces, and how much of it first passes into the blood-vessels and thence penetrates the walls of these into the surrounding tissues, it is difficult to determine.

Since examining some very thin sections from animals recently experimented on, I have come to realize that much if not all of the pigment which I had considered to be outside the blood-vessels is really contained in the very fine prolongations which these vessels of the sclero-corneal junction send off, and which Preiss has described as connecting directly with the lymph-spaces of the cornea. But as I know of no way to distinguish positively between lymph and blood capillaries in an ordinary section, unless the latter happen to contain red blood corpuscles, I prefer to leave the question open.

Beside passing into the blood-vessels, the pigment passes from Fontana's spaces into the lymph-spaces of the iris-root, the ciliary processes, the choroid, the sclera, and the inner-

most layers of the cornea, in the neighborhood of the chamber angle. In passing to the choroid and perichoroidal space the pigment is found in some cases, but not all, to pass on both sides of the ciliary muscle, leaving the main body of the latter free. In the choroid and perichoroidal space I have found pigment, apparently free as well as in cells, as far back as the equator of the eye. The distance to which it penetrates backward varies according to the amount and kind of pigment used and the length of time that the animal is allowed to live after the operation. In some experiments, where cinnabar was used, it did not penetrate as far back even as the beginning of the choroid; this coincides with the results of Morf (who used cinnabar and found it in the choroid in none of his experiments) and is probably accounted for by the greater weight of the particles of cinnabar. There is no accumulation of pigment in the perichoroidal space proper, but its outer wall and the layers of sclera immediately adjoining are often well filled with pigment, at least as far back as the venæ vorticosæ. Along the walls of these veins the pigment passes to the space of Tenon, into which I have not been able to trace it farther than about a millimetre outside of the sclera. As a rule, not more than the inner quarter of the sclera contains pigment (except along vessels), but occasionally it occurs throughout its entire thickness, in the region corresponding to the ciliary processes.

Regarding the passage of pigment into the cornea, I have been unable to understand why other investigators have overlooked it. It is true that no passage into it occurs through the membrane of Descemet, but from Fontana's spaces I have invariably found pigment penetrating for a short distance into the inner layers of the cornea, often only in a single fine line immediately anterior to Descemet's membrane. Pigment is always found in the epithelial cells of Descemet's membrane, located principally in the periphery of each cell. So marked is this arrangement at the periphery of the cells that the appearance with a low magnifying power is as if the pigment were taken up entirely by the interepithelial cement, and Morf actually describes the

pigment as occurring in the lines of this cement. A close examination, however, has always shown me the pigment within the cell protoplasm and the cement lines free or nearly so. In no case has the slightest indication of a passage through the membrane of Descemet been observed. In the iris the pigment, in the deeper layers, mostly appears to be enclosed in leucocytes, and at the iris root these pigment-holding cells sometimes penetrate clear through into the posterior chamber.

VI.

INTRODUCTION OF ANTHRAX BACILLI INTO THE ANTERIOR CHAMBER.

I have made four experiments of this kind, with results as follows: When a few drops of an aqueous suspension of anthrax spores are injected into the anterior chamber of a rabbit, an abundant growth of the bacillus can generally be seen with the naked eye in the course of 24 hours, and at the end of 48–60 hours, the animal is found dead. In some animals, particularly young ones (several animals were inoculated without my examining the eyes microscopically), a rupture of the corneal limbus below is observed. A microscopic examination shows more or less bacilli in all the blood-vessels, as is usual in cases of general anthrax infection. Besides this, the periphery of the anterior chamber and Fontana's spaces are filled with bacilli. Leaving these spaces, they pass back into the ciliary processes (in the loose connective tissues of which they are found in great numbers), and into the perichoroidal space, in which I have not found them farther than about 1 *mm* back of the beginning of the choroid proper. They also pass for a short distance into the cornea, directly in front of the membrane of Descemet. Regarding their passage into the blood-vessels of the sclero-corneal junction and into the lymph-spaces around these vessels, my first three experiments, made while under the misapprehension that there was no direct connection between Fontana's spaces and the blood-vessels, led me to believe

that the bacilli passed only into the perivascular lymph-spaces; but my last experiment, from which I was able to get much thinner sections, plainly showed the bacilli passing in multitudes from Fontana's spaces directly into the blood-vessels. In most points the anthrax experiments form simply a confirmation of the results obtained with india-ink; but with regard to the iris and choroid there is a marked contrast between the two. In the anthrax experiments the tissues of the iris are found entirely free from bacilli, except those contained within the blood-vessels; in the choroid also there are few or no bacilli, except within the blood-vessels, while the perichoroidal space contains many.

These experiments show conclusively, I think, the untenability of Leber's belief that no open channels exist for the outlet of the aqueous. The results of Heisrath would seem to be sufficient proof of the free communication between the anterior chamber and the blood-vessels of the sclero-corneal junction. His experiments, however, consisted mainly in post-mortem injections, and though he also mentions having found pigment in the blood-vessels, after the injection of small quantities into the anterior chamber of the living animal, he devotes but a few lines to this, which seems to me the most important part of his results. I therefore wish to lay particular stress on the fact that, in the living animal, pigment passes readily from the anterior chamber into the blood-vessels of the sclero-corneal junction, thus demonstrating an outlet for the aqueous, beside which others must be of comparative insignificance.[1] The regular pas-

[1] Since the body of this paper was written the paper of Staderini (*loc. cit.*) has appeared, in which the passage of pigment from the anterior chamber into the circumcorneal blood-vessels is again denied. I have therefore gone over my old preparations again and have made new ones from fresh experiments, and can only say that these last sections show the pigment passing from Fontana's spaces into the blood-vessels so plainly that it must be evident to any one with normal vision. Staderini admits finding pigment in the endothelium of the vessels, and that is exactly where one would expect to find it if it had entered the vessels. Unless large quantities of pigment are introduced into the chamber, and kept in, one cannot expect to find it free in the lumen of the vessels, for the current tends to keep that clear; but when the chamber is

sage of pigment to the choroid and perichoroidal space, especially where anthrax bacilli follow the same courses, shows that here, too, are outlets which must carry off a certain small amount of the aqueous. To be sure, the evidence for any decided current in these lymph-channels is very slight. Much of the pigment found in them appears to be free, and the bacilli certainly are so. But, aside from the difficulties in judging between free pigment and that contained in the fine prolongations of cells, the fact is that, as I have mentioned in connection with the posterior part of the eye, in these fine lymph-channels apparently free pigment seems to pass indifferently, in opposite directions. This is probably because, there being no decided current, the fine pigment particles are, by the movements of the eye, gradually disseminated more or less uniformly through the entire network. Nevertheless, there must, on the whole, be some current, however slight, away from the anterior chamber, since the pressure in the subconjunctival tissue is less than that in the chamber, as must also be that in the perichoroidal space, on account of the intervention of the elastic choroid between this space and the vitreous.

In the foregoing I have made no special reference to the canal of Schlemm, for the reason that I consider it fully proven that this canal is only part of the circumcorneal plexus of veins. In the rabbit no part of this plexus is sufficiently separated from the rest to deserve a special name; but by chloroforming one of these animals with the head hanging down, as recommended by Heisrath, and keeping the eye under alcohol for about ten minutes after death, before enucleating, every part of this plexus which could by courtesy be called Schlemm's canal, can be found filled with red blood corpuscles. But while these vessels plainly connect freely with the venous system, it is probable, as Schwalbe

filled with pigment by the method described above, nearly every section shows pigment, free and in leucocytes, in the lumen of the vessels. A single specimen is more convincing than many words, and I shall be glad to send a specimen illustrating this point to any one taking enough interest in the matter to write me about it. Also specimens demonstrating the passage of pigment from the perichoroidal space out along the venæ vorticosæ (around which it has been denied by several writers that any lymph-spaces exist) can be had on demand.

suggests, that in life they contain but little blood, on account of the pressure from the anterior chamber. As a matter of fact, they sometimes are found to contain little or no blood while the neighboring vessels of the limbus are gorged; and their irregular shapes and fine prolongations (especially well shown after leaving pigment in the chamber 24 hours) make it perhaps questionable whether they should be placed in exactly the same category as ordinary veins.

Post-Mortem Injections into the Anterior Chamber.

The injection of india-ink suspension (two experiments) and of asphalt chloroform (two experiments), under the low pressure of 25 to 30 *mm* of mercury, into the anterior chamber of dead rabbits, and one injection of alkanet of turpentine into a dead sheep's eye, confirmed conclusively the results of Schwalbe and of Heisrath, as opposed to Leber, regarding the direct connection between the anterior chamber and the blood-vessels at its periphery. At the same time, they confirm the conclusion at which I had arrived by experiments on the living animal, as to the connection between the anterior chamber and the perichoroidal space, on the one hand, and the corneal lymph-spaces, on the other. From some cause, the injection of the blood-vessels from the chamber does not always succeed, even when very high pressure is used. My first few attempts led to such entirely negative results that I was tempted to conclude that no direct connection existed. With Berlin blue, but one successful injection was made, and that in the eye of a fowl, where, according to Heisrath, the connection seems to be freer than in quadrupeds. But on perfecting my apparatus for regulating the pressure (I have succeeded better with a low than with a high pressure), and on using alkanet of turpentine, asphalt chloroform and india-ink suspensions, such successful injections and constant results were obtained that, as they simply confirmed the results already obtained in the living animal, I contented myself with the few successful experiments just mentioned.

Why other observers have not noticed the connection of the chamber with the lymph-spaces of the cornea and the

choroid it is difficult to say. Heisrath, in the figure accompanying his article, depicts with perfect clearness the passage of Berlin blue into the cornea, just anterior to Descemet's membrane, but makes no mention of it in the text. Both Schwalbe and Heisrath have observed a continuation of the injection mass into the iris root and back toward the ciliary processes, and the former was inclined to consider this one of the inlets to the chamber.[1] I have found this line of the injection mass continued back several millimetres into the perichoroidal space. To observe this continuation, however, one should examine a number of successive sections, as one sometimes meets with several in which it does not appear. The channels here are evidently extremely fine; they have never been injected from behind and as in the case of the blood-vessels, in injecting them from the anterior chamber, I have succeeded better with a low than with a high pressure.

Experiments to Determine the Presence of Lymph-Streams in the Cornea.

Pflüger's (*loc. cit.*) results, obtained by dropping a solution of fluorescein into the conjunctival sac, strongly indicated the existence of quite a decided stream from the periphery toward the centre of the cornea, the same gradually passing inward to the anterior chamber. Ehrenthal was unable to confirm these results and with the latter my work leads me to agree entirely.

I.

EFFECTS OF FLUORESCEIN ON SLIGHT LESIONS OF THE CORNEAL SURFACE.

After anæsthetizing the cornea of a rabbit with a weak cocaine solution, slight cuts were made in various parts of the corneal surface and a 2½ % solution of uranin dropped freely upon them. In all cases, each cut was soon surrounded with a fluorescent border, densest in the immediate vicinity

[1] SCHWALBE. *Schutze's Arch. f. Mikr. Anat.*, vi., p. 316.

of the cut, and fading off gradually in the surrounding tissue; but instead of the fluorescence extending farthest from the cut on the side toward the centre of the cornea, as one would expect from Pflüger's article, the coloration extended with uniform rapidity in all directions, if care had been taken to make the cut perpendicular to the surface of the cornea. If it were made obliquely into the corneal tissue, there was sometimes a slight difference in the fluorescence on the two sides, the broader margin being on the side toward which the bottom of the cut inclined. From a cut made half-way between the centre and the periphery, the fluorescence spread with equal rapidity toward the periphery and toward the centre. From a cut at the summit of the cornea, the fluorescence progressed at apparently the same rate toward the periphery, as it did in the reverse direction from a peripheral cut. From a defect of the conjunctiva near the cornea, instead of seeing a corresponding corneal sector become fluorescent, as described by Pflüger, I could only observe the fluorescence spread out into the cornea in a semicircular or semielliptical form, according as the defect was short or long; differing in no way from the form of the fluorescent border of a corneal defect, taken at the same distance from the starting-point of the fluorescence. The different appearance given by the conjunctival defect is due to the white background of the sclera, which prevents our seeing plainly this starting-point. I have repeated these experiments on different animals a number of times, always with the same negative results.

II.

INTRODUCTION OF PIGMENT INTO THE CORNEA.

Morf (*loc. cit.*), as the result of a single experiment, in which pigment granules passed from the anterior chamber, along an anterior synechia, into the cornea and thence toward the periphery, concludes that there is a corneal lymph-stream passing from the centre toward the periphery. To test this point, india-ink suspension was injected into the left cornea of a rabbit at four points about equidistant

from each other and about half-way between the centre and the periphery. A hypodermic syringe was used and the ink passed hardly at all beyond the walls of the canal made by the needle, but enough remained behind to make a well-marked longish black spot at each point of injection. In the right eye of the same animal the cornea was pierced, and, with the needle of the syringe, the membrane of Descemet was scraped away at several points about half-way between the corneal centre and the periphery. A few drops of india-ink suspension were then injected into the anterior chamber. No considerable reaction followed. After about six weeks, the animal was killed and the cornea examined microscopically. Each quadrant was cut into sections corresponding as nearly as possible to radial lines from the centre to the periphery. In the left eye the pigment was found to have penetrated a short distance in all directions from the injection wounds, much of it apparently free, the rest in leucocytes and corneal cells. In some sections the pigment appeared to have penetrated considerably farther toward the centre than toward the periphery, while in others, the reverse was seen. On the average, however, there had been no noticeable difference between the progress made in the two directions. In the right eye, practically the same conditions were observed. Where the membrane of Descemet had been scraped off, the pigment had penetrated from the anterior chamber for a short distance into the cornea, but no positive difference could be observed between the extent to which it had extended toward the periphery and toward the centre.

These experiments indicate that if there be any lymph-stream in the cornea it is not of sufficient strength to influence perceptibly the movement of pigment particles nor the spread of fluorescein through its substance.

Summary.

(1) The ferro-cyanide and fluorescein methods are not calculated to give trustworthy results in determining the physiological currents of the eye. Many of the blue lines, obtained by the former method, represent simply the boun-

daries between tissue into which the ferro-cyanide has diffused and that containing none. The lines upon which most stress has been laid can be obtained perfectly well in the dead eye. (2) The view of Stilling that there is no outlet from the vitreous forward around the lens is incorrect. The zonula is freely permeable for solid particles, free pigment being carried regularly from the vitreous into the anterior chamber. The failure of the attempts to inject the anterior chamber from the vitreous is probably due to the closure of the chamber angle from the increased vitreous tension. It is probable that the fluid secreted by the ciliary processes, posterior to the zonula, divides into two portions, one part passing forward into the posterior chamber and thence through the pupil into the anterior chamber; the other passing back through the vitreous and out through the central canal of the opticus into the tissues of the orbit. (3) There is no evidence of any current passing from the posterior chamber through the iris root. Pigment-bearing leucocytes may pass into the latter from either posterior or anterior chambers, much more readily, however, from the latter, from which they sometimes pass clear through the iris into the posterior chamber. The blue line in the iris root obtained by the ferro-cyanide method can be obtained perfectly well in the dead eye. (4) There is no evidence of any current from the anterior chamber through the membrane of Descemet into the cornea. Pigment particles from the aqueous are taken up by the protoplasm of Descemet's epithelial cells; not so much by the cement-substance between them. Experiments on both dead and living animals show a free connection for non-diffusible substances between Fontana's spaces and the circumcorneal veins. It is therefore probable that the greater part of the aqueous leaves the eye in this way. Other finer lymph-channels lead from Fontana's spaces into the posterior layers of the cornea, into the perivascular spaces of the sclero-corneal junction (possibly), into the sclera, choroid, and peri-choroidal space. Wherever these channels communicate with spaces in which there is a lower pressure than that within the anterior chamber they must, on the whole, serve to some extent as outlets. This

L
a.c.
c.m.
c.h.
v.v.

also applies to the perichoroidal space, which, beside being connected with the intervaginal space, communicates with the space of Tenon by numerous lymph-channels surrounding the vessels and nerves which pierce the sclera. The rare cases in which Deutschmann and myself have observed a passage from the intervaginal to the perichoroidal space were probably due to exceptional causes. If there is any regular current here it is more probably from the perichoroidal to the intervaginal space. In these finer channels apparently free pigment seems to pass indifferently in any direction. (5) Between the retinal pigment-epithelium and the layer of rods and cones is a tolerably well defined space, from which pigment passes freely into the retina, but hardly or not at all into the choroid proper except along occasional penetrating blood-vessels in the neighborhood of the optic nerve. (6) While certain facts, such as the regular passage of pigment and bacilli from Fontana's spaces into the cornea and the progress of subconjunctival hemorrhages in the same direction, together with the impermeability of Descemet's membrane from behind, speak for the nourishment of the cornea from its periphery, the corneal lymph-stream, if any exists, is too weak to perceptibly affect the diffusion of fluorescein or the progress of pigment particles through its tissues.

Explanation of the Accompanying Plate.

The figure is drawn from an albino rabbit's eye, into the anterior chamber of which india-ink suspension had been introduced and left for a month before death. The drawing is a composite from two different sections, as I had not the good luck to find the passage of pigment into a blood-vessel of the sclero-corneal junction and along a vorticose vein as well, clearly shown in any one section. It should be remembered that in the rabbit the ciliary processes send prolongations far into the posterior chamber.

l. = Lens.
a. c. = Angle of anterior chamber.
c. m. = Ciliary muscle fibres.
ch. = Choroid.
v. v. = Vorticose vein.

BINOCULAR METAMORPHOPSIA PRODUCED BY CORRECTING GLASSES.

By HARRY FRIEDENWALD, A.B., M.D., Baltimore.

TWO years ago an interesting article by Dr. J. A. Lippincott appeared in these ARCHIVES,[1] under the above title. It described those peculiar disturbances of vision, such as a distortion of the sides of rectangular surfaces, etc., which patients sometimes complain of when they are provided with certain correcting glasses for *both eyes*, through which the vision of *each eye looking separately* is normal. The description of the phenomena, as produced by different glasses under varying conditions, is exceedingly careful; there is little that need be added. The manner in which he explains the phenomena is unsatisfactory. The proper explanation has been suggested by Dr. John Green.[2]

This subject has received little attention. The best works on refraction[3] do not mention it. Beside the articles cited above, there are only one by Culbertson[4] and several by Savage[5] bearing upon it. Both of these writers agree upon a rotation of the eyeball upon its antero-posterior axis as the cause of the phenomena, and Savage develops theories of an "harmonious non-symmetrical action," and recently of an "harmonious symmetrical action of the oblique muscles." These explanations are false in theory and dangerous in practice. In theory they have led Savage to accept unwar-

[1] Vol. xviii., No. 1, p. 18.
[2] *Transactions Amer. Ophth. Society for 1889.*
[3] Donders, Mauthner, Landolt.
[4] *Am. Jour. of Ophth.*, May, 1888.
[5] *Journ. of the Am. Med. Assoc.*, November 5, 1887. *Am. Journ. of Ophth.*, September, 1888, p. 245. *Ophth Record*, vol. i., No. 1, p. 1.

ranted strains and insufficiencies of the oblique muscles; in practice he, as well as Culbertson, recommends altering the position of the axes of the cylindrical glasses, as found on careful examination of each eye separately to correspond with the supposed rotation of the eyeball.

In studying the phenomena, we find that they are also observed by emmetropic eyes when looking through certain glasses. They can therefore be repeated easily and verified.

The numerous appearances may be reduced to a few elementary forms, which we shall formulate below. They may be demonstrated by allowing the emmetropic observer to look at a square surface[1] held vertically before the eyes. Placing a convex cylindrical glass before the right eye, we find that the square surface appears as a trapezoid,

a. with axis at 45° t, the lower side seems lengthened, the right side inclined.
b. " " " 45° n, the upper side seems lengthened, the right side inclined.
c. " " " 0° v, the right side seems lengthened, the upper and lower sides inclined.
d. " " " 90° h, the right side seems shortened, the upper and lower sides inclined.

Placing the glass in symmetrical positions before the left eye reverses these figures. On substituting a concave for the convex cylindrical glass, we find that the same sides are affected as above, but those that seemed lengthened before appear shortened now, and *vice versa*. Thus, with a concave cylindrical glass placed before the right eye,

e. at 45° t, the lower side seems shortened, the right inclined.
f. " 45° n, " upper " " " " " "
g. " 0° v, " right " " " the upper and lower sides inclined.
h. " 90° h, the right side seems slightly lengthened, the upper and lower sides inclined.[2]

---

[1] In demonstrating this to the Med. and Surg. Society of Baltimore, a card 12 *cm* square was used. Other objects are equally good. In general, a cylindrical glass of 2 D is found most useful.

[2] In these statements the effect mentioned is the most prominent. A slight change of a contrary character in the opposite side is frequently noticed; for example, in c. it is evident that while the prominent change is a lengthening of the right side, there is also slight narrowing of the left side.

When glasses of equal strength are placed in symmetrical positions before both eyes (as, for example, 45° t for each eye) their effect is very much increased. If the axes, on the other hand, point in the same direction (whether horizontal, vertical, or in any other position), the effect of both glasses will be the same as of each one singly, namely, of causing lines of dispersion only, and if the axes are oblique, slight slanting of the object looked at.

A peculiarity of utmost importance, but which Lippincott does not mention, is that the side which appears lengthened seems to be more distant and the side that appears shortened to be nearer, though we may convince ourselves that the plane of the surface is perpendicular to our visual axis. This fact proves that the change depends upon stereoscopic illusion.

Before going farther, it is necessary to mention the effect of cylindrical glasses upon the retinal images. This has been worked out in detail by Lippincott.[1] It is shown that cylindrical glasses with oblique axes cause slight obliquity of the retinal images, the obliquity approaching the direction of the axis when concave cylindrical glasses are used, and receding from it with convex cylindrical glasses. This obliquity affects all lines that do not run parallel to the axis of the cylindrical glass or perpendicular to it. If, then, the figure looked at be a square held vertical with upper and lower edges horizontal, the retinal image will appear slightly tilted to one side or the other, accordingly as convex or concave cylindrical glasses are used at oblique axes.[2] Besides the image is more or less indistinct, on account of dispersion. On the other hand, it is evident if the same object be looked at through a cylindrical glass with axis vertical or horizontal, that though the direction of the sides (and all lines parallel to these) will remain unaltered, the effect will be an

[1] *Loc. cit.*

[2] The obliquity and slight incongruity of the retinal images has induced Dr. Savage to construct his hypothesis of a necessary rotation of the eyeball, for he says "there must be double vision, unless the oblique image in the (one) eye and the horizontal image in the (other) eye can be made to occupy corresponding parts of the two retinæ. This can be effected alone by the *harmonious symmetrical action of the oblique muscles.*" (*Ophthalmic Record*, vol. i., No. 1, p. 11.) This is an error. Double vision is not the result, but the images are fused into one.

obliquity of all other lines upon its surface, especially of the diagonals, and the resulting figure will be a rectangle.

The binocular fusion of such an altered image with one that is unchanged, or changed in a different manner causes *stereoscopic appearances of solidity and depth.* In consequence of this there is also a change in the apparent length of lines, for these vary according as we project them nearer or further from us. The lines of dispersion clear up to some extent, and a more definite mental picture is produced.

Now, if images which are slightly dissimilar can be fused into a single mental picture, it remains to be inquired whether the slightly dissimilar images produced upon the retinæ of emmetropic eyes by a cylindrical glass fall under this head. Place such pictures in a stereoscope, and the mental impression will be found to be identically the same as that produced by the cylindrical glass placed before the eye. For example, place before both eyes + 2 D, cyl. Ax. 45° t. The resulting retinal images of the square card are parallelograms. Insert two similar parallelograms in the stereoscope. In both ways you receive the impression of the same form of trapezoid, narrow at the top, and which is apparently *leaning forward* so that the top seems to be much nearer the eye than the base. *This proves that they are fused in the same manner; the appearance of depth points conclusively to the fusion of dissimilar images.* The experiments can be repeated for all the figures, whether produced by cylindrical glasses with oblique or with vertical or horizontal axes.[1] This suffices to explain the effect of cylindrical glasses on emmetropic eyes.

What is the effect on astigmatic eyes? Practically the same. Astigmatic persons have retinal images distorted to conform to their astigmatism and its axis, just as the emmetropic have when provided with cylindrical glasses. But having seen in this manner from childhood, they see things as they are and not distorted, for visual judgment is the result of experience. Correct their astigmatism and produce

[1] Cases d and h in the tables may appear anomalous, because the glasses have very different effects, if looked through with but one eye. The difficulty disappears when we remember that the lengthening or shortening depends entirely upon the apparent distances of the parts of the stereoscopic image.

better and more accurate retinal images; yet at the same time you cause a relative displacement to what has previously been the position of retinal images. One of the factors upon which visual judgment relied will then be disturbed and consequently the mental picture will be distorted. This distortion is the same as when cylindrical glasses are placed before the eyes of the emmetrope, as can be readily demonstrated. Let us cite one case. A lady who had suffered considerably from eye-strain and headache was provided with the following glasses, which gave full vision: Both eyes + 1.25 D, cyl. Ax. 75° n. When allowed to use both eyes she had great metamorphopsia; a book which she held in her hand appeared wider at the top, the floor seemed to be going down hill before her, the wall appeared to be inclined backwards. This is the same effect as produced upon a person with normal eyes with the same glasses. Two weeks afterward, having worn them continually, she returned and said that she had had much difficulty in wearing the glasses during the first few days but that she could now see very well with them. On examination it was found that the metamorphopsia had almost disappeared. On taking off the glasses, however, it immediately returned but changed, for now the floor seemed to rise before her, a book or a square appeared narrower at the top, etc.; without her cylindrical glasses she was exactly in the position of an emmetropic person with concave cylinders in the same position as above.

There is still another theoretical aspect of this subject which needs attention. On examining the tables above, it will be found that a cylindrical glass has opposite effects, according as the axis is horizontal or vertical. Lippincott,[1] moreover, has found, and we have verified his statement, that these effects are not equal, but that the *effect is greater when the axis is vertical than when it is horizontal.* Consequently if two equal cylinders are placed upon each other with their axes at 0° v, and at 90° h, respectively, they but partly neutralize each other, *the vertical cylinder having a preponderating influence*, and thus their combined

[1] *Loc. cit.*

action is equal to that of a weaker cylinder with its axis placed vertically. But two equal cylinders placed upon each other with their axes at right angles are optically equal to a spherical glass of the focal power of each cylinder.[1] This gives us the solution of the problem of the very annoying metamorphopsia[2] due to prescribing unequal glasses for anisometropia without astigmatism. If both eyes of an anisometrope are corrected, the optical difference between the glasses causes the same effect as a cylinder with its axis vertical; the square test-card as well as all other objects looked at, appears much wider on one side, and this gives rise to great annoyance. The explanation agrees thoroughly with the facts. As examples take the cases furnished by Lippincott[3]: RE plano, LE + 1 D. The left side appears wider. Or to quote from my records: "RE — 0.75, $S = \frac{20}{xx}$, LE emmetropic, $S = \frac{20}{xx}$. RE reads best with a plano, L E with plus .75; left side appears wider." To quote another case: "RE + .25, $S = \frac{20}{xx}$; LE + 2.5, $S = \frac{20}{xxx}$; RE reads best with + 1.75; LE with + 4 D; left side appears much wider."

Thus we have found that the various forms of metamorphopsia—1st, that due to cylindrical glasses with axes oblique, 2d, that due to cylindrical glasses with axes horizontal or vertical, 3d, that due to a spherical glass (as in anisometropia)—require but one explanation.

It is useless to spend any time in refuting other theories that have been advanced, but it may not be without interest to mention them. The theory of the rotation of the eyeballs has been referred to above. Lippincott[4] thinks there are "reasons for supposing the explanation to be connected in some way with accommodation," though he admits that "in a number of thoroughly atropinized eyes precisely the same results, both in kind and degree, followed the use of cylinders," as in non-atropinized eyes, and he therefore sug-

---

[1] Mauthner, *Optische Fehler des Auges*, p. 717.
[2] Landolt, *Refraction and Accommodation*, Eng. trans., p. 527.
[3] *Loc. cit.*, p. 23.
[4] *Loc. cit.*, p. 26.

gests a change in the "accommodative impulse." The accommodative impulse, he assumes, is affected unequally and varies with the position of the axis. There is nothing to sustain this hypothesis.

The phenomena under discussion are not always described by patients. But it is rare that they do not recognize them when their attention has been directed to them. They frequently complain of the great disturbance of vision, headache, pain in the eyes, and dizziness, even when unable to describe the trouble. The metamorphopsia manifests itself most when patients look at the floor when walking, or when going down a flight of stairs. If the metamorphopsia is such that the square trial-card appears broad at the base, everthing else that is looked at will show the same change. Moreover, that part of every image which lies lowest in the field of vision will appear more distant. The lower part of the wall will appear farther away; the wall will seem to incline forward. That part of the floor nearest the feet, lying lowest in the field of vision, will appear very deep, and therefore the floor will seem to rise before the person. On the other hand, if the metamorphopsia is such that the test-card looks narrower and consequently nearer at the base, then the part of the floor where the person is standing seems to be very high; it will appear as though it could almost be touched with the hands, though standing erect, and the person will feel very short. Metamorphopsia, which will cause one of the sides of trial-card to appear broader or narrower, will give rise to the appearance of slanting from side to side when the floor is the object gazed at. Patients suffering with this form of metamorphopsia, when writing on unruled paper, find that their lines run up or down and are not parallel with the upper border of the sheet. The disturbances wear off in a few days, depending partly upon the strength of the glasses and partly upon the persistence with which they are worn. If they are worn only at times, as when reading, the metamorphopsia will last for a long time. This suggests that such patients be advised to wear their glasses continuously, unless this is otherwise contraindicated.

It is evident from what has been said that binocular metamorphopsia may be produced in other ways[1] than by correcting glasses. As an instance let me cite the following case: A patient who had complete atropine mydriasis of the left eye, but whose eyes were otherwise normal, found that the floor appeared to slope downward toward the right side (the right side of a book looks wider than the left), etc.[2]

In conclusion, it is of interest to point out that the phenomena of binocular metamorphopsia throw some light upon the physiology of vision in ametropic eyes. It is shown by the frequency with which metamorphopsia is met with that most ametropic persons are able to fuse their imperfect retinal images and to form judgments of distance just as emmetropic persons. This implies, in other words, that identical points in the retinæ depend, to a great extent at least, upon experience.

We can also account for the advantage of binocular vision over monocular vision when both eyes are equally deficient, for the fused mental picture of two equally imperfect images is more distinct than either one of its components.

The constancy with which the phenomena of metamorphopsia are met with even in the lower degrees of astigmatism is a strong argument against the theory of irregular ciliary contraction and compensatory accommodation. For if such low degrees were neutralized by accommodative effort, then the phenomena of metamorphopsia would be absent when this correction is substituted by that of glasses. As mentioned above, this does not occur, and I have always been able to evoke the phenomena.

The phenomena of metamorphopsia may be made use of in the examination of binocular vision as already suggested by Lippincott.[3] I have examined several cases of congenital amblyopia of one eye and found that the imperfect eye

---

[1] For a discussion of the effect of prismatic glasses on binocular vision see *Graefe and Saemisch*, vol. vi., p. 366.

[2] The visual discomfort arising from monolateral paralysis or paresis of the accommodation is similarly explained.

[3] "New Tests for Binocular Vision," *New York Med. Jour.*, Sept. 27, 1890.

takes part in the visual act by fusing its image with that of the better eye. In strabismus I have never been able to find metamorphopsia, as would be expected from our knowledge of the binocular vision of squinting eyes.[1]

---

[1] "Recent Investigation in Strabismus," *N. Y. Med. Jour.*, Aug. 16, 1890.

AN IRIS SHIELD—A NEW CATARACT INSTRUMENT.

By CHAS. W. DODD, M.D., Cincinnati, O.,

LECTURER ON OPHTHALMOLOGY IN THE CINCINNATI COLLEGE OF MEDICINE AND SURGERY, FORMERLY ASSISTANT IN THE OPHTHALMOLOGICAL DEPARTMENT OF THE VIENNA GENERAL HOSPITAL.

(*With a wood-cut.*)

IN extraction by the simple operation, capsulotomy, whether performed by means of the Graefe cystotome or with the curved toothed-forceps, always exposes the iris to more or less risk of injury during introduction and withdrawal of the instrument; the sharp point of the cystotome or the projecting teeth of the capsule-forceps easily become entangled in the loose tissue of the iris; or the inner surface of the cornea may suffer abrasion in attempting to avoid the iris. To obviate the above difficulty, the instrument here illustrated and described suggested itself recently to the writer; its simplicity and efficacy are its own endorsement.

It is simply a small, thin plate of silver fastened edgewise to a flexible silver shank; the flexibility of the latter allowing the shield-plate to be placed at will at the most convenient angle with the handle. It is applicable to either eye and for use in right or left hand; when the forceps are used in the right hand, the shield is of course held in the left, or *vice versa*.

The shield-plate is introduced into the corneal wound and covers the adjacent section of iris, its inner edge extending

just to the margin of the pupil. The tip of the forceps or the cystotome is introduced lying upon the upper surface of the shield, and thus is prevented from contact with the iris; slight pressure upon the iris produces a free space between the shield and inner surface of cornea, and thus abrasion of the latter is easily avoided. The shield-plate must be perfectly smooth and only so thick as to give it the necessary strength. The accompanying illustration shows the size of the instrument.

ON VACCINE BLEPHARITIS.

By CHARLES ZIMMERMANN, M.D.,

AURAL AND OPHTHALMIC SURGEON TO ST. MARY'S AND EMERGENCY HOSPITALS, MILWAUKEE, WIS.

ONLY a few cases of vaccine blepharitis (vaccine-ophthalmia, vaccinia of the eyelids, vaccine, vaccinula on the border of the eyelids) with subsequent affections of the eyes are published by Hirschberg,[1, 2] Senat,[3] Hervieux,[4] Berry,[6] Schapringer,[6] J. T. James,[7] Peiper,[8] Schirmer,[9] so that a further contribution will not be superfluous.

H. P., a boy twelve years old, was brought to my office by his father, October 31, 1891, on account of an inflammation of his right eye. The right lower lid showed two ulcerating patches at the ciliary margin, close to the external canthus. Both lids were slightly œdematous. These patches bearing a great resemblance to vaccine pustules in the ulcerating stage, I at once asked the father whether the boy had been recently vaccinated, which, however, had not been the case, and neither of them knew that he had come into contact with anybody who had been vaccinated. I gave him hydrarg. oxydat. flav. ointment, and ordered cold applications. The next day the father came alone, stating that the eye of his son had become very much inflamed, so that he could not see out of it, and that the left eye was commencing to get sore. At his residence I found the following condition: The right upper lid is red, intensely swollen, overhanging the lower one, and cannot be raised voluntarily; it feels hard to the touch, which causes pain. It cannot be everted, but lifted with the finger it shows the conjunctiva infiltrated by a gray membranous exudation, which cannot be wiped away. Thin yellow fluid is discharged. The ocular conjunctiva is in a state of in-

tense chemosis, but not coated. The cornea is perfectly clear. The conjunctiva of the lower lid exhibits the same appearance as the upper one, and the ulcers at the ciliary margin are likewise covered by a grayish-yellow material. The left eye shows slight œdema of lids and some mucous discharge, but is open, although the palpebral fissure has become smaller. The right preauricular and submaxillary glands are considerably swollen and tender. Both tonsils are inflamed and very much enlarged, but without pseudo-membranes. Swallowing is painful, and he has fever and general prostration. Upon renewed inquiry as to the etiology of the two ulcers, I learned that the younger sister of the patient, who was occupying the same bed with him, had been vaccinated in school a few days previously on her left arm, which presented a pretty large ulcer covered by a scab. Both eyes were treated with cold applications day and night (the pieces of linen used for each eye being kept on separate blocks of ice in separate dishes) and irrigated and washed with chlorine water. The swelling disappeared gradually, so that on November 4th a better aspect of the grayish infiltrated conjunctiva could be obtained. The chemosis was still very large, projecting as a thick red wall around the cornea. The latter remained entirely clear. On November 7th he could open the right eye, which was discharging more freely now. The inflammation of the left eye had been arrested from the first day. On November 12th the patient could come to my office, where the conjunctiva was found to be free from membranous deposit, but, being still red and velvety, was treated with a 3 % solution of nitrate of silver. The condition improved steadily, so that on December 16th nothing of the disease was left but a slight redness of the ciliary borders, and a moderate ptosis of the right upper lid, which, however, did not cause any annoyance. No scars and no change in the position of the lids or cilia. Cornea perfectly clear. V = 1.

Although the boy and his parents were not aware of the manner in which the inoculation of the vaccine virus was effected, it was undoubtedly caused by an accidental transmission from the vaccinated arm of his sister. In one of Berry's[5] cases a direct transference of lymph took place, owing to the child's arm being often in contact with its mother's face; in another the handkerchief used for wiping the vaccinated arm was admittedly used by the mother also.

Cook's[11] patient had most likely infected himself, not from the baby directly, but from a towel that had been used in drying it. Darling[10] observed vaccine vesicles on the eyebrow of a farm-servant, who was in the habit of milking cows, and very likely got it from them, although she could not remember if any of the cows had sores on the teats. Senat[3] saw a military surgeon who had a vaccine pustule at the left lower lid, with corneal ulcers, caused by lymph squirting into his eye from the pocks of a young cow, while he was vaccinating soldiers.

To decide the question whether there was any lesion of the ciliary margin or not for the introduction of the virus was not possible in this case, as it will hardly be in others, unless it presented itself very conspicuously. And then it will become rather unimportant, if further experimental investigations will prove that even a general infection from the intact conjunctiva may follow, as Braunschweig[13] found it with Ribbert's bacillus of intestinal diphtheria in the conjunctiva of rabbits. (He was unsuccessful, however, with staphylococcus pyog. aur., anthrax, septicæmia of mice, chicken cholera, and tetragenes.) Most frequently the vaccine vesicle developed on the border of the lower lid, causing a consecutive ulcer on the corresponding portion of the upper lid by direct contact. In our case (and one of Schapringer[6] and Berry), it was confined to the lower lid. The affection of the conjunctiva, starting from the two ulcers, had the aspect of diphtheritic conjunctivitis. Although observed by others and not taken for diphtheritic, our case appears different, on account of the considerable swelling of the preauricular and submaxillary glands and tonsils, the constitutional symptoms, as fever and general prostration, and in the propagation to the second eye. If a so far healthy conjunctiva may become the seat of a diphtheritic inflammation, why should not the same occur in an eye predisposed by ulcers at the ciliary margin, no matter of whatever origin? Plastic inflammation, with an exudation in the substance of the conjunctiva, was present, and this is the chief local symptom in simple plastic, pseudo-diphtheric, croupous, and diphtheritic conjunctivitis, which

are various grades of the same pathological condition, differing from each other only in intensity.

The *diagnosis* is, of course, easiest when the vaccinia is observed in the first stage, exhibiting the typical vesicles pitted in the centre. Most cases, however, presented the ulcerating pustules, as in ours, having such a characteristic appearance that they are readily recognized. In later stages, however, the diagnosis may become very difficult. Syphilitic ulcers, which have a different appearance, cause also such hard infiltration of the lids, but they require a time of incubation not less than at least twelve days,[4] and, as well as a tubercular affection, run quite a different course. As the only complication on the eyeball itself, inflammations of the cornea have been noticed in seven cases of vaccine belpharitis by Hirschberg, Senat, Schapringer, Schirmer. Schirmer[9] once observed a superficial marginal infiltration, twice a very tedious keratitis profunda with peculiar ring formation. Leber[12] mentioned that Critchett saw a purulent affection of the cornea from an injury of the latter by a lymph-lancet. There are some other reports on affections of the eyes in vaccinia, in which the latter were only secondarily suffering from vaccine pustules situated not on the lids themselves, but on neighboring parts, as on the eyebrow and cheek (Darling[10]), on the malar eminence $\frac{1}{3}$ of an inch from the external angle of the eye, with huge œdema of the eyelids completely closing the eye, the glands being very much enlarged and tender (Cook[11]), and an indurated ulcer at the angle of the eye (Hervieux[4]). The preponderance of females and adults, pointed out by Berry and Schapringer, finds, I think, a natural explanation in the fact that these are more exposed to contagion, being chiefly engaged in nursing and handling children, from whom, in most instances, the infection took its origin. Although most cases recovered perfectly, their occurrence might be avoided altogether, if the source of infection, the vaccinated place of the body, were protected by proper dressing, the enforcement of which is the duty of every physician who performs vaccination.

LITERATURE.

1. HIRSCHBERG, these ARCHIVES, 1879, viii., p. 371.

2. HIRSCHBERG, *Centralblatt f. p. Augenh.*, 1885, p. 235, and these ARCHIVES, 1886, xv., p. 115.

HIRSCHBERG, *Centralblatt f. p. Augenh.*, 1892, p. 17.

3. SENAT: "Vesico-pustule de la paupière inférieure gauche et kératite ulcéreuse, suite d'inoculation accidentelle du vaccine."—*Arch. de méd. mil.*, 1885, October. *Centralblatt f. p. Augenh.*, 1886, p. 59, quoted from *Recueil d'ophtalmolgie*, 1886, January.

4. HERVIEUX, Vaccine ulcéreuse (*Bull. de l'acad. de méd.*, 1889, No. 37; *C. Bl. fur klin. Med.*, 1890, No. 12, p. 217).

5. BERRY, *Brit. Med. Jrl.*, 1890, p 1483.

6. SCHAPRINGER, *New Yorker med. Monatsch.*, Nov., 1890 and 1891.

7. JAMES, J. T., *Transact. af the Ophth. Soc.*, 1890–1891, xi., p. 29.

8. PEIPER, *C. B. f. klin. Med.*, 1891, p. 697.

9. SCHIRMER (*Sitz. der oph. Gesellsch. in Heidelberg*, 1891. *C. B. f. pr., Augenh.*, 1892, p. 18, and *Deutsche med. W.*, 1891, p. 1139) observed in all seven cases "diphtheroid" ulcers of the intermarginal portion of the lids, which had developed from small superficial pustules, causing violent inflammatory symptoms, chemosis and œdema of lids. In the discussion Weiss, E. Meyer, Schweigger, Vossius, related similar cases of mild character.

10. DARLING, *Brit. Med. Jrl.*, 1890, p. 1362.

11. COOK, *Brit. Med. Jrl.*, 1891, p. 284.

12. LEBER, the same as 9.

13. BRAUNSCHWEIG, *Fortschr. d. Med.*, vii., p. 921–928; *Centralbl. f. Chir.*, 1890, p. 372.

IDIOPATHIC VITREOUS HEMORRHAGES.

By Dr. JAMES A. SPALDING, Portland, Me.

IDIOPATHIC vitreous hemorrhages are so rare (Nieden saw but six cases in thirty-four thousand patients) that it seems well worth while to bring before the readers of the Archives, after a long silence on this topic in the ophthalmic literature of this country, a report of a few new cases of this unusual affection.

It is of the greatest practical value to the student, as well as to the practitioner of medicine, now and then to reopen old topics like the one at the head of this article, for we thus refresh our memories with the opinions of other observers, we recall our former doubts and fears in regard to the result of apparently so serious a case, and, most interesting of all, we bring back to mind apparently similar cases in which, although the treatment had been eminently successful, we are forced to acknowledge to ourselves that our diagnosis had been entirely at fault.

Whilst vitreous hemorrhages are sometimes perplexing in their diagnosis,[1] especially to those whose practice is not extensive, and often tedious in their recovery, it is nevertheless pleasant on the whole to be able to assure our patients that useful vision will in all probability be regained. And this is all the more agreeable, when both eyes of a busy man are, for instance, so abundantly filled with hemorrhages, that for weeks he is unable to attend to his work, though ultimately he recovers *useful vision* in one if not in both eyes.

[1] I will at once exclude all vitreous opacities of whatever nature occurring in myopic eyes, all hemorrhages of a traumatic origin, and the ordinary run of vitreous opacities in which a vitreous hemorrhage can with all probability be denied.

The chief reason, however, why I have gone to the trouble of looking over my case-books, and consulting all accessible authorities in regard to the causation, prognosis, and treatment of vitreous hemorrhages, is because *one of my cases had for months been treated in vain as a case of double detachment of the retina.*

From the fact of an erroneous judgment in these cases, I think that we can easily see how some of the cases in our journals hailed as cure of retinal detachment after one and another sort of treatment have actually been nothing more nor less than the simple cure of a vitreous hemorrhage.

The chief cause for this error in diagnosis lies, in my opinion, in the fact that if the extravasation is partial or has retrograded at all, we may see through its interstices a greenish reflex, which bears so great a resemblance to a detachment of the retina that, heedless of *the perfect visual field*, a detachment is diagnosticated. As the resorption of the hemorrhage advances, the observer sees this green reflex resolve into green bands either in the retina itself or else in the posterior portion of the vitreous. And even after the cure of the detachment so called, and the restoration of vision, there the bands remain, rising above the level of the retina, but without the overlying retinal vessels. Thus in one of my cases, the margin of the papilla with the refraction ophthalmoscope was *Em*, a portion of the green ridge-like elevation + 2 D, and the summit of the same + 4 D, above the level of the retina. Perhaps this elevation represents a hyperplasia of the retina, or a cicatrix in the retina, similar to that depicted in Jaeger's Atlas (Fig. 84), and in which a *new formation of tissue in the vitreous* was diagnosticated. The exact locality of the elevation can only be defined by the presence or absence of the retinal vessels.

It is still an open question whether the blood in the vitreous escapes from the choroid through the retina, and so into the vitreous, or whether it actually arises from the retina. As I have never seen any traces of a retinal hemorrhage at a time when the vitreous has cleared, I am inclined to think that there can be no question of the hemorrhage

arising exclusively from the choroid, and rather in front toward the ciliary region.

Before reporting a few cases, I may venture to quote, in the briefest possible fashion, a few accessible authorities, and chiefly in so far as their words throw any practical or pathological light on the subject in hand.

Swanzy remarks that vitreous hemorrhages are not uncommon, and are the result of those diseases of the retina and choroid which are accompanied with hemorrhages into those membranes. He gives no especial diagnostic signs or treatment, except in the section on ordinary vitreous opacities; Heurteloup's leech, dry cupping, and pilocarpine hypodermatically are suggested.

Wells gives a satisfactory account of the symptoms and treatment. His prognosis is bad. The hemorrhage is likely to recur and permanent opacities to remain. The retina is almost always detached, and we may later see the cicatrix. Treatment: Heurteloup, attention to the health, saline cathartics, and sometimes a compress bandage.

Schweigger offers a poor prognosis. A few forms of inflammatory origin may recover. Recurrent hemorrhages are fatal to the sight. When the opacity clears off we may discover a retinal hemorrhage, which has possibly excited the hemorrhage into the vitreous. These occur most often in young people. Syphilis and hemorrhoids may be the chief indications in our treatment, which is not encouraging.

DeWecker has often seen hemorrhages from the papilla. Whilst isolated hemorrhages may resorb with astonishing rapidity, recurrent hemorrhages into the vitreous constitute a desperate disease. The younger the patient the more favorable the prognosis. Pilocarpine into the eye and hypodermatically, the constant current, and Heurteloup are highly praised.

Galezowsky has an excellent chapter on this topic. He insists on the impossibility of illuminating the fundus; all light is absorbed by the effused blood; the effusion clears off not by a succession of levels, but by a succession of tints. Sometimes the effusion looks red by oblique illumination. Mauthner opposes this assertion, but Loring agrees with it.

The disease is generally in one eye alone, and is due to rupture of the ciliary vessels. The original cause is to be sought for in the suppression of habitual epistaxis and of the menses, in hemorrhoids, and in constitutional disorders. Detachment of the retina ought never to be confounded with vitreous hemorrhages, for in the former we have loss of a portion of the field, and additionally we can see the retinal vessels coursing over the detached portion of the retina.

The most favorable cases are those in which the effusion lies in the anterior portion of the vitreous, because of the abundant vascularity in that region. The older the patient the slower the recovery. Atropine and eserine alternately, warm fomentations, friction on the temples, cupping, blisters, iodide of potassium, pilocarpine hypodermatically, salines, and even an iridectomy, are suggested in the line of treatment.

It would take too much space to relate all of the cases of vitreous hemorrhage discoverable in modern literature, but I will very briefly cull a few of the most interesting for those who care to study this interesting topic.

Daguenet thinks that the blood in his six cases came from the choroid. Albuminuria, irregular menstruation, and atheroma of the arteries must not be overlooked in the etiology. Relapses are more frequent in the youthful than in the aged. The rupture probably takes place far back in the fundus of the eye, a fact not excluded by the presence of the clot directly behind the lens.

Abadie has frequently seen the vitreous hemorrhage preceded by epistaxis.

Talko examined the eyes of a patient killed by a fall. Blood in the intravaginal spaces of both optic nerves, but the hemorrhage into the left vitreous had no connection with the blood in the spaces. Indirectly, this effusion in the intravaginal spaces had compressed the left optic nerve and its central vein till it burst near the yellow spot and the blood exuded into the vitreous. The pathology in this case may explain that in others of non-traumatic origin.

Nieden and Eales have called attention to recurrent vitreous hemorrhages in young men. They emphasize the sudden

blindness, the lack of evident cause, and the favorable prognosis. The hemorrhage arises in the choroid. One eye only is generally affected in emmetropic patients, vision generally completely restored in time, but usually after one or more relapses. Mercurials and the iodide of potassium are advised.

Mooren attributes some cases to rheumatism, or to sudden cold, owing to which the ciliary vessels are rapidly depleted. The stress of treatment is to be laid on the rheumatic nature of the affection. Mercurial inunctions are highly praised.

Hutchinson thinks that recurrent vitreous hemorrhages are almost invariably seen in young men alone, and in both eyes. Unilateral hemorrhage, on the contrary, is a senile affection, and occurs about equally in both sexes.

Porteret has written concerning nine cases of this disease. The cause was unknown in six. In one it followed eclampsia, and two of the patients were drunkards with atheromatous arteries. Two of the patients recovered, three improved, two remained the same, and two lost their sight entirely. The treatment consisted in the use of the constant current and antisyphilitic measures.

Unterharnscheidt suggests the possibility of an apoplexy between the retina and the vitreous, simulating vitreous hemorrhage, and Badal has shown that *this may occur* without perforation of the hyaloid membrane.

Amongst isolated cases I will venture to quote the following as perhaps throwing light on the etiology of this rare disease:

Jacobson saw periodic hemorrhages with epistaxis.

Cognet observed the same coincidence and additionally convulsions.

Hutchinson saw a patient one of whose eyes had already been destroyed by hemorrhages and apparent glaucoma when seventeen years old. The other eye later exhibited hemorrhages in the retina and vitreous, without glaucomatous symptoms. Constipation, epistaxis, and irregular heart. Gout in the family. The vitreous hemorrhages in the eye first lost may have originated from the retina.

Mayweg saw a young man of eighteen who had previously lost the left eye from recurrent vitreous hemorrhages, and now presented himself on account of what he asserted was the fourth attack of hemorrhage into the vitreous of the right eye, that condition having been three times before diagnosticated by competent men. Six relapses followed in rapid succession, and the sight was reduced to perception of light. Finally the right common carotid was ligated, with the result of effecting a permanent cure, so that after several months vision remained at $\frac{20}{60}$ with a normal ophthalmoscopic image.

Dor observed repeated vitreous hemorrhages in a girl of fourteen who had never menstruated; after establishment of this function the hemorrhage ceased.

Dujardin had a male patient who suffered from recurrent hemorrhages, first in one eye and then in the other, and he never was able to discover the cause.

Schiess' patient was a boy of twelve who suddenly became blind in both eyes whilst at school. "A blue cloud," as he expressed it, "came down over his sight." He never saw again.

Constipation is the one cause quoted by nearly all the writers on vitreous hemorrhages.

In regard to the treatment I would say that the whole question was very freely discussed as far back as 1864 at the Heidelberg Congress, and v. Graefe, as well as many others, were inclined to think *that the result was about as good if left to nature, as if every remedy in the pharmacopœia were administered in rotation.*

In conclusion, I will now report six cases from my private practice:

Case 1.—A man aged twenty-two lost the sight of his left eye a few hours previous to coming to me. He knew of no other cause than that he had been sawing wood. After resting a while, "a greenish veil dropped down over the eye." This attracted his attention, so that on covering the other eye he perceived that the left eye was blind. Ophthalmoscope revealed nothing but a black cloud. The fundus could not be illuminated with the mirror. This being my first case, I remember telling the attendant physician that the case was one of detachment of the retina. Under the influence of iodide of potassium in small

doses, given for lack of anything better then available (this was in 1874), the sight recovered to $\frac{20}{200}$. Two years later the patient had useful vision, being able to read, though long words had to be spelled out, Snellen 6. Some years later, S = $\frac{20}{60}$. The ophthalmoscope revealed a greenish opacity in the vitreous directly in front of the optic papilla. The yellow spot was not implicated, but as the patient looked at objects, the floating opacity in the vitreous sank down before anything that he was reading, hiding it temporarily. Ten years later, with a weak cylinder, + 0.25 D, axis 90°, S = $\frac{20}{30}$. Right eye normal throughout.

A delicate opacity extends from the margin of the papilla to near the posterior capsule; the greenish hyperplasia in the vitreous remains as before.

Case 2.—S. D., a man of thirty-five; March, 1885. Total loss of sight, right eye, since December. This began in August without pain. A sudden mist before the eye. The left remained normal till a week before consulting me, when it began to fail so rapidly that whereas, a fortnight before, he could read ordinary type with this eye, he could at present scarcely count fingers at 18″. Right eye detects the movement of shadows close before it. Ophthalmoscopic examination: Right, impossible on account of a dense opacity in the vitreous. No distinctive color on oblique illumination. Left, a dark greenish reflex from the fundus, directly in centre of visual axis. In the periphery some dense black vitreous opacities.

Heurteloup to each temple. Iodide of potassium in increasing doses up to four grammes daily in divided doses. Later, mercurial inunctions were used for considerable time. Fluid extract jaborandi in suitable doses had a visible effect on the opacities, so that when they gradually lightened the posterior layer of the vitreous exhibited the same green elevations as in the former case. That the hyperplasia was in the vitreous and not in the retina, seemed demonstrated by the absence of the overlying retinal vessels, as we see them in detachment of the retina.

The highest point of the greenish "neoplasm," if it may be so styled, was about 4 *mm* in front of the retina.

A year later sight in the right eye $\frac{20}{60}$, left eye $\frac{20}{40}$; a very remarkable improvement. The man is now, and has been ever since, earning the daily wages of the average workman.

Case 3.—A young lady aged eighteen lost the sight of the right eye in July, 1890, without any visible cause, except, perhaps, too

much use of the eyes at night. Perception of light. Fundus not illuminable. After using iodide of potassium six months the sight began to improve, so that fingers were counted. No green reflex. Pilocarpine injections were now freely employed, with the effect of increasing the sight considerably. A constant battery was then used and the sight cleared still further up to $\frac{20}{100}$. After several other attempts with pilocarpine, mercurial inunction, mercurials internally, and large doses of the iodide of potassium, the patient ceased to follow any treatment. The sight is at present $\frac{20}{100}$, Sn. 8 with some difficulty, but after all this is useful vision in case the good eye were lost or injured.

CASE 4.—A young man of thirty-two came home with an uneasy feeling in his eyes, from a concert where he had been facing a very bright electric light. On waking the next morning he perceived a black cloud in front of the right eye. Extensive hemorrhage into the vitreous visible as a reddish cloud behind the pupil with oblique lumination. No trace of fundus; perception of light. Pilocarpine injections $\frac{1}{10}$ grain producing profuse expectoration, twenty injections on alternate days. The sight gradually improved. No green reflex. The iodide was then given in increasing doses up to 3 grammes daily. Result after seven months, $\frac{20}{60}$ and Snellen 6. No traces in the retina of any disease, and only a slight opacity far back in the vitreous.

CASE 5.—Is very much like the preceding. A young man of twenty-four, working in a draughting office suddenly observed a mist over his right eye. As he could not find time for pilocarpine injections, he took granules of the same every night at bedtime, $\frac{1}{10}$ grain. Vision at first $\frac{5}{200}$, gradually increased, under the exhibition of pilocarpine, and the iodide in small doses, to $\frac{20}{40}$ and Snellen 8. Long words have to be spelled. No new formation in the vitreous. A long floating opacity in the vitreous. Left eye normal throughout.

CASE 6.—Is the most remarkable that I have seen for many years, in that the patient had been treated, for nearly two years before he came under my care, with the iodide of potassium, mercurials, repeated and abundant leechings, Heurteloups to the temples, rest in bed, pressure bandages, pilocarpine injections, and even an iridectomy had been proposed for the condition diagnosticated in both eyes and that by several competent observers as a well-defined detachment of the retina.

April 10, 1891.—He was led into my office as he had to be led

into any room with which he was not familiar, although he can find his way about his own home. History: Age thirty-two. At the age of eleven, after a long attack of the measles followed with whooping-cough, it was discovered that his right eye was defective. He could see to read only the headings of newspapers. In June, 1889, the left eye suddenly failed. In one day the sight was so much reduced that he could only see the movements of his fingers. The eye was treated as above stated for eighteen months without the slightest improvement. In the interval, on the 30th March, 1890, the right eye, on which he had relied for some months for orientation and a small amount of farm work, failed as the other had done. The result was, that from that date till April, 1891, the amount of vision in each eye was the perception of the movement of the fingers in front of the eyes. When lying down, he could, on a very bright day, see people as they moved by the foot of the lounge on which he passed most of his time.

The green reflex plainly visible with the ophthalmoscope, the perfect field of vision, and the remembrance of the few other cases that I had seen, led me to tell him that there was no reason why he could not be made to see. Whereupon he told me what he had been doing for two years. Of course I felt rather dumbfounded on learning that he had taken all of the most approved remedies without avail. Nevertheless, knowing that the case could not possibly be one of detachment, and having great faith in the iodide of potassium in all stages of this new formation in the vitreous, he was directed to get a saturated watery solution of the iodide and to begin with small doses and increase to the largest that he could tolerate. He went as high as thirty drops three times a day, representing about 5 grms. In three weeks the sight began to improve. He continued the same medicine and has taken no other up to this date, February 16, 1892. He can see $\frac{20}{200}$ and Snellen 20, right, which is as good as before the late trouble. With the left eye he has $S = \frac{20}{50}$ and Snellen 6 with ease, except in the case of long words, which he has to spell, as he says he "cannot see all of the word at once." Vitreous clear in both eyes. Extending from each papilla, and embracing it, though not hiding it, is a green band, as nearly as I can express it, above and below, about one papilla diameter wide, and reaching out apparently over the retina about four disc diameters upward and three downward. With the refraction ophthalmoscope

the new formation or hyperplasia measures from +3 D to +5 D above the level of the rest of the retina. There are no vessels upon it. It looks somewhat like the doubled contoured fibres in Jaeger's Figure 36, but is distinctly green.

Not the least remarkable about this curious case is the fact that the iodide of potassium, which had been given in abundance before without any effect, should a year or two later act so efficaciously. This may be analogous to the fact that we often see one eye recovering from an attack of iritis, and the other just entering upon the same, despite the system being completely under the influence of mercurials, or of the iodide or other suitable remedies.

DIAGNOSIS.—It does not seem as if there were much if any need to insist that this disease ought not, under any circumstances, to be mistaken for a detachment of the retina. But I am convinced that many, if not all, of the reported cures of detachment of the retina after the use of pilocarpine are nothing but cures of vitreous hemorrhages. Even here we must not forget that, according to some authorities, spontaneous cure of these hemorrhages have been observed. So in the same way we may explain spontaneous cures of apparent detachment of the retina, as really nothing but the spontaneous disappearance of a vitreous hemorrhage. If, however, we are to insist on the diagnosis between hemorrhages and a detachment, it must be made on the basis of a perfect field of vision in the hemorrhage; and as the latter dissipates, the absence of the retinal vessels on the greenish bands, if such be present, as is oftentimes the case.

The PROGNOSIS seems to be favorable. No perfect restoration is possible, but useful vision is regained in a majority of cases. If a person has lost the sight of an eye from vitreous hemorrhage and yet recovers it so far as to be able to read Snellen 6 to 10, he has useful vision and could gain a living at many trades. If relapses occur, the chances may become worse. Only one patient complained of eccentric vision after slight restoration, but even that was soon remedied.

ÆTIOLOGY.—This remains in doubt. So long as we exclude all myopic eyes, and as we generally find the other eye, if

unaffected at first, apparently healthy, it would seem as if some strain, such as too violent exercise of the system, or the suppression of habitual discharges, or actual overwork of the eyes must be the exciting cause. In this respect the opinions of authors as before advanced in this paper may reasonably be consulted.

TREATMENT.—In the first place I should put hypodermatic use of pilocarpine hydrochlorate or nitrate. This is to be given in $\frac{1}{12}$ grain doses once a day for two weeks. Perhaps fewer doses may do as well. If any dose produces weakening effects on the heart then the next dose may be decreased or omitted for two days. In case no visible effect is produced, the dose may go as high as $\frac{1}{6}$, though I have never seen the need of more than $\frac{1}{10}$. It is not necessary to produce visible physiological effects, for the remedy to be useful to the eye. It may also be given by the mouth, though it is not so efficacious when thus administered. The fluid-extract of jaborandi may be substituted, but it is much more disagreeable to take than the alkaloid.

Mercurials may be used in some cases, when the rarefication of the vitreous ceases from any cause. Inunction may be done by causing the patient to put a lump of blue mass into the stockings every day. Or blue mass and iron sulphate in equal parts in pill form may be used. Hypodermatic sublimate is occasionally indicated. It was substituted for the iodide in one case with apparently great benefit.

The constant current has been highly extolled by some, but the difficulty in keeping batteries in order where there is but little call for them will generally prevent its use in these as in other cases. In point of fact, two patients who do not appear in this list as they are still under treatment, have shown great improvement whilst using an ordinary faradic battery to each eye twice daily for five minutes.

Heurteloup's artificial leech is quite indispensable in the beginning of the attack. I never failed to advise its use. Care should be taken not to injure an artery. The application demands considerable skill on the part of the physician, but the reward is worth the time expended in doing the little operation neatly and with despatch.

RETENTION CYST OF THE CONJUNCTIVA OF TRAUMATIC ORIGIN.

By Dr. ENRIQUE LOPEZ, Habana.

Translated by Dr. C. E. Finlay.

THE case which I purpose to relate is, it seems, unique and interesting.

An injury from the horn of a cow produced a laceration of the soft parts around the eye, and a fracture of the internal, inferior and external portions of the margin of the orbit. The patient remembers being able to see with the eye immediately after the injury; but a violent inflammation set in, both lids became fastened together, and the cyst developed, without the patient's knowing whether he still had an eyeball or not, so that the discovery of the eyeball at the time of the operation was quite a surprise.

The piece of the cyst-wall which was extirpated, and which comprised the anterior and external portions, contained three fragments of bone in its interior. The cyst-wall was formed by the palpebral and retrotarsal conjunctiva; it was thick, unyielding, and firmly adherent to the neighboring soft parts.

Dr. Finlay, Sen., who made the histological examination, sends me the following report:

"The internal aspect of the cyst-wall is perfectly smooth. Remnants of epithelium are found on a more or less structureless, moderately thick basement membrane. The cyst-wall proper is extraordinarily thick, and is formed by a very dense network of connective tissue.

"The tissue of the cyst-wall merges into that of the neighboring soft parts without any special line of demarcation. Most

exteriorly one finds fatty tissue, and in some places striated muscle fibres."

The posterior wall was constituted by the cornea and bulbar conjunctiva. The cornea was perfectly transparent—the iris and pupil being plainly visible. The sclera could be seen through the bulbar conjunctiva. The eyeball had been pushed back into the orbit, and was fixed in the position of superior strabismus.

The contents of the cyst were a watery liquid, transparent and slightly yellowish. This fluid was not examined, all having escaped at the time of the operation. It probably was lachrymal fluid.

I consider the mode of formation of the cyst to be as follows: The traumatism produced lacerations of the conjunctival mucous membrane. Both the palpebral conjunctivæ wounded near their free border, adhered together and formed a cavity closed on all sides, and lined by the corneal and conjunctival epithelium. The tears filling this bag distended it and compressed the epithelial layer, which flattened out, the internal aspect of the cyst-wall becoming perfectly smooth, and the wall proper increasing in thickness. The conjunctival sac, once filled out, the retained tears compressed the lachrymal gland, and brought about its atrophy, or at least a considerable diminution in its secretory activity. In a word, the tumor which I describe, in my opinion, is nothing but a *retention cyst.*

CLINICAL HISTORY.

A laborer, twenty-four years of age, on being admitted to the Mercedes Hospital, relates that when a child both his eyes were healthy; that when twelve years old he received an injury from the horn of a cow in the left orbital cavity; that a violent inflammation set in, and that he was taken to the hospital of Ferrol (Spain), where he underwent an operation.

From that time a tumor commenced to form in this region, which has increased gradually up to its present size without causing any discomfort other than that produced by the deformity.

The tumor is conical on its anterior aspect, and is covered by the anchylosed eyelids, the free borders of which can only be separated about 4 *mm* from each other, through which small fissure one sees a band of red and thickened conjunctiva.

The tumor is fluctuating; the sensation on palpation being

that of a ball filled with fluid ; it is indolent ; there is no change in color of the skin of the lids. There is a diverticulum toward the lachrymal sac. Its limits within the orbit cannot be determined. The height of the cone is about 3 centimetres. Near the inferior and external orbital margin there is a sequestrum.

OPERATION.

The diagnosis of a serous cyst having been made, and under the supposition that there was no eyeball, I purposed to extirpate it entirely.

Chloroform ; division with a scalpel and a grooved director of the tissues joining the two lids ; the palpebral fissure being enlarged, both outward and inward. The lids were then separated from the cyst-wall with scissors and a grooved director. In cutting, the cyst was opened, giving exit to a yellowish, transparent fluid ; and at the bottom of the cyst-cavity the eyeball was discovered in a perfectly healthy condition.

The operation was finished by removing a portion of the anterior wall of the cyst, embedded in which were three pieces of dead bone, which had become separated from the orbital margin.

Sutures were then introduced to reduce the palpebral fissure to its normal size, and iodoform dressing was applied,

The following days there was only perception of light in the newly discovered eye, but at the end of a month the patient could count fingers.

SOME SQUINT STATISTICS.

By H. H. SEABROOK, M.D., New York,

SURGEON, NEW YORK EYE AND EAR INFIRMARY.

THIS study has as its basis the New York Eye and Ear Infirmary records of Dr. Chas. Stedman Bull, from 1876 to 1891. Intended originally merely for private information, it seemed probable that the results might prove interesting to ophthalmologists in general. Cases from Dr. Bull's later records, others from the records of Dr. M. E. Tully, and my own cases have been added, increasing the original number more than one fourth, but not affecting the general average to any extent. An attempt has been made to draw conclusions from these cases without reference to current views upon the subject, so far as possible.

STRABISMUS CONVERGENS.

(Physiological.)

The following are cases in which no lesion was known to exist in either eye. Cases of cured strabismus convergens, as well as secondary divergence following tenotomy of the internus, are included. There were in all 290 females and 249 males; many of these were children so young that no accurate study of their refraction and vision could be made.

Refraction.—For evident reasons only the cases under atropine are tabulated. On account of the intense spasm of accommodation so frequent in young subjects with internal squint, a distinction must be drawn between H T and H under atropine. Sometimes after an operation for the squint, or following the use of convex glasses, H M was

found to be greater than H under atropine had been. In such cases the higher H has been chosen as more nearly correct. In astigmatic cases the mean meridian is taken—H + ½ Ah in compound, ½ Ah in simple astigmatism.

Table I.

H of Strabismus Convergens under Atropine

	Determined in one eye only.	Alike in both.	Differing in each	Totals.		
D 0.50			2	2	Under D 1.	
0.75		1	4	6		
1.			5	5	13	
1.25		7	8	22	D 1 to D 2.	Under D 2.
1.50	4	5	13	27		
1.75		1	3	5		
2.	5	1	19	26	80	93
2.25	1	2	5	10	D 2 to D 3.	Under D 3.
2.50	2	2	22	28		
2.75	2		7	9		
3.	3	7	19	36	83	176
3.25	2		8	10	D 3 to D 4.	Under D 4.
3.50	1	1	7	10		
3.75	1		3	4		
4.	2	4	27	37	61	237
4.25		2	3	7	D 4 to D 5.	Under D 5.
4.50	4	10	21	45		
4.75	2		3	5		
5.	7	2	20	31	88	325
5.25		1	2	4	D 5 to D 6.	Under D 6.
5.50		4	10	18		
5.75	2	1	5	9		
6.	1	1	13	16	47	372
6.25			1	1	D 6 to D 7.	Under D 7.
6.50		4	3	11		
6.75			1	1		
7.		1	3	5	18	390
7.50			2	2	Over D 7.	Total eyes
8.		2	1	5		
9.			2	2	9	399
Patients.....	39	59	121		Total . . 219	

Average refraction + D 3.67.

There were two cases of convergent squint and Am under atropine, although in one the refraction may be considered doubtful. In four cases M of high degree. Two of these had apparent convergence, periodically changing to real convergence. In one V O U $= \frac{4}{cc}$, with sph. — D 14 $= \frac{20}{cc}$, astigmatism by the ophthalmometer, with the rule, D 2.75. Jaeger No. 1 at $2\frac{1}{2}''$. Diplopia with the real convergence, M congenital or infantile, squint noticed recently.

As to whether the H of these squint cases is considered to be of high or low degree depends entirely upon the standpoint. For instance Donders says: "In general, it is not the highest degrees of H with which strabismus is combined . . . Where it was manifest, it amounted to from $\frac{1}{30}$ to $\frac{1}{10}$ rarely to $\frac{1}{7}$ or more . . . with $\frac{1}{30}$ manifest H more than $\frac{1}{15}$ total H may be assumed." Gould found in over 2,000 eyes HT averaging about D 1.50, counting the most hyperopic meridian in Ah. So it would seem that the standard at Utrecht thirty years ago differed from that more recently acquired at Philadelphia.

Two thousand eyes under atropine (1,028 patients) from Dr. Bull's clinical records, figured upon the same basis as the squint cases in Table I. gave average H = D 2.61. These cases with poor V, asthenopia or blepharitis counted in with the squint cases, give 2,399 eyes with average H = D 2.79. Consequently the 140 eyes in the table up to D 2.75 inclusive are below the hyperopic mean, while 259 are above it. And I should say: "In general *it is the higher degrees of H with which strabismus convergens is combined.*"

Vision.—The best V obtained by correction is shown in Table II. Where a second test showed a result markedly different from the first, the eyes were again tested and the correct V decided by weight of evidence.

The general decrease in V as H increases is here seen. The part astigmatism plays in defective V cannot be shown because of insufficient data in the earlier cases. At the bottom the 44 cases, refraction not determined, show how bad the V was when the patient was too young for proper correction, yet not too young to get a rough estimate of V. There was, in general, higher H by the ophthalmo-

scope in these than in the other cases, due no doubt to the fact that internal squint with good V in both eyes and moderate H is usually acquired after the beginning of school life, when the refraction can be obtained by testing the eyes with glasses. A comparison of the 255 eyes tested but once with the 399 tested two or more times emphasizes the fact that the more carefully the V is corrected the less "congenital amblyopia" there is.

Table II.

H and V of Strabismus Convergens under Atropine.

	20 XX	20 XXX	20 XL	20 L	20 LXX	20 C	20 CC	less than 20 CC		Per cent. V
D 0.50		2							2	Under D 1.
0.75	3	2		1					8	
1.	2	1		2					13	.733
1.25	9	5	5	1	2				35	D 1. to D 2.
1.50	9	8	6	1		2	1		62	
1.75	4	1							67	
2.	4	7	7	2	5		1		93	.665
2.25	1	9							103	D 2. to D 3.
2.50	18	1	1	2	2	2	2		131	
2.75	4	3	1	1					140	
3.	13	6	5	6	4	1	1		176	.703
3.25	3	2	1	2	2				186	D 3. to D 4.
3.50	1	3		4	1		1		196	
3.75		2	1	1					200	
4.	8	7	8	5	6	1	1	1	237	.559
4.25	2	2	1		2				244	D 4. to D 5.
4.50	9	15	5	8	2	3	2	1	289	
4.75	2	1	1	1					294	
5.	4	7	4	8	4	3		1	325	.565
5.25		1	2				1		329	D 5. to D 6.
5.50		6	3	4	3		2		347	
5.75	2	1	1	2	1	1	1		356	
6.		6	2	2	2	1	2	1	372	.453
6.25					1				373	D 6. to D 7.
6.50		2		4	1		3	1	384	
6.75			1						385	
7.		2	1	1	1				390	.383
7.50					2				392	Over D 7.
8.		1		3		1			397	
9.							2		399	.315
Totals	98	103	56	61	41	15	20	5	399	.592
Average H	D2.64	3.59	3.54	4.27	4.16	4.22	4.97	5.20		
V Atropine. Refraction unknown.	3		1	2	4	4	10	20	44	
V No atropine	60	46	33	31	25	18	17	25	255	
V Totals.	161	149	90	94	70	37	47	50	698	

As regards the question of "Anisometropia Hypermetropica" as a cause of squint, the following is submitted: Over 40 per cent. of the 1028 cases before mentioned had a different degree of H in the right from that in the left eye, this difference occurring mostly in the higher degrees of H. Among the converging eyes V being known in both eyes of 343 patients, there were with V and refraction the same in the right and left eyes, $\frac{20}{XX}$, 19; $\frac{20}{XXX}$, 18; $\frac{20}{XL}$, 10; $\frac{20}{L}$, 10; $\frac{20}{LXX}$, 2; $\frac{20}{C}$, 1; $\frac{20}{CC}$, 2; a total of 62 cases, while 31 had equal V in both eyes, refraction differing as follows: $\frac{20}{XX}$, 11; $\frac{20}{XXX}$, 10; $\frac{20}{XL}$, 5; $\frac{20}{L}$, 3; $\frac{20}{LXX}$, 2, making 93 cases with V the same in both eyes, only 7 with $\frac{20}{LXX}$ or less. The V differed, but refraction of the right and left eyes was the same in 24 cases, making 86 cases with refraction the same in both eyes.

Perhaps these figures prove something, yet I cannot say that I know just what. The data are given, because of the interest upon this point displayed by certain ophthalmologists, who seem to consider it of great importance.

The following cases are those which I have tested within two years: In case No. 1 the eyes were tested once, the left not improved, and a diagnosis of congenital amblyopia made yet corrected V = $\frac{20}{XX}$. Unusual care was taken after this to ascertain the refraction of squinting eyes with defective V, the test glasses and atropine being mainly relied upon, with the ophthalmoscope and later the ophthalmometer as auxiliaries. The later results were by far the more satisfactory, as the ciliary muscle is really paretic in many of these eyes, although the other eye, with better apparent V and less squint, may have considerable spasm of accommodation. If the proper correction is not put upon the weaker eye at first, the eye or the patient becomes rapidly fatigued, and the result is much less satisfactory.

The later cases were tested as follows: The V of the more defective eye was first taken; then the V of the other, in order to eliminate alphabetical recitations from memory,

which otherwise might interfere with the test. H in the meridian of least curvature was then measured with the ophthalmoscope; afterwards the astigmatism with the ophthalmometer. The correction thus obtained was put upon the eye, and in many cases was found to be the best obtainable, although variations were tried. It will be seen by the tests how often and how much the V was improved. The corrected V was always verified with a fresh test-card, and the better eye held shut by the hand of the patient while the other was tested; this not only to avoid error, but to enable the open eye to fix better, so as to more accurately obtain the V at the macula. In some the correction of the astigmatism gave no better result than the spherical glass alone, yet was accepted, the patient even claiming to see more distinctly with the cylinder added. In such cases the cylinder is enclosed in brackets in the list of cases. Where a glass was accepted without improvement, V is given unimproved; V given as do. meaning that the V dropped under atropine, to be brought back to the original V by means of the given glass. A spherical, estimated, means, where the diagnosis of astigmatism is given, in the least meridian of H. Macula Cases 52 and 63 are not in Table I, but among the pathological cases.

No.	Age.	Eye.	V.	Corrected V.	Correcting Lens.	V Other Eye.	Corrected V.	Correcting Lens.	Remarks.
1	16	L	$\frac{20}{C}$	$\frac{20}{XX}$	Sph. + D 3.75 ⌒ Cyl. + D 1.50 axis 90°	$\frac{20}{XXX}$	$\frac{20}{XX}$	Sph. + D 4 ⌒ Cyl. + D 1.50 axis 90°	Homonymous diplopia. Insufficiency of left superior rectus.
2	11	R	$\frac{20}{XL}$	$\frac{20}{XXX}$	Sph. + D 1 ⌒ Cyl. + D 1 axis 180°	$\frac{20}{XXX}$	do.	Sph. + D 1 ⌒ Cyl. + D 1 axis 180°	
3	7	R	$\frac{20}{LXX}$	$\frac{20}{XXX}$	Sph. + D 4	$\frac{20}{XXX}$	do.	Sph. + D 4	
4	11	R	$\frac{20}{C}$	$\frac{20}{XL}$	Sph. + D 4 ⌒ Cyl. + D 2.25 axis 105°	$\frac{20}{C}$	$\frac{20}{XXX}$	Sph. + D 4 ⌒ Cyl. + D 2.25 axis 75°	
5	14	R	$\frac{5}{CC}$	$\frac{20}{L}$	Sph. + D 3 ⌒ Cyl. + D 3 axis 90°	$\frac{20}{XL}$	$\frac{20}{XXX}$	Sph. + D 4	
6	15	R	$\frac{20}{C}$	$\frac{20}{LXX}$	Sph. + D 5	$\frac{20}{XL}$	$\frac{20}{XXX}$	Sph. + D 5 ⌒ Cyl. + D 1.25 axis 90°	
7	12	R	$\frac{20}{CC}$	$\frac{20}{L}$	Sph. + D 8	$\frac{20}{C}$	$\frac{20}{L}$	Sph + D 8	H + Ah.
8	16	R	$\frac{20}{CC}$	$\frac{20}{L}$	Sph. + D 1.50 ⌒ Cyl. + D 4.50 axis 90°	$\frac{20}{XXX}$	do.	Sph. + D 1.25	R E improved without atropine.
9	8	L	$\frac{20}{C}$	$\frac{20}{L}$	Sph. + D 3	$\frac{20}{CC}$	Unimproved		With ophthalmoscope H = D 4 50.
10	10	R	$\frac{20}{C}$	$\frac{20}{L}$	Sph. + D 1.75	$\frac{20}{L}$	Unimproved		No atropine.
11	15	R	$\frac{10}{CC}$	$\frac{20}{C}$	Sph. + D 3.50	$\frac{20}{XL}$	do.	Sph. + D 1.50	No atropine.
12	12	R	$\frac{20}{CC}$	$\frac{20}{LXX}$	Sph. + D 2.50	$\frac{20}{XX}$	do.	Sph. + D 2.50	No atropine O D.
13	13	R	$\frac{20}{XL}$	$\frac{20}{XXX}$	Sph. + D 1.25	$\frac{20}{XX}$	do.	Sph. + D 1	Test of 1883, operation, then V O D = $\frac{20}{XXX}$ V O S = $\frac{20}{XX}$
	21	R	$\frac{20}{XX}$	do.	Sph. + D 1.50	$\frac{20}{XX}$	do.	Sph. + D 1.75	Insufficiency of interni. *Homonymous* diplopia, fused by prism of 10° base in. Field of vision normal O. U.
14	11	L	$\frac{20}{CC}$	$\frac{20}{L}$	Sph. + D 3.50 (Sph + D 4 (est.)	$\frac{20}{C}$	$\frac{20}{L}$	Sph. + D 3.50 (Sph. + D 4 (est.)	Convergent squint in family for six generations. Operation (tenotomy right internus), then O S parallel with O D for distance. Converges when O D fixes near point.
	11½	"	"	"	Sph. + D 4.50 (Cyl. + D 0.50 axis 90°	"	$\frac{20}{XXX}$	Sph. + D 4.50	
15	8	R			Sph. + D 3 (est.)			Sph. + D 4 (est.)	
16	11	R	$\frac{20}{XXX}$	$\frac{20}{XX}$	Sph. + D 2.75 ⌒ Cyl. + D 1 axis 90°	$\frac{20}{XXX}$	$\frac{20}{XX}$	Sph. + D 4.	Double tenotomy four months later; tenotomy right internus one month after this. Result: O D converges on fixation for near point; parallelism for distance.
17	5	R			Sph. + D 4 (est.)			Sph. + D 4 (est.)	Weak externi.
18	8	R	$\frac{2}{CC}$	Unimproved	Sph. + D 7 (est.)	?	$\frac{20}{XXX}$	Sph. + D 4.50 ⌒ Cyl. + D 1.50 axis 90°	H + Ah O D.
19	7	R	$\frac{6}{CC}$	$\frac{20}{C}$	Sph. + D 7 ⌒ Cyl. + D 2 axis 60°	$\frac{20}{L}$	$\frac{20}{XXX}$	Sph. + D 7 ⌒ Cyl. + D 2 axis 120°	
20	17	L	$\frac{20}{L}$	do.	Sph. + D 6.50	$\frac{20}{XXX}$	do.	Sph. + D 6.50	Insufficiency of interni; convergence disappeared in two months under Sph. + D 5.
21	6	L	$\frac{20}{CC}$	Unimproved		$\frac{20}{LXX}$	do.	Sph. + D 5	

No.	Age.	Eye.	V.	Corrected V.	Correcting Lens.	V Other Eye.	Corrected V.	Correcting Lens.	Remarks.
22	20	R	6/CC	20/LXX	Sph. + D 3.50 ⌒ Cyl. + D 1.50 axis 45°	20/C	20/L	Sph. + D 4 ⌒ Cyl. + D 2 axis 135°	
23	10	L	2/CC		Sph. + D 2 (est.)	20/XX		Sph. + D 1.50 (est.)	Estimated under atropine; nasal side of disk hazy and indistinct. Lenticular astigmatism or neuritis?
24	15	R	20/CC	Unimproved		20/XX	do.	Sph. + D 2.75	
25	13	R	20/C	20/XL	Sph. + D 8	20/XL	20/XX	Sph. + D 6	
26	7	L	10/CC	20/CC	Sph. + D 9	20/XXX	do.	Sph. + D 6	
27	15	L	20/XXX	20/XX	Sph. + D	20/XX	do.	Sph. + D 4	Homonymous diplopia. Parallelism with glasses in one month.
28	7	L	20/LXX	20/XL	Sph. + D 4	20/LXX	do.	Sph. + D 5.50 ⌒ Cyl. + D 1.50 axis 90°	
29	7	L	20/C	20/LXX	Sph. + D 7 ⌒ Cyl. + D 1 axis 90°	20/XL	do.	Sph. + D 7	
30	7	L			Sph. + D 3 (est.)			Sph. + D 2.50 (est.)	H + Ah O S.
31	4	L			Sph. + D 4.50 (est.)			Sph. + D 3.50 (est.)	H + Ah O U.
32	10	L	20/C	20/XX	Sph. + D 3.25 ⌒ Cyl. + D 2.50 axis 115°	20/XL	20/XX	Sph. + D 2.50 ⌒ Cyl. + D 1.25 axis 80°	Operation sixteen months before.
33	5	L			Sph. + D 5.50 (est.)			Sph. + D 4 (est.)	
34	12	L	2/CC	Unimproved	Sph. + D 6 (est.)	20/L	do.	Sph. + D 5	Faint striæ in lens O. S.
35	7	L	20/C	20/LXX	Sph. + D 6	20/XL	20/XXX	Sph. + D 5	
36	18	L	20/XL	20/XX	Sph. + D 5.50 ⌒ Cyl. + D 1.25 axis 120°	20/XX	do.	Sph. + D 5 ⌒ Cyl. + D 1.50 axis 90°	
37	6	R			Sph. + D 4.50			Sph. + D 4.50	Estimated under atropine.
38	7	R			Sph. + D 3.50			Sph. + D 3.50	Estimated under atropine.
39	6	R			Sph. + D 2 ⌒ Cyl. + D 3 axis 110°			Sph. + D 2 ⌒ Cyl. + D 3 axis 90°	Ophthalmoscope and ophthalmometer.
40	9	L	20/XL		Sph. + D 2.50	20/XX		Sph. + D 1.50	Ophthalmoscopic approximation.
41	13	L	20/CC	20/XL	Cyl. + D 5, axis 60° ⌒ Sph. + D 4	20/XL	20/XX	Cyl. + D 3.50 axis 150° ⌒ Sph. + D 2 50	
42	14	R	20/CC	20/C	Cyl. + D 6 axis 105° ⌒ Sph. — D 1 50	20/XL	do.	Cyl. + D 4 axis 105° ⌒ Sph. + D 3	Operation five years before. Marked internal squint at present.
43	9	L	3/CC		Sph. + D 6 (est.)	20/CC		Sph. + D 3 (est.)	
44	7	R	20/CC		Sph. + D 5.50 (est.)	20/LXX		Sph. + D 3.50 (est.)	
45	11	L	15/CC	20/LXX	Sph. + D 8 (Cyl. + D 1 axis 120°)	20/XX			No atropine. O D hyperopic.
46	19	R	20/CC	20/C	Sph. + D 3.50 ⌒ Cyl. + D 3 axis 90°	20/L	20/XXX	Sph. + D 8 ⌒ Cyl. — D 1 axis 30°	
47	12	L	20/CC	20/L	Sph. + D 5 (Cyl. + D 2.50 axis 120°)	20/XX	do.	Sph. + D 4.50	

No.	Age.	Eye.	V.	Corrected V.	Correcting Lens.	V Other Eye.	Corrected V.	Correcting Lens.	Remarks.
48	7	L	$\frac{20}{C}$	do.	Sph. + D 4 (Cyl. + D 3.75 axis 75°)	$\frac{20}{L}$		Sph. + D 3 ⌒ Cyl. + D 2.50 axis 120°	V O D before atropine = $\frac{20.}{L}$ After atropine = $\frac{20}{CC}$. With lens given = $\frac{20}{LXX}$
49	10	R	$\frac{8}{CC}$	$\frac{20}{CC}$	Sph. + D 6.50	$\frac{8}{CC}$	$\frac{20}{CC}$	Sph. + D 6 50	H + Ah O U.
50	3	L			Sph. + D 7			Sph. + D 6	Estimated. Child is wearing Sph. + D 4 O D Sph. + D 6 O S.
51	11	R	$\frac{20}{XX}$	do.	Sph. + D 2.50	$\frac{20}{XX}$	do.	Sph. + D 2.50	
52	12	L	$\frac{1}{CC}$	Unimproved		$\frac{20}{XX}$	do.	Sph. + D 2.75	Macula corneæ; strabismus sursumvergens O S. Slight convergence only left after tenotomy and correcting glass.
53	29	L	$\frac{6}{CC}$	$\frac{15}{CC}$	Sph. + D 5.50 ⌒ Cyl. + D 2.50 axis 90°	$\frac{20}{XV}$	do.	Sph. + D 0.75 ⌒ Cyl. + D 1 axis 75°	Tenotonomy left internus eight years before; perfect parallelism. No glass worn.
54	17	L	$\frac{20}{CC}$		Sph. + D 4 ⌒ Cyl. + D 2.50 axis 90°	$\frac{20}{XX}$		(Sph. + D 4)	
55	15	R	$\frac{20}{CC}$	$\frac{20}{LXX}$	Sph. + D 7	$\frac{20}{LXX}$	$\frac{20}{L}$	Cyl. + D 1.75 axis 180°	
56	14	L	$\frac{20}{XXX}$	do.	Sph. + D 3.50	$\frac{20}{XX}$	do.	Sph. + D 3.50	No atropine. After operation.
57	18	L	$\frac{20}{C}$	$\frac{20}{XXX}$	Cyl. + D 2.50 axis 150°	$\frac{20}{XX}$	do.	Sph. + D 1.50	Tested under atropine by my assistant, Dr. Burnham, who found H O D = D 5, but did not correct O S. Test here given is the third, practically agreeing with first. No atropine.
58	12	R	$\frac{20}{L}$	$\frac{20}{XXX}$	Cyl. + D 1 axis 90°	$\frac{20}{XXX}$	$\frac{20}{XX}$	Cyl. + D 0.75 axis 165°	
59	20	L	$\frac{20}{L}$	do.	Sph. + D 1.25 (Cyl. + D 1 axis variable)	$\frac{20}{XX}$	do.	(Cyl. + D 0.50 axis 60° ⌒ Sph. + D 0.50)	O S formerly converged. Tenotomy internus three years before. Parallelism at first (patient's statement). O S now diverges. After atropine *convergence* O U. Ophthalmometer shows: O D astigmatism D 0.50 axis 60° centre of pupil; just to either side D 1 axis 90°. O S. Two meridians of curvature (+ D 0.50) crossing line an X, and sharply defined.
60	11	R	$\frac{20}{L}$	$\frac{20}{XXX}$	Sph. + D 3	$\frac{20}{L}$	$\frac{20}{XL}$	Sph. + D 3.50	Squinted up to about five years of age. Spontaneous recovery. Has worn glasses over one year for asthenopia. No atropine.
61	8	R	$\frac{20}{XXX}$	do.	Sph. + D 4	$\frac{20}{XX}$	do.	Sph. + D 3.50	Squint recently acquired.
62	8	L	$\frac{3}{CC}$	$\frac{20}{CC}$	Sph. + D 4.50 (Cyl. + D 2 axis 135°)	$\frac{20}{L}$	$\frac{20}{XL}$	Sph. + D 3 (Cyl. + D 1.50 axis 90°)	
63	33	L	$\frac{3}{CC}$	Unimproved	Sph. + D 5 (est.)	$\frac{20}{C}$	$\frac{20}{XL}$	Sph. + D 5.50	Operation for squint O S years before. Result good — not perfect. No glasses worn. No atropine. Small macula corneæ *O D.*

These cases emphasize in a marked manner the results shown in Table II. Briefly stated, so-called congenital amblyopia is ametropia. Counting H + Ah in the above cases, the eyes with V before correction = $\frac{20}{Lxx}$ or less average well over D 6, and the more sure the correction the higher the H + Ah.

When V can not be satisfactorily corrected, one of the following causes can usually be demonstrated: 1. A high degree of astigmatism, with the axis diagonal. 2. Astigmatism, meridians of greatest and least curvature not at right angles. 3. Irregular corneal astigmatism, and of this there are many varieties. 4. Lenticular astigmatism. When we add to these other possible causes of defective V, such as improper centring of the cornea or lens as regards the axis of vision, there is little need to fall back upon defective retinal development as an explanation of poor V in these cases. The ophthalmoscopic signs by which congenital amblyopia is diagnosed would seem to be due to ametropia, for they are in great part absent where V is defective, and H is not of high degree just where their presence would be most useful and suggestive, and high degrees of H in which they are present can sometimes be markedly improved with a glass. V of eyes, with moderate errors of refraction and healthy media and fundus, varies from $\frac{20}{xxx}$ to $\frac{20}{x}$, and such good V is not expected from the correction of the higher refractive errors.

Eyes with defective V usually do not squint. Fifteen years' clinical records show among the hyperopic eyes, with V $\frac{20}{Lxx}$ or less:

EYES WITH CONVERGENT SQUINT.	EYES WITHOUT SQUINT.
158.	246.
Under atropine, 93.	Under atropine, 139.
Average H = D 4.23 in 56 corrected under atropine.	Average H = D 3.91 in 122 corrected under atropine.
Average H = D 4.07 in 47 with V = $\frac{20}{L}$ or better; the other eye with less V.—Under atropine.	Average H = D 2.83 in 64, with V = $\frac{20}{L}$ or better; the other eye with less V.—Under atropine.

Comparison of these eyes with defective V, with and without squint, has shown me but one difference between them. In the squinting eye H, in the normal axis of V, is sometimes of higher degree than in the acquired axis in the squinting position. So far I have not seen an eye without squint in which eccentric V was even apparently better than central. Defective V at the macula has been considered by competent observers as a peculiarity especially pertaining to squinting eyes, and I have come to consider it as a factor in the causation of squint.

STRABISMUS CONVERGENS.

(*Pathological.*)

Records of over fifty cases are at hand. In some it is certain that the squint antedated the pathological condition. It is not necessary to mention these in detail, although it is highly probable that the following list contains a number of cases where investigation would show the disease to be a complication rather than a cause of the squint.

Macula Corneæ.—Including 1 case of old pannus, there were 18 cases with corneal macula. In 7 of these the refraction is not noted. In 1, nineteen year old, V O D $= \frac{20}{xx}$; V O S $= \frac{20}{cc}$ with cyl. — D 3.50; axis 180°; macula, O S; squint, OU. Another, V O D $= \frac{20}{L}$; leucoma adhærens; V O S $= \frac{5}{cc}$, with sph. $- \frac{1}{18} = \frac{20}{cc}$; macula corneæ and strabismus convergens. In 9 cases (13 eyes) the refraction was hyperopic, averaging D 4. Whether the position of the macula had anything to do with the determination of the character of the squint, I do not know in most of the cases, but can positively answer, as regards several, that it had not, the opacity not being upon the pupil, although irregular corneal astigmatism may have encroached upon the pupillary region.

There was 1 case of macula, cataract, and H in addition to the above.

Cataract.—There was H in 2 cases of cataract and convergent squint, with nystagmus in 1 of these; M in 4; choroidal atrophy, with nystagmus, in 1; refraction not determined in 1.

Nystagmus.—Of the nystagmus cases not mentioned above, there was H in 3; refraction not determined in 1.

Atrophy of optic nerves or choroid, 5 cases. In 1 there was M of low degree; in another H.

Leucoma adhærens, phthisis bulbi, irido-choroiditis, and *following traumatism to eyeball*, 8 cases. This exclusive of the case under macula corneæ, the other eye in these cases being hyperopic, so far as is known.

Associated with other deformity, 3—coloboma iridis, 1; cleft palate, 1; tumor of orbit, 1.

One case seems to me so significant that I give a brief history:

A man, aged forty-one, with convergent strabismus, senile cataract almost mature, paralytic external recti, facial palsy, V O D $= \frac{3}{cc}$, V O S $= \frac{1}{cc}$. The squint dates from infancy, and V O S has been defective from earliest remembrance. The facial palsy occurred during childhood. Progressive failure of V O U, for two years. The cataract was extracted later, from the left eye; ten months afterward from the right. V O D, one month after operation $= \frac{20}{L}$, with sph + D 10; V O S, eleven months after operation $= \frac{20}{xxx}$, with sph + D 10.

This case certainly looks like "congenital amblyopia" from lenticular, or possibly corneal, astigmatism, and the history is decidedly against defective retinal development or disuse as a cause of the original defective vision in the left eye.

STRABISMUS DIVERGENS.

The most concise method of presenting the statistics upon this subject appears to be by means of a table, which it is to be hoped will explain itself, as probably no one will care to take the trouble to explain it:

STRABISMUS DIVERGENS.

	Hyperopia.	Myopia.	Mixed astigmatism and anisometropia.	Emmetropia and refraction unknown.	Total.
Physiological	34	21	2	8	65
Choroidal atrophy		8		2	10
Macula corneæ	1	8	1	9	19
Atrophy of optic nerve		8		10	18
Cataract (senile)	1	1		11	13
Cataract (traumatic)	1			4	5
Membrane, or connective tissue in vitreous		1		1	2
Nystagmus	1	1		1	3
Following disease of iris, injury to globe, etc	3	4		5	12
With acute choroidal or retinal disease		2		2	4
Following general disease				2	2
Totals	41	54	3	55	153

The number of cases of H treated at the New York Eye and Ear Infirmary is more than double the number of cases of M. Parents bring children with squint to be treated, and the refraction in these cases is usually hyperopic. Divergent squint with M is usually acquired, and adults who are "wall-eyed" consider the deformity much less of a blemish than "cross-eye," and the slight consideration of the "beam in their own eye" is fostered in some cases by the fact that the eyes can be brought parallel long enough to observe an image in the mirror. Consequently, patients with divergence apply less often for treatment. Yet the facts remain that H and divergence are associated with more frequency than is generally supposed (see Nemier, *Recueil d'Oph.*, April 1890), that the myopic cases are usually associated with disease (if decided choroidal atrophy with greatly diminished V be counted with the other diseases), and that good V in both eyes is far less frequent in strabismus divergens than in strabismus convergens. In the former 1 case of Em and 2 of M of low degree had $\frac{20}{xx}$ OU; 3 of H, 1 with Am and 1 with irregular corneal astigmatism, had $\frac{20}{xxx}$ OU. Of the

other cases with known V, or lack of V, 20 were absolutely blind, while 45 others had V of $\frac{5}{cc}$ or less.

The influence of the refraction in the production of squint is involved in some obscurity. Among the 55 cases with divergence, classified as "emmetropia and refraction unknown," were many with $\frac{20}{xx}$ or $\frac{20}{xxx}$ vision in at least one eye which would no doubt have shown some H under atropine, while not one appeared to be myopic. Paralyses of the ocular muscles are of course not included among the cases treated of in this paper, as the term is ordinarily understood, yet essential muscular defects were frequent even in concomitant strabismus convergens. It will be seen that chronic diseases known to markedly affect central vision are frequently associated with squint, while not one case of chronic glaucoma appears in the list.

CONTRIBUTIONS TO CLINICAL OPHTHALMOLOGY: BEING GLEANINGS FROM MY CASE-BOOKS.

By SWAN M. BURNETT, M.D., Ph.D., Washington, D. C.

(*With eight illustrations.*)

MUCH valuable clinical material embodied in the histories of cases has been allowed to run to waste, because the observers did not deem the peculiarities or interesting features of sufficient importance to form the subject of a separate article for publication. It may have been that those points which attracted the attention of the observer were only single features of otherwise ordinary cases, and it was a question as to whether, after all, these features would be of the same interest to other practitioners; or it may be that they were of such a character as to be merely uncommon or *bizarre*, without any direct reference or suggestion as to pathology or therapeutics. And yet such cases may hold the key that is to unlock some of the treasures of knowledge still hidden from us. We are not yet in the position to ignore isolated facts seemingly small or insignificant; and there is not a single question in the whole range of ophthalmological studies in regard to which the final word has been said, and in respect to which some knowledge is not desirable; and it has seemed to me that if practitioners of experience were, from time to time, to publish a collection of such cases, recorded in a succinct manner, as have been interesting or novel in their eyes, we would be likely to find among them some nugget of knowledge which would be an addition to the golden granary of

ophthalmological science. With this opinion, then, I feel that no apology is necessary for offering the following cases for the perusal of my fellow-practitioners, premising only, in answer to a possible criticism, that I have considered that those cases which held sufficient interest for me to cause me to report them, would not be without an interest likewise to, at least, some others to read. No attempt has been made to go into the literature of the different subjects suggested by the clinical histories, and they are submitted simply as gleanings from my case-books.

Case I.

RETRO-BULBAR NEURITIS, WITHOUT DISCOVERABLE CAUSE; MARKED SHOT-SILK RETINA; CENTRAL SCOTOMA FOR RED; PECULIAR VISUAL FIELDS.

Webster Burke, a strong, healthy negro boy, was seen at my clinic for the first time October 15, 1887. He was then fifteen years old. He had first noticed a failure of vision about a month before. There was no history of any disease, and the only thing

FIG. 1.—Visual field of Webster Burke.

he had to offer in explanation of his trouble was a blow on the left cheek some six months previously. There was nothing at the time of this examination to account for the bad vision, which was only $\frac{3}{50}$ in either eye. The so-called "shot-silk" appearance of the retina was as pronounced as I have ever seen it,

though it is very common in the negro race. The ophthalmoscope showed him to be emmetropic, and the disk normal. As there were no general symptoms of any kind, he was treated expectantly. He reported at the clinic regularly for some months, during which time there were no changes, and was then lost sight of until November, 1891, when he again presented himself, and was thoroughly examined. His vision is now $\frac{2}{60}$ in either eye. The visual fields are peculiar. They are approximately normal, as to outer limits for white, as shown in the diagram, Fig. 1, and also for red and blue. Green he cannot distinguish at all, calling it always brown in every part of the field. There is a central scotoma for red in each eye, which is nearly circular, extending from 15° to 25° from the point of fixation. Inside of this limit he says that the red looks dark, but of no definite color. The patient is an intelligent boy, and neither drinks nor smokes. Very marked changes, however, have taken place in the optic nerves since the first examination. Both disks are now white, and slopingly excavated. There is no material change in the size or number of the retinal vessels, except that there are scarcely any capillaries on the surface of the disks. The shot-silk appearance continues the same.

The interest in this case consists, first, in the obscurity of the cause of the nerve atrophy. It was caused undoubtedly by a post-ocular neuritis, and began most probably behind the chiasma, but so far as we can rely upon the absence of symptoms it was an isolated pathological process. It is hard to conceive of the blow he received as having a causative connection with the atrophy since this was bilateral, unless we suppose a fracture of the *sella turcica*. Secondly, the visual fields are peculiar. To find an approximately normal field for white in such an atrophy and with such a low central vision, cannot be common. In addition, we have a field for red of normal extent, but with a central scotoma quite clearly defined, and an inability to distinguish green in any part of the field; but normal fields for blue and yellow.

How far the SHOT-SILK OR WATERED-SILK APPEARANCE OF THE RETINA is a pathological condition it is hard to say. I have attempted to give some idea of its appearance in the

drawing, Fig. 2. The whitish streaks are seldom seen along the sides of the vessel unbroken for any considerable distance, and their position changes with the slightest change in the position of the mirror. It can be seen to advantage only in the erect image. You quite frequently get a shimmer from the surface of the retina itself, independent of the vessels. Sometimes a small vessel seems to be broken up into a series of beads, and the vessels appear to be broadened at places. But the most remarkable change is in the macular

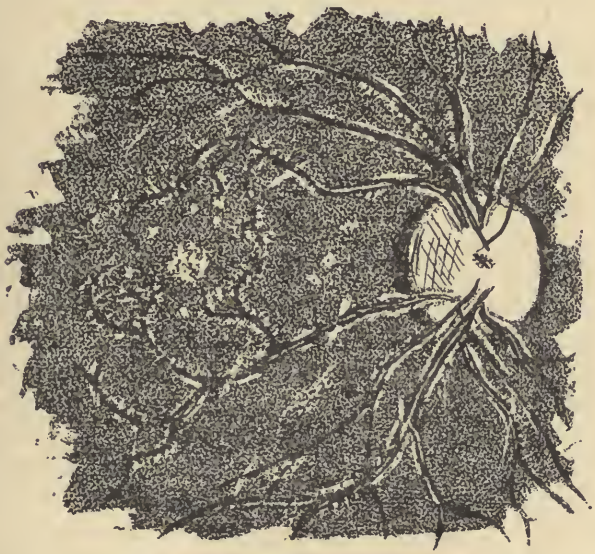

FIG. 2.—"Shot-silk" retina and white atrophy of the optic nerve.

region. Here, directly over the fovea, there is a spot having a diameter about equal to that of three veins of the first magnitude, of an irregular circular form, whose outlines are constantly changing with the slightest movement of the eye or the mirror. This must not be confounded with the halo around the macula which is so frequently seen in dark fundi particularly, though it seems to me that they both depend upon the same cause, namely, reflection from the hyaloid membrane. I have frequently seen it, however, on a small scale, in persons with much pigment directly at the yellow

spot. The reflex alongside of the vessels can be seen faintly on the surface of the white disk, but the width of the vessel itself appears much less on the disk than after its passage over on to the retina.

The most satisfactory explanation of this shot-silk appearance that I can offer is a thickening and opalescence of the hyaloid membrane, and I am disposed to regard it as pathological, or at least abnormal. In a recent paper on the ophthalmoscopic appearances in hypermetropia in the *Ophthalmic Review* for November, 1891, Mr. Bristowe offers the suggestion that the reflex which is more or less marked in certain cases of hypermetropia associated with arrested development, is due to a striated condition of the ganglionic cells of the retina, which remains over from the embryonal state. This view, it seems to me, is negatived by the fact that the appearance along the vascular walls is continued quite perceptibly on to the disk surface, where, of course, there are no ganglionic cells. The appearance which Loring speaks of on page 64, vol. i., of his text-book, is not the same as this, and is correctly, I think, accounted for by him as being due to increase of the normal connective tissue. That this appearance has any important connection with the nerve trouble in this instance we cannot say with positiveness, but I have one case in mind of a girl who has a low visual acuteness with emmetropia, in whom such a shot-silk appearance is very pronounced. In another case of a negro girl of ten there was associated with the shot-silk appearance a very contracted visual field in both eyes, most pronounced in the left. Her vision in this eye was $\frac{5}{12}$, in the right $\frac{5}{9}$, and the failure in vision was said to have been noticed after an attack of measles four years before.

Case II.

CYST OF THE IRIS.

John H. D., colored, aged thirty-five, was seen by me for the first time July 18, 1885. He stated then that eleven years before he had been struck on the right eye by a bit of steel, which cut the eyelashes and penetrated the cornea, carrying some of the lashes with it. The steel and, as he supposed, all of the hairs were

removed by Dr. Bacon of New Haven, where the accident occurred. The lens was gone, and some capsule still remained in the pupillary space, which latter was drawn into the cicatrix. A CILIUM WAS SEEN LYING IN THE ANTERIOR CHAMBER as shown in the diagram C, Fig. 3. He can barely see his way

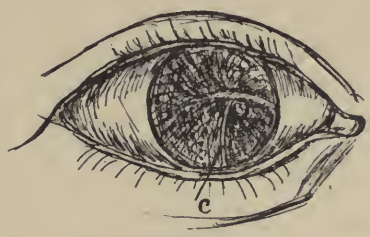

FIG. 3.—Cilium (C) in the Anterior Chamber.

about (the other eye was blind from optic atrophy following orbital cellulitis, an account of which I published in the ARCHIVES OF OPHTHALMOLOGY, 1885, p. 177).

On the 28th of September, I opened the anterior chamber, took out the cilium, and removed a piece of the iris, up to the dotted line of the drawing, Fig. 3. A discision of the opaque capsule was made later, which freed the pupil from the cicatrix, and with + 12 his vision was $\frac{4}{18}$. I saw him no more until February 18, 1887, when he came complaining of pain, which had begun about three weeks before, and a diminution of vision. I found some slight injection of the conjunctiva, and a state of things represented in Fig. 4. The lower and outer portions

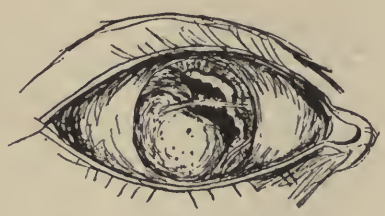

FIG. 4.—Cyst of the Iris.

of the anterior chamber were filled with a smooth clearly outlined body which looked not unlike a dislocated lens, whose surface was dotted with points of pigment. The lens being absent, I made the diagnosis of cyst of the iris. He was sent to Garfield Hospital, and on the 25th I made an incision with a triangular

knife below, evacuated the cyst, and attempted to remove the walls, but after the collapse they could not be identified. The piece of iris which appeared to contain the base of the cyst was cut off. The patient made a good recovery and saw fairly well. Eighteen months later there was no return of the cyst.

Case III.

LOSS OF EYE IN EARLY LIFE FROM INFLAMMATION (TRAUMATIC); SYMPATHETIC IRIDO-CHOROIDITIS MANY YEARS AFTER; ENUCLEATION OF THE ATROPHIC BALL; RELIEF TO THE IRIDO-CHOROIDITIS; FORMATION OF BONE IN THE VITREOUS OR RETINA, SPRINGING FROM THE OPTIC DISK.

It is much to be regretted that the detailed history of this case, taken during the patient's stay in the hospital, has been misplaced and cannot be found. As, however, its chief value lies in the pathological condition of the enucleated eye, I think it may not be without interest to give the general outlines of the clinical history as I remember it, to accompany the drawing of a section of the eye.

The patient was a mulatto, twenty-eight years old when he was admitted to Garfield Hospital in 1885. He was at that time suffering from an intense irido-choroiditis in the *left* eye, and had been for many weeks. He had had recurring attacks of inflammation in that eye for eighteen months or more, for which he had been treated by a surgeon, who, however, had never suggested the removal of the *right* eye, that had been lost in early life from an inflammation which he thinks began after an injury. The *right* eye was not inflamed, nor had it been for a very long time. It was quite hard, but there were no points sensitive to the touch. It was smaller than the other eye; the cornea was quite clear; the pupil closed, and the anterior chamber shallow. I advised the removal of the lost eye as the first step in the treatment, and it was readily assented to and done. Within forty-eight hours there was an amelioration in the intensity of the irido-choroiditis, which went steadily on to complete disappearance of pain and inflammation in the course of four weeks. Vision was very much impaired, and he was barely able to see his way about when he left the hospital. He has not been heard of since.

The eyeball, when opened by a cut at the equator, was found to contain a nearly globular mass, as hard as a bone, and it

seemed attached to the posterior pole of the eye. It was hardened in Müller's fluid, and in due time, after decalcification, some beautiful sections through the entire globe were made by Dr. Gray at the Army Medical Museum. A drawing of one of these sections through the optic nerve is given in Fig. 5. There is a mass springing from the optic-nerve entrance which contains what are undoubtedly the elements of bone, and between the Haversian canals there are the distinctive cells of adipose tissue. The lens has disappeared, but the anterior capsule remains. There are bands of pigment running down from the ciliary body towards the neoplasm, but do not reach it. There are a few pigment

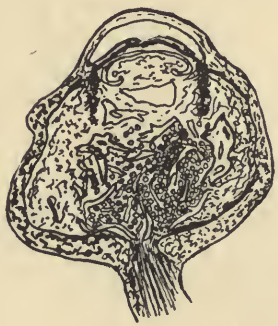

FIG. 5.—Formation of bone in the eye, starting from the optic-nerve entrance.

granules near the apex of the bony mass, otherwise it is free. The sections showed the mass to be a solid, and not a shell, and it touched the walls of the globe at no place except the optic-nerve entrance.

Clinically this case is of interest as another instance of sympathetic ophthalmia setting in many years after the loss of the fellow-eye; for that the irido-choroiditis was sympathetic can hardly be doubted, since it began to improve immediately upon the removal of the degenerated ball; and had the surgeon who saw him in the first place removed the offending cause, that would have ended the whole trouble, and the vision in the remaining eye would have been saved. It also substantiates the opinion that intra-ocular bony formations always, in time, bring about sympathetic trouble in the other eye. Such cases tend to deepen rather than to clarify the mystery of the pathogenesis

of sympathetic troubles generally, though this particular case would seem to support the migratory theory, since the attachment of the bone to the optic-nerve entrance would be more likely to set up a disturbance in the nerve itself, which might be transmitted along the nerve through the chiasma, and to the nerve of the healthy eye. But here we have, as the prominent symptom at least, the irido-choroiditis as we usually find it in sympathetic ophthalmia. That the cause is microbic must be seriously questioned, unless we are prepared to admit the very prolonged vitality in germs remaining in a quiescent state.

FORMATION OF BONE in the eye is most commonly found in connection with inflammation in the choroid, and often as a shell occupying the position of that membrane. We find occasional mention in literature of cases in which this connection with the choroid seems to be doubtful. I am not able to recall any recorded instance, however, in which the bony growth appeared to originate from the optic-nerve entrance, as it undoubtedly did in this case. It almost seems as if the detached and degenerated retina had undergone this bony transformation, or else that it had taken its origin from the vitreous itself. Another feature of the growth which I do not think has been described in any other case is the presence of fat cells in large numbers.[1] The connection between these and the bony tissue is obscure, unless we regard it as the effort to complete the bony transformation by supplying it with marrow.

CASE IV.

TOTAL DISLOCATION OF THE LENS UNDER THE CONJUNCTIVA TO THE NASAL SIDE FROM A BLOW; REMOVAL; PRESERVATION OF THE EYEBALL.

A man of forty-five years was admitted to the Providence Hospital on September 20, 1891, with the history that while splitting kindling-wood two days before a piece flew up and hit him on the right eye.

When I saw him there was swelling of the lids, intense bloody

[1] I have found, since this has been in type, that De Wecker figures a bony formation in the eye in his text-book, 1889, in which there are a few fat cells. He credits the observation to Haase.

chemosis of the ocular conjunctiva, with a large ill-defined swelling to the nasal side of the cornea. The cornea itself seemed clear, but the anterior chamber was filled with blood. Tension was much reduced, and there was great pain. It looked as if there had been an extensive rupture of all the coats of the eyeball, and the prognosis seemed unfavorable for preserving the globe. It was determined, however, to attempt to save it. He was placed in bed, hot antiseptic dressings were applied, and pain quieted with anodynes. In a few days improvement began to show itself, and at the end of two weeks the eyeball was comparatively clear and presented the appearance shown in the drawing, Fig. 6. The large tumor with a circular outline to the nasal side of the cornea I took to be a dislocated lens. The pupil reached up to the inner edge of the cornea on that side and was irregularly triangular in shape. The tension had increased somewhat. I resolved to remove the dislocated lens from under the conjunctiva, and on the

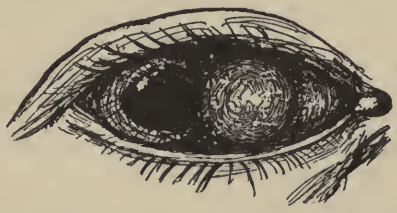

FIG. 6.—Dislocation of the lens under the conjunctiva.

5th of October I did so by making a longitudinal incision in the conjunctiva over it. A quantity of soft lens substance immediately came out. The nest which the lens had made for itself in the tissues was thoroughly cleansed by a spoon and irrigation. There was no escape of vitreous, showing that the scleral wound had perfectly healed. The eye was made thoroughly aseptic and bandaged. No reaction followed. The conjunctival wound healed nicely and when examined on the 28th of October tension was almost normal. The anterior chamber was muddy with the remains of hemorrhage. The inner side of the cornea is bulged considerably forward; no reflex from fundus; no pain.

In this connection I give a sketch of

CASE V.

A CASE OF PARTIAL DISLOCATION OF THE LENS UNDER THE CONJUNCTIVA UPWARD.

T. H. M., age forty, presented himself at my clinic on February

18, 1890, with the history of a blow on the right eye some days before. An examination showed a tumor at the upper sclero-corneal margin which proved to be the lens, a portion of which was evidently still engaged in the scleral rupture, Fig. 7. There

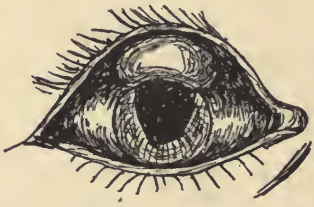

FIG. 7.—Lens engaged in a scleral rupture.

was a retroversion of the iris at the location of the wound. The pupil was black, but there was no reflex from the fundus. There was but a small amount of congestion of the conjunctiva. He promised to return and have the lens removed, but failed to come and has not been seen or heard of since.

CASE VI.

SUCCESSFUL EXTRACTION OF A FLOATING DEGENERATED LENS FROM THE VITREOUS CHAMBER.

A negro man sixty-nine years old was admitted to the Providence Hospital for mature senile cataract of the right eye on June 11, 1891. This was extracted successfully without iridectomy, and the healing was normal and the result satisfactory. There was no accident during the operation, though the vitreous was evidently fluid. The left lens, perfectly and uniformly white, was floating in the vitreous humor, and he reported that the eye had been bad for a great many years. When the lens was not behind the pupil he could see, and this was all the vision he had during the maturing of the cataract on the right eye. The tension was a little below the normal. He expressed an earnest desire to have this eye operated upon also, though warned that the result was very doubtful. On the 10th of June I extracted the floating lens in the following manner :

The assistant held the upper lid gently with his fingers against the orbital edge. I fixed the ball with the forceps just below the vertical meridian of the cornea and made puncture and counter-puncture with a Graefe knife as in ordinary extraction. As soon

as the counter-puncture was effected, and there was an escape of aqueous, I made firm but steady pressure with the fixation forceps directly backward. This threw the lens forward into the pupil and thus prevented an escape of the vitreous until the completion of the section, when the persistent backward pressure delivered it through the pupil with a gush of fluid vitreous. We were prepared for this, and as soon as the lens was thrown out the assistant quickly dropped the upper lid, and the bandage was immediately applied. The dressing was not disturbed for five days, and when the eye was opened at the end of that time the corneal wound was found well united, with an entanglement of the iris, however, as was expected. There had been no undue reaction, and there was, and is yet, quite an amount of vision. The lens, which came out in its capsule, was found to be entirely fluid, and rolled about like a drop of water. Unfortunately, while manipulating it, though very gently, the capsule burst and the contents, which seemed clear, ran out and not a trace of nucleus was visible. The capsule also was quite transparent.

In addition to the interest attaching to a successful extraction of a floating lens, the condition in which the lens was found, I think, affords a possible explanation of the sudden disappearance of some long-standing cataracts, of which we now and then have accounts. It would be very easy in a case like this, by a sudden jar or by a continuance of the regenerative process, for the capsule to have ruptured, when the contents would diffuse itself readily in the fluid vitreous. It might be advisable in such cases, for the attainment of this end, to prick the lens with a needle. I have used the bident devised by Dr. Agnew three times in extracting lenses dislocated into the anterior chamber, but I deem the method I employed in this case preferable for lenses floating in the vitreous.

Case VII.

CHEMOSIS OF THE CONJUNCTIVA AND LID CAUSED BY THE INGESTION OF A SINGLE GRAIN OF QUININE.

The vagaries of quinia intoxication are very great, and one of the most interesting in its effects on the eye that I have seen is the following:

Mrs. W. H. R., age thirty-two, came on March 6, 1891, with a marked clear chemosis of the outer part of the bulbar conjunctiva and the lower lid of the right eye. On making inquiry as to the cause she stated that an hour before she had taken one grain of sulphate of quinia. It appears that she has always been peculiarly susceptible to the influence of quinia. In early life, whenever taken in any quantity it produced urticaria. Three years ago, however, she was able to take it without any unpleasant manifestations, but one year ago her physician, Dr. Busey, prescribed four grains, and in one hour it was followed by a marked chemosis of the lids and conjunctiva of both eyes. This subsided in about two days. It was looked upon as a mere coincidence, and some months later the quinia was repeated with the same result as regards the chemosis. This morning at nine o'clock she ventured to take a single grain with the result as described. Vision was not impaired, and there were no unpleasant general manifestations. The chemosis subsided in about forty-eight hours.

Case VIII.

PERIODIC CONGESTION OF THE CONJUNCTIVA FROM VASO-MOTOR DISTURBANCE.

Mrs. J. W. B. I saw first March 3, 1884, on account of congestion of the conjunctiva which had come on suddenly the day before. There was no discharge of mucus or pus, but quite a flow of hot tears. The congestion of the conjunctiva was quite marked and mostly pericorneal, and the eye generally had a suffused look. The conjunctiva of the lids participated very little in the congestion. The iris was normal. There was some photophobia but no decided pain. She states that she has had occasional attacks like these during and since the climacteric period ; she is now over fifty. They are always preceded by some nervous disturbances, the principal of which are coldness of the extremities and drowsiness. They have been known to follow nervous excitement or strain. These attacks have been treated at different times as iritis and conjunctivitis by means of leeches, astringents, etc. The attacks generally last about three days. Sometimes one eye is affected and sometimes the other, very seldom both at once. There is always a feeling of heat, and a flushing of the side of the head corresponding to the eye affected.

They would occur sometimes as often as every two months, but once she was free for two years. She has slight hypermetropia in the right and a hypermetropic astigmatism of 0.5 in addition in the left.

There can hardly be a doubt that the congestion in this case is due to a disturbance in the vaso-motor nervous system, though an exact connection with the cause cannot be made out beyond its association with the climacteric disturbances. Of late years the attacks have become much less frequent and severe, owing most probably to the fact that her general health has been much improved by rest and travel.

Case IX.

WRINKLING OF THE CORNEA.

That the nutrition of the eye is interfered with to such an extent as to cause a contraction or wrinkling of the cornea in certain cases of general malnutrition is well known, but I do not think it is generally recognized that an inflammation, confined to one eye, will bring about such a change in the corneal outline. It is very probable, however, that if we examined eyes in a state of inflammation by means of the keratometer more frequently, such changes in its curvature would be observed oftener. The most marked example of this that I have observed is as follows:

Mrs. L. S. F., age twenty-five, was first seen March 21, 1889. There was then a good deal of suffusion of the right eye, with pain, which had existed for several days; it was somewhat sensitive to touch. She had had an inflammation in that eye some years ago. The cornea was, at the time of the examination, perfectly transparent with no sign of present or past inflammation. Vision in the right eye was $\frac{5}{12}$, in the left $\frac{5}{6}$, and in the latter was increased by — 0.5 180. No glass improved vision in the right. The ophthalmometer gave, in the left, a curvature corresponding to 40.5 D in the horizontal, and 39.25 D in the vertical meridian. In the left it gave 40 D, but the image was very irregular. Examination with Placido's disk gave the image as shown in the drawing, Fig. 8. The peculiarity of this image is that, though

the lines are approximately circular as they are in the normal cornea, they are almost regularly fluted. I have frequently seen parts of a line or lines of this form in corneal troubles, but never, as in this case, throughout its whole extent and affecting all the circles. The skiascope did not show any amount of irregular astigmatism, but the ophthalmoscopic picture was not as clear

FIG. 8.—WRINKLING OF THE CORNEA.

and distinct as in the other eye. The iris was normal, tension slightly reduced. About a week later a circumscribed keratitis developed in this eye, which ran a rather slow course, but ultimately resolved itself perfectly. An examination on December 14th showed that the cornea was of normal transparency and vision was nearly $\frac{5}{5}$, while the keratoscopic and ophthalmometric examinations gave absolutely nothing abnormal.

It seems probable that we had here to deal with a mild cyclitis which was, however, sufficient to lower the tension and diminish nutrition to such an extent as to destroy the normal elasticity of the cornea.

(*To be continued.*)

ON CONGENITAL COLOBOMA OF THE OPTIC NERVE.

By Prof. W. MANZ, Freiburg, Baden.

Translated by Dr. Ward A. Holden, New York.

(*With Figures 1–4, Plates I. II., and figure c, Plate III.*)

In his account of the development of the eye[1] von Ammon described a peculiar condition of the optic nerve in a sheep-embryo under the name "Coloboma nervi optici," and gave a drawing of it. The observers who first saw this condition with the ophthalmoscope found that the cleft was not in the nerve proper, but in its sheath.

The ophthalmoscopic picture in the uncomplicated cases, of which perhaps twenty have been reported,[2] is on the whole similar, so that the diagnosis is not difficult. There is an excavation at the papilla, with strongly reflecting walls, for the most part bounded by a pigment layer of varying breadth. This excavation may be from two to twenty times the size of the transverse section of the nerve. The depth of the depression varies in different positions, but, as a rule, is greatest below.

This may also be the case when the papilla is not much enlarged, but is near a coloboma of the choroid; then there is a partial eccentric excavation such as that described by Jaeger.[3] These small and, for the most part, sharply limited excavations in the disc have been frequently observed of late, but they are not always situated downward, and

[1] "The Development of the Human Eye," *Graefe's Archiv*, vol. ix., p. 42.
[2] See Makrocki, *Arch. f. Augenheilk.*, vol. xx., p. 29.
[3] *Ophthalmoscopic Hand Atlas*, p. 148.

therefore may not have always the same significance with reference to the development of the optic nerve.

With Caspar[1] I am of the opinion that the condition of the vessels gives us a clue to the structure of the coloboma. In this respect we may differentiate two sorts of coloboma, that in which the central vessels emerge from the middle of the excavation, and that in which they first appear at the margin. A typical coloboma of the nerve, which I saw some years ago in the left eye of a boy of fourteen, was of the first category. The four vessels emerged from the deep central portion of the white figure, and were distributed with a certain amount of symmetry to the four quadrants of the fundus, no anastomoses between them being found.

This condition, which has been seen in some other cases, differs from the majority, of which the case to be described is an example (Fig. c, Plate III.). Here almost all the vessels appear at the periphery or quite at the margin, none being seen in the middle; or they pass from some portion of the margin over the coloboma, as in this case, from below upward. This latter condition has been explained by anatomical examination; the former has not been so explained as yet, and our idea of the form and structure of the intra-ocular end of the optic nerve in these cases is still hypothetical. Caspar also divided the cases into groups with respect to the arrangement of the vessels, but gave a third variety in which the vessels appeared in the neighborhood of the upper margin, which resembles more nearly the condition in those cases in which the disc lies at the upper margin of a coloboma of the choroid, and the greater portion of the vessels run first in a characteristic way to the upper portion of the retina. Between this form and the second named above there is this great difference, that in one the central vessels run in the optic nerve, and in the other, outside the nerve.

From these introductory remarks I shall proceed to the description of the eyes which I have examined anatomically. For the human eye I am indebted to the kindness of

---

[1] "On Coloboma of the Optic Nerve," *Inaug. Dissert.*, Bonn, 1887.

Professor Pflüger of Berne, and to Dr. Eissen assistant to the Berne eye-clinic for the clinical notes accompanying it, and the ophthalmoscopic drawing which is reproduced here.

P. A., a farmer, aged twenty-five, was admitted to the medical clinic with phthisis pulmonum. The patient had had poor vision from childhood, and was sent to the eye-clinic for examination.

Both eyes were of normal size, the cornea, lens, and vitreous clear in each, the pupils responsive to light.

The ophthalmoscope showed in the position of the disc a fairly round white field (Fig. c, Plate III.) excavated in varying degree in different portions. The functional examination of the eye gave a myopia of 6 D, while with the ophthalmoscope the myopia was 10 D in the middle of the coloboma, and from 13 to 14 D near the lower margin. The coloboma is surrounded above, below, and to the inner side with a white ring, which at its inner and outer margins is pigmented; at its inner side there are irregular patches of pigment in the coloboma itself. The greater portion of the coloboma is of a glistening white color, and the lower portion is funnel-shaped and its margin sharply marked.

The retinal vessels which come from below bend abruptly at the margin of the funnel and vanish into the depth of it, as in case of a marginal excavation; and the vessels which descend from above seem also to take their course in the funnel.

In the periphery the fundus is uniformly red and shows no pathological changes.

The patient died, and the eye was enucleated twelve hours after death and put into Müller's fluid. The hardened ball had the following diameters: sagittal 27 *mm*, transverse 27 *mm*, and vertical 26 *mm*. The corneal diameters were: transverse 13 *mm*, and vertical 11.5 *mm*.

Connected with the ball was a portion of the optic nerve 15 *mm* long; with its sheath its diameter was 5 *mm* at its insertion, and 4 *mm* at its central end; without its sheath its diameter was 3.5 *mm*.

Exteriorly the ball appeared well-formed excepting a slight prominence below the entrance of the nerve. After being rehardened in alcohol the ball was divided by an

equatorial section, and the posterior half drawn, double the natural size (Fig. 1, Plate I. II.).

As the drawing shows, there is an excavation at the disc, 4.5 *mm* high and 4 *mm* broad, with a sharp margin below and at the sides.

The upper margin is formed by a thick elevated fold which spreads out fan-shaped into the retina. At either side of this elevation the floor of the excavation is red and translucent. The ball was then cut at right angles to the previous section, the knife passing through the centre of the nerve entrance, when the relation of the nerve to the coloboma could be made out with a loupe. The nerve, as seen in Fig. 2, lies only in the upper portion of the coloboma, and joins the sclera above in the normal manner, but below there is a broad space between it and the scleral margin. The foramen scleræ posticum is therefore markedly widened, measuring 5 *mm*, while the diameter of the optic nerve at the lamina cribrosa is only 2 *mm*. The lower larger portion of the foramen is filled with an areolar tissue which lies behind the plane of the inner surface of the sclera. This tissue consists for the most part of coarse and fine tracts of connective tissue, which in the middle layer cross and intermingle, leaving open spaces of varying size and form, the larger ones distinguishable macroscopically. Many of these cavities, which rarely have an endothelial lining, communicate with one another, and are separated only by thin septa. These cysts lie mostly near the inner surface of the coloboma, some, however, deeper in the angle between the optic nerve and the sclera, but all in the lower portion of the ball. A particularly large cyst (*c*) lies at some distance from the nerve, on the outer surface of the sclera, which latter, with its predominating longitudinal fibres, is of a closer texture than the areolar tissue lying on it.

This tissue runs from the nerve across beneath the sclera and into the retina, and at this point the sclera projects over the coloboma, forming the sharp margin seen with the ophthalmoscope.

The upper margin of the scleral opening, of normal form, compresses the optic nerve just within the well-developed

lamina cribrosa, and the fibres of the nerve pass for the most part upward, a few passing downward over the coloboma.

As the number of nerve fibres varies in different preparations, we must assume that the fibres passed the lower margin of the coloboma in isolated bundles. This is of importance in explaining certain functional disturbances which are found with this malformation. While the central acuity of vision is more or less reduced, in some cases, as *e. g.* in these reported by Nieden,[1] there is a sharply limited defect in the upper portion of the visual field, reaching to the point of fixation.

The microscopic examination in our case showed that there had not been a defect in the lower portion of the field, as the portions of the retina above and below the coloboma were not particularly different. In both locations the layers of the retina showed their normal arrangement, and were equally thick; the layer of rods and cones was present, as was also the layer of nerve cells above the nerve-fibre layer.

Choroid and pigment epithelium were normal, or showed merely irregularly formed clumps of pigment at the margin of the scleral opening, explaining the single or double pigment girdle of the coloboma that was seen with the ophthalmoscope.

The central vessels did not run in the nerve but beneath it, partly in its external sheath, partly between the external and internal. Here were found a number of vessels, cut obliquely and transversely, having thick walls, and in calibre somewhat exceeding the normal central artery. Some of these vessels lay in the sheath of the nerve, others outside; almost all, however, perforated the floor of the coloboma, reached its inner surface low down, and gave off branches running in the disc and over the lower margin of the coloboma. In the optic nerve itself was but a single small twig entering below and running near the neurilemma toward the lamina cribrosa.

The microscopic examination thus proved what the ophthalmoscope had made seem probable, that the central

[1] "Four Cases of Coloboma of the Nerve Sheath, without Clefts in the Uveal Tract," these ARCHIVES, viii., p. 501.

vessels did not pass to the retina from the optic nerve, but from outside it. What was found here holds good for all the cases in which the vessels appear in a similar manner behind the margin of the coloboma. H. Becker,[1] found a similar condition of the vessels in the case which he examined microscopically.

The position of the central vessels seems of importance in the genesis of this malformation. The optic furrow may close without having included the vessels, not, however, without retaining evidences of such abnormal closure. In this case the sheaths of the optic nerve were abnormal. The conditions might probably have been more clearly studied in transverse sections, but they are clearly recognized in the longitudinal. The dural sheath near its insertion is thicker (0.15 *mm*) than the normal, but it is particularly thick below and passes over into the connective tissue, which fills the angle between the optic nerve and the sclera, forming the floor of the coloboma. The inner sheath, here 0.03 *mm* thick and separated from the outer sheath by a broad intervaginal space (0.15), extends to the lamina cribrosa.

The structure of the optic nerve is normal, as is also that of the anterior segment of the ball.

The abnormal features in this eye were limited to the anomalous entrance of the optic nerve, and in fact to the nerve sheaths, which form the lateral connection between the nerve and the ball; we have then a coloboma of the sheaths of the nerve with which the nerve proper is only indirectly concerned.

An analogous condition has been found in three other eyes that have been examined anatomically. Liebreich first published an ophthalmoscopic drawing of such a case,[2] and examined two such eyeballs in Arlt's clinic. The sections explained the ophthalmoscopic picture; the sheath of the optic nerve beneath the disc before passing over into the sclera was widened out into a deep pocket, over which stretched a membrane proceeding from the nerve,

---

[1] "A Case of Microphthalmus Congenitus Unilateralis," *Graefe's Archiv* vol. xxxiv., p. 105.

[2] *Graefe's Archiv*, vol. v., p. 246, Liebreich, *Atlas*, Plate XII., Fig 4.

while the margin of the excavation was continuous with the sclera bounding the nerve above. As no microscopic examination was made, the nature of this membrane was not explained, but Liebreich believed that although continuous with the optic nerve and retina, it contained no retinal elements.

Falchi [1] has recently described a case of hydrophthalmus, having what he called a coloboma of the optic nerve. His case resembles mine in some respects, but there are important differences between them, so that I am not certain that his case should be considered one of coloboma of the sheath.

The second case of coloboma of the optic nerve that I examined anatomically was in a white rabbit, in which the malformation was discovered by accident. The condition existed in each eye, in the right being accompanied with a change in the vitreous which with the ophthalmoscope appeared to be a posterior polar cataract with a persistent hyaloid artery, a diagnosis which was only partially confirmed by the autopsy.

The eyeballs appeared normal exteriorly, the anterior chamber being somewhat deeper perhaps than is usual in the rabbit.

In the left eye the media were clear. In the position of the disc was a large, deep, nearly circular excavation, sharply limited from the surrounding parts. The network of vessels which borders the lower margin of the disc in the rabbit, was here below the lower margin of the coloboma, in which were but a few small vessels.

In the right eye the changes in the disc were similar, but being veiled by the opacity of the vitreous were not so clearly seen.

In the enucleated balls there was a conical prominence of 5 *mm* near the posterior pole, and a thinning and stretching of the sclera beneath the disc. When the right eye was opened behind the equator, a white cord containing a vessel filled with blood was seen running from the nerve to the

[1] "On Acquired Hydrophthalmus," *Beitr. z. path. Anat. und allg. Path.*, Ziegler, vol. vii., p. 411.

lens, being continuous below with a delicate membrane which passed through the vitreous to the retina (Fig. 3, Plate I. II.). A number of sections showed this cord ending free in the vitreous as in the figure; some preparations, however, showed its continuation and end, the latter being of two varieties: either the cord bent sharply and spread out into a lamella showing retinal structure, or the transition occurred at the point of bending without the lamellar spreading. This remarkable portion is shown highly magnified in Fig. 4, Plate I. II. The cord-like structure is seen to broaden gradually at the turn and finally to become transformed into the various layers of the retina.

Coloboma of the nerve and nerve-sheath has a further interest because of its relation to another anomaly which has but recently received much attention, viz., conus inferior. Since it was found to be congenital, it has been proved to be due to a defective closure of the fœtal ocular cleft. I would refer the reader particularly to the publications of Schnabel,[1] Vossius,[2] Van Duyse,[3] and Fuchs,[4] who have supported this view, and have found disturbances of vision and limitations of the visual field with conus inferior, showing that the distribution of the nerve fibres in the retina is not normal.

The fact that these coni are found in the region of the nerve entrance and are therefore not to be considered small choroidal colobomata, is shown by the frequent anomalies in the ramification of the central vessels, and the different ces in the level of the disc.

Whether congenital coni of this sort are also found at the temporal side of the nerve, as many claim, and whether these different positions are due to a turning on its axis of the fœtal eyeball (Vossius), are questions which cannot yet be answered, and for the solution of which more extended embryological and histological studies must be made, particularly as regards the macula lutea.

---

[1] "On macular Coloboma," etc., *Wiener med. Blätter*, 1884, No. 6–9.

[2] "Contributions to the Study of Congen. Conus," *Zehender's klin. Monatsbl.*, vol. xxiii., p. 137.

[3] "Contributions to the Study of the Anomalies of the Optic Nerve," *Ann. d'Oculist.*, vol. xcii., p. 44.

[4] "A Contribution to the Congenital Anomalies of the Optic Nerve," *Graefe's Archiv*, vol. xxviii., p. 139.

Explanation of the Figures.

PLATE I. II.

Fig. 1. Front view of the disc in the human eye.

Fig. 2. Vertical section through the coloboma in the same eye : *r* retina ; *ch* choroid ; *scl* sclera ; *c c c* cysts ; *v v v* vessels.

Fig. 3. Vertical section of the nerve entrance in the rabbit's eye : *r* retina (pigment epithelium, red); *ch* choroid; *o* optic nerve ; *l* lens.

Fig. 4. The same eye. The vitreous cord passing over with the retina : *f* cord in vitreous ; *r* fragment of retina ; *c* cysts in the retina.

PLATE III., FIG. C.

Ophthalmoscopic picture (erect image) in the human eye.

DETACHMENT OF THE CHOROID.

By Dr. ANTON ELSCHNIG,

ASSISTANT TO PROFESSOR SCHNABEL, GRATZ.

Translated and abridged by Dr. J. A. Spalding, Portland, Me.

(*With one figure—Fig.* 5, *Plate I. II.*)

IT is a very remarkable fact that clinical morbid pictures which were observed and carefully studied, and zealously followed up in the early days after the discovery of the ophthalmoscope, do not seem ever to have been seen again, and that at a time when the practical side of ophthalmoscopy has never before been so scientifically and ardently pursued. Thus, for example, as far back as 1854, Jaeger accurately described an ophthalmoscopic image of stasis of the vascular system of the retina.[1] But although a few observers have seen an image bearing some slight resemblance to that of Jaeger, yet in the totality of all the symptoms not a single ophthalmoscopist has since that early date described an image that could be reasonably regarded as precisely similar to that which this learned surgeon has given to the world in his reports.

v. Graefe and Liebreich in 1856 or 1857 described detachment of the choroid as a morbid condition in which without the slightest alteration in the external form and nature of the eye, and with preservation of perfectly normal tension of the globe, a firm, smooth, precisely circumscribed globular nodule resting on the sclera, and with a rather nar-

[1] "Ueber Staar und Staaroperationen," p. 104, and "Ergepnisse der Untersuchungen mit dem Augenspiegel," 1876, p. 100.

row base, and covered with choroid and retina, is developed within the eye. It may rise 6 *mm* above the level of the sclera, grow with great slowness, is next followed with detachment of the retina and terminates in softening and phthisis of the globe long since rendered blind by the disease.[1]

Since then but few cases have been reported, among which are first that by Knapp (Intraoculare Geschwuelste, 1868, pp. 194–200), who extracted with partial loss of vitreous a dislocated lens in its capsule from the eye of a man of forty-six. Five weeks later, after the incision had spontaneously opened in the third week after the operation, and perception of light had entirely disappeared, there came to view in the vitreous, and close behind the plane of the pupil, three brown globular masses with a velvety surface, which, resting in the ciliary region, touched one another, and totally hid the upper and inner portion of the vitreous.

As the case seemed to be one of choroidal sarcoma, the eyeball was enucleated, when the tumors were found to represent detachment of the ciliary body and of the anterior portion of the choroid from the sclera, due to the presence of a transparent fluid.

De Wecker, Michel, Berger, Hjort, Hay, Walter, and Groenouw have described similar cases ophthalmoscopically, but none of them corresponded precisely in all their features with the image given us so long ago by v. Graefe and Liebreich.

The following case was observed at three different periods, with long intervals between, during the space of eight years, and for the first time just after the beginning of the visual disturbances, when the alterations were already considerable, but before the detachment had made its appearance, while at the second and third periods the nodule covered with the choroid and retina had already attained considerable size, and exhibited in the most beautiful manner all of the characteristics described so minutely by the first observers.

---

[1] *v. Graefe's Archiv*, Bd. iv., Abt. 2, p. 225, and Bd. v., p. 259, and in *Liebreich's Atlas*, Text, p. 18, and Plate VII., Fig. 6.

Michael K., aged forty-five, was first seen March 1, 1882. Left eye externally normal, media transparent, optic papilla rather more pallid than usual, but with normal contours, retinal vessels normal. The region of the macula is covered with scattered, irregular, yellowish, glittering spots. Outward from the papilla, and about half a papilla diameter distant, is an irregularly shaped whitish-green patch of about two papilla diameters, in which the retinal vessels are at one spot indistinct, then hidden entirely from view, and then again starting up into plain view. The entire patch, which bears the appearance of swollen retina, is marked by various differences in level.

The right eye is entirely normal.

Diagnosis : Retinitis of the left eye.

Nearly seven years later, January 4, 1889, the patient returned for a second examination. Since his first visit the sight of the left eye has slowly and steadily diminished, though there has never been any sensations of pain in the eye.

The central portion of the visual field is absent over a circle of from 30° to 40° in diameter, but in the remaining ring-shaped zone, not only are fingers counted at a short distance, but in the superior and middle portions of the field large red and blue squares of paper are distinctly recognized.

After remaining a short time in the hospital the patient disappeared from view till January 2, 1890, when at our request he once more presented himself. He reported that the sight had been totally lost soon after his last visit, but that otherwise there had been no change in the eye.

The ophthalmoscopic image, as seen on January 4th, is depicted in Fig. 5. The posterior portion of the vitreous exhibits a structure completely solid and immovable, slightly transparent, rather oval in shape, and projecting forward into the vitreous to a considerable extent, just below and to the temporal side of the papilla. It is about six papilla diameters across, and four in vertical measurement. As calculated by the aid of the refraction ophthalmoscope, it projects nearly 6 *mm* into the vitreous above the level of the retina. It is covered scantily with vessels and pigment. The margin is overhanging, so that the base of the nodule cannot be seen with the ophthalmoscope. The retina is detached at a little distance from the margin, and exhibits the usual image of that condition. At other portions of the fundus the retina lies in place. The vitreous, close around the margin of the prominence, is filled with fine opacities.

The tension of the right eye is normal, that of the left subnormal.

The only observable alteration during a month's sojourn in the hospital was a slight increase in the retinal detachment.

The only change between the first and the second visit was to be seen in the increased elevation of the growth, and the serous infiltration in the retina.

January 5, 1891, the patient came once more, the eye now being distinctly smaller than the other, and the retina exhibiting hemispherical detachment in three places in the fundus.

If now we think over the history of this case we notice that at the spot where, in 1889 and 1890, v. Graefe's and Liebreich's ophthalmoscopic image was well defined, a distinct inflammatory condition of the retina (retino-choroiditis) had been observed seven years before. Hence the case before us belongs really to the broader group of retino-choroiditis, and we feel justified in including the cases reported by v. Graefe and Liebreich, as well as that of Berger, under this title.

In v. Graefe's second case the detachment occurred suddenly, and produced almost instantaneous blindness. v. Graefe that there could be little doubt of the accuracy of what the patient asserted, because he was an officer accustomed to gunning, and in the habit of frequently using first one eye and then the other. For that reason, then, he thought that the trouble was of an apoplectic nature.

Pathogenesis of the Detachment of the Choroid.

A circumscribed retino-choroiditis with a moderate amount of exudation occurs in the choroid and between the latter and the sclera, so that the choroid is raised in a flat surface from over the sclera. The choroid with the retina in the immediate vicinity of the inflammatory focus becomes intimately agglutinated with the sclera by the action of the products of the chronic inflammation. At the same time, the inflamed portion becomes encapsulated. Ultimately, if the inflammation and the exudation persist, both of the inner membranes of the eye must necessarily be pushed forward into the vitreous in the form of a nodular swelling.

The intimate union of the choroid with the sclera in the neighborhood of the focus of exudation alone causes the nodular form of the detachment, and prevents it from extending over a greater extent of surface of the fundus of the eye.

When finally the disease has reached the same intensity, as in the case so often cited from v. Graefe and Liebreich, and indeed in our own case, the circulatory and nutritive disturbances which it excites in the rest of the eye produce a deleterious detachment of the retina, while the diminution in the size of the eye closes the scene.

A CASE OF SARCOMA OF THE CORNEA.

By Dr. KONRAD RUMSCHEWITSCH, Kiew.

Translated by Dr. Ward A. Holden.

(*With Figure 6, Plate I. II.*)

IN 1870 Classen (*Arch. f. path. Anat.*, vol. l., p. 56) distinguished two principal forms of corneal neoplasm, melanotic sarcoma, and epithelioma, which always develop in the region of the limbus conjunctivæ. Later investigators have confirmed his views. Benign tumors of the cornea are of extreme rarity. The case which I shall describe is of particular interest as the malignant growth developed in the cornea proper.

A peasant, aged sixty-one, received a blow on the head a year and a half ago, which was followed by hemorrhage from the right eye and ear, and loss of consciousness; the sight of the right eye failed somewhat. A year ago he was again struck on the right side of the head and there was again hemorrhage from the right eye; vision was entirely lost and the eyeball began to protrude through the palpebral fissure so that the lids could not be closed.

A soft, smooth tumor protrudes through the palpebral fissure. The ball preserves its mobility and its perception of light. The eyelids are normal, the conjunctiva is pale, the limbus slightly hyperæmic and thickened. A sound can be passed at some points between the tumor and the margin of the cornea.

The eye was enucleated. The further history of the patient was not obtained.

The enucleated ball was hardened in Müller's fluid and later in alcohol. Fig. 6 shows a horizontal section of the anterior segment of the ball. The tumor has a fairly uniform thickness, becoming a little thinner toward the margins. In the sections radiating stripes may be seen with the naked eye.

The upper half of the ball was imbedded in celloidin and the lower in paraffin.

HISTOLOGICAL EXAMINATION OF THE TUMOR.

A. *Conjunctiva.*—The conjunctiva was thickened particularly in the upper outer segment. The epithelium consisted of ten or more layers. The cells of the lowest layer were of cubical form, in the following layers round or irregular, and in the outer layers flat. For a distance of 2 *mm* from the limbus, epithelial processes dipped down into the cornea, and at the corneal margin were well-marked papillæ. These papillæ consisted of loose connective tissue containing numerous round cells, particularly about the vascular network that was always present. Deeper there was a thick layer of still looser connective tissue with vessels and many cells. This layer became gradually thinner as it approached the corneal margin and was bounded from the latter by the epithelial processes which dipped down in the region of the limbus. The blood-vessels of the conjunctiva were much thickened, so that the conjunctiva resembled cavernous tissue. The vessel walls were of considerable thickness and were surrounded with few leucocytes, whereas the thin-walled vessels in the papillæ were surrounded with quantities of lymphoid cells.

The tumor approached nearer the corneal margin in the upper outer segment and more conjunctival vessels passed to it here than at any other point. The rôle of the conjunctiva in the development of the tumor was in furnishing the blood-vessels.

B. *The Epithelium of the Tumor and its Connection with the Cornea.*—The epithelium of the cornea passed uninterruptedly over upon the tumor, being thickest at its base. The blood-vessels ran beneath the epithelial layer, but after reaching the tumor they divided and the branches assumed a radiating direction. In the vascular portion of the conjunctiva there was little fibrillar connective tissue and few lymphoid cells. In the base of the tumor there was more loose connective tissue.

The inner margin of the epithelial demarcating layer, or rather the margin of the opening through which the tumor was connected with the cornea, was much thickened and in places uneven. Excepting in the upper outer segment of the cornea in which the nutrient vessels of the tumor entered, I found no changes either in Descemet's membrane or in the deep lamellæ, but in the superficial portion the lamellæ were loosely connected and there were many corneal corpuscles but no trace of leucocytic infiltration. Bowman's membrane was also fully preserved up to the margin of the opening, where it became interrupted and the portions which were preserved had an abnormal direction.

C. *The Constitution of the Tumor Proper.*—Horizontal sections stained with hematoxylin slightly magnified show the darkly stained demarcating epithelial layer with the opening about 3 *mm* in diameter. Just outside this, in the base of the tumor, was a layer of light violet color with prolongations 1½ *mm* in diameter, running out to the periphery of the tumor. In the temporal half of this layer were vessels from the conjunctiva, between which the connective tissue was better developed than in the vascular portion of the conjunctiva and cornea. In the nasal half of this layer fibres of the substantia propria of the cornea crossed each other in all directions, and few cells were present. External to this layer were the clear stripes which ran out in a radiating direction through the entire tumor. The remainder of the mass, stained darkly with hematoxylin, made up the tumor proper.

In the base of the tumor vessels and fibres of the substantia propria of the cornea crossed each other at all

angles. The bundles of fibres passed over into ordinary loose connective tissue in the tumor. Very little connective tissue entered the tumor with the vessels. The connective tissue with the vessels formed the stroma of the tumor which divide it up into fields of various sizes. In the mass of the tumor the vessels were mostly very small, and capillary vessels were found in considerable quantity just beneath the epithelial covering of the tumor.

At some points on the surface of the tumor degenerated blood was found in place of epithelium, and fresh hemorrhages were seen in the substance of the tumor proper. There was very little intercellular substance. The cells were of various forms. Near the clear stripes the sarcoma cells were small and spindle-formed with the long axis perpendicular to the surface of the cornea, and these made up the bulk of the tumor. Some round cells, apparently leucocytes, were found near the blood-vessels. In the base of the tumor were large vessels which broke up into many branches, which latter ran in a radiating direction to the periphery of the tumor.

The narrow tracts of connective tissue after reaching the tumor divided in such manner as to give a picture similar to that of the radiating fibres of the retina at the limitans interna. This same direction was followed by the capillary network and also by the spindle-formed sarcoma cells.

The capillary vessels stand in immediate relation to the structure of the tumor. Next the capillary walls were one or two rows of round cells similar in every way to leucocytes, and farther outward were spindle cells with the long axis parallel to the long diameter of the meshes of the capillary network. Between the round and spindle cells transition forms were noticed.

Only the large cells formed the groups usually found. In the bulk of the tumor the lymphoid and the small spindle cells were mingled, although the lymphoid cells were grouped about the vessels. It seems to me, therefore, that the elements of the tumor developed from lymphoid cells which escaped from the vessels.

Explanation of the Figure (slightly magnified).

Conj, conjunctiva bulbi.
Scl, sclera.
Am, muscle of accommodation.
Pr, perichoroidal space.
I, iris.
C, cornea.
mB, Bowman's membrane.
mD, Descemet's membrane.
L, lens.
S, new growth.
es, epithelial covering.
ww, proliferated epithelium.
ex, hemorrhages.
el, proliferation of epithelium of limbus.
G, vessels.
ec, corneal epithelium.
cew, proliferation of corneal epithelium.

ON PIGMENT STRIÆ WITH SECONDARY CHANGES IN THE RETINA AFTER HEMORRHAGE.

(FROM THE EYE CLINIC OF DR. NIEDEN, BOCHUM.)

By Dr. O. PLANGE, Münster.

Translated by Dr. Ward A. Holden, New York.

(*With Figs. a and b, Plate III.*)

WHILE assistant in Nieden's clinic, I observed a peculiar affection of the retina which in appearance bore a certain similarity to the disease known as retinitis striata, but in etiology resembled retinitis proliferans. There is no similar case, to my knowledge, in literature.

Mrs. H., aged thirty-eight, came to the clinic in May, 1889. She is of healthy parentage, and was never seriously ill until after her marriage. Since 1870 she has had severe headaches recurring periodically. These were most severe in the summer of 1879, and at that time she noticed a failure of vision, for which she consulted Dr. Nieden, and was under his treatment for a time. There was a transient improvement, but in the course of years the vision failed again. Three years ago she had pneumonia, but is now in fair health, except for the headaches, which still recur at times, but are less severe than formerly.

Following are notes from the record book, at the time of her first visit:

July 14, 1879.—The patient complained of periodic headaches since March, 1879, and a marked diminution of vision in the

right eye. Objects appeared veiled and misty at first, and this increased until objects were not seen at all directly. The trouble came on in the late months of her third pregnancy, and both the headache and visual disturbance increased after her normal delivery.

L V = $\frac{2}{3}$; R V = $\frac{1}{3}$ eccentric. Right, a small central scotoma. The ophthalmoscope shows peculiar brown membranous filaments in each eye. These have about the breadth of the retinal vessels, and are 2–3 disc diameters long. In general they run in the direction of the vessels, and at the peripheral end of each is a small retinal hemorrhage. In the right eye there are three such striæ uniting at the nasal side of the disc, one running upward, one outward, and the third downward. Besides these a similar filament runs from the opposite side of the disc to the macula, ending in a white atrophic plaque which includes the entire macula, and in which are scattered masses of pigment. In the left eye there is a single pigment stria running from the nasal side of the disc upward and inward, and ending also in a retinal hemorrhage.

No etiological factors could be discovered. The urine contains neither albumen nor sugar. There is no evidence of syphilis. The treatment consisted of hydr. biniodid. rubr. and potas. iodid. in pill form.

The case was kept under observation until November 11th, and in this time the hemorrhages partially absorbed and recurred several times in the right eye, the membranes developing as the hemorrhages underwent resorption. November 11th, R V = $\frac{1}{5}$; L V = $\frac{2}{3}$.

The condition of the fundus when I saw the patient is shown in the drawings. In the right eye peculiar dull brown striæ pass from the disc in a radiating direction toward the periphery of the fundus. Their origin near the disc is not sharply marked; they seem to proceed from a layer of opaque grayish-white glistening tissue. At this point they are double or triple the width of the central vessels, and toward the periphery they become narrower and break up into a number of plaques and points of the same color.

These striæ are included in broader light stripes, which

unite, forming a zone about the disc. The color of the lighter stripes is light gray or grayish-brown, and they give a reflex similar to that from the retina of a myopic child's eye. This reflex is seen over the pigment striæ and over the vessels which are particularly veiled in the neighborhood of the disc.

In the macular region there is a pure white plaque not giving a reflex, and stippled over with pigment masses, showing the usual picture of atrophic choroiditis. None of these plaques or stripes project into the vitreous.

There are four main branches of the pigment striæ, each of which divides, and the smaller branches finally end in a number of pigment spots, as is seen in the drawing made in the inverted image. V = fingers at 3 *m* eccentrically. There is a central scotoma of 30° lateral extent and 40° vertical. The periphery of the field is free. The limits of the color fields are slightly narrowed.

The left eye shows like changes but of less marked degree. Four main pigment striæ, narrower and more tortuous than those in the right eye, run with their branches from the neighborhood of the disc out into the periphery. The light stripes following the course of the vessels in the right eye are not found here, although about the disc the red of the fundus is pale, and there is an increased retinal reflex. The fundus is otherwise normal, as are also the vitreous and lens and the remainder of the eye.

With the less marked changes in the left eye the functional examination shows it to be normal in vision, fields, etc.

The only abnormal feature elicited by the general examination of the patient was the radial pulse curve, which is particularly low and has the character of a pulsus durus with a long extended wave flattened at the summit, and scarcely an indication of the second rise, all signs of elasticity being wanting.

The history of this case shows it to be a rare and unusual form of retinal disease. The pathological process was the same in the two eyes, more extensive in the right. Without a microscopic examination it is not possible to define

it pathologically, but a detailed study of the case will allow some probable conclusions as to the nature and the more accurate localization of the disease.

The pigment striæ, the atrophic plaque in the macular region of the right eye, and the grayish-white reflecting parts, should be differentiated, since in all probability they lie at different levels, in different layers of the fundus.

In the macular atrophic plaque the white sclera shines through. No trace is seen of the choroid, which must be destroyed in all its layers. In the mass of irregular pigment clumps we see doubtless remains of the pigment epithelium, and the absolute scotoma indicates the absence of at least the nervous elements of the retina. At this point, where recurrent hemorrhages occurred, we have these deposits of pigment, and complete degeneration of choroid and retina.

The degeneration was less extensive in those parts in which the hemorrhage recurred not at the same point, but at neighboring ones. Here, after each hemorrhage, only a deposition of pigment remained, and through the coalescence of these deposits the brown stripes were formed. This process was followed by Dr. Nieden with the ophthalmoscope, and the gradual lengthening of the stripes noted in his case-book. It was noticed, also, that the patient's headache had a certain relation to the retinal hemorrhages, preceding each one with such regularity that from the recurrence of the headache a new hemorrhage could be prognosticated.

The next question is, in what tissue do these formations lie? This is more easily answered by considering the left eye, for here the details are sharper, and there is not the complication of the reflecting stripes.

The normal red is slightly pale only about the disc, the striæ pass above the choroid just as the retinal vessels do, and the pigment epithelium is everywhere normal. The pigment striæ are without doubt products of the coloring matter of the exuded blood, and lie in the retina proper. They cannot have had their origin in the pigment epithelium, as this shows no changes, and the rods and cones were

proven to be unaffected by the functional examination. The vessels lie above the striæ, and the latter must therefore lie in the middle layers of the retina.

It is impossible to say why in this case the coloring matter of the blood was not absorbed, as is usually the case, and why the hemorrhages recurred periodically. We can only suppose that in the patient's pregnancy a nephritis or a general alteration of the entire vascular system developed, which could not be determined later. This is indicated by the pulse curve, which shows that the vessel-wall had lost its elasticity, and must have undergone a pathological change. What was true of the radial artery might also be assumed to be true of the arteries of the head, and particularly of the eye, and this vascular affection may reasonably account for both the headache and the hemorrhages.

As for the grayish-white glistening stripes in the right eye, it is probable that they also were consecutive to and dependent on the original affection, although the direct connection was not clinically observed. In the case-book for 1879–80 there is no notice of their existence, and Dr. Nieden remembers that at the time the right eye presented a picture similar to that now seen in the left. The changes must have come on later, and it is probable that they developed slowly.

We have seen that these glistening stripes covered both the pigment striæ and the retinal vessels, so that the only question as to their location is whether they lie in the retina or before it in the vitreous. Where the vessels cross the pigment striæ, the reflex before the striæ is much more marked than that before the vessels which lie higher. This can only be explained by a greater thickness of the stripe, and it must therefore lie in the retina. The inner layers of the retina are then certainly involved, but possibly not merely the inner layers. The fact that the grayish color and also the reflex are more marked near the striæ and the vessels, makes it appear probable that the deeper layers of the retina are also involved. There is also a possibility that the hyaloid membrane, which lies on the limitans interna, may

also have been involved in the process, although the changes are seen to be at the level of the retina, and do not project into the vitreous.

The last question is as to the pathological character of these grayish changes. The simplest and most reasonable explanation is that there have been changes, possibly hyperplasia, in the supporting fibres of Müller, which changes are not rare after parenchymatous affections.

The supporting fibres run transversely through the retina, ending at the inner portion of the nerve-fibre layer in funnel-shaped dilatations, which unite to form the membrana limitans interna. If through some change these fibres had lost their normal transparency, they would reflect the light which enters the eye. This reflection would be greatest where the network of supporting fibres is thickest, and in accordance with the structure of the individual fibres this is at their internal end. The number of the fibres is greatest near the disc. These facts correspond to the appearance of the changes; and the peculiar glitter obtained when the ophthalmoscope was moved is explained by the fact that the individual fibres are met by the rays of light at various angles, so that moving the source of light causes other portions to be illuminated, and further by the fact that the membrana limitans interna and the membrana hyaloidea, on account of the changes in the fibres, do not present a plane surface.

I believe that so much may be said in regard to the origin, nature, and localization of the affection without verging too much upon the hypothetical. We have, then, *a deposition of pigment in striæ in the retina after hemorrhage, followed by changes—probably hyperplastic—in the supporting fibres of Müller.*

I have not found an analogous case in literature. Some cases of retinal disease, denominated retinitis striata, have been observed, but these differ in many respects from our case, and have a different origin. There is a certain similarity to retinitis proliferans, since both arise from hemorrhages, in both there is deposition of pigment, and the connective-tissue changes in these cases are not dissim-

ilar to the grayish-white stripes in ours. Yet the peculiar course of the pigment striæ, similar in the two eyes, and the fact of their not projecting into the vitreous, seem to justify us in considering the changes as constituting a retinal affection which is unique.

ON THE FORMATION OF DARK ANGIOID STREAKS AS AN UNUSUAL METAMORPHOSIS OF RETINAL HEMORRHAGE.

By H. KNAPP.

(*With an ophthalmoscopic drawing.*)

DR. O. PLANGE'S remarkable case from Dr. Nieden's practice, published in this number of these ARCHIVES, has given me the explanation of a case which was under my care two years ago. The ophthalmoscopic picture which I here reproduce from my sketch-book of opthalmoscopic drawings, is so similar to the condition in Nieden-Plange's case as to leave no doubt in my mind that both belong to the same affection, namely the conversion of extravasated blood into streaks of dark brown or black pigment in the retina. The case is as follows:

Miss Ottilie Kaiser, children's nurse of New York City, consulted me first Oct. 8, 1889, with the following history. She was well until July 23, 1889, when she went to Newport, R. I., with the family in which she was employed. Two days later she and the whole family were taken sick—from bad water as was alleged—with vomiting, diarrhœa, and general indisposition. Five days after the beginning of the vomiting she was sewing on the machine while the sun shone brightly on the plate. This produced in her eyes a sudden pain and dizziness which she could not wipe away, and her eyes have been weak ever since. The family stayed at Newport one week only. She accompanied them to Bar Harbor, Me., where her vomiting ceased in a few days, but her sight became steadily weaker. When she came to me, I found the sight

in each eye $\frac{20}{200}$, with $-\frac{1}{18}$ $\frac{20}{70}$. She read Schweigger 0.5. Her visual field was much contracted, namely: L: 45° temporally, 30° nasally, 10° up, 15° down. R: 25° temporally, 15° nasally, 15° up, 10° down. She saw better at night than in the bright day. Her pupils were responsive, both optic discs white, but the vessels of normal calibre. The background of each eye was dull and mottled. My diagnosis was atrophy of the optic nerves in myopic eyes. From the contraction of the visual field I inferred that the amblyopia would progress. I ordered her calomel tablets in ½ cgrm. doses four times daily. She remained under treatment sixteen months, at the end of which her sight was reduced to the perception of movements of the hand. In a month from her first visit a peculiar ophthalmoscopic picture had developed. (See accompanying drawing). The odd. remained white, and the blood-

vessels nearly of normal size; the background, however, in a radius of about 6 P-Ds, still showed the irregularly mottled appearance, but the choroidal pigment was arranged in irregular figures, many small black dots, further patches with offsets, and communicating curved and angular lines, on a whitish background. Most peculiar was a system of dark-brown or black streaks, radiating from the neighborhood of the optic disc in every direction. The thickness of the streaks was irregular and varied considerably. They all lay upon the choroid, and the retinal vessels passed over them, but nowhere could I discover a direct connection between the streaks and the retinal vessels. I noticed no hemorrhages, but in a few places the dark streaks had red portions. Trying to explain

to myself the origin and nature of these peculiar streaks, which had the appearance of an obliterated system of blood-vessels, I examined the background carefully in the indirect and direct methods. The streaks originated and ended sharply in the retina without uniting with any other formation.

The further history can be briefly told. The sight continued to decrease and the field of vision to contract. The ophthalmoscopic picture, when once in the state as above described, did not materially change; the red parts on the streaks disappeared completely. The patient, who had taken mercury, iodide of potassium, salicylate of soda, iron, strychnia, cod-liver oil, and at times bromide of potassium, left off treatment on my advice.

On my request she came to be examined again, March 29, 1892. The eyes were materially in the same condition. There has been no irritation of any kind. She could count fingers near by, though not always correctly. The visual field had a radius of about 25°. The atrophy of the optic discs was marked; the retinal vessels were fairly normal. The streaks were essentially unchanged, only some were shrunken, and surrounded by white bands broader than the black centre. The mottled appearance of the background was less pronounced.

As to the etiology, our case furnishes another of these rather rare examples in which blindness follows excessive or prolonged vomiting. I have seen a few cases of this kind. They came under my observation weeks or months after the blindness had set in. All showed atrophy of the optic nerves, but I remember no retinal changes. That in the case above related there was hemorrhage into the sheath of the optic nerve is very doubtful. In the cases of hemorrhage into the sheath of the optic nerve which have come under my notice the extravasated blood could be directly seen with the ophthalmoscope to encircle the optic disc, encroaching slightly on its area and surrounding it either on all sides, or extending in large streaks 3 or 4 P-Ds over the retina.[1]

In the case under consideration the extravasated blood was evidently situated in the outer layers of the retina, for

[1] Compare my paper "On Pathological Formation of Pigment in the Optic Disc and Retina," with three colored drawings, *Graefe's Arch.*, xiv., 1, p. 252, 1868.

the retinal vessels passed over the streaks. It disintegrated the choroid, and was changed into black pigment, deposited in numerous dots and short lines, and the very conspicuous long and tortuous streaks. In Plange-Nieden's case there were signs of inflammation in the right eye only, but the optic discs did not look atrophic. The vision also was relatively good, namely: $R=\frac{1}{6}$; $L=\frac{2}{3}$.

While having the patient under observation I had no idea of the hemorrhagic origin of the peculiar dark-brown streaks, and if Dr. Nieden had not watched directly the gradual conversion of the blood into these streaks, I do not think that he or any one would have made the diagnosis on examining the conditions represented in his drawings. The left eye (Fig. 2, Plate XXIII.), with no other abnormity than a system of streaks resembling the retinal blood-vessels in every respect except their color, might have puzzled every one. In my case I looked upon those streaks as obliterated blood-vessels, either retinal or choroidal, but the explanation remained unsatisfactory. As soon as I saw the drawings of Nieden-Plange I was convinced that theirs was a parallel case to mine. To see extravasated blood converted into dark vessel-like streaks is certainly rare, yet since my attention has been drawn to this subject, I have come across forms which, though not identical, were at least similar to those under consideration. In one case, numerous small dark-red patches of blood were seen above the region of the yellow spot, and near by there were curved, dark streaks, only not so long, nor so regularly radiating as in the above cases. Below the yellow spot there was a large patch, shining white in color, and irregular in outline, over which some retinal blood-vessels passed, just as over the black streaks. Both the streaks and the white patch were evidently metamorphoses of extravasated blood and lay in the outer layers of the retina.

In this communication it has not been my intention to discuss in detail the changes extravasated blood may undergo in the retina, but to furnish a second case of the rare and puzzling formation of dark, angioid streaks which Dr. Plange has described.

ON GLAUCOMA AFTER DISCISSION OF SECONDARY CATARACT AND ITS SUCCESSFUL TREATMENT BY IRIDECTOMY.

By H. KNAPP.

IN my reports on cataract extraction, I have mentioned several times the outbreak of glaucoma after the secondary division of the capsule. Glaucoma, following sooner or later simple or combined extraction prior to any after-operation, has been described by different authors. No such case, to my recollection, has occurred in my own practice. The occurrence of glaucoma after operations for secondary cataract seems to have been but rarely recorded in literature.[1] As the number of such cases has gradually increased in my own practice, I thought it opportune to make them the subject of a special communication, so much the more as all the patients were promptly cured by an iridectomy, a fact worth knowing.

I shall first give BRIEF HISTORIES OF THE CASES, and then see what conclusions may be drawn from them.

CASE 1 (reported in these ARCHIVES, 1888, p. 71).—The case being typical I will copy the publication. Mr. Stewart, aged fifty-nine; suffering from Bright's disease and alcoholism in a high degree. Extraction April 16, 1887. Normal. Round, perfectly free pupil. S $\frac{20}{70}$. Nine weeks later a simple division of a wrinkled, not thickened or adherent capsule was, within twenty-four hours, followed by an attack of acute glaucoma. +T2. Relief by eserine for a day, but then + T2 again, and vision re-

[1] See a case by Dr. T. R. Pooley, in the *Am. Journ. of Ophth.*, 1891, No. 12.

duced to $\frac{1}{\infty}$. Upward iridectomy, the incision behind the corneal scar, gave instantaneous relief. Prompt recovery. S $\frac{20}{50}$.

CASE 2 (reported as No. 67 in the second series of one hundred simple extractions; these ARCHIVES, 1889, p. 6).—M. Cramer, sixty years, of Kalamazoo, Mich. Extraction Oct. 3, 1888. No disturbance. With + $\frac{1}{8}$ S = $\frac{20}{200}$. Discission Oct. 24, 1888. No accident. Left Oct. 30th, with S $\frac{20}{30}$. Caught violent cold, with sneezing and abundant secretion. Eye painful and weak. Recovered, but eye had repeated attacks of irritation, the worst at end of Dec., 1890. An oculist gave him drops to relieve the tension. Patient came to New York Feb. 12, 1891. Eye free from inflammation. External aspect: iris, pupil, and media normal. + T1. *Glaucomatous excavation and atrophy of optic disc.* $S = 0$.

In the third series of one hundred simple extractions, there were two cases had glaucoma after the discission, viz.:

CASE 3.—Jas. Conkling (No. 24, p. 291, ARCHIVES OF OPHTHALMOLOGY, 1890). Fifty-nine years. Extraction April 12, 1889. Regular. S $\frac{20}{100}$. Discission in four weeks. Discharged in five days. A glaucomatous attack on the eighth day *cured* by *eserine.* S $\frac{20}{40}$; later $\frac{20}{20}$. Has remained permanent.

CASE 4.—Mrs. Smith, seventy-eight years (reported as No. 49 *l. c.*). Extraction June 5, 1889. Discharged in two weeks. S $\frac{20}{200}$. Discission five weeks after extraction. Discharged in four days. Round, regular pupil. S = $\frac{20}{50}$. From sixth month on attacks of glaucoma set in repeatedly, and were relieved by eserine, until in March, 1890, the anterior chamber being shallow, the iris bulging, + T1, a regular upward iridectomy was made, which resulted in prompt and permanent recovery.

Since January 24, 1890, where the report of the third series of 100 simple extractions ends, I have made about 350 extractions, on which I shall report later. The method of operating has, as a rule, been the simple extraction, opening the capsule at the upper periphery, underneath the iris, and performing a subsequent discission of the capsule in almost every case. Particular attention has been paid to the occurrence of glaucoma, and the following cases have come under observation:

CASE 5.—E. Hahnemann, S. Norwalk, Ct., sixty-two years old. Regular simple extraction Nov. 19, 1890. No reaction eleven days, then irido-cyclitis with a small quantity of blood and puriform substance at bottom of anterior chamber. Discharged in seven weeks with S $\frac{3}{300}$. On Feb. 21, 1891, came back, eye much better. S $\frac{15}{200}$. Capsule opaque; split with discission needle Feb. 21, 1891, thirteen weeks after the extraction. No particular reaction the first week, but then the eye grew hard and the sight dim. Relief by eserine. Discharged March 21, 1891, with S $\frac{20}{60}$. Having had several relapses at home, he returned April 20, 1891. Cornea and pupil clear, but iris somewhat bulging and tension increased. The next day I performed an upward iridectomy. The iris, escaping the capsule forceps, was drawn out with a blunt hook. A few drops of aqueous first flowed out, then some vitreous, as usual. Instantaneous relief and prompt recovery. S, May 1, in seven days, $\frac{20}{60}$. On Dec. 9, 1891, eight months, $\frac{20}{20}$. No excavation. Tn.; eye quiet.

The next case is very important, because both eyes had glaucoma after regular extractions, performed at an interval of eight months:

CASE 6.—Lilly M. Lees, thirty-two years old, of Newport, R. I. R. eye cataract of three years' standing, mature, uncomplicated. Functional examination normal. Neither diabetes nor albuminuria. Dec. 6, 1890, simple extraction; operation and recovery normal. Discharged Dec. 15, 1890, *i.e.*, in nine days, with S = $\frac{20}{50}$. Returned Jan. 2, 1891, with S = $\frac{20}{70}$. Discission as usual. Five days without reaction, then acute glaucoma, with intense pain, œdema of lids, chemosis, muddiness of anterior chamber, dulness of pupil, bulging of iris all around its periphery, sight very dim, + T2. Eserine repeatedly instilled brought some relief at first, and in the afternoon the tension was so much less that there was hope of a recovery. In the night, however, the pain returned with greater severity, and the other symptoms were worse than before. On receiving this report in the morning, I went at once to the hospital and made an upward iridectomy at 8.30 A.M. Incision with a lance 2 *mm* behind the corneal section. Clear, viscid vitreous escaped. The iris was drawn out with a Wecker capsule forceps, and cut together with the protruding vitreous, close to the cornea. The eye was kept shut with the ordinary small

pad of corrosive sublimate gauze and absorbent cotton, held by two strips of court plaster. From that moment the pain had left; the recovery was undisturbed. In two days the wound had united, the coloboma was clear, the iris in normal position. Jan. 12th, 5 P.M., four and one-half days after the iridectomy, the patient left the hospital with a clear pupil and good sight, which when tested on April 20, 1891, and again on Sept. 29, 1891, proved to be $\frac{20}{20}$. The patient has had no relapse or other inconvenience from that eye.

CASE 7.—Sept. 16, 1891, Miss Lees, the patient of Case 6, came to have the cataract removed from the other eye. This was done Sept. 17th. Everything normal. Discharged Sept. 29th with a round pupil; no adhesion; S $\frac{20}{50}$. Oct. 23, 1891, the capsule was split, though her sight was $\frac{20}{40}$, and in conscious remembrance of the outbreak of glaucoma in the other eye after the discission. The operation was done without difficulty or accident. In the night violent pain and the other symptoms of a severe attack of acute glaucoma, + T2 diminished to + T1 by eserine and subcutaneous injection of morphine in the temple. Remission in the evening, but return of the symptoms in the night. The next morning the iris pushed forward, pupil hazy, sight dim, chemosis. Iridectomy at 10 A.M. with Tyrell's hook. Escape of vitreous. Immediate relief. No reaction. Discharged Nov. 4, 1891, with S $\frac{15}{xx}$. No relapse.

CASE 8.—Josephine Lory, Elizabeth Home, Harlem, N. Y. City. Extraction Feb. 3, 1891. Normal. Discharged Feb. 13th with S $\frac{20}{200}$. Returned March 9th with S $\frac{20}{30}$. Thin capsule. Split March 10th. Glaucoma the same night. Relieved temporarily by eserine. Relapse the next day. Iridectomy upward with considerable loss of normal vitreous. Immediate relief. Eye remained somewhat red, but free from pain, for ten days. Discharged with S $\frac{20}{70}$; vitreous and new pupil still hazy.

There are two cases to be added in which glaucoma broke out a longer time after the discission.

CASE 9.—Mrs. Mary Tureman, of Chicago, aged about forty-four, had a cataract removed from her left eye Nov. 26, 1890. Normal. S $\frac{20}{60}$. Discission Dec. 20, 1890. Normal. S $\frac{20}{20}$

Oct. 10, 1891, she came and had a cataract removed from the right eye. Normal. Oct. 25th, S $\frac{20}{20}$.

The left eye, operated on a year previously, showed now S $\frac{20}{15}$ a perfectly clear pupil, and iris and interior of eye normal; but near the centre of the scar of the corneal section there was a minute vesicle, the surroundings of which were red at times; then the vesicle broke, and all was right again. This was evidently a small corneal fistula or cyst, which had been noticed before she came to New York for the operation on the second eye and during the recovery from the same. It gave rise to so little inconvenience that nothing was done for it. When she had returned to Chicago, however, it grew more troublesome; there was inflammation, pain, and dimness of sight—in short, glaucomatous attacks—from time to time. Dr. B. Bettman, who treated her, after having tried myotics, etc., performed, on my suggestion, an iridectomy, which cured the disease at once, restoring her sight. No discomfort since.

Case 10.—L. Durocher, Porto Plata, St. Domingo, fifty-eight years old, had a cataract removed from his right eye Jan. 15, 1891. Normal. S $\frac{20}{70}$. Discission Jan. 30, 1891. Normal. Feb. 12, 1891, S $\frac{20}{60}$. April 8, 1891, S $\frac{20}{40}$.

In March of 1892 he came for the operation on the other eye, which was done, and healed without disturbance. On dressing it a week after the extraction I accidentally inspected also the eye previously operated on, and found the cornea hazy, and the pupil crater-shaped, + T1, and the sight dim. On asking him whether he felt no pain in that eye, he said he did feel pain. The eye was not so clear as before. He did not think it to be of importance, and therefore had not drawn my attention to it. I gave him eserine and morphine, but the attack increased, and was so marked the next day that I made an iridectomy outward, the upper part of the iris showing some adhesion to the capsule. A few drops of vitreous were lost. The eye recovered speedily, and regained its clear aspect and good sight in less than a week.

Besides these cases of well-developed acute glaucoma there are three cases in which, with symptoms of irritation (cyclitis), transient increase of tension is noted, but it was controlled by eserine or pilocarpine, and the eyes recovered permamently without an operation. Dr. Pooley's case, quoted above, seems to have been of this nature.

In the foregoing pages lies all my experience on this subject, and I dare say that no case of glaucomatous inflam-

mation has been overlooked. I remember a few cases from previous years which passed under the diagnosis of iridocyclitis, and had a varying course. How often glaucoma complicates extraction of primary and discission of secondary cataract I am unable to tell. Ten cases in six years, or somewhat more than 1 %, shows that this is not a negligible quantity.

As to the pathogenesis of glaucoma under these circumstances, I do not venture on any hypothesis. It is an example of experimental glaucoma in aphakial eyes of man. All the cases in which it occurred, excepting the one with corneal fistula, had no complications, except a few that had non-inflammatory posterior synechiæ where the capsule had been opened. There was no incarceration of iris in the corneal section, or any other abnormity. The occurrence in both eyes of the same patient after a longer interval confirms the supposition that certain persons have a predisposition for glaucoma.

The mode of operating may, perhaps, have favored the outbreak of glaucoma. During the last years I have made the division of the capsule more extensive than I used to do. Instead of splitting the capsule in the shape of of a T, I did it in the shape of a +, making at first a horizontal incision, then passing the knife up before the upper part of the capsule, transfixing this, and cutting it from above down into the horizontal section; then I split the lower half of the section in a similar way from below upward. This method produces unimpeachably clear pupils, and the results of such operations cannot be excelled; they are truly ideal, and remain so, as I have convinced myself by re-examining multitudes of cases, of from one to six years' standing. Yet the occurrence of glaucoma has made me return to the T-shaped discission, and I take care not to enter the blade of the little knife more deeply into the vitreous than is necessary for a sufficient opening in the capsule.

Do these cases of traumatic glaucoma recover without operation? Some do, as Case 3 of our series demonstrates; others do not, as is proven by Case 2.

Does an iridectomy always cure them? It seems it does;

at least the acute cases of which I have recollection and full notes were promptly and permanently cured by it. I have in most cases made the iridectomy upward, with a lance-shaped knife and a blunt hook. The incision was somewhat behind the corneal section and not very broad. Iris forceps, even those with the teeth projecting downward, mostly fail to grasp the iris. It is therefore necessary always to have an iris hook at hand, and best to use it without first trying the forceps.

In all the operations normal vitreous, which partially or, in the recent cases, totally filled the anterior chamber, flowed out. It had no influence on the healing of the wound, for in all cases the relief was immediate, and the recovery prompt, good, and permanent. This experience takes away the dread of the accident. I would, therefore, recommend the performance of an iridectomy whenever myotics do not promptly and satisfactorily relieve the patient. I never forget a little boy who after the third discission of a congenital cataract developed inflammatory glaucoma, which I recognized and judged correctly, but at that time I had not the courage of making an iridectomy, waiting for a recovery without operative interference until it was too late. The iridectomy, too long delayed, cured the inflammation permanently, but did not restore sight.

All these cases of glaucoma after discission bear the same stamp—pain, swelling of lids and conjunctiva, dulness of cornea and pupil, bulging of the periphery of the iris, with pupillary border drawn back—a crater-shaped pupil—increase of tension, impairment of sight, general disturbance, even vomiting.

Will another operation, paracentesis or sclerotomy, cure these cases? I know not. There seemed to me so much responsibility involved in treating such cases, as to make me at once resort to that glaucoma operation which I deem to be the most reliable, iridectomy, and when experience had once demonstrated its efficacy, I have clung to it. Its performance is not difficult, and the piece of iris to be exsected need not be large. The optical conditions are not essentially prejudiced.

Should the occurrence of about 1 *% of glaucoma after discission induce me to modify the method which I have preferred in operating for cataract? Should I lacerate the anterior capsule freely, or try to remove a portion of it, and in order to do this to the best advantage, should I return to the combined method?* I have not the slightest intention to do anything of the kind, as a rule. The longer I practise simple extraction, the more I like it, for the more I have learned how to control its one dark side, prolapse of the iris. Occasionally I make an iridectomy, or remove a piece of capsule, or lacerate the capsule more freely, or remove the lens in its capsule, but I do those procedures only on special indications. The general method for me remains the simple extraction, with peripheric opening and subsequent discission of the capsule, for this method has continued to give me fewer failures and more permanently good results than any other.

AN EXTREME CYLINDRICAL EFFECT FROM A TILTED SPHERICAL LENS.

By E. L. JONES, M.D., Florence, Ala.

In September, 1888, I removed from the left eye of Peter R., aged fifty-three, a hypermature cataract of fifteen years' duration. The healing process was complicated by a prolapse of the iris, drawing the pupil to upper margin of cornea. He then returned to his home, some distance away, and as his condition, physical and financial, was very poor, and he was also somewhat indifferent, he did not return for glasses until November, 1891, when I found the pupil situated as above described, but clear; and without any glass V = $\frac{4}{200}$. Plain sphericals did not improve this much, but with $\frac{1}{10}$ + $\frac{1}{6}^{c}$ ax. V = $\frac{20}{60}$, and with $\frac{1}{5\frac{1}{2}}$ combined with the cylinder he easily reads J 1.

He then produced an old dingy and scratched glass, a + $\frac{1}{6}$, which his children had unearthed in an old field, which he had rudely rimmed with leather and adapted with a handle, and with this he said he had been reading since the extraction. Being requested to show how he did it, he began by removing the glass six inches from his eye, and then rotated it to an angle of 75° from vertical and read J No. 1 as easily as with his proper correction.

While the optical principles here involved have long been known, it is interesting in this case from the extreme effect produced, and from its independent discovery and application by a wholly illiterate person. Any one with a little patience can demonstrate the preceding facts, by putting in trial frames the neutralizing combination (− $\frac{1}{5\frac{1}{2}}$ − $\frac{1}{6}^{c}$ ax. h), and then holding a + $\frac{1}{6}$ the proper distance from the eye,

rotating it to a sufficient degree, and moving the types to the right distance, when J 1 can be easily read.

As having a probable causal relation to his cataract, which was double, I would mention that his general health is very poor, the most noticeable feature being an anchylosis of the cervical vertebræ, or an ossification of the cervical muscles, which are of stony hardness. His face is in a position of outward and downward rotation, and his head is as immovable, by himself or outside force, as if it were of marble. The high degree of astigmatism resulting from the operation is also of interest.

SYSTEMATIC REPORT ON THE PROGRESS OF OPHTHALMOLOGY DURING THE SECOND QUARTER OF THE YEAR 1891.

By ST. BERNHEIMER, Heidelberg; C. HORSTMANN and P. SILEX, Berlin.

WITH THE CO-OPERATION OF

S. M. Burnett, Washington; Dantone, Rome; Hirschmann, Charkow; E. Marckwort, Antwerp; P. v. Mittelstädt, Metz; L. Werner, Dublin; C. H. A. Westhoff, Amsterdam; Schiötz and Ole Bull, Christiania, and Deus, Berlin.

Translated by Dr. F. E. D'Oench, New York.

Sections I.–V. Reviewed by Dr. ST. BERNHEIMER.

I.—GENERAL OPHTHALMOLOGICAL LITERATURE.

TEXT-BOOKS, MONOGRAPHS, TREATISES ON GENERAL, BIBLIOGRAPHICAL, AND HISTORICAL SUBJECTS.

136. St. Bernheimer. The roots of the optic nerves of man. The origin, development, and course of their fibres. Wiesbaden, J. F. Bergmann, 1891.

137. Leber. The development of inflammation and the effect of the injurious influences causing it, viewed in the light of experiments upon the eye. Leipsic, W. Engelmann, 1891.

138. Gowers, W. B. A manual and atlas of medical ophthalmoscopy. Third edition. Edited with the assistance of Marcus Gunn. London, 1890.

139. Manara. Due anni nell' istituto oculistico della R. Università di Roma. Rome, C. Mariani, 1891.

Bernheimer (136) has made a close study of the origin, devel-

opment, and course of the fibres in the roots of the optic nerves of man, his material being sixty tractus optici and their ganglia, obtained from embryos, immature, mature, and hypermature fœtuses (Weigert's hæmatoxylin staining). The book contains an introduction (methods of examination), chapters on the outer and the inner corpus geniculatum, the thalami optici, and the region of the corpora quadrigemina, and concluding remarks. Three colored plates furnish material aid in the comprehension of this difficult subject. He found among other things that the corpus geniculatum laterale is a true original ganglion of the optic nerve, and not merely an interposed ganglion. The inner corpus geniculatum is also an original ganglion, but also furnishes fibres which, passing over, around, and through it, really have their source in a part of the corpus Luys, thalamic end (*v.* the original). The root of the optic nerve discovered by Stilling and having its origin in the nucleus amygdalæ (corp. Luys) was traced farther than ever before and shown in the drawing; it furnishes a large share of the fibres of the optic nerve, if not the largest.

With almost equal exactness the superficial and deep root of the optic thalamus was shown, and long and short fibres were recognized in the latter, of which it could only be said that they differed from all others in their course and in the formation of their medulla. (*v.* the original).

The condition of the region of the corpora quadrigemina could be made out with great probability, but not with certainty like that of the others. The superficial roots of the optic nerves coming from the corpora quadrigemina have not been demonstrated, and their existence could be denied. The existence of the deep root from the posterior corpora quadrigemina is most probable, less so that from the anterior.

The existence of a basal optic-nerve ganglion could not be shown, and the opinion is expressed that the so-called ganglia belong to entirely different fibre-areas.

MANARA (139) reports at length upon the eye diseases observed at the Rome clinic from 1888 to 1890 in 2,693 patients (sixty per cent. diseases of the conjunctiva and cornea), and the operations performed (eighty-two extractions, sixty-five iridectomies).

DANTONE.

II.—GENERAL PATHOLOGY, DIAGNOSIS, AND THERAPEUTICS.

140. DESPAGNET. Anophtalmie congénitale. *Soc. franç. d'opht.*, June 6, 1891.

141. FRANKE. Investigations on the disinfection of eye lotions. *v. Graefe's Arch. f. Ophth.*, vol. xxxvii., 2, p. 92.

142. GÜNSBURG. On pseudo-ephedrin. *Virchow's Arch.*, vol. cxxiv., 1.

143. SPIERER, S. Absorption of a piece of bone in the eye. *Zeh. klin. Monatsbl. f. Augenhk.*, vol. xxix., p. 224.

DESPAGNET (140) demonstrated before the Paris Ophthalmological Society a case in which there was microphthalmus of the left and anophthalmus of the right side. In connection with this Gillet de Grandmont reports that in a case of unilateral anophthalmus he performed canthoplasty on account of the narrow palpebral fissure so common in these cases, so that an artificial eye could be inserted. MARCKWORT.

According to the extensive investigations of FRANKE (141) chemical disinfection of eye lotions should in general be preferred to boiling, as the latter does not protect the solutions against the entrance of germs from the air. It is safest to combine both methods. For the purpose of sterilization the following solutions may be used: Sublimate, 1:5,000 and 1:10,000; the oxycyanide of mercury, from 1:1,000 to 1:5,000; resorcin, 1:1,000; carbolic acid, 1:500; four-per-cent boracic acid with 1:1000 carbolic; Panas' solution; thymol as thymol water. It is impossible to obtain an antiseptic effect with the substances examined in the dilution necessary for our purposes. In general the addition of sublimate 1:10,000 is sufficient for atropine and cocaine; such a solution will certainly remain aseptic for half an hour to an hour. For eserine sterilization the addition of sublimate or resorcin is advisable. Atropine conjunctivitis does not occur when sublimate is added. For practical purposes it is sufficient to add for every ten grammes of liquid two drops of a one-per-cent. solution of sublimate.

GÜNSBURG (142) has made extensive experiments on Merck's pseudo-ephedrin. It resembles the alkaloid prepared from ephedra vulg. by Wagai in Tokio. The author thinks that the dilatation of the pupil produced by pseudo-ephedrin is due to excitation of the sympathetic nerve, while there is no paralysis of the terminations of the oculomotor or of the non-striated muscular fibres.

III.—INSTRUMENTS AND REMEDIES.

144. BURNETT, S. M. On the reform in numbering prisms. *Med. News*, May 2, 1891.

145. FISCHER, R. Cure of a case of embolism of the central retinal artery by rubbing the eye. *Deutsche med. Wochenschr.*, 1891, No. 23.

146. GASPARINI e MERCANTI. Sull' azione della linfa di Koch nella tuberculosi oculare sperimentale. *Ann. di ottalm.*, vol. xx., 1–2, p. 128.

147. GUENDE. Un nouveau modèle de seringue pour les injections des voies lacrymales.

148. OSTWALT. Quelques remarques sur l'ophtalmomètre de Javal et de Schiötz. *Rev. génér. d'opht.*, 1891, No. 13, p. 100.

149. OSTWALT. De la force réfringente de la cornée, de l'ophtalmomètre et du cylindre correcteur de l'astigmatisme cornéen. *Rev. génér. d'opht.*, 1891, Nos. 5 and 6, p. 193.

150. PERCIVAL, A. Square prisms and a trial frame adapted for them. *Brit. Med. Jour.*, April, 1891, p. 919.

151. RANDALL, B. A. "Prism-dioptre" *vs.* "centrad" in the reformed numeration of prisms. *Med. News*, April 4, 1891.

152. THOMAS, C. H. Construction and adaptation of spectacle frames. *N. Y. Med. Journ.*, April 4, 1891.

BURNETT (144) advocates the prism-dioptry—that is, a standard prism giving a deflection of one *cm* at one metre distance—as proposed by Prentice, in opposition to the centrad as proposed by Dr. Dennett. BURNETT.

GASPARINI and MERCANTI (146) have made experiments with Koch's lymph upon the eyes of thirty-five rabbits, and have come to the following conclusions: (1) Tuberculin introduced into the conjunctival sac or anterior chamber of a healthy eye causes slight irritation. (2) Injections of lymph into the anterior chamber, when tuberculosis by inoculation has already developed, produce no changes either in the bacilli or in the tubercular tissue. On the contrary, they give rise to inflammatory reaction with exudation and infiltration with leucocytes in the tissue surrounding the tubercles, leading to an aggravation of the primary affection. (3) Injections of tuberculin, made before the development of tuberculosis by inoculation, can neither prevent this nor check the disease in its early stages. The experiments were made and recorded with the greatest exactness, and verified throughout by parallel experiments. DANTONE.

GUENDE (147) has constructed a new syringe for the lachrymal canal, in which the part containing the piston is replaced by a

rubber balloon. The connection with the canula is made without a screw. MARCKWORT.

OSTWALT (148) shows that the results obtained with the ophthalmometer of Javal and Schiötz (model of 1889) are not entirely correct. The true value of the refractive power of the cornea in dioptries is equal to only three fourths of that found with the apparatus; for instance, if 45 D are found, the correct number is $33\frac{3}{4}$. The astigmatism indicated by the apparatus is also one fourth greater than the real. MARCKWORT.

OSTWALT (149) publishes another paper on the ophthalmometer and comes to the conclusion that the objective test for astigmatism must be supplemented by the subjective, in order to determine the part played by the lens in making up the total astigmatism. MARCKWORT.

PERCIVAL'S (150) prisms are a modification of the Maddox series. As the prisms are square, they can be placed before the eye either vertically or horizontally. WERNER.

RANDALL (151) criticises Burnett's article on the prism-dioptry in the *Ophthalmic Review* for January, and advocates the "centrad" in numbering prisms. BURNETT.

In this paper THOMAS (151) considers the mechanical theory of fitting spectacle-frames, with illustrations. It is instructive and valuable, but no abstract can be made with justice to its merits. BURNETT.

IV.—ANATOMY.

153. MERIAN, KARL. Experimental investigations on the lymph-passages of the eyes.—*Arch. f. Anat u. Physiol.*, anat. part, 1891.

W. His publishes an abstract of the paper prepared twenty years ago by the late KARL MERIAN (153), containing, besides a critical discussion of the literature of the subject, a description of his own numerous experiments. Among other facts he found that the canal through the vitreous (central canal), lately described at length by Stilling has no connection with the lymph-vessels. Neither the canal nor its posterior end (Area Marteg) has any relation to fœtal blood-vessels. The lymph-vessels of the eye are extensively connected with cavities, their contents depend largely upon the varying pressure of very large blood-vessels. This circumstance, as well as the almost complete exclusion from the lymph system of the vegetative part of

the body, proved by numerous experiments, might suggest the thought of separate connections with the circulation of the blood. Escape of the liquid by filtration from the anterior chamber can also be assumed. The arachnoidal space, however, must possess special drains—lymph- or blood-vessels—but it was impossible to demonstrate them.

V.—PHYSIOLOGY.

154. ADLER. The test with colored crayons. A new method of examining for color-blindness. *Wiener klin. Wochenschr.*, 1891, No. 21.

155. FICK. Investigations on the movement of the pigment in the retina of the frog. *v. Graefe's Arch. f. Ophth.*, vol. xxxvii., 2, p. 1.

156. KESSLER, H. M. De perichorioideale ruimte in betrekking tot de Lymphbeweging in het oog. Utrecht, 1891.

157. LANDOLT. Un nouveau cas d'achromatopsie totale. *Arch. d'opht.*, vol. xi., No. 3, p. 202, May.

ADLER (154) uses colored crayons besides the worsteds in testing color-perception. This method has the great advantage that the result with the crayons (oil or pastel) can be permanently preserved on a proper surface.

FICK (155) concludes from a number of experiments that the fact of the movement of the pigment caused by light, as discovered by Czerny, Boll, and Kühne, is certainly correct, but that the outer position is not found in all frogs kept in the dark, and on the whole only rarely occurs in the retina. The greater abundance of pigment in the middle and lower parts of the retina, as well as its greater inclination to occupy the inner position, can be demonstrated on frogs kept in the light or in the dark. The inner position in the illumined eye is not manifested in the other kept in the dark, either by way of the optic nerve or the blood-vessels. This can be shown in frogs whose brains have been removed, optic nerves divided or carotids ligated. This view is contrary to that of Engelmann.

KESSLER (156) finds that in the perichoroidal lymph-space, which is connected by the lacunar tissue of the iris-angle with the anterior chamber and by the perivascular lymph-sheaths of the vortex-veins with Tenon's space, the action of the ciliary muscle is that of a pump, which forces the lymph from the

anterior chamber along the vortex-veins into Tenon's space. The lymph secreted by the ciliary body at once enters the tissue of the zonula, without previously passing through the vitreous. Under normal conditions the liquid flows rather from the anterior chamber than in the reverse direction. WESTHOFF.

LANDOLT (157) reports another case of total color-blindness besides the two already published by him. It is that of a woman of forty-five with nystagmus, whose vision had always been poor, but lately had fallen to $\frac{1}{5}$. Visual field of both eyes somewhat contracted. The papilla pale, the blood-vessels narrow. The color-sense of the parents and children was normal, but one brother was also completely color-blind. All colors produced the sensation of gray in varying shades. Yellow, light-blue, gray, and green appeared brightest; but dark-blue, violet, and grayish-black, which to the healthy seem the darkest colors, appeared brighter than purple-red and the shades of brown, which seemed darkest. The same conditions were found in the two other cases. He regrets that the other observers did not note the vision with greater accuracy, which is of particular value in estimating the nature of color blindness. Poor vision, contraction of the visual field, anæmia of the fundus, conditions which Landolt also observed in his other cases, indicate peripheric location of the congenital defect. v. MITTELSTÄDT.

Sections VI.-XI. Reviewed by PROF. C. HORSTMANN.

VI.—ANOMALIES OF REFRACTION AND ACCOMMODATION.

158. COHN, H. The eyes of the scholars of the Breslau Deaf-Mute Institute. Breslau, 1891.

159. MARTIN, G. De la correction astigmatique. *Ann. d'ocul.*, vol. cv., p. 139.

160. PROSKAUER, TH. A contribution to the statistics of myopia. *v. Graefe's Arch. f. Ophth.*, vol. xxxvii., 2, p. 199.

161. SECONDI, G. Valore di A nel campo di sguardo. *Ann. di ottalm.*, vol. xx., 1–2, p. 104.

162. VALK, F. Astigmatism of low degree. *The Post-Graduate*, April, 1891.

163. WHITE, J. A. Relations of refractive errors and muscular defects in asthenopic or weak eyes, ocular headache, and other reflex neuroses. *Trans. Med. Soc. of Virginia*, 1890.

Among 286 deaf-mute children COHN (158) found 18 with myopia, 45 with hypermetropia, and 196 with emmetropia, while 27 were amblyopic. Among the myopes there were 8 with a congenital high degree of this refractive error. It was worthy of note that the number of near-sighted children did not increase from class to class, nor with advancing age. This is due to the frequent interruption of near-work, to good illumination, properly constructed desks, and the small number of study-hours. Among the 27 cases of amblyopia there were 12 with corneal opacities, but no case of retinitis pigmentosa was observed.

MARTIN (159) defends the theory of astigmatic accommodation. As is well known, the examination with the astigmatometer frequently indicates corneal astigmatism, which the subjective examination with the cylindrical glasses fails to verify. Martin explains this fact by assuming that the ciliary muscle contracts in only one axis, thereby changing the curvature of the lens in only one axis, thus correcting the corneal astigmatism. Tscherning and Bull deny this astigmatic accommodation, and assert that the correction of the astigmatism is brought about by an oblique position of the lens (rotation about its vertical axis). In support of his theory Martin cites the frequent disappearance of the correction after the long-continued use of atropine, and the change in the correction ; for the degree of the latter varies during a short period, it decreases or disappears in advancing age and after severe illness, etc. MARCKWORT.

PROSKAUER (160) presents the results of his investigation of 3,216 myopic eyes. He finds that the average visual acuteness of myopes is less than that of emmetropes, and that it steadily decreases with the degree of myopia and the age of the individual. The number of myopic persons diminishes with age. The highest degrees are more frequently found in women than in men. The learned professions and those occupations demanding close application, furnish the greatest percentage of these high degrees. In the low degrees of myopia there is frequently no posterior staphyloma. In 12.3 per cent. of the women and 4.6 per cent. of the men there were chorio-retinal changes at the macula. They were found especially in the highest degrees of myopia and in later life. Opacities of the vitreous were found in 39 cases, detachment of the retina in 23.

VALK (162) finds benefit from correcting an astigmatism as low as 0.25 D. BURNETT.

In eighteen months WHITE (163) has seen in private practice 453 cases of refractive troubles, and 115 cases of muscular defects (heterophoria). Of these latter there was esophoria in 51 cases, exophoria in 34 cases, hyperphoria in 31 cases. He has performed graduated tenotomy 60 times, and resection of a piece of the weak muscles 18 times. No operation was done until all other means had failed, and in all the patients were cured of their asthenopia. BURNETT.

VII.—LIDS.

164. CHANTRE. Étude sur la restauration des paupières. *Thèse de Lyon*, 1891.

165. CHISHOLM, F. M. The eccentric growth of eyelashes. *Amer. Journ. Ophth.*, April, 1891.

166. DENTI. Rinoblefaroplastica col metodo indiano. *Boll. d'ocul.*, vol. xiii., 11–12.

167. GILLET DE GRANDMONT. Nouvelle opération du ptosis congénital. *Rec. d'opht.*, 1891, p. 267.

168. GOULD, G. M. Superciliary entropium. *Med. News*, June 27, 1891.

169. NOVELLI. Di un caso di blefaroplastica della palpebra superiore. *Boll. d'ocul.*, vol. xiii., 7.

170. RAEHLMANN, G. Primary new formation of hairs on the intermarginal edge of the lid as the usual cause of trichiasis. *v. Graefe's Arch. f. Ophth.*, vol. xxxvii., 2, p. 66.

171. WEISS, L. The pathogeny of chalazion. *Zeh. klin. Monatsbl. f. Augenhk.*, vol. xxix., p. 206.

172. WICHERKIEWICZ, B. Sur une nouvelle méthode blépharoplastique. *Rev. génér. d'opht.*, 1891, p. 7.

CHANTRE (164) recommends the formation of lids according to Tripier. For the lower lid a bridge-like flap is taken from the upper, containing skin and orbicularis muscle. By transplanting the muscle, closure of the lower artificial lid is sometimes said to be obtained. In forming the upper lid a similar flap is taken from the forehead above the eyebrows. MARCKWORT.

In CHISHOLM'S (165) two cases an eyelash had grown from the free border of the upper lid into the integument, forming a bluish line about half an inch in length running directly upward.

BURNETT.

DENTI (166) has never seen any noteworthy results from the treatment of epithelioma of the lids with pyoktanin. In a well-developed case, in which the treatment with the chlorate of potassium produced only a temporary scar, he made a radical extirpation of the neoplasm and covered the defect, which included half of both lids and the skin from the inner canthus to the bridge of the nose, with a flap taken from the forehead. Healing proceeded without interruption. The palpebral fissure was formed later, and the reunion of the cut was prevented by introducing a small triangle of skin at its inner end and fastening it with a suture. The palpebral fissure formed in this manner permitted the eye to exercise its functions, and had remained unchanged at the end of a year. DANTONE.

GILLET DE GRANDMONT (167) describes a new operation for ptosis, which might be described as tarso-muscular resection. After the introduction of Snellen's lid clamp, an incision is made through the skin of the lid 2½ *cm* long, 3 to 4 *mm* from the edge and parallel to it; excision of the orbicularis muscle and exposure of the whole tarsus; incision 2 *cm* long through the whole thickness of the tarsus and lid to the clamp, this incision being also parallel to the edge and 2 to 4 *mm* from it. From the ends of this cut a second in shape of a crescent with the convexity upward is made through the tarsus, dividing everything down to the clamp, so that the piece of cartilage lying between these two incisions is removed. The height of the convexity of the second cut depends upon the greater or less effect desired. The two parts of the tarsus are united with three catgut sutures, none are applied to the skin. MARCKWORT.

Under the name of superciliary entropium GOULD (168) designates that condition in which the long hairs of the eyebrows in old people curve down and inward and rub on the eyeball through the palpebral opening. BURNETT.

NOVELLI (169) reports a successful case of blepharoplasty with a flap taken from the temple in extensive ectropium of the upper lid resulting from burns. DANTONE.

Distichiasis or trichiasis respectively is caused according to RAEHLMANN (170) by proliferation of the epithelial stratum, due to long-continued hyperæmia of the blood-vessels of the lid-margin. This proliferation can and frequently does give rise to the new formation of hairs and sebaceous glands, when it has reached a certain degree.

WEISS (171) introduced pieces of freshly removed chalazion into the anterior chamber of rabbits. In not a single case did tuberculosis of the iris develop, and the tissue introduced was soon absorbed. It follows that chalazion is not the result of local tuberculosis, as Tangl has asserted. Deutschmann came to the same conclusions as Weiss.

After removing the upper lid, on account of melano-carcinoma, WICHERKIEWICZ (172) performed blepharoplasty by taking a pedunculated triangular flap with its apex upward from the lower lid, using it to cover the defect. Six days after the operation he completely severed the broad base from the lower lid. In forming the flap he cut through the whole thickness of the lid, taking, therefore, more than the mere skin. MARCKWORT.

VIII.—LACHRYMAL APPARATUS.

173. CHIBRET. Nouvelle série d' ablations de la glande lacrymale palpébrale. *Rev. génér. d'opht.*, 1891, p. 3.

174. FICK, A. E. On tuberculosis of the lachrymal sac. *Correspondenzbl. f. Schweizer Aerzte*, 1891.

175. TERSON, A. Sur la déstruction du sac au thermocautère et son exstirpation totale dans les fistules et tumeurs lacrymales rebelles. *Arch. d'opht.*, vol. xi., 3, p. 224.

CHIBRET (173) reports fourteen cases more of removal of the palpebral lachrymal gland according to de Wecker. In four cases considerable lachrymation persisted, and Chibret therefore tried to increase the effect by touching the insufficiently excised parts with the thermo-cautery. In three of these four cases he obtained a good result in this way, in the fourth no effect whatever was produced. MARCKWORT.

FICK (174) observed in a patient, aged twenty-six, tuberculosis of the lachrymal sac, which at first had the appearance of dacryocystitis. An incision proved it to be tuberculosis. The pre-auricular glands, the lymph glands at the lower jaw, and the neck of the same side were swollen. The lachrymal sac was excised.

TERSON (175) first presents a review of the treatment of chronic affections of the lachrymal passages, especially the fistulas and ectasia of the sac. He recommends the application of the thermo-cautery in all cases of fistula in which the ordinary methods of treatment are insufficient, where the naso-lachrymal

duct is obliterated, in which a constitutional disease exists, or in which an affection of the nasal cavities prevents recovery. Similar treatment should be adopted in cases without fistula in which probing has failed and dilatation of the sac has developed. After extensive incision of the sac under narcosis, and cessation of the hemorrhage, the author introduces a Pacquelin thermo-cautery, bent and ending in an olive according to Panas, and extensively cauterizes the whole inner surface, especially the upper part. The sac is then filled with iodoform gauze, which remains in place for two days. No pain is said to follow, and the symptoms of irritation in the surroundings are very slight. The iodoform pledgets are introduced until the floor is seen to rise. After the healing, complete obliteration is the rule; sometimes it is only partial, and the channels of efflux remain open, while the fistula is cured. The chemical caustics may be used when there is hope of keeping the canal patent. The author reports three cases cured with the cautery and one by extirpation of the sac, and describes the structure of the latter after removal, with illustrations. Extirpation, with or without subsequent cauterizing with the thermo-cautery, is especially indicated when the sac is much distended and closed.

v. MITTELSTÄDT.

IX.—MUSCLES AND NERVES.

176. DERBY, R. H. Successful effort to restore binocular vision by a partial tenotomy of the superior rectus. *N. Y. Med. Rec.*, May 16, 1891.

177. D'OENCH, F. E. A case of traumatic paralysis of the abducent and oculomotor nerves. *N. Y. Med. Rec.*, April 4, 1891.

178. DUNN, J. A case of injury to the left supra-orbital nerve. *N. Y. Med. Jour.*, May 20, 1891.

179. HANSELL, H. F. A clinical study in the diagnosis and treatment of hyperphoria. *Amer. Journ. Med. Sci.*, April, 1891.

180. HOOR, K. The etiology of acquired nystagmus. *Wiener klin. Wochenschr.*, 1891, No. 18.

181. LIEBRECHT. The etiology and prognosis of paralysis of the ocular muscles. *Münchener med. Wochenschr.*, 1891, No. 24.

182. QUINLAN, F. J. A case of convergent squint corrected by Adams' modified operation for deflected septum. *N. Y. Med. Rec.*, May 20, 1891.

183. SIEMERLING, E. On chronic progressive paralysis of the ocular muscles. *Arch. f. Psychiatr.*, vol. xxii., supplement.

184. TAMAGNI. Della paralisi di convergenza. *Ann. di ottalm.*, vol. xx., 1–2, p. 68.

185. WILSON, H. A contribution to the study of the ocular muscles. *Journ. Ophth., Otol., and Laryng.*, April, 1891.

DERBY (176) reports two cases in which he has made a partial tenotomy of the superior rectus for weakness of the inferior, and in both he was successful in restoring binocular vision, and the asthenopia disappeared. BURNETT.

In D'OENCH's (177) case a boy ran a rib from an umbrella into his right eye near the inner canthus and close to the orbital margin. Movement limited outward and upward. Recovery in about two months. BURNETT.

In DUNN's (178) case a man was struck with a stone on the left supra-orbital region. The symptoms, referable to the eyes, which developed were diminished visual acuteness ($\frac{18}{40}$), restricted visual fields in both eyes, spasm of accommodation, clonic contraction of the orbicularis of the lower lid. All these symptoms subsided on section of the supra-orbital nerve. It is curious that the same patient suffered from somewhat the same symptoms from an injury to the brow of the other eye, which were also relieved by section of the nerve. BURNETT.

HANSELL (179) concludes from his experience that hyperphoria is a real affection, though it does not always give rise to asthenopia, and that there are reflex phenomena in highly sensitive persons affected with hyperphoria which are not due to it. It does not depend upon errors of refraction. Tenotomy and not prisms, is the treatment, and the tendon should be completely divided. He reports six cases, three of which were treated successfully. BURNETT.

LIEBRECHT (181) reports on seventy cases of paralysis of the ocular muscles which were kept under observation for some time at Schöler's clinic in Berlin. In twenty-one the cause could not be discovered, six were due to syphilis, twenty-five to tabes, seven to general paralysis, and the remainder to various causes.

In QUINLAN's (182) case a boy with a deviating septum was also affected with converging strabismus. On relief of the trouble in the septum by means of Adams' operation, the squint disappeared. BURNETT.

SIEMERLING (183) has finished and published a paper on progressive paralysis of the ocular muscles, which he found after Westphal's death among his papers. It is based upon eight cases observed clinically, after death, and microscopically. In every one there was paralysis of varying degree of the twelve external muscles of the eyes, and always as an affection accompanying a psychosis. In all, the nuclei of the abducent nerves and the roots had degenerated, in one case only on one side, in many also the nuclei of the trochlearis and their roots. The affection of the nuclei consisted in degeneration of the ganglion-cells, diminution of the number of fibres in the nucleus, with participation of the basal tissue ; hyperæmia and proliferation of the ependyma were not always found. In the cases described the cause of the progressive paralysis was an affection of the nuclei involving also the muscles and nerves, but also of the two latter only, the nuclei being sound, or sclerosing foci in the course of the intramedullary roots of the nerves, the nuclei, muscles, and nerves not being affected. In two of the eight cases the spinal cord was healthy, in three there was sclerosis of the posterior columns, in two there was an affection of both the posterior and lateral columns, in one there was chronic anterior poliomyelitis besides. Chronic progressive ophthalmoplegia is sometimes the precursor or part of an affection of the nervous system, in which sometimes the spinal, sometimes the cerebral, sometimes both groups of symptoms are most prominent. As regards the psychic disturbance, it generally follows the paralysis of the ocular muscles. Although we are familiar with cases of chronic paralysis of these muscles which run their course without any complication on the part of the nervous system and may continue for decades without it, yet it is worthy of note that in scarcely any case in which an autopsy was performed a complicating nervous affection was absent, while many ended in insanity.

According to TAMAGNI (184), asthenopia of convergence with diplopia, which Parinaud has designated as paralysis of convergence, is nothing but concomitant strabismus, in which the eye which is not used for fixation has been unable to suppress its double image. The author comes to this conclusion after careful examination of such a case. DANTONE.

In 114 cases suffering from asthenopia, WILSON (185) found in hypermetropia, lateral orthophoria, just equilibrium in 14 %, vertical orthophoria in 37 %. In myopia the orthophoria was lateral

in 5 %, vertical in 12 %. In emmetropia, lateral 7 %, vertical 7 %. All the rest had heterophoria of some kind. He reports twenty-two operations for hyperphoria by partial tenotomy. Permanent relief in nine, none in five, others doubtful. BURNETT.

X.—ORBIT AND NEIGHBORING CAVITIES.

186. WÜRDEMANN. H. V. Metastatic abscess and cellulitis of the orbit following double suppurating chancroidal buboes of the inguinal region. *Amer. Journ. Ophth.*, May, 1891.

In WÜRDEMANN's (186) case the orbital abscess was attendant upon suppurating bubo, and an enucleation had to be done finally. BURNETT.

XI.—CONJUNCTIVA, CORNEA, SCLERA, ANTERIOR CHAMBER.

187. CAUDRON. Tumeurs gommeuses de la conjonctive. *Rev. génér. d'opht.*, 1891, No. 4.

188. DE SCHWEINITZ, G. E. A case of persisting hemorrhage from the conjunctiva of a new-born infant following the instillation of a solution of nitrate of silver. *N. Y. Med. Rec.*, April 18, 1891.

189. GREEFF, R. A remarkable case of pseudo-trachomatous inflammation of the eye. *Arch. f. Augenhk.*, vol. xxiv., p. 60.

190. LOPEZ. Granular ophthalmia in the negro. *Sociedad de Estudios Clinicos*, April 17, 1891.

191. RUMSCHEWITSCH. The oncology of the conjunctiva. *Zeh. klin. Monatsbl. f. Augenhk.*, vol. xxix., p. 261.

192. RYERSON, G. S. Extreme cases of pterygium. *N. Y. Med. Rec.*, May 9, 1891.

193. SCOTT, KENNETH. Result of operating in cases of xerosis co-existing with trichiasis. *Oph. Rev.*, 1891, No. 116.

194. SEDAN. Le trachome. *Rec. d'opht.*, 1891, p. 208.

195. SNELL, S. The prevention of ophthalmia neonatorum. *Lancet*, 1891, p. 926.

CAUDRON (187) reports a case of syphilitic gummata of the conjunctiva. They were destroyed with the galvano-cautery. Three months later there was a relapse. A permanent cure was effected by general anti-syphilitic treatment. MARCKWORT.

In the case of DE SCHWEINITZ (188) a solution of nitrate of

silver—20 grs. to ℥ i.—was applied to the healthy conjunctiva of a negro child, after Credé's method, at birth. In eight hours a bloody discharge set in. At the end of the third day the hemorrhage was replaced by a slightly purulent discharge, and a small ulcer developed on the cornea. There was no hemorrhagic diathesis in the family so far as could be learned.

BURNETT.

As a contribution to the question of trachoma, GREEFF (189) reports an interesting case of granular conjunctivitis in a boy aged fourteen. The picture resembled follicular trachoma. Perfect spontaneous recovery. Greeff believes that trachoma and follicular conjunctivitis are quite different diseases, though they may at first present the same clinical symptoms. (Will be translated, K.)

At the meeting of the "Sociedad de Estudios Clinicos," on April 17, 1891, LOPEZ (190) brought up the often discussed subject of the existence or non-existence of trachoma in the negro, with the object of learning the experience of observers in Cuba. After an animated debate, Montalvo and Santos Fernandez agreed with Lopez as to the rarity of the disease. According to the statistics of the two latter, the ratio was 1:2400 and 1:2200.

RUMSCHEWITSCH (191) describes a melanotic sarcoma of the plica semilunaris and an angiosarcoma of the conjunctiva of the lids.

RYERSON (192) reports two cases of pterygium covering the pupil, in which he made a small iridectomy down and out, with great benefit. The pterygia were not removed. BURNETT.

SCOTT (193) finds that remedying the trichiasis greatly improved the xerosis of the conjunctiva and cornea. WERNER.

SEDAN (194) discusses the methods of treating trachoma which have lately been proposed, some of which are old, others new—for instance, the treatment with nitrate of silver, sulphate of copper, washing with sublimate, rubbing the conjunctiva with sublimate, treatment with boracic acid, scraping, etc. Sedan is opposed to all of these, and favors only jiquirity and excision of the retrotarsal fold. MARCKWORT.

SNELL (195) is inclined to believe that careful cleansing of the infant's eyes with plain water, taking care to avoid secondary infection in the bath, may be sufficient to prevent ophthalmia.

WERNER.

196. CAMO, J. L'opération du staphylome. *Arch d'opht.*, vol. xi., 3, p. 365.

197. CZERMAK, W. Further contributions to the knowledge of corneal fistula. *v. Graefe's Arch. f. Ophth.*, vol. xxxvii., 2, p. 58.

198. FERDINAND, G. Treatment of some forms of corneal opacities by rubbing. *Times and Register*, vol. xxii., 22, p. 456.

199. GALEZOWSKI. De la suture de la cornée et de la sclérotique. *Rec. d'opht.*, 1891, 4, p. 262.

200. HIRSCHBERG, J. A case of keratoconus. *Centralbl. f. prakt. Augenhk.*, 1891, p. 245.

201. INOUYE. Peculiar opacity of the cornea. *Centralbl. f. prakt. Augenhk.*, 1891, p. 244.

202. MARLOW, F. W. Two cases of interstitial keratitis occuring in the tertiary stage of acquired syphilis. *N. Y. Med. Journ.*, June 13, 1891.

203. NIEDEN, A. The value of fluorescin staining in treatment with the galvano-cautery. *Centralbl. f. prakt. Augenhk.*, 1891, p. 129.

204. SIMI. Hypopyon-keratitis. *Boll. d'ocul.*, vol xiii., 9.

FERDINAND (198) gently rubs corneal opacities with a rubber eraser every second day. V in one case rose from $\frac{6}{18}$ to $\frac{6}{9}$.

WERNER.

INOUYE (201) describes a case of enormous numbers of punctate opacities of the cornea without pericorneal injection.

MARLOW (202) reports two cases of interstitial keratitis occurring in the tertiary stage of acquired syphilis, one in a man of 39 and the other in a woman of 57. BURNETT.

In the galvano-caustic treatment of corneal affections NIEDEN (203) recommends the use of fluorescin, as with its aid the diseased tissue can easily be distinguished from the healthy.

Under the date of May 2d, the time at which the harvest begins, SIMI (204) discusses hypopyon-keratitis so common then among the Italian laborers in the fields, and cautions physicians not to neglect affections of the lachrymal sac in their patients, as even a slight abrasion of the cornea may lead to purulent infiltration and destruction of the membrane if blennorrhœa of the lachrymal sac exists at the same time. DANTONE.

Sections XII.–XXI. Reviewed by Dr. P. SILEX.

XII.—IRIS.

205. Acosta. The frequency of specific iritis. *Revista de las Clinicas Médicas*, April, 1891.

206. Liebrecht. Gummous iritis in hereditary syphilis. *Zeh. klin. Monatsbl. f. Augenhk.*, vol. xix., p. 184. (Child 7 months old, death).

207. Vossius, A. On iritis with nodular neoplasms resembling tubercles. *Beiträge zur Augenhk.*, No. 2, 1891.

Acosta, (205) found from the statistics of Santos Fernandez, based on 21,000 patients, that gummous iritis forms 4 % of the whole number and 52 % of all cases of iritis. The gumma is the only characteristic symptom, and that is found only in rare cases.

Burnett.

Vossius (207) presents the clinical history of six cases and a bibliography of the subject. Four of his patients were females aged respectively 16, 17, 31, and 39, and two males of 14 and 15. Some of the tumors resembled tubercles, others gummata or syphilitic papules respectively, which affections, however, could be excluded by the clinical course and experiments. In every case the disease developed under the picture of serous iridocyclitis with deposits on Descemet's membrane, opacities of the vitreous and posterior synechiæ. The nodules disappeared after 4 months at the latest. In conclusion he asserts that there is an iritis attended with the development of nodules on a constitutional basis (tuberculosis, syphilis, leprosy), and another form dependent on the pathological condition of the blood (leucæmia, pseudo-leucæmia) and in disturbed nutrition of the body. The connecting link between the constitutional affection and iritis is probably to be found in diseases of the vascular system (walls thickened and showing hyaline degeneration).

XIII.—CHOROID.

208. Grandclément. Uvéite irienne. *Rec. d'opht.*, May, 1891, p. 257.

209. Rolland. La fluxion périodique du cheval. *Rec. d'opht.*, April, 1891, p. 197.

210. Spierer. Absorption of a piece of bone in the eye. *Zeh. klin. Monatsbl. f. Augenhk.*, vol. xxix., p. 224.

211. TAILOR. Terza osservazione di tuberculosi bulbare. *Ann. di ottalm.*, vol. xx., 3, p. 147.

212. TAILOR. Di un sarcoma endoteliale della chorioidea con degenerazione jalina. *Ann. di ottalm.*, vol. xx., 3, p. 240.

213. VALUDE. Origine de la tuberculose du tractus uvéal. Recherchés expérimentales. *Arch. d'opht.*, vol. xi., 3, 1891, p. 258.

214. WOOD, H. Formation of bone in the choroid. *Arch. f. Augenhk.*, vol. xxiv., 1, p. 49.

According to GRANDCLÉMENT (208) inflammation of the parenchyma of the iris should be distinguished from that of the uveal layer, just as we distinguish pneumonia from pleurisy. The former inflammation of the iris runs its course without any marked symptoms of irritation, yet it produces posterior synechiæ.

MARCKWORT.

ROLLAND (209) produces further proof for his assertion (*Rec. d'opht.*, 1891, p. 80) that the moon blindness of animals is an iritis. Before purchasing a horse he advises the introduction of a 1 % atropine salve into the eye, in order to recognize remnants of this disease, a few synechiæ or more extensive adhesions, which may be of importance for the prognosis. MARCKWORT.

TAILOR (212) describes at length a neoplasm which had developed in the choroid and retina of the left eye of a girl of 11, had broken through the sclera in its upper outer part and had spread out into a tumor 2 *cm* broad. The diagnosis of intraocular tuberculosis was verified after enucleation with the microscope, the neoplasm proving to consist of a conglomeration of tubercles which were embedded in soft, infiltrated tissue developing from the degenerated normal. No tubercle-bacilli, however, were found. DANTONE.

VALUDE (213) endeavored to produce in rabbits with vaccine-tuberculosis of one eye tuberculosis of the other healthy one by an injury. It did not develop either after contusions or stab-wounds of the uveal tractus, even when the autopsy showed general infection. The latter generally did not manifest itself until after the vaccinated eye had perforated. The eye therefore seems to be protected against tubercular infection from another organ, just as the body is protected against general infection from a tubercular eye. Probably the germs are not transmitted through the blood but through the lymph-vessels. Tuberculosis of the eye generally depends upon external infection.

V. MITTELSTÄDT.

XIV.—GLAUCOMA.

215. COLLINS, E. T. Aniridia and glaucoma. *Ophth. Rev.*, vol. x., p. 101.

216. DUNN, JOHN. A case of hemorrhagic glaucoma ; enucleation ; report of the condition of the ball. *Amer. Journ. Ophth.*, May, 1891.

217. TAILOR. Sull incisione dell' angolo irideo (contribuzione alla cura del glaucoma) ; nota preventiva. *Ann. di ottalm.*, vol. xx., 1–2, p. 117.

COLLINS (215) records three cases of glaucoma in eyes with aniridia, in two of which the absence of the iris was congenital, and in one traumatic. Microscopical examination of one of the congenital cases showed that a rudimentary iris nodule, which was not large enough to be seen through the cornea, was adherent to the posterior surface of the latter. In the traumatic case the most anterior ciliary processes were adherent to the cornea.

WERNER.

DUNN (216) reports a case of hemorrhagic glaucoma where the eye was enucleated. There was much hemorrhage from the stump and it was hard to control. There was hemorrhage in the vitreous, in the choroid, and in the iris. There was evidently a sclerosis of all the intraocular vessels. The other eye was unaffected.

BURNETT.

TAILOR (217) describes a new method devised by de Vincentiis for reducing the intraocular pressure, which consists in making an extensive incision of the iris-angle at the lig. pectinatum with a sickle-shaped needle. The instrument, which must be so constructed that after its introduction and during the incision no aqueous can escape, is passed in through the sclera 1½ *mm* from the corneal margin and pushed across to the other side parallel to the iris ; the incision is made in drawing it back. Experiments made on 12 dogs showed beyond a doubt that this little operative procedure reduced the tension, which did not return to the normal until after 2–5 weeks. He then tried it in 8 cases of absolute glaucoma with marked increase of tension. He claims to have obtained a remarkable result : the tension was reduced in every case, in some below the normal ; the symptoms of irritation disappeared. The patients were kept under observation for months ; only one had a relapse.

DANTONE.

XV.—SYMPATHETIC OPHTHALMIA.

218. ABADIE. La question de l'ophtalmie sympathique devant la société d'ophtalmologie de Paris. *Ann. d'ocul.*, vol. cv., p. 108.

219. PONCET. Ophtalmie sympathique. *Soc. d'opht. de Paris*, Feb. 3, 1891.

220. TROUSSEAU. Un cas d'ophtalmie sympathique malgré la résection du nerf optique. *Rev. génér. d'opht.*, 1891, No. 3, p. 97.

According to ABADIE (218) the primarily affected eye should only be enucleated, in case sympathetic ophthalmia has developed in the other, if it has been affected so long and so severely that there can be no more hope of restoring vision. If this is not the case, subconjunctival injections of sublimate may be tried.

MARCKWORT.

PONCET (219) examined six eyeballs which had been enucleated on account of sympathetic ophthalmia, but could find no microbes and therefore denies that the disease is caused by the transmigration of germs. The results of all his examinations were negative as regards the presence of parasites in the sympathizing eye. MARCKWORT.

TROUSSEAU (220) publishes a case of sympathetic ophthalmia after resection of the optic nerve. On Dec. 12, 1890, he exsected a piece of the optic nerve 4–5 *mm* long, followed by thorough disinfection with sublimate solution (1:2000) in a case of cyclitis of the left eye, painfulness to touch and therefore threatened sympathetic ophthalmia. On March 1st, the latter disease broke out. On March 21st, enucleation was performed, and some coagulated blood and serous liquid were found behind the left eye. The sympathetic ophthalmia disappeared under mercurial treatment. MARCKWORT.

XVI.—VITREOUS.

221. HAAB, C. On pseudo-tumors of the interior of the eye. *Beiträge zur Augenhk.*, No. 2, 1891.

In two of HAAB'S (221) patients extraction had been performed without accident, in the third exenteration of one orbit had been done 5 years previously on account of carcinoma. The picture resembled that of intraocular tumors, but the tension was never increased, and in all three cases the pseudoplasms soon disappeared. He thinks they were not detachments of the

choroid, but cysts at the periphery of the retina, such as are not infrequently observed in later years. He recommends puncture to settle the diagnosis.

XVII.—LENS.

222. DIMMER, F. The correction with glasses in aphakia. *Zeh. klin. Monatsbl. f. Augenhk.*, vol. xxix., p. 111.

223. FULTON, J. F. Treatment of immature cataract. *Amer. Journ. Ophth.*, May, 1891.

224. HARLAN, H. A case of hernia of iris occurring on third day after cataract extraction without iridectomy ; hernia replaced ; recovery. *Arch. of Ophth.*, vol. xx., 1, p. 81.

225. PARINAUD. Il prolasso dell' iride nella estrazione della cateratta. *Boll. d'ocul.*, vol. xii., 10.

226. SCHNABEL. Remarks on cataract in children. *Oestr. Ung. Centralbl. f. d. Med. Wissensch.*, No. 26, p. 547, 1891.

227. VAN DUYSE. De l'hémorrhagie choroidienne grave dans l'extraction du cristallin cataracté. *Ann. d'ocul.*, vol. cv., p. 112.

228. VENNEMANN. Un cas de lenticône double antérieur. *Ann. d'ocul.*, vol. v., p. 158.

229. WAGENMANN, A. The anatomy of the thin secondary cataract, with remarks on the healing of wounds in Descemet's membrane. *v. Graefe's Arch. f. Ophth.*, vol. xxxvii., 2, p. 21.

DIMMER (222) : "It seems proven that when in aphakia a sphero-cylindrical glass is prescribed after the usual form of examination, the glass furnished by the optician over-corrects the eye. This is especially true of lenses of more than 10 D combined with cylinders, and vision may thereby be materially reduced. To obviate this it is advisable to make the refractive determination with a plano-convex spherical glass, which is placed in front of the cylinder in the trial-frame."

FULTON (223) reports the results of 25 extractions of immature cataract without iridectomy, all successful. He makes a large corneal incision and when necessary washes out the corticalis remaining in the anterior chamber with a boric acid solution. He does not favor the methods of hastening the maturation of cataract.

BURNETT.

VAN DUYSE (227) reports some new cases of destructive hemorrhage from the choroid after extraction. In the first (from

the practice of Bribosia) the hemorrhage destroyed both eyes which had been operated on at one sitting. In the second (also Bribosia's) the hemorrhage began on the second day in one eye while the other healed without accident. He also briefly reports two cases from the practice of Coppez. In a very long paper Van Duyse then discusses the causes of these hemorrhages. The principal result, however, seems to be that we do not know them.

MARCKWORT.

VENNEMANN (228) publishes another case of lenticonus. The patient claims to have seen well when she was a child ; with the beginning of menstruation, however, vision diminished. At the age of twenty the patient was first seen. V without correction was R $\frac{5}{60}$, L $\frac{1}{120}$. Convex glasses up to 3.5 D as well as concave glasses from 11 to 22 D improved sight. Focal illumination clearly showed the abnormal projection of the lens into the pupil.

MARCKWORT.

(*To be concluded in the next number.*)

BOOK REVIEWS.

Festschrift zur Feier des Siebenzigsten Geburtstages von Hermann von Helmholtz. Stuttgart, 1891. Published by the German Ophthalmological Society.

Reviewed by Dr. S. M. BURNETT.

It is one of the chief glories of Germany that she honors her great men of science. A recent evidence of this fact is a sumptuous volume issued under the direction of the Heidelberg Congress of Ophthalmologists, to commemorate the natal day of one whose name will be intimately associated with ophthalmological science for all coming time.

This volume contains contributions from pupils and followers of the great scientist in all quarters of the globe, and reflects in every respect credit upon its promoters and authors. It contains eighteen separate papers, some of them accompanied with chromolithographic plates, of great beauty as well as accuracy of representation. Space forbids us to go into an elaborate analysis of all these papers, and we can only outline the general tenor of each. But all will repay a careful study.

I.—*Cases of congenital coloboma of the optic nerve and chorio-retinitis striata.* (Plate I.) By Prof. **Sämisch,** of Bonn, and Drs. **Caspar** and **Krüger.** Besides a consideration of other reported cases of coloboma, two observations are detailed. The case of *chorio-retinitis striata* showed peculiar white string- or band-like formations in the background of the eye, probably caused by a congenital inflammation of the choroid and retina, which has been gradually increasing.

II.—*A case of hemorrhagic disease of the retina.* (Plate II.) By **R. Marcus Gunn.** Hemorrhages near several of the tortuous retinal veins, which are due, the author thinks, to inherited gout.

III.—*Unusual appearances in a case of retinal embolism about thirty hours after its occurrence.* (Plate III.) By **E. Nettleship.** The peculiarities of this picture are some arborescent grayish figures along the vessels which run toward the macula region, and the stagnation of the arterial blood-stream without diminution of the blood-column.

IV.—*Anatomical examination of an eye, blind from embolism of the central artery of the retina.* By **Wm. Manz.** A woman of sixty-five had sudden blindness, with signs of embolism of the central retinal artery. Glaucoma developed not long after, and a sclerotomy was made. The patient died, and the eye was removed twenty-four hours after death and examined. An embolism was found in the artery near the anterior part of the lamina cribrosa. The nerve was very much atrophied. The author thinks that some of the changes found are due to a thrombosis of the vessels secondary to the embolism.

V.—*Some rare ophthalmoscopic pictures.* (Plate IV.) By Prof. **Otto Haab.** 1st. Chronic tuberculosis of the choroid (Fig. 1). 2d. Syphilitic disease of the retinal arteries (Figs. 2–5).

VI.—*Contributions to the ophthalmoscopic diagnosis of changes in the vascular walls of the retina.* (Plate V.) By Dr. **Ed. Meyer.** The author recognizes two kinds of changes. Case 1. Transformation of the whole vascular system of the retina into white bands in a syphilitic, who was also affected with chorio-retinitis in the other eye. Some little vision still remained in the eye, while the chorio-retinitis of the other recovered. 2. A girl with inherited syphilis has somewhat the same appearances of some of the vascular walls in the disk. The other kind of changes were noted in the vascular walls in Bright's retinitis. All are pictured in colored drawings.

VII.—*Contributions to the question of tuberculosis.* (Plate VI.) By Prof. **H. Knapp.** In eighteen colored figures the successive stages of two series of inoculation tuberculosis of the eye are represented, the first series (figs. 1–7) ending in recovery, the second (figs. 8–18) in destruction of the eyes by caseation. The tuberculosis bacillus was found microscopically, according to Koch-Ehrlich's method, in all rabbits, as well as by re-inoculation with pieces gained by iridectomy. For the first series (ending in recovery) the grafts were taken from the eye of a man, enucleated for iris-tuberculosis; for the second series, from the conjunctiva of a girl which had become tuberculous after a sub-

conjunctival squint operation. Her eye recovered completely, but all the eyes inoculated from it perished.

VIII.—*Binocular vision in its relations to strabismus.* By **E. Javal.** This is an elaborate paper, with a number of illustrations, of which we can give only the conclusion that binocular vision is totally in disaccord with the theory of projection ; and the author lays stress upon the existence of identical retinal points, in accordance with the experience of the individual, as playing an important rôle in the act.

IX.—*A case of cornu cutaneum palpebræ superioris.* By the Duke **Carl Theodor,** of Bavaria. With a figure.

X.—*Skiascopy ; its history and practical application.* By Dr. **Chibret.**

XI.—*A theoretical exposition of the process of ophthalmoscopic optometry of Cuignet, or skiascopy.* By Dr. **H. Parent.**

In neither of these papers, which contain nothing specially new, is there any mention made of those in America that have helped to extend the use of the method and facilitate its practical application. Parent suggests the names ophthalmo-skiascopy or ophthalmo-photoscopy for the method.

XII.—*The concomitant occurrence of disseminate choroiditis and hemorrhagic retinitis or retinal hemorrhage in the same eye.* By Prof. **Theo. Leber.** Leber points out a connection which he has observed in some recent cases between hemorrhagic papillo-retinitis and disseminate choroiditis.

XIII.—*The rôle of infection by interior channels, or endo-sepsis, in ophthalmology.* By Prof. **Panas.** Panas shows from some very carefully studied cases that there are certain intra-ocular suppurations which are incontestably due to ento-infection, one of the most frequent causes of which he believes to be thrombosis of the vessels of the uveal tract and retina.

XIV.—*On the determination of the visual acuteness after the operation for cataract.* By Prof. **Gayet,** of Lyons. Gayet discusses the causes of diminished visual acuteness after cataract extraction. He doubts whether the capsule is as much at fault as has been supposed, and cautions against the indiscriminate employment of capsulotomy. He thinks some regular uniform system should be used by all operators in testing, so that results may be fairly compared. Among other things, he notes the exercise of the patient in seeing, a uniform illumination of a certain adopted candle-power, and the accurate measurement of aphakia and astigmatism.

XV.—*Contributions to the physiology of the movements of the eyes.* By **E. Landolt.** From a number of apparently very carefully executed experiments on the movements of the eyes in reading, Landolt concludes that we have not added much to the classical work of Helmholtz.

XVI.—*On the persistence of constantly called-for states of innervation as a factor in the latent and manifest lateral deviations of the eyes; a clinical contribution to the innervation theory of concomitant strabismus.* By **G. A. Berry.** This elaborately wrought out paper is intended to show that the innervation hypothesis of strabismus as advocated by Hansen-Grut is not only consistent with the phenomena of squint, but is sustained by the analogy which exists between squint and normal positions in respect to these innervations. He accepts the assumption, that a great existing tendency to convergence leads, under favorable conditions, to manifest convergent squint; and a feeble tendency to convergence, to manifest divergence.

XVII.—*A note on astigmatic vision, and its dynamic correction.* By **Carlo Raymond.** Raymond shows in this paper how corneal astigmatism, of low degrees particularly, can be neutralized so that the patient can have good vision for objects by a contraction of the ciliary muscles as a whole, bringing each meridian successively and rapidly to have a focus on the retina.[1] He does not think it necessary to call in for an explanation a partial or unequal contraction of the ciliary muscle as contended for by Dobowolsky and some others.

XVIII.—*On the objective determination of refraction, and on the electric ophthalmoscope.* By Prof. Schweigger. This is a plea for the accuracy and for the more extended use of skiascopy, with a description of a method of employing the electric light in the ophthalmoscopic examination direct and indirect.

---

[1] Only the principal meredians have foci, the intermediate meridians have none.—H. K.

Obituary.

I. Sir WM. BOWMAN, Bart., F.R.S.,

died March 29, 1892, of pneumonia, at Joldwynds, Dorking, near London. He was born at Nantwich, July 20, 1816. His father was a distinguished naturalist. After his early education, he became a pupil of the Birmingham General Hospital. In 1837 he entered the Medical Department of King's College, and obtained the membership of the Royal College of Surgeons, in 1839. He was appointed demonstrator of anatomy and curator of the museum at King's College. All his literary contributions are original and of lasting value. The earliest are: "The Structure of Voluntary Muscle"; "The Structure and Use of the Malpighian Bodies of the Kidney," an investigation of fundamental importance. In 1847 appeared the first volume of his and Dr. Todd's famous work on the "Physiological Anatomy of Man," the second volume of which appeared eleven years later. In 1848 he was appointed professor of physiology at King's College, which position he resigned in 1855. From 1840 to 1855 he was assistant surgeon, and in 1856 became full surgeon at the College. He was noted for his diagnostic skill and operative excellence. The death of Dalrymple, which occurred soon after, threw the bulk of ophthalmic practice upon Bowman, forcing him, somewhat against his will, to devote his whole time and energy to ophthalmology. His success was complete and unparalleled. His little treatise, "Lectures on the Parts Concerned in the Operations of the Eye," published in 1849, is classical. In 1851 he first published his mode of treating strictures of the tear duct; later, an excellent paper on "Conical Cornea," in which are first mentioned the pupillary shadows, which subsequently have acquired such great importance in the development of retinoscopy. Later he devised

the method of trephining the apex in kerato-conus. Simultaneously with and independently of E. Brücke (who died in 1891) he discovered and described the muscle of accommodation, but never claimed priority for the discovery. He took a great interest in the foundation of the—now flourishing—Ophthalmological Society of the United Kingdom, of which he was made the first president.

More than by his writings, he has served his fellow-men and medical science and art, in particular ophthalmic surgery, by his example and personal teaching. Thousands of young men have received from him most useful knowledge and productive inspiration. His kindness was so genuine, his conduct so gentlemanly, his self-control so complete and constant, and his character so noble, that he had no enemies, but was admired and beloved by every one. His memory will remain sacred to all who knew him, and his name will occupy a permanent position in the history of medical progress.[1] H. K.

II. HASNER VON ARTHA

died Feb. 22, 1892, aged 73. He was professor of ophthalmology at the University of Prague for twenty-eight years, and was distinguished by his energy, industry, originality, and independence. He published a good text-book on eye surgery, and many valuable pamphlets on various subjects of his specialty. He was the most prominent and uncompromising opponent to the brilliant Berlin school under the leadership of A. von Gräfe. Among the few who never adopted v. Gräfe's "modified" cataract extraction he was the most noted, and, before his death, he had the satisfaction of seeing restored to honor Daniel's "simple" extraction, whose champion he had been all his life. Homage to independent conviction and honest work. H. K.

---

[1] For many of the data of this obituary notice, we are indebted to a very appreciative article on the life of Bowman in *The Lancet* of April 2, 1892.

Verlag v.
ARCHIV FÜR AU

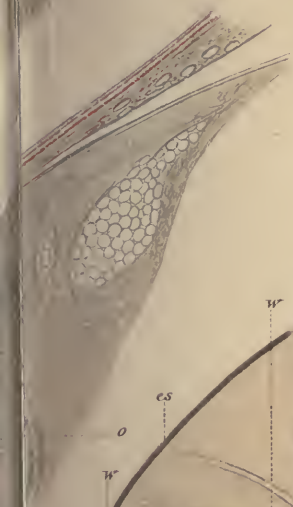

Fig. 5.

Fig. 6.

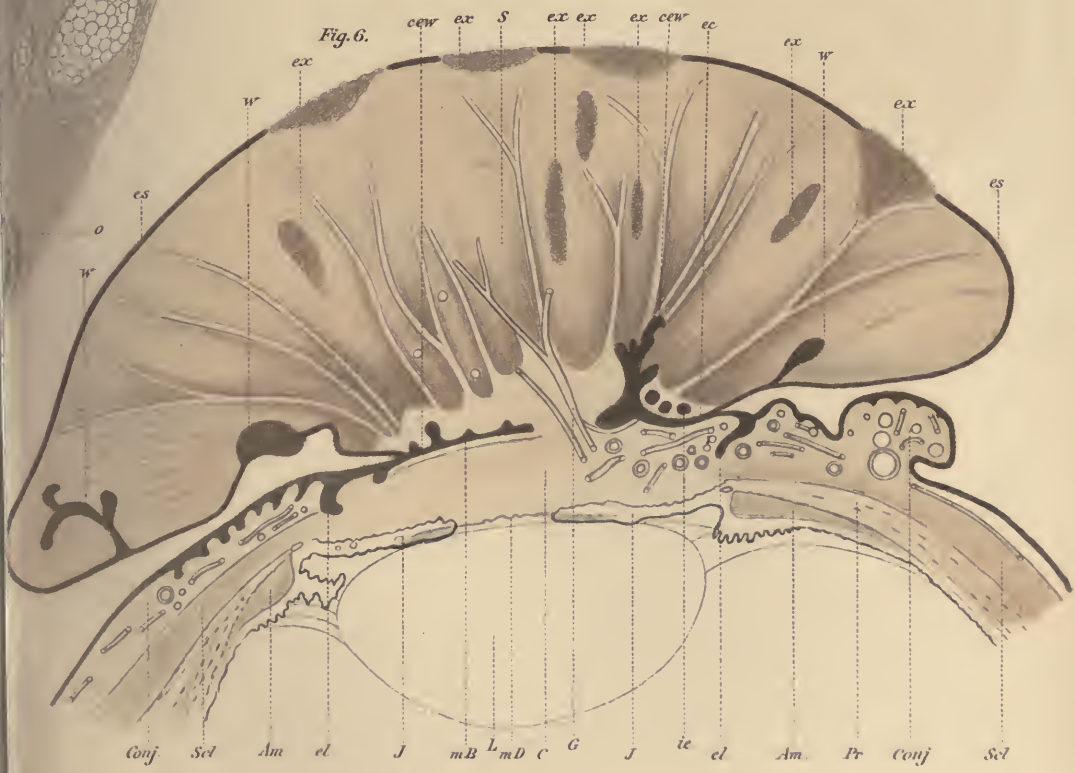

Wiesbaden.
Lith. Anst. v. C. Kirst Leipzig.

a

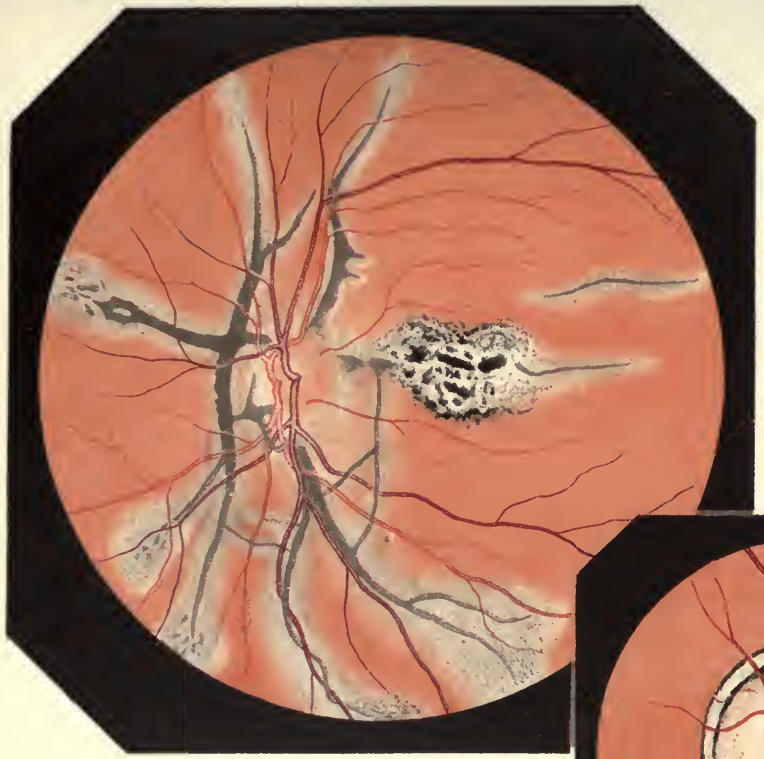

Rechtes Auge.
(Umgekehrtes Bild.)

b

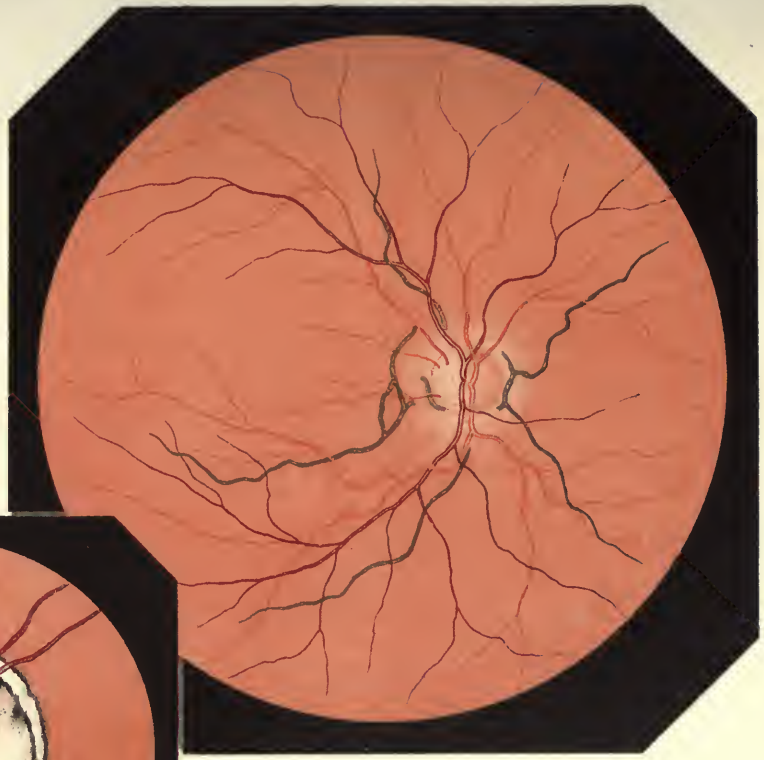

Linkes Auge.
(Umgekehrtes Bild.)

c

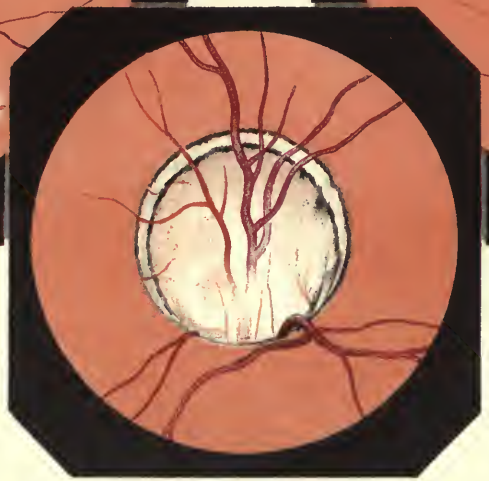

CONTENTS OF VOLUME XXI., NUMBER 3.

1. Does Javal's Ophthalmometer Render the Use of Atropine Unnecessary. By G. Melville Black, M.D., Denver, Colo. . . 333
2. Optic Nerve Atrophy in a Child, following a Fall on the Head, with Severe Cerebral Symptoms. By S. Kohn, M.D., New York, 339
3. On Synergetic Ocular Movements. By Dr. O. Bull, Christiania, Norway 342
4. The Removal of a Tumor of the Optic Nerve with Preservation of the Eye. By the late Dr. Geo. S. Norton. Reported by A. B. Norton, M.D., New York. (With one wood-cut) 354
5. Unusual Family History in Two Cases of Glaucoma. By W. B. Pusey, M.D., Louisville, Ky. 358
6. Another Case of Synchronous Movements of the Upper Lid and Lower Jaw. By Dr. O. Bull, Christiania, Norway 360
7. Attempt to Remove a Chip of Steel from the Background of the Eye Unsuccessful through an Accident which might have been Avoided. By H. Knapp 362
8. A Case of Reflex Micropsia upon Posterior Hypertrophy of the Inferior Turbinates. By John Dunn, M.D., Richmond, Va. . 365
9. A Valuable Experiment Bearing upon Sympathetic Ophthalmia with a Critical Review of the Subject. By Robert L. Randolph, M.D., 367
10. On the Pathology of Circumbulbar Dermoid Cysts. By Dr. J. Mitvalsky. Translated by Dr. Ward A. Holden. (With plates iv., v., vi., and vii., of vol. xxiii. German edition) 376
11. Fifty-four Cases of Cataract Extraction. By J. H. Woodward, M.D., Burlington, Vt. 398
12. Systematic Report on the Progress of Ophthalmology during the Second Quarter (conclusion), and during the Third and Fourth Quarters of the Year 1891. By P. Silex, Berlin; St. Bernheimer, Heidelberg; and C. Horstmann, Berlin. With the Co-operation of S. M. Burnett, Washington; Dantone, Rome; Deus, Berlin; Hirschmann, Charkow; E. Marckwort, Antwerp; P. v. Mittelstädt, Metz; L. Werner, Dublin; C. H. A. Westhoff, Amsterdam; Schiötz and Ole Bull, Christiania. Translated by Dr. Jas. A. Spalding, Portland, Me. 407

    C.—Dr. P. Silex. Retina and functional disturbances, 407; Optic nerve, 410; Injuries, foreign bodies (parasites), 412; Affections of the eye in general diseases, 414.

    A.—Dr. St. Bernheimer. General ophthalmological literature, 417; General pathology, diagnosis, and therapeutics, 418; Instruments and remedies, 419; Anatomy, 424; Physiology, 426.

    B.—Dr. C. Horstmann. Anomalies of refraction and accommodation, 430; Lids, 434; Lachrymal apparatus, 435; Muscles and nerves, 438; Orbit and neighboring cavities, 441; Conjunctiva, cornea, sclera, anterior chamber, 444.

13. Book Reviews 453

    Diseases of the Eye. A Handbook of Ophthalmic Practice for Students and Practitioners. By G. E. De Schweinitz, M.D.

    The Diagnosis of Diseases of the Nervous System. By C. A. Herter, M.D., 454.

14. Miscellaneous Notes 455

ARCHIVES OF OPHTHALMOLOGY.

DOES JAVAL'S OPHTHALMOMETER RENDER THE USE OF ATROPINE UNNECESSARY?

By G. MELVILLE BLACK, M.D., Denver, Colo.,

EX-HOUSE SURGEON TO THE MANHATTAN EYE AND EAR HOSPITAL, NEW YORK; PROFESSOR OF LARYNGOLOGY AND RHINOLOGY IN THE MEDICAL DEPARTMENT, UNIVERSITY OF COLORADO.

AFTER using Javal's ophthalmometer continuously for two years and a half, I have arrived at the conclusion that it is sometimes deceptive; that it will register an astigmatism with or against the rule, when the eye will accept the cylinder in just the reverse axis from that indicated, even after careful tests under atropine. These instances are in the minority, but if such be the fact, even though the number be small, being about 14 per cent., yet it establishes the fact that it is not reliable to prescribe a pair of cylinders upon Javal's test alone. Dr. D. B. St. John Roosa sets forth his views on this matter in the *Medical Record* of March 26, 1892, and says: "It is easy by its use" (the ophthalmometer) "to exactly measure the corneal astigmatism in every case. We can, therefore, I believe, dispense with any mydriatic for the purpose of suspending the accommodation, except in very rare and entirely exceptional cases." He concludes his paper by saying: "The almost complete uselessness of paralyzing the accommodation, when we can now accurately and quickly determine the corneal astigmatism by the ophthalmometer is incidentally shown." Such emphatic statements coming from so high an authority naturally causes me to hesitate and wonder if there is anything amiss in my manner of using the ophthalmometer, that I cannot place more reliance on its readings.

But having been so fortunate as to have been taught to use the instrument by Dr. Roosa, and having used it under his directions for about a year and a half, I naturally feel that I have mastered the instrument, and am using it with precision and accuracy. I find it one of the greatest aids in refraction work, in advance of the ophthalmoscope for that purpose. I would not be without it in my office, and use it as one of my tests in every case of refraction. I, however, have not found it sufficiently accurate to prescribe glasses by it alone. What I mean by alone is, for instance: a patient gives every subjective symptom of eye strain yet will accept no glass. Javal's ophthalmometer shows 1 D ast. with the rule, *i. e.*, ax. 90° for a + cyl., and ax. 180° for a — cyl. The ophthalmoscope is indefinite, shows the eye to be hypermetropic between one half and one dioptry. Would it be right to give this patient cylinders according to Javal's test alone, which we would be doing in this instance, all our other tests being negative? I presume, then, we would be committing no error in such cases to subtract one half dioptry if with the rule, and add one half dioptry if against the rule, from Javal's reading, and give him the cylinders, whether he accepts them or not. I am not in accord with such a view of the case, for it is probable that if atropine or homatropine were used no cylinder at all would be accepted, and if one were accepted it would be exactly in the opposite axis to that indicated by Javal's ophthalmometer.

I find in almost all of my young patients that I cannot satisfy myself sufficiently as to their exact refraction without using some form of mydriatic to suspend the action of the ciliary muscle. I find that homatropine answers the purpose admirably, using a two-per-cent. solution every ten minutes for an hour, with an occasional drop of four-per-cent. cocaine. Or putting a specially prepared disk of $\frac{1}{60}$ grain each, cocaine and homatropine (manufactured by Wyeth) into the conjunctival sac, and having patient sit with closed lids for an hour, when the accommodation will be found completely paralyzed in almost every instance. I prefer the disk to the solution, owing to its being less troublesome and no danger of getting physiological effects,

which will sometimes happen when using the solution in anæmic females.

In looking over my case books I find a great number of cases which corroborate my remarks. I will cite a few that have accepted the cylinders in radically the opposite axis from that indicated by Javal. These patients came to me complaining of the various forms of asthenopia, and by the glasses prescribed and appropriate constitutional treatment have been relieved of their trouble.

CASE 1.—Miss J. T., aged twenty-eight.
O D V = $\frac{20}{200}$; $\frac{20}{15}$ w − 1.75 s ⌒ − .50 cyl. ax. 75°
O D V = $\frac{20}{200}$; $\frac{20}{15}$ w − 1.75 s ⌒ − .50 cyl. ax. 105°
Javal's oph. = O D 1 ax. 75°, O S 1 ax. 105°
Ophthalmoscope = M.
Under homatropine. { O D V = $\frac{20}{200}$: $\frac{20}{15}$ w − 1.50 s ⌒ − .50 cyl. ax. 75°
O S V = $\frac{20}{200}$: $\frac{20}{15}$ w − 1.50 s ⌒ − .75 cyl. ax. 105°

Javal's ophthalmoscope shows this case to have an astigmatism with the rule, and yet minus cylinders are accepted against the rule.

CASE 2.—Mr. H. G. M. Age twenty-six.
O D V = $\frac{20}{20}$; accepts + .75 cyl. ax. 105°
O S V = $\frac{20}{20}$; accepts + .75 cyl. ax. 75°
Javal's oph. = O D and O S 1 D ax. 90°
Ophthalmoscope = H.
Under homatropine { O D V = $\frac{20}{40}$: $\frac{20}{15}$ w + 1.50 s ⌒ + .25 cyl. ax. 135°
O S V = $\frac{20}{40}$: $\frac{20}{15}$ w + 1.25 s ⌒ + .25 cyl. ax. 150°

This case was under homatropine twice. Same result each time.

CASE 3.—Mrs. M. G. Age twenty-eight.
O D V = $\frac{20}{20}$; $\frac{20}{15}$ w .50 cyl. ax. 180°
O S V = $\frac{20}{20}$; $\frac{20}{15}$ w .50 cyl. ax. 180°
Javal's oph. = O D and O S .50 ax. 90° both.
Ophthalmoscope = H.
Under homatropine { O D V = $\frac{20}{40}$: $\frac{20}{15}$ w + .50 cyl. ax. 180°
O S V = $\frac{20}{40}$: $\frac{20}{15}$ w + .50 cyl. ax. 180°

CASE 4.—Mr. H. T. J. Age twenty-four.
O D V = $\frac{20}{20}$; $\frac{20}{10}$ w .75 cyl. ax. 180°

O S V = $\frac{20}{20}$; $\frac{20}{10}$ w .75 cyl. ax. 180.
Javal's oph. = O D and O S = 1 D ax. 90°
Ophthalmoscope = H.
Under homatropine { O D V = $\frac{20}{100}$; $\frac{20}{10}$ − w + .50 s ⌒ + 1 cyl. ax. 180°
O S V = $\frac{20}{100}$; $\frac{20}{10}$ − w + .50 s ⌒ + 1 cyl. ax. 180°

Case 5.—Mrs. W. M. H. Age sixty.
O D V = $\frac{6}{200}$; $\frac{20}{20}$ w − 4.50 s ⌒ − 1 ax. 180°
O S V = $\frac{6}{200}$; $\frac{20}{40}$ w − 4.50 s ⌒ − 1 ax. 180
Javal's oph. = O D and O S 2 D ax. 180
Ophthalmoscope = M.

Owing to patient's age a mydriatic was unnecessary. Javal shows the astigmatism to be against the rule, and the eyes accept the minus cylinders with the rule. I examined her three different times, obtaining the same result each time.

Case 6.—Miss J. F. Age twelve.
O D V = $\frac{20}{50}$; $\frac{20}{20}$ w + .50 s ⌒ + .50 cyl. ax. 180°
O S V = $\frac{20}{50}$; $\frac{20}{30}$ w + 1 s.
Javal's oph. = O D = 1.50 ax. 75°, O S 1.50 ax. 105°
Ophthalmoscope = H.
Under atropine three days { O D V = $\frac{20}{70}$; $\frac{20}{15}$ w + .25 s ⌒ + .25 ax. 180°
O S V = $\frac{20}{70}$; $\frac{20}{15}$ w + .25 s ⌒ + .25 ax. 90°

Case 7.—Mr. L. G. Age forty-one.
O D V = $\frac{20}{20}$
O S V = $\frac{20}{20}$ accepts no glass.
Javal's oph. = .50 ax. 90° both.
Ophthalmoscope = H.
Under homatropine { O D V = $\frac{20}{50}$; $\frac{20}{15}$ w + .50 cyl. ax. 10°
O S V = $\frac{20}{50}$; $\frac{20}{15}$ w + .50 cyl. ax. 170°

Case 8.—Miss L. M. Age twenty-four.
O D V = $\frac{20}{20}$; $\frac{20}{15}$ w + .25 s ⌒ + .50 cyl. ax. 90°
O S V = $\frac{20}{30}$; $\frac{20}{20}$ w + .50 cyl. ax. 180° ⌒ − .25 cyl. ax. 90°
Javal's oph. = .50 ax. 90° both.
Ophthalmoscope = H.
Under homatropine { O D V = $\frac{20}{50}$; $\frac{20}{15}$ w + .50 s ⌒ + .50 cyl. ax. 180°
O S V = $\frac{20}{50}$; $\frac{20}{15}$ w + .75 cyl. ax. 180°.

Case 9.—Mrs. W. B. Age twenty-six.
O D V = $\frac{20}{30}$; $\frac{20}{15}$ w − .50 ax. 70°
O S V $\frac{20}{20}$; $\frac{20}{15}$ w + .50 s.

Javal's oph. = O D 1 D ax. 135°, O S = 1 D ax. 105°
Ophthalmoscope = H.
Under homatropine { O D V = $\frac{20}{70}$; $\frac{20}{15}$ w + .50 s ⌒ + .50 cyl. ax. 165°
O S V = $\frac{20}{40}$; $\frac{20}{15}$ w + .75 s.

Case 10.—Miss J. T. Age nine.
O D V = $\frac{20}{20}$
O S V = $\frac{20}{20}$ accepts no glass.
Javal's oph. = O D .75 ax. 45° O S 1 ax. 90°
Ophthalmoscope = H.
Under homatropine { O D V = $\frac{20}{50}$; $\frac{20}{15}$ w + .50 s ⌒ + .25 cyl. ax. 45°
O S V = $\frac{20}{40}$; $\frac{20}{15}$ w + .50 cyl. ax. 170°

I am very positive about the axis indicated in left eye by the ophthalmometer being at 90°. And yet she persisted in taking it at 170° at three different tests under homatropine.

Case 11.—Miss A. T. Age eight.
O D V = $\frac{20}{20}$
O S V = $\frac{20}{20}$ accepts no glass.
Javal's oph. = O D 1 ax. 60°, O S 1 ax. 90°
Ophthalmoscope = H.
Under homatropine { O D V = $\frac{20}{50}$; $\frac{20}{20}$ w + .50 s ⌒ + .50 cyl. ax. 60°
O S V = $\frac{20}{70}$; $\frac{20}{20}$ w + .50 s ⌒ + .50 cyl. ax. 180°

I think I have cited sufficient cases to show that the ophthalmometer is sometimes in error, and that its addition to our armamentarium, while of inestimable value, does not enable us to do away with atropine in young people. It may be difficult for those not familiar with the instrument to understand the meaning of *with*, and *against the rule*. *With the rule* is where the pointer of the instrument indicates the axis of the meridian of lesser corneal curvature to be at 90° or thereabout, and the two small pointers, projecting outward from each of the mires, shows the axis of the greater corneal curvature to be at 180° or thereabout. To correct this astigmatism, according to Javal, a plus cylinder should be placed before the eye with its axis at 90°, so as to add on to the lesser corneal curvature, or a minus cylinder can be used, its axis being placed at 180° so as to subtract from the meridian of greatest corneal curvature. By the term *against the rule* we mean a condition just

the reverse of the former—*i. e.*, where the instrument shows the axis of the meridian of the lesser corneal curvature to be at 180° and the axis of the greater at 90°. To correct this, according to Javal, a plus cylinder should be placed at 180° or a minus cylinder at 90°. Those who do a great deal of refraction work know that the majority of plus cylinders are accepted at 90° or thereabout and the majority of minus cylinders at or about 180°.

This condition of affairs being in the majority, the minority represents the eyes which accept plus cylinders at 180° and minus cylinders at 90°. And from this come the terms *with the rule* and *against the rule*, the former representing the majority and the latter the minority.

OPTIC NERVE ATROPHY IN A CHILD, FOLLOWING A FALL ON THE HEAD, WITH SEVERE CEREBRAL SYMPTOMS.

By S. KOHN, M.D., New York.

In the early part of March, 1891, I was called to see Hermann Hoexter, æt. seven years. I found him in bed, almost completely comatose.

History: In the morning of the day of my visit, whilst sliding down the banister in the hall of the house where he lives, he fell over the railing of the balustrade, about five steps from the floor, and struck the carpeted floor on the left side of his head, in the parieto-temporal region.

Status Præsens: Respiration regular; pulse normal, not slowed; pupils equally dilated; no response to light. Sensorium so benumbed, that it is impossible to make him answer questions that are asked in the loudest tone of voice possible in a room; calling loud into his ear does not make any impression, and his eyes remain fixed; occasionally he would groan in answer to our questions.

Diagnosis: Cerebral concussion. Ordered calomel, which acted fairly. The following day, the stupor if anything was deeper.

Dr. G. W. Jacoby saw him with me and thought he detected a paralysis of the left arm, because when he lifted it from the bed it fell back limp and lifeless, which was not the case with the right.

Needles introduced into the thighs and calves produced no reflex; but tickling the soles of the feet produced slight reflex contractions of the muscles of the lower limbs.

Dr. Jacoby's prognosis was decidedly unfavorable. His diag-

nosis: hemorrhage into the brain from a fracture of the inner table of the skull on the right side by *contre-coup*. He thought the only chance lay in trephining the skull on the right side.

In the afternoon we met Dr. F. Lange in consultation. He also thought the prognosis grave, not, however, so decidedly unfavorable as Dr. Jacoby, and advised a delay of twenty-four hours before operating. Calomel and jalap were administered in large doses. The following morning after a most thorough purging, the boy became conscious (the fourth day after the injury), and answered our questions, and thereafter made a rapid recovery.

There was a slight rise of temperature, the highest being 101° F. in the rectum. At no time was the pulse slow, intermittent, or irregular.

I should have stated above, that the coma did not set in immediately after the fall. The boy walked upstairs after he fell, told his mother of the accident, complained of headache, and in the course of four or five hours lapsed into unconsciousness, shortly after which he vomited twice. During the coma, lasting seventy-two hours or thereabouts, he was fed from a spoon, swallowing whatever liquids were given him in this way.

When he had been out of bed a few days his mother called my attention to his eyes, and upon examining them I found that he could not see my fingers with the left eye.

Dr. Born saw him with me and found nothing specially noteworthy in the optic disk, but thought that, in all probability, the fracture of the skull, produced by the fall, must have compressed or cut through the optic nerve.

I had noticed a depression of the skull at the point where the left external angular process of the frontal bone meets the frontal process of the malar, and it seemed to me that this depressed fracture must have resulted in a hemorrhage on the anterior surface of the frontal lobe, because the coma came on slowly.

The crushing in of the skull at this point must have produced such a narrowing of the optic foramen that the nerve was completely compressed or cut through.

The hemorrhage cannot have been of large extent, because the recovery without any permanent paralysis was too

rapid; still we must consider that there was some compression of the brain either by the skull or by a clot, to account for the coma lasting over seventy-two hours.

At present, a year after the injury, the boy is perfectly well, except that he is totally blind in the left eye, which shows optic nerve atrophy.

The case is instructive as showing the great reparative and recuperative powers of the child's brain, also its powers of resistance, and is further instructive in showing the care which should be exercised in giving a decided prognosis in any given case of injury to a child's brain. In this case, the decidedly unfavorable prognosis of Dr. Jacoby plunged the parents of the boy into the deepest grief.

ON SYNERGETIC OCULAR MOVEMENTS.

By Dr. O. BULL, Christiania, Norway.

IF we look through the modern ophthalmological literature, we shall find that the doctrine of cortical localization has not modified our opinions on the ocular movements in such a degree as should be expected. The oculists are yet far from appreciating alterations in the cortical centres as a cause of pathological alterations or physiological abnormities to such an extent as the neurologists for the present do. There are certainly some authors who take this factor into due regard, but most of the publications on this subject show that the greater number of ophthalmologists are still, in this respect, entangled in opinions which must be considered obsolete. The latest handbooks may serve as proof of this. Mauthner,[1] for instance, states that experimental investigation, clinical and pathologico-anatomical observations do not admit the introduction of cortical palsy of the ocular muscles. This can only be taken into account as regards the levator palpebrarum, although even this most probably is caused by nuclear alterations. Later on[2] he seems to admit the existence of cortical centres, having observed a case in which the upward movements of the eyes could not be made without an extraordinary effort on the part of the patient. This case, he says, proves, beyond doubt, a peculiar centre for raising the eyes. H. D. Noyes[3] has adopted the opinion of Mauthner.

---

[1] *Vorträge aus der Augenheilkunde*, 1889, Bd. ii., p. 388, and following.
[2] *Ibid.*, p. 688.
[3] *Diseases of the Eye.* New York, 1890.

Landolt et Eperon[1] admit that cortical centres exist, but maintain that we cannot yet give even an approximate idea of their situation.

Scepticism is certainly needed in medicine, but sometimes it may be exaggerated. To doubt the existence of cortical centres for the movements of the eyes would necessarily lead one to doubt the whole doctrine of cortical localization, and we might then just as well adopt the opinion already given up by Andral sixty years ago.

That cortical centres for volitional movements of the eyes exist is just as well founded upon physiological experiments, upon pathologico-anatomical and clinical observations, as those for any other volitional movements. To deny this would be to set aside the investigations by Hughlings Jackson, Hitzig, Ferrier, etc., and fall back on theories quite useless for the purpose of explaining facts easily explicable, if we adopt the theory of cortical localization.

Certainly there is much left to be elucidated concerning the motor centres of the eyes and of the fibres going to and from them, but the same may be said about the nuclei and their reciprocal relations. The latest investigations of Westphal, Darkschewitsch, and Perlia have served mostly to show how defective our knowledge in this matter hitherto has been.

It seems as if the oculists generally have taken but little pains in trying to explain physiological and pathological eye movements, in accordance with the theory of cortical localization. This is the more remarkable, as we have here to cope with the same questions as when other palsies are to be explained.

The situation of the centres for the volitional eye movements —and for those conducted through the eye-branch of the facial—is *most probably at the base of the first and second frontal gyri.*[2] Most likely all the centres for each eye lie

[1] L. de Wecker et G. Landolt, *Traité complet d'Ophtalmologie*, Paris, 1887. t. iii.

[2] That the motor centres of the eye should be located in the occipital lobe or in gyrus angularis, as some authors believe, is improbable, merely for the reason that these are beyond the motor region. That irritations of the said parts produce movements of the eyes, may be explained by the visual impressions thereby occasioned. That deviations or immobility of the globes sometimes

on the opposite side of the brain, analogous to those of the limbs.[1] This does not, however, involve the independent action on each side. We must here keep in mind the predominant influence of the visual impressions which counteract unsymmetrical movements as being repugnant to binocular sight.

From the mode of the movements it must be inferred, that impulses are not forwarded to each muscle separately, but to sets of muscles acting synergetically. This is *a priori* probable from the reason that the organ of vision is our chief reliance in surveying space. For this purpose movements in six directions, corresponding to the three dimensions of space,—viz., upward and downward, to the right and to the left, inward and outward — would suffice. Both experiments and clinical facts argue in favor of the theory that both cortical centres for the muscles acting synergetically, and the fibres leading the synergetic impulses, are in close local relationship. Concerning the centres, the question was settled already by Hitzig. He and after him Ferrier and others have by irritation of the motor centres obtained a deviation of both eyes in a sidewise direction—sideways and somewhat upward. Deviations in any other direction have not up to date, as far as I know, been obtained by experiments, obviously because these were not done on both sides simultaneously. In 1890 Mott and Schäfer,[2] however, have produced conjugated deviations up and down as well as adduction and abduction, by irritating at the same time corresponding places of the corticalis. They have found in the motor-region three zones, 1, upper-

---

are found by destructive processes of the occipital lobe, does not prove that the motor centre is located there. So long as we do not know through which paths the impulses from the volontorium are transmitted to the motor-centres, nothing can be derived from such facts. To suppose that the occipital lobe is the seat of the motor centre is inconsistent with the fact that extirpation of this lobe does not produce palsy. That blindness without palsies repeatedly has been observed from destructive processes of the corticalis in this region, makes it rather certain that the perception-centre is located there.

[1] Already Hitzig, *l. c.*, p. 44, maintained that the centres lie on the opposite side, and he believed he had proved a separate centre at least for each of the four recti.

[2] "On Associated Eye-Movements Produced by Cortical Paradization of the Monkey Brain. *Brain*, t. ii., 1890. I know their *mémoire* only by a short abstract in *Forschritte der Medicin*, Bd. ix., 1891.

most, governing the movements downward; 2, an intermediate for movements to the opposite side; 3, a lower for the movements upward and to the opposite side. The same effect was obtained for one eye only, when the corpus callosum or the motor centres in the corticalis of the opposite side were destroyed. Analogous results were produced by irritation of certain places in the occipital lobe. By simultaneous irritation of centres, having an antagonistic action, in the frontal and occipital lobes, the result from the former was in preponderance.

Already before Hitzig made his experiments Hughlings-Jackson directed the attention to the motor function of some parts of the corticalis. He showed that by irritative processes in certain gyri of the great hemispheres, cramp can result, but that cramp does not attack a single muscle, or set of muscles at random, but a highly specialized set of muscles governing the movements to the side and upward. If destructive processes are present, palsies will result, and then the same muscles are attacked.[1] That the deviations are by affections of the great hemispheres, almost exclusively in side-direction, is in accordance with the experiments.

These lateral conjugate deviations have been much discussed since Prevost in 1868 wrote his work. Deviations in other directions have been hitherto but little heeded, although Priestley Smith and Parinaud several years ago have directed attention to them. The latter divides the synergetic movements into parallel and non-parallel. As the first are made in four, the latter in two, directions, his scheme is in conformity with that of Donders and Hering. Disturbances in one or more of the four pairs, turning the eyes in parallel directions, correspond consequently to what has been described as associated or compensatory palsies. Defects in non-parallel directions have been usually not recognized as palsies. Many cases are, no doubt, related under the neutral denomination "insufficiency of the recti."

About the above-named palsies and their significance in

[1] That the deviation is caused by palsy of the antagonists was concluded by Andral already in 1834.

determining the kind of innervation of the synergetic muscles, some words may here be said.

Parinaud states that palsies of the different ocular muscles[1] (turners, rotators) are not at all rare. I think every oculist who has his mind directed to this subject soon will be able to corroborate this. The frequency of the palsies of the different turners is, however, not alike. In the most cases the side-turners are attacked. An incomplete palsy of one of these turners is, in affections of the great hemispheres, according to some authors (Parinaud, Leichtenstern), very commonly found, but mostly overlooked, as the tonus of the affected muscles need not be so much diminished that the eyes are brought by the antagonists to the opposite side. Anyhow the cases of acquired weakness of one of these turners already referred to are so numerous that a publication of more, at least when these are not elucidated by a post-mortem examination, must be regarded as superfluous. Otherwise, with the bilateral palsies of the same muscles. These have hitherto been published only in a limited number. They have never, so far as I know, been demonstrated as a result of affections of the cerebral hemispheres. In all cases where autopsies have been made, either a general affection of the central system or humors affecting the parts through which fibres from the hemispheres run, collected on a little space, have been proved as a cause. Bilateral palsies of the side-turners are generally, when acquired, also complicated with palsies of other turners, either at the same time or in succession.

AFFECTIONS OF THE MUSCLES MOVING THE EYES PARALLEL.

CASE I: *Paresis of the side-turners and the up-turners.*—P. Lofsberg, aged thirty, Zaalsberg. The patient consulted me April 26, 1888, complaining of weak sight. The movements of the eyes appeared to be very restricted sideways and inward.

[1] If we would adopt the words: right and left side-turners, up-and-down turners, out-and-in turners, special names (such as pleuroplegia for the palsy of the side-turners) would be superfluous. The denominations hitherto used do not properly express the pathogenesis of these palsies.

When both eyes are left open, corneal margin cannot be moved farther than 4 or 5 *mm* from the outer canthus. When one eye is covered the excursion of the other eye is a little larger. Upward he cannot bring the globes farther than that the lower margin of the cornea stands 1 to 2 *mm* from the lower palpebral margin. Most excursive are the movements downward. V r. eye $\frac{4}{36}$, left $\frac{4}{12}$; C blue-yellow $\frac{1}{2}$, red $\frac{1}{3}$, and green $\frac{1}{6}$ right eye; left, pretty nearly normal. Fields of vision restricted outwards. Ophthalmoscopically nothing abnormal.

Five to six years ago the patient was troubled with dizziness, especially when walking in sunshine. At the same time he had double vision. Denied syphilis, but admitted to have had gonorrhœa. The patient was seen once only, wherefore the examination was not completed.

Probably in this case there has been once an affection also of one of the turners moving the eyes in non-parallel direction.

CASE 2: *Paresis of the side-turners, up-turners, and the levatores palpebr.* — Oscar Gustavsen, thirty-nine years, Korsgaden 20, Christiania, called on me April 11, 1890. Some fifteen years previously he had been under treatment for weak sight. Five or six days ago he noticed that he was unable to look up when he had walked about in the street for some hours. When seen, both palpebræ superiores drooped, covering more than half of the corneæ. When the lids were kept up by the observer, the globes were seen to maintain a slight deviation downwards. When he tried to look up, the eyes were set in oscillating movements. They could not be raised over the horizontal plane. The lateral movements were also very imperfect, and were made in an unsteady manner. He was able to bring both eyes some degrees beyond the median plane, but they soon glided back into their position in rest. Convergence was done perfectly. V. $\frac{1}{40}$ both eyes. C. can perceive hues of colored glasses. Ophth., atrophia nerv. optic.

There was some swelling about the ankles. In the urine some albumen. Patellar jerk absent. Syphilis denied. A month later he had regained his power over the levatores palp. and over the up-turners. The paresis of the side-

turners was unaltered. His wife stated that his mental power was decreasing; memory mostly gone.

I saw the patient some weeks ago. He was then much in the same condition.

Of interest in these two cases is the decrease of sight, which has been repeatedly observed in cases of paresis of one or more turners. In No. 2 the paralysis of the levatores palp. is remarkable, as this, in cases where the affection is acquired, but seldom coincides with the palsy of the up-turner.[1] May be that such is the *rôle* in congenital cases. Of such I know only the case related below; but, to judge from the note, referred to in Noyes'[2] handbook, analogous cases have been observed.

CASE 3: *Congenital paralyses of the up-turners and the levatores palpb.*—Gunda Tollepsen, aged twenty, Spydeberg, called on me, because she wanted to have her eyes operated on. She states that she was born with both lids hanging down, and that she never had been able to look upwards. There is complete paralysis of the up-turners and levat. palpb. In order to enlarge her visual field, she holds her head backward. This, together with the downward direction of the look, gives to the patient a very peculiar appearance. The skin covering the upper lids feels a little stiff. Attempts to raise the lids result in contraction of the frontalis only. When the lids are raised by the fingers, and the patient is requested to look upward, she makes excessive convergent movements. The position of the globe in rest is also convergent. Binocular vision not present. Double vision can be called forth, at least, by using luminous objects. The crossed images stand *vertical* and at the same height. V (rainy day) $\frac{4}{6}$, right; left, $\frac{4}{9}$; C normal. Emmetropic. Ophthalmoscope, nothing abnormal. Other malformations not present. No consanguinity between the parents. I saw her but once; she promised to call again, but did not re-appear.

[1] I do not remember to have seen related more than one case in which such was the fact, namely No. iv., by Priestley Smith, *Lond. Ophth. Hosp. Rep.*, ix., p. 25.

[2] *L. c.*, p. 149. "Defect in the levatores palpebrarum and in both superior recti (?) of congenital type must be referred to nuclei. If it should prove correct that in congenital cases the palsy of the levatores were combined with that of the upturners, we would have an analogon to the palsy of the eye-branch of facial in congenital palsy of the side-turners." (Alf. Graefe, Chisolm, Möbius, and Schapringer). It points to an intimate topographical relation between the origin of the nerves in question. In congenital monolateral affections the paresis of levator and the up-turner is often found combined.

From the literature I know about ten cases of paralysis of the up-turners. Beyond these I know two more lately observed by Prof. Hjort of this town, making in all fourteen cases. One of Hjort's patients was somewhat imbecile and had morbus Basedowi. The upper lid was in this case raised to the utmost, and the eye kept directed downward.

The paralysis of the down-turners seems to be very rare. Setting aside the cases of complete ophthalmoplegia, I know only two cases, published by Parinaud and Hulke.[1] In both it occurred together with palsy of the up-turners. Parinaud states that Priestley Smith has seen another case, and refers to *Lond. Ophth. Hosp. Rep.*, 1879, but here is spoken of a patient suffering from palsy of the left-side turner. There is another case, which is much quoted, that of Wernicke,[2] in which the up- and down-turners are said to have been almost completely paralyzed,[3] but from the discussion which followed on Wernicke's communication, it appears doubtful whether or not his case is to be considered a paralysis of the down-turners. Possibly some cases are related under the diagnosis, "cramp of the recti superiores." A differential diagnosis between tonic cramp and paralysis of the antagonist may sometimes be impossible. A case, in which the patient during several weeks was unable to look down, is reported by P. Winge, chief physician of the lunatic asylum in this town.[4] It occurred in a man, twenty-nine years old, who had been a criminal and lived a dissipated life. His father and sister had been insane. The patient had a fit two months before he came to the asylum, and had since been maniacal. When seen his eyes remained steady in an upturned position, so that only a small segment of the cornea was visible. As he gradually became better, the eyes returned to their natural position, but were again turned upwards when he, after some days, got a relapse of his mania.

---

[1] *Lond. Ophth. Hosp. Rep.*, 1881.

[2] *Berlin. klinisch. Wochensch.*, 1876, No. 27.

[3] In *Traité complet d'Ophthalm.*, Landolt and Eperon, p. 803. This case of Wernicke has become two cases with "l'abolition complète des mouvements verticaux."

[4] *Norsk. Magazin for Lægevidenskaben*, 1857.

AFFECTIONS OF THE MUSCLES MOVING THE EYES NOT PARALLEL.

CASE 4: *Paralysis of the out-turner and paresis of the side-turners.*—A. Solberg, painter, aged forty-eight, Königsberg, called on me December 11, 1890. He stated that he, seven or eight years ago, was troubled with dizziness and vomiting. With this exception he was always in good health. Some weeks ago he was seized with influenza, and, since that time, he has had some asthenopia, which is occasioned by a slight conjunctival affection.

On examining his eyes I found that he was quite *unable to make convergent movements.* Also the movements in side-directions were not of normal extent, and were accompanied by jerking movements when the globes were brought somewhat far out. Double images cannot be perceived by the patient. V right eye, $\frac{4}{5}$; left, $\frac{4}{6}$. Ophthalmoscopically, nothing abnormal. The patient believed that he never had been able to move his eyes inward. I saw him six months afterwards. The condition of his eyes was then unaltered.

Besides this case, I have seen two others with incomplete paralysis of the in-turners. In both, impulses to convergence produced nystagmus-like movements. In one of the patients both side-turners acted incompletely and binocular vision was lost. In the other the movements were impaired by looking to the right and downward, by which the nystagmus became very strong.

CASE 5: *Paralysis of the out-turners with paresis of the side-turners.* Jacob Nielsen, farmer's son, aged twenty-six years, Blakjer, was sent to me by Dr. Asker, May 20, 1891. As a baby the patient suffered from fits. One month before seen, he had herpes zoster on the left side of the breast, otherwise he has always been in good health. The sight has been good until six days ago, when it began to fail in the left eye, a cloud gradually coming before it from inwards and below. Left eye in convergence. Whether this has been so always or not he cannot tell. Mobility free upward and downward, but seems to be restricted sideways. The defect in mobility to the left side is greater than to the right. V right eye $\frac{4}{4}$; left amaurosis. Both eyes hypermetropic, 1 D.

Ophthalmoscopically a little hyperæmia of the left disk; right, nothing abnormal. Tension normal both sides. No pain from pressing the left globe backwards. Left pupil does not react to light of any intensity. By convergence good reaction. Ordered potassii iodidum. 23d, patient able to see shadows of the fingers moving before the eye. After that time sight rapidly improved. 27th, Snellen No. 18, 50 *cm;* through colored glasses he can perceive blue. Ophthalmoscop., nothing abnormal. 2d of June, V $\frac{4}{6}$; C blue $\frac{1}{8}$, yellow $\frac{1}{6}$, red and green $\frac{1}{14}$; the last colors[1] sometimes called gray; no constriction of the field of vision. The condition remained the same during a week. The patient then returned home. When seen again 28th of November, V and C on the left eye normal. The position of the eye still in convergence. When objects were brought far out in sidewise direction, the patient used the opposite eye for fixation. When alternately one eye was covered, the position of the screened eye was alike. The defect in mobility to the left still larger than to the right. The distance between the external corneal margin and canthus externus being on this side at least 2 *mm;* when the right eye is covered on the right side under the same circumstances, no more than 1 *mm.* Double images could be brought to perception when one eye was armed with a colored (blue-green) glass and a lighted candle used as an object, but they were always indistinct. The distance between the homonymous images amounted to 3° in sidewise directions. They were standing at the same height and the distance remained the same for *every direction of the look.*[2]

As seen the case is rather a complicated one. The symptoms from the side of the muscles would certainly by many be explained as a double-sided paresis, but if so we should expect the distance of the double images would have been increased, when the object was brought to the left, as on this side the external muscle was the weaker.

---

[1] Physiological green and red on my chromatometrical tables.

[2] The instrument used in such examinations is a phorometer of my own construction. It consists of a rod in which are 5 holes, 4 of which are covered with prisms and one with a plane-glass. The uppermost prism, angle 10°, has its base turned down; the others, angles respectively 10°, 16°, and 20°, to the right side of the patient. The rod can be drawn up and down in order to bring any glass before the eye of the patient. On each side of the rod are two rotating disks with 8 holes in each. Seven of the holes are covered with prisms of respectively 2°, 4°, 6°, 8°, 10°, 12°, and 14° angle. On the right side the

In the congenital and acquired cases of palsy of the different muscles we have a chain of symptoms, which can be explained only by assuming an affection of central paths through which the impulses are led to sets of muscles acting synergetically. This explanation is, however, far from being commonly adopted. Many authors still assert that the causes for these affections are to be sought in affections of single nerves or nerve branches or in such of the nuclei. It is however not difficult to prove that such affections cannot produce the palsies in question. If we take, for instance, a case of congenital paralysis of the side-turners, and try to explain this as a palsy of both abducentes,—such as one of the first authorities on this topic, Prof. Alfred Graefe, has done,—the difficulty to understand why the recti interni should not be able to act by associated movements at once presents itself.

In congenital cases we could assume a nuclear affection. The defect in the nuclei, being intercalary ganglia, had, however, to be explained as secondary, depending on a defect of the cerebral centres. In acquired cases a nuclear affection can be excluded, almost with certainty, as it would be very improbable to suppose that exactly the corresponding points of the nuclei on both sides could be affected and the rest remain sound.

The etiology of these palsies can only be explained in a satisfactory manner by supposing that the centres for the muscles acting synergetically, and the fibres from the centre, lie in a close local relation.

That impulses to synergetic movements are transmitted through separate fibres within the cerebrum must consequently be inferred both from the character of the physio-

---

prisms have their bases turned to the centre of the disk; on the left to the periphery. The rod and the disks are put up in a frame, standing at a right angle to a small table. The table is well fixed, and by screws brought to a horizontal position. In the frame are three holes, one in the middle corresponding to the holes in the rod, and one on each side of this, corresponding to the holes in the rotating disks. Consequently adducting or abducting prisms up to 34° (20° + 16°) can be brought before the eyes of the patient. When the power of adduction is to be tested, the patient places his left eye before the intermediate opening in the frame; if abduction is to be tested, his right eye before the same opening. The instrument is in a way a combination of that invented by Dr. Stevens and that invented by Dr. Schiötz.

logical movements and from the above described palsies caused by affections beyond the nuclei. That the fibres through which impulses to movements—whether volitional or reflected—are conducted, are almost fully developed by the time of birth, must be concluded from the fact that children being few days old move their eyes symmetrically.

The trophic (cortical) centres of these fibres must, as stated before, be supposed to be on the opposite side. That such is the case we must conclude from the existence of total monocular palsy of all external muscles. This is, however, not easy to explain in accordance with the fact that cortical affections of one side only are capable of bringing both eyes in a sideways direction.

The existence of separate centres for volitional movements on each side should enable us to move each eye separately, just as we can move each hand separately. This is true to a certain degree. We can, especially when under the influence of visual impressions, in order to preserve binocular sight, make rather excursive movements to which we in daily life are quite unaccustomed. Such movements require always, especially when made in vertical directions, a strong exertion of the will. Also, such movements may be done, quite independently of visual impressions, as far as I know, only in a horizontal plane. A young man of my acquaintance has the power of moving each eye independently of the other, having first brought both in strong adduction. Keeping, so to say, one eye bound in this position, he lets the other wander with unsteady movements and rather slowly from one canthus to the other. During this he perceives double images in corresponding directions. V in case $\frac{1}{4}$, each eye, and binocular vision present. If independent movements were of any benefit to us, we should perhaps speedily acquire the power of making them. Most movements are, however, done by reflexes called forth by visual impressions. How great their influence is may be concluded from the fact that we involuntarily never make dissociated movements except in sleep and under narcosis.

ANOTHER CASE OF SYNCHRONOUS MOVEMENTS OF THE UPPER LID AND LOWER JAW.

By Dr. O. BULL, Christiania, Norway.

IN these ARCHIVES, vol. xvii., I published an article on this subject. Since then other cases have been reported by Fränkel, Reuss, Bernhardt, and Schapringer. The explanation still generally accepted is that given by Gowers, according to which the levator palp. should in such cases receive fibres from the nuclei of the fifth or seventh pair. That this hypothesis is not plausible I desired to show by publishing the case above referred to. Shortly afterward I had occasion to see the following, in most respects, quite analogous case.

Gunnerius Hansen, sixteen years old, examined July 11, 1888. The patient states that he was born with the left lid hanging down. He wanted to have it raised by operation.

The lid covers three quarters of the cornea. It remains motionless during all movements of the globes, when both eyes are open. On opening the mouth, in speaking and in mastication, it is raised, wherefore the patient, in order to conceal as much as possible the disfiguring appearance caused by the drooping lid, generally keeps his jaws apart. Involuntarily the lid is also raised by keeping the mouth shut and bending the head backwards. Voluntarily he can raise his lid when the other eye is covered, and he can do so to the same extent as when he keeps his mouth widely open, viz., so much that the upper margin of the cornea becomes visible. By putting the orbicularis into action he is able to check the involuntary movements.

Rectus superior on the left side paretic. V normal, both eyes. Ophthalmoscopically nothing abnormal. Double vision present when the left lid is raised.

We have in this case raising of the lid (not of the eye) when the patient opens his mouth as well as when he bends his head backwards; consequently, not only active contractions of the digaster but also passive extension of the said muscle produce involuntary contractions of the levator. Further, the elevator can be voluntarily contracted independently of any action of the muscle innervated by the fifth and seventh pairs, when the right eye is covered and the patient asked to contract his paretic rectus superior. How these facts can be explained by an hypothesis of an abnormal origin of the nerve going to the levator, I am unable to understand. Bearing in mind that the elevation of the lids is often made involuntary by gaping, and still more by turning the head upwards, it seems more plausible to explain the voluntary contractions of the elevator in this and in analogous cases, as associated or as reflex movements. In cases where the raising of the lid is induced by muscular contractions only, an assumption of an irradiation from the motor centres of the muscles in question to that of the elevator may be a more plausible explanation. That anyhow a hypothesis of an abnormal innervation (which must be considered congenital) should be applied to all such cases, we must reject, judging only from the case of Fränkel. Here the drooping of the lid comes on after a lapse of several years, the raising of the lid by chewing having meanwhile become less,

THE REMOVAL OF A TUMOR OF THE OPTIC NERVE WITH PRESERVATION OF THE EYE.

By the late Dr. GEO. S. NORTON,

Reported by A. B. Norton, M.D., New York.

(*With one wood-cut.*)

As only a few instances of the successful removal of tumors of the optic nerve with preservation of the eye have been reported, the following case with successful operation, as made by Dr. Norton, is deemed worthy of record. This report is taken from his case records precisely as it there appears.

Miss J., aged thirty, was first seen on September 25, 1890, at which time she gave the following history: The right eye began to protrude ten or twelve years ago and has steadily increased ever since. For five years she had much sharp pain in the orbit, extending to the back of the head and down to the stomach. Examination showed O D V = $\frac{1}{200}$, O S V = $\frac{15}{15}$. There is a protrusion of the right eye directly outwards of twenty-two millimetres, which, she says, varies at different times, being greater on some days than others, and greater during menstruation, and that the vision seems to be better when the eye is small.

The ophthalmoscope shows the retinal vessels contracted and the optic nerve atrophic. The movements of the eye were as good as could be expected from the amount of the protrusion. The patient was very nervous and would not allow of deep pressure to determine the nature of the growth.

Oct. 7th.—Eyeball protrudes directly forward, so that the

posterior portion of the globe is just even with the outer border of the orbit. No pulsation could be detected. Patient extremely nervous; had a fainting spell with retching before being put on the table for operation, but recovered after taking some whiskey. Ether was given and well borne throughout the operation until just at the end, after the tumor had been removed, when the pulse became so much weakened that a hypodermic injection of brandy was made. Palpation after she was under ether showed a soft elastic tumor behind the eyeball and connected with it. An aspirating needle inserted at the outer canthus drew out a drop or two of serum.

An incision was then made between the superior and internal recti muscles of sufficient size to permit of the finger being passed down to the tumor. Using the finger as a guide, the tissues around the tumor were severed back to the optic foramen. The nerve was then divided at the optic foramen and afterwards severed close to the eyeball. Tumor at once appeared at the opening and was removed.

By rotating the eye the cut end of the nerve could be seen, which appeared clear and white. The socket was washed out with a 1 to 4,000 solution of the bichloride of mercury, the eyeball replaced and covered with the lid. There was but moderate hemorrhage throughout, yet some infiltration of blood underneath the conjunctiva and into the lids, so that the protrusion appeared about the same as before the operation. A compress bandage was applied and the ice-bag used locally. The day following the operation the temperature was 99½° and pulse 102.

Oct. 21st.—The ice was used three or four days. Patient has had no pain at any time. The eyeball protruded greatly for some days, from the infiltration of blood into the orbit and into the lids around, extending even to the other eye. There was quite extensive chemosis below, so that the conjunctiva protruded between the lids. Upper lid greatly swollen, but covered the eyeball; this swelling gradually subsided, so that about the sixth or seventh day the lid retracted, leaving the eyeball exposed, and the cornea became hazy. The eyelid was drawn over the globe and held in place by adhesive strips, which were kept on for four or five days. To-day there is still considerable haziness of the cornea, but has diminished greatly. The eye has sunken back into the orbit, nearly as much as the other eye.

The eye, however, is nearly immovable, especially outward and inward, and stands somewhat outward. The conjunctiva still protrudes between the lids, but is diminishing, and with but slight discharge. No pain or other unpleasant sensations.

Nov. 20th.—Still some swelling at the inner canthus and moderate discharge. Cornea a little hazy below, but clearing. Much better movements of the eye.

Dec. 18th.—Optic disc very white, but from its centre are seen two small vessels running upward for about the distance of the diameter of the optic disc. There are also seen slight choroidal changes. Much less redness of the eye and movements much better.

This was about the last time the patient was seen by my brother, but in order to make the record more complete I requested her to call at my office, which she did on May 3, 1892, about eighteen months after the operation, when I found little if any perceptible protrusion of one eye over the other. The movements of the eye are a trifle limited in all directions, but the eye stands perfectly straight. An oblique illumination of the cornea shows a very slight opacity. The pupil is slightly dilated, but not as much so as one year ago. In fact, the general external appearance of the eye is not noticeably different from the other, and the operated eye could only be told by a close examination. The ophthalmoscope shows the optic papilla of an extremely white glistening appearance, with a faint line showing the position of the central vessels; at the upper part of the papilla there appears a leash of small vessels. There are some choroidal changes a short distance from the disc, and in the lower part of the field there appear to be two good-sized retinal vessels. The fundus in all other respects appears normal.

In the special effort to save the tumor for microscopical examination a fresh solution of Müller's fluid was procured from a presumably reliable pharmacist, but, unfortunately, it was not properly prepared, so that instead of hardening the tumor it entirely disintegrated and destroyed it within a few days. Judging, however, from the macroscopical appearance of the tumor, it was a myxoma.

The accompanying illustration was made immediately after the removal of the tumor, and is its exact size and shape. The covering of the tumor seemed to be formed by the dilated sheath of the nerve. The structure of the tumor

seemed to be of a gelatinous substance held together by a cellular network; the nerve fibres, apparently passing directly through the centre of the tumor, and after removal of the tumor appeared as though they had retracted into the substance of the growth.

UNUSUAL FAMILY HISTORY IN TWO CASES OF GLAUCOMA.

By W. B. PUSEY, M.D., Louisville, Ky.

THE following cases are of sufficient interest, I think, to justify a report. Although the cases in themselves do not differ from numerous others of a similar character, the family history given is very unusual. I have seen in any of the reference books no mention of heredity in glaucoma, yet both cases here reported present indisputable evidence of such an influence at work in its causation.[1]

Case 1. John C., aged seventeen years, white, vigorous, well-developed, and intelligent, describing concisely his trouble and great family misfortune. Seven months before presenting himself for examination had had a severe attack of *neuralgia*, involving the left eye, then a few hours later the right, and occasionally for about thirty-six hours in each. The pain was intense, and vision greatly blurred. The usual rainbow shades around a flame were very noticeable. After the subsidence of this attack the vision improved. In about four weeks he had another, and in a short while still another attack, with steady and final complete loss of vision. I now find the eyes in about the same condition: marble hard, painful; pupils dilated; chamber shallow; vitreous hazy; sclera thinned; and vision in right eye equal to faint, uncertain perception of light centrally. In the left it is zero. Instillations of eserine sulph. accomplished nothing; nor did the iridectomy, which was done with only the faintest hope of any resulting good, afford any relief. It was simply a typical

[1] Hereditary disposition to glaucoma is not very rare, but seldom is it so pronounced as in Dr. Pusey's cases.—H. K.

case of too long-neglected glaucoma which is so frequently met with. The onset of the disease in its acute form is so sudden, and its distressing agonies and effects so easily accounted for by the mere suggestion of neuralgia, that medical advice and attention are frequently not sought until the damage is irreparable.

The following is the *family history:* His mother, his mother's uncle, his mother's brother, his sister, his brother, and himself were all blinded by *neuralgia.* His mother and his uncle saw the vari-colored lights around a flame, and he tells of their staring eyes at a later stage. His brother was released from the regular army because of his blindness, due to the same cause, and his sister was operated upon, when fifteen years old, for glaucoma, by Dr. Cheatham; the record of her last visit showing nearly perfect vision. This patient I have seen, and he talks of the others in such a manner as to leave little doubt as to what their trouble was.

CASE 2. I saw in the practice of Dr. Cheatham, and, by his permission, I report it with the preceding.

Will G., age thirteen and a half years. Sight failing gradually for eight months. Pain in head and about eyes. Vision $\frac{8}{200}$ in each, and no improvement with glasses. Visual field contracted, T +. Optic nerve excavation, and arterial pulsation.

His family history is as follows: His father, his father's mother, a brother, and a sister are all blind from glaucoma.

That all these people in the two families should suffer from the comparatively rare affection, glaucoma, is rather too remarkable to be a coincidence, and that in each family there are several persons of the age which is generally accredited with only about 1 per cent. of all cases of glaucoma, is also remarkable.

ATTEMPT TO REMOVE A CHIP OF STEEL FROM THE BACKGROUND OF THE EYE UNSUCCESSFUL THROUGH AN ACCIDENT WHICH MIGHT HAVE BEEN AVOIDED.

By H. KNAPP.

FAILURES being as instructive as successes, mostly even more so, I beg to relate the brief history of the following case.

Mr. Feigenbaum, aged forty, presented himself at the N. Y. Ophthalmic and Aural Institute, September 28, 1891, with a simple plastic iritis of the right eye, for which he received atropine instillations. December 8, 1891, he complained of not seeing quite well with that eye, though all pain and redness had disappeared. On examination with the ophthalmoscope, I found the media normal, but on the inner upper part of the fundus a black, elongated substance, which I at once declared to be a piece of iron. It touched the margin of the optic disc, lay in the retina, projected into the clear vitreous, measured $\frac{2}{3}$ P D in breadth and 3 P D in length. It was surrounded by a white seam, which extended twice as much upward and inward toward the equator. It was the thickened edge of a rupture of the retina which held the foreign body tight, and, beyond it, marked the limits of a perforation of the retina through which the normal choroid could be seen lying bare. On questioning the patient it was ascertained that five months previously a piece of iron struck his right eye while he was hammering a chisel to open a case. The eye was inflamed for two months, and the sight was poor but gradually improved. When I examined him it was $\frac{20}{30}$, and a triangular defect in the visual field upward and inward, with

its apex about 15° from the point of fixation, was made out. No trace of the entrance of the supposed foreign body could be detected. The retina in the vicinity of the foreign body and the perforation was slightly hazy, the optic disc somewhat redder than usual, and beset with a few small hemorrhages. The tension was normal ; no irritation in either eye.

The patient was told that a chip of iron was in the depth of his eye, for which nothing need be done as long as it remained quiet. He was asked to come every week or two to have the eye examined. The eye kept free from irritation until the beginning of April, 1892. Then the sight became impaired from streaks of detached retina, which increased from week to week. At the end of April it was $\frac{20}{200}$, and the field greatly contracted in its inner and upper side.

I advised the patient to let me try to save his eye by drawing the foreign body out, but to allow me to remove his eye if I failed in the attempt. He consented.

Operation.—Under cocaine I laid bare the tendon of the internal rectus, placed a suture through its upper edge and the upper part of the episclera near the corneal margin, and another suture in like manner through the lower edge of the tendon ; left both threads untied, laying them up, respectively down, so as to draw the muscle forward again at the end of the operation. I detached the tendon from its insertion and dissected it, the muscle, and the adjacent episcleral tissue clear off as far as the entrance of the optic nerve into the sclerotic. The posterior half of the ball was then drawn forward by means of a sharp double hook, a small squint-hook passed around the optic nerve, and the sclera incised with a Beers knife in the horizontal meridian from the optic nerve, slightly nasally and upward, about 4″ in length. A drop of vitreous presented. Now I wanted to draw the foreign body into the wound with an electro-magnet, seize it with forceps, and cut it out of its connections. The magnet, which had been found in good order before the operation, did not work, and by examining the wires and their connection, shaking the battery, etc., I could not find out where the current was broken. Not being able to use the magnet, I tried to extract the supposed foreign body with forceps, but brought out only vitreous and shreds of soft pigmented tissue. Not succeeding in taking hold of the foreign body, and thinking that further attempts, even if successful, would destroy the eye anyhow, and possibly en-

danger the other by sympathetic inflammation, I enucleated the eye at once, relieving the pain by instilling cocaine. The patient did not complain much of pain, and made a good recovery.

As soon as his eye was bandaged, I opened the enucleated globe by an equatorial section, and found that a black metallic body, 1 *mm* by 3 *mm* in size, lay close by the incision which I had made into the sclerotic. It was attracted and raised with the surrounding tissue by the electro-magnet, which now worked well again. The commutator had been moved inadvertently, which caused the interruption of the current, but had not been noticed during the operation.

The experience gained from this case shows that the plan of the operation was judicious and the execution correct. The result in all probability would have been satisfactory had the disturbance of the battery not occurred, or been detected during the operation. The method of the operation is the same according to which tumors of the optic nerve have been removed, with preservation of the eyeball, the sheath of the optic nerve incised, and cysticerci extracted from the posterior part of the retina. That it may successfully be applied to the removal of foreign bodies from the posterior segment of the globe seems proven by the above case.

A CASE OF REFLEX MICROPSIA UPON POSTERIOR HYPERTROPHY OF THE INFERIOR TURBINATES.

By JOHN DUNN, M.D., Richmond, Va.

Miss W——, aged eighteen, complained of frequent headaches; of pain about and especially behind the balls of her eyes; of inability to use her eyes any length of time continuously, because use of them caused them to pain, and, especially, because the letters in the part of the page at which she would be looking would get smaller and smaller, and, finally, become too small to read. It is not that the size of the book, or of the page, seems to diminish, but only the letters and the words for about two inches around the word upon which her eyes are focussed for the time, and this diminution in the size of the words "follows" her "eyes all over the page," while the words outside of this area do not seem to be decreased in size. This diminution in the size of the letters is not constantly present when she is reading, but occurs frequently enough to make reading with any comfort impossible. I showed Miss W—— Saeger's test types. "The letters of an ordinary book became as small as those of No. 1," she says. This trouble has existed for about a year. When in the open air Miss W—— has never noticed that any of the objects around her were smaller than she knew them to be; but, frequently, when she would look through a window-pane at objects on the street, they would appear much diminished in size. Has never seen double. No inflammation of the eyes. Fields of vision normal. Miss W—— has never been very strong, and one of her sisters has died of consumption.

Under atropia, refraction for O D and O S was found to be the same $+ \frac{1}{4}$ D, sph. c. $+ \frac{1}{2}$ D, cyl. ax. 90°. Exophoria $\frac{1}{2}$° for

distance. Hyperphoria, possibly, $\frac{1}{4}°$ to $\frac{1}{2}°$, although this is uncertain. Although it seemed little likely that the refractive condition of the eyes was the cause of the trouble, glasses correcting the astigmatism were ordered tentatively. Miss W—— was not seen again for about three months, and then to report that the trouble with her eyes was no better. Examination of the nose was then made. Anteriorly, the middle and inferior turbinate were normal, showing no sign of hypertrophy. Posteriorly the inferior turbinates were found to be immensely hypertrophied, so as to fill up the space between them and the septum. This hypertrophy extended forward for the posterior one third of the inferior turbinates, and except at the posterior ends was chiefly along the lower border of the turbinates. There was considerable mucous secretion from the hypertrophied membrane, so that the inferior air passages of the nose were entirely closed for a distance corresponding to the hypertrophy of the turbinate. The upper air passages were open, so that the nasal obstruction was noticeable to patient chiefly during expiration. The mucous secretion, of course, gave sensation of constant cold in the head. The posterior ends of both inferior turbinates were removed, and patient was given syr. ferri. iod. Since the removal of the hypertrophied turbinates, now more than three months ago, Miss W—— had not been annoyed by the diminution in size of the words while reading.

The micropsia in this case was the result of temporary ciliary paresis; the increased ciliary efforts necessary for accommodation causing a misinterpretation by the brain of the size of the letters. While the general health and, perhaps, the neurotic tendency of the patient prepared the nervous system for the expression of a neurosis, it is highly probable that in the area irritated by the hypertrophied turbinates is to be sought the origin of the nerve waves whose reflex expression was temporary ciliary paresis; the strength of the probability consisting in the fact that treatment directed to the hypertrophied turbinates was followed by disappearance of the ciliary paresis.

A VALUABLE EXPERIMENT BEARING UPON SYMPATHETIC OPHTHALMIA WITH A CRITICAL REVIEW OF THE SUBJECT.

By ROBERT L. RANDOLPH, M.D.,

ASSISTANT OPHTHALMIC AND AURAL SURGEON TO THE JOHNS HOPKINS HOSPITAL AND TO THE PRESBYTERIAN EYE AND EAR HOSPITAL, BALTIMORE; OPHTHALMOLOGIST TO THE BALTIMORE AND OHIO RAILROAD.

IT is seldom that we meet a case where all the conditions are favorable for thoroughly testing the truth of the infectious origin of sympathetic ophthalmia, and I am satisfied that the case here reported, together with the laboratory experiment, form a valuable supplement to my earlier work on this subject.

The following typical case of sympathetic ophthalmia came to the Presbyterian Eye and Ear Hospital early last summer.

J. M., forty-one years old, farmer; while endeavoring to dig out a large stone deeply imbedded in the earth, a piece of the pick broke off and flew into his right eye. This was on June 1, 1891. He kept on, however, with his work though seeing very indistinctly with the wounded eye. He was not conscious of any pain at the time. He continued regularly at his farming for three days longer, when pain and dimness of sight compelled him to rest. He came to the hospital on the fifth day. At this time he had only light-perception left in the wounded eye. The eye was exceedingly sensitive to the touch. He remained in the hospital three days, and left with directions what treatment to follow, and with the understanding that he should return in case the pain persisted. After he had been at home six weeks, and suffering all the time, his good eye began to show signs of sympathy,

photophobia, lachrymation, and dimness of vision, and according to his account he could not see a horse a hundred yards away. Before this he possessed unusally acute vision. His family physician treated him with blisters and cold applications to eye, and sight improved. Thursday, August 13th, he came to the hospital again, and the condition of his eyes was as follows:

In the injured eye light-perception was gone. Eyeball very sensitive to touch. At the point of the wound, the sclera was injected, cornea clear, pupillary margin entirely bound down by adhesions to anterior capsule. His good eye had a vision of $\frac{1''}{200}$. The anterior capsule showed abundant inflammatory deposits upon its surface, together with numerous evidences of old iritis all around the pupillary margin. Indeed, it was difficult to make out the fundus with any distinctness on account of the general dirty appearance of the lens. He complained of great pain in forehead and in the region behind the nose. He was persuaded to have the eye enucleated, and I prepared to have everything ready to make cultures from the vitreous and anterior chamber.

The eye was removed, and after sterilizing with a hot knife a point at the corneo-scleral junction not far from the wound, I entered the anterior chamber with a spade-knife, which had been sterilized by passing it several times through an alcohol flame. I withdrew the knife and followed it with a platinum wire loop, which was stirred up in the anterior and posterior chambers of the eye, and *smear* cultures on agar were made, also three Esmarch tubes.

These tubes were subjected to the proper temperature in an oven for as long as ten days, and not a sign of growth showed itself. Prof. Welch, Dr. Flexner, and myself each examined cover-slips made from the vitreous and anterior chamber, but discovered no organisms.

I then obtained a rabbit, and made a small opening into the anterior chamber with an iridectomy knife. I may add that all the instruments were thoroughly sterilized. An iris-forceps was introduced into the anterior chamber of the enucleated eye, and a regular iridectomy was performed. I found the iris very hard to pull away from its adhesions to the lens capsule, but managed to draw out and cut off a good-sized piece of the iris. This latter was then forced into the anterior chamber of the rabbit's eye, and moved about several times in the chamber, and partly drawn out and left.

In one week's time, with the exception of a slight blush about

the wound, the rabbit's eye showed no evidence of disease, and in two weeks this injection had faded entirely away, and only a slight prolapse of the iris at this point gave any evidence of the operation. The cornea remained clear throughout, and the prolapsed iris was simply the result of the manipulation, and in no way interfered with the functions of the eye,—just what we sometimes see in cataract-operation without iridectomy. During the operation I took pains to bruise the tissues about the incision, thus imitating, as far as possible, the conditions peculiar to a penetrating wound of the eye.

One cannot read the literature of this subject for a single year without being struck by the want of certainty that exists as to its exact nature, and I mean that this has been the case every year even since Deutschmann's experiments. The solution proposed by Deutschmann and the history of his experiments are praiseworthy, and few scientific articles may be read with more interest by all medical men than his contribution to the pathogenesis of sympathetic ophthalmia. Let me review briefly his experiments.

The earlier experiments of Deutschmann were made with the spores of the aspergillus fumigatus, and consisted in making repeated injections of a suspension of this organism into the corpus vitreum of a rabbit. Choroido-iritis followed the first injection, and at the end of four weeks, or a few days after the fourth injection, he discovers choroido-iritis and opacities in the vitreous of the fellow-eye. The animal is killed, and the microscopic examination confirms the diagnosis. Evidences of inflammation are seen throughout the inoculated eye. Interstitial inflammation of the optic nerve extending up to the chiasm, with an involvement of the latter, is seen, the process passing on down to the other eye by way of its optic nerve. The iris and ciliary region of the sympathetically affected eye were not examined. The posterior half of the eyeball shows abundant signs of inflammation in round-cell infiltration. He concluded therefore that a sympathetic inflammation may be produced in one eye by the introduction of infectious matter into the other eye, and that the track of this inflammation is along the optic nerve and its sheaths. Inasmuch, however, as he

regarded the inflammation resulting from the inoculation with the aspergillus fumigatus as the result of chemical irritation, and knowing that such irritation is rarely, if ever, concerned in the production of sympathetic ophthalmia, he resorted to the pus organism for the inoculating material. He injects two or three drops of a suspension of staphylococcus aureus into the vitreous of one eye. The animal dies of meningitis on the third day. To avoid this complication, he uses a very dilute suspension of the same organism and experiments on five rabbits. Only one of the animals gives a negative result, negative in so far that after remaining alive for several weeks no change was observed in the fellow eye.

Meningitis does not occur in any of these cases, but all the rabbits die of general infection at periods ranging from five or six days to three weeks. As regards the microscopic examination, round-cell infiltration with micrococci were to be found in both optic nerves and chiasm and in the posterior half of second eye; a typical case of sympathetic ophthalmia, he concludes, in all but one feature, namely, in the non-participation of the iris and ciliary region of the second eye. And the reason the iritis is absent is because the animal dies before the organisms have time to reach the anterior portion of the eye.

In reading the account of these experiments one is forcibly struck with their simplicity; and in these five experiments the result of each one never fails to confirm the result of the foregoing, so that after coming to the end of Deutschmann's work one feels that there is strong reason to believe that the theory is proven. I doubt whether any scientific problem in pathology has ever been proven so smoothly.

The nature of sympathetic ophthalmia has always been an interesting topic of discussion among ophthalmologists, and when Deutschmann's work appeared in 1882 it can be imagined with what satisfaction the account of his experiments was read and how generally they were accepted.

As is always the case in experimental pathology, any special solution of a problem is subjected to verifying tests at the hands of different observers. Such has been the fate of this class of work for years, and it is no uncommon thing to

find what seemed a valuable discovery fall into disrepute simply because it could not stand the test in the hands of others. And such a course is right, as any one can readily see. The explanation of any phenomenon in medicine only becomes valuable when that explanation can be verified by others than the originator. The things in the science of medicine which remain are those things which have been proven by many, both in the laboratory and in the hospital, and the things which have been discarded and are forgotten are those things which have been found worthless except possibly in the hands of one man.

Such striking and uniform results as those which attended the experiments of Deutschmann would seem to promise an easy confirmation, and it was almost with this conviction that I entered upon the experiments published in these ARCHIVES three years ago (vol. xvii., 187–213). The first parallel experiments of Deutschmann's work were made by Dr. H. Gifford,[1] of Omaha, who at the time he was engaged in this work was serving as one of Horner's assistants in Zürich. I shall not go into an account of his experiments in detail, but will simply state that after repeating Deutschmann's experiments on seventeen rabbits, he failed on any point to confirm the work of the latter. Eighteen months later I commenced my own work on this subject, and after spending many months in a series of thirty experiments I obtained nothing but negative evidence from Deutschmann's point of view.

For the first few months I used dogs as subjects, as I supposed they would be less likely to succumb to the effects of a general infection, and in consequence would enable me to follow out more accurately the theory, and my results proved that I was right, as none of the animals, with the exception of one case, showed any evidence of constitutional disturbance. Until this time the character of my work had differed in only one point from that of Deutschmann, namely, in the fact that mine were made on dogs. Thinking that this difference might impair the value of my work as a control of that of Deutschmann, I concluded to repeat his

[1] *Ibid.*, vol. xv., 281–295.

experiments on rabbits. This line of experiments consisted of fifteen in number, and they resulted just as did the first series; in other words, at no time during the life of the animal could any sympathetic disturbance be detected in the second eye, and though an ophthalmoscopic examination was made every day the fundus of the second eye never indicated the slightest departure from the normal, and I may add that the microscopic examination only served to strengthen this state of the case.

My work then, so far as verifying the results of Deutschmann's experiments, resulted negatively. As I remarked in my previous work on this subject, the microscope always showed infiltration of the intraocular end of the infected eye. A moment's glance was sufficient to tell me that. The excess of the nuclei present over what is seen in the normal condition was too apparent to be mistaken, but any noticeable progress of this increased nucleation for more than a short distance from the eye was never observed.

Mazza[1] experimented also upon rabbits and guinea-pigs, but reports only failures from Deutschmann's point of view. Nor did this observer notice any change in the second eye with the ophthalmoscope. In those animals that had died of meningitis cocci were to be found in the optic nerve and its sheaths.

And finally I would call attention to the work of Limbourg and Levy[2] of Strassburg. These experimenters inoculated twenty-five rabbits and seventeen guinea-pigs after the method of Deutschmann. As the changes in the inoculated eye resembled precisely those observed in my own experiments, I shall only allude to the condition of the second eye. To use their words "as regards any changes in the second eye which could be looked upon as sympathetic, none were observed with the exception of a very doubtful hyperæmia of the fundus. The examination for organisms was in every case negative." Their work simply confirms my own. It is surprising that the authors after finishing such a valuable piece of work did not feel themselves justified in

[1] *Bericht uber den VII. Internat. Ophthal. Congr.*, zu Heidelberg, 1888.
[2] *Archiv. f. experiment. Path. u. Pharmak.*, Bd. xxxviii., S. 153–166.

drawing any further conclusion than as follows: "It follows from these experiments how difficult a thing is the experimental investigation of this question."

It would seem that Limbourg and Levy were so influenced by Deutschmann's views as to distrust their own work, and yet their experiments were far more exhaustive than those of the latter. Even if they did not feel warranted in expressing in so many words their doubts as to the value of Deutschmann's work, they certainly had a right to conclude that it is impossible by the method employed to produce a sympathetic ophthalmia in a rabbit.

As regards the discovery of organisms in an eye which has been enucleated for fear of sympathetic disease in the other eye, experience differs widely, and even this point is too often decided in the negative to admit it as an additional support of the germ theory of the disease. Deutschmann rarely failed to find organisms in an eye enucleated to avoid sympathetic trouble, and though I have examined at least a score of such eyes I have succeeded in detecting organisms in but one case, and that was when the injury dated only two weeks back, a fact which has led me to conclude that the very questionable agency of micro-organisms in the production of sympathetic ophthalmia is rendered more unlikely when the sympathetic disturbance makes its appearance from two to six months after the injury.

Ohlmann[1] records recently having examined thirty eyes enucleated to avoid sympathetic disturbance, and in not a single one did he find organisms.

It should be remembered that sympathetic ophthalmia is a very rare disease. I can safely say that, in by far the majority of cases where I have performed enucleation, it has been on an eye which had been sightless for many months, certainly for many weeks and frequently for years, and this I feel sure has been the experience of most ophthalmic surgeons. In other words, enucleation is practised almost invariably as a precaution against the disease, and when we consider how all-pervading organisms are, is it not strange that, if they are really factors in this disease, they do

[1] *Archiv. f. Augen.*, Bd. xxii., 1.

not begin their work sooner, or is it not stranger still that in the majority of cases they accomplish nothing? When we consider the fact that organisms have almost certainly been introduced into all eyes which have been destroyed by penetrating wounds, and furthermore that a large number of such patients have carried these sightless eyes for a long time,—when we consider this, there remains a striking lack of anything like cause and effect between the opportunity offered the organisms to do their work and the actual occurrence of the disease. These remarks though are simply by the way, for I do not desire to pronounce myself positively against the infectious origin of the disease.

As to the experiments on rabbits, guinea-pigs, and dogs, the weight of evidence goes to show that not only is there no analogy between the disease, as seen in man and these animals, but that sympathetic ophthalmia cannot be produced in these animals through the agency of the staphylococcus, and that consequently such a character of experiments can throw no positive light on the subject.

It is unaccountable how Deutschmann discovered in every case such uniform conditions of neuritis extending along both optic nerves including the chiasm. Professor Deutschmann, no doubt, rejects the possibility of having mistaken the normal for the pathological condition, but I would again, as in my former work, emphasize the fact, that there is no question about the difficulty of differentiating unless one has at hand sections of a nerve which are known to be *normal*, and with which we can compare the supposed pathological section.

The rabbits, it will be remembered, all die at the end of two or three weeks, and in consequence the chief distinguishing feature of a neuritis at this stage is the increase in nuclear elements, and upon this point we must mainly rely in making our diagnosis. Changes in the *nervous* bundles are not readily demonstrable features of a neuritis of three weeks' duration. And though one will invariably detect an increased number of nuclei at the intraocular end of the infected eye, one will be astonished to find on comparing such a section with a normal eye what an enormous number of nuclei are present in the latter (physiological condition).

But, apart from this, in the light of all the control work that has been put upon this subject, and with nothing but negative results, it seems unreasonable to look upon the infection theory as demonstrated by the experiments of Deutschmann as anything yet awhile but an idea.

And finally, to return to my experiment in the laboratory. It seems to me that this is a most valuable test of the question as to what rôle bacteria play in the production of the disease. We have here an undoubted case of sympathetic ophthalmia, and if bacteria in the injured eye gave rise to the sympathetic trouble, it is reasonable to suppose that the means employed to discover them would have been successful, and that the experiment on the rabbit would at least have suggested something which might be regarded as positive evidence.

The reasonableness of the infectious origin of sympathetic ophthalmia no doubt accounts for the general acceptance of the theory, but we ought to recollect that this theory owes almost its entire support to a few experiments with the pus organism. And if there is an organism which we might almost predict would not produce the disease it is the pus organism. Purulent inflammation of the eyeball, in a word "panophthalmitis," where the pus organisms are most abundant, as a rule do not give rise to sympathetic ophthalmia.

As I have said before, I do not wish to be regarded as absolutely arrayed against the infection theory, but against the theory only so far as the pus organism is concerned. There are many organisms about which we know nothing, with which it might be possible to produce the disease in animals; and, again, sympathetic ophthalmia may have its own specific organism.

It is possible too that the disease is not of bacteric origin, but that an organism of some other class may be present. And again, we have strong reason for believing that the lower animals do not have sympathetic ophthalmia, just as they do not have many other diseases peculiar to the human race.

The experiment here recorded I regard as strong proof against the views set forth in the work of Deutschmann.

ON THE PATHOLOGY OF CIRCUMBULBAR DERMOID CYSTS.

By Dr. J. MITVALSKY,

LECTURER ON OPHTHALMOLOGY AND ASSISTANT TO THE ROYAL BOHEMIAN EYE-CLINIC IN PRAGUE.

Translated by Dr. Ward A. Holden.

(*With Plates IV., V., VI., and VII., of Vol. XXIII., Germ. Ed.*)

TWO years ago I examined clinically and microscopically a dermoid cyst of the orbit, of the size of a hen's egg, the wall of which presented such a peculiar structure that it was incomprehensible to me, nor did the literature of the subject assist me in explaining it. There remained nothing then but a systematic study of the cysts so often found in the neighborhood of the orbital margin to clear up the subject, which seemed to me of the greatest importance, as it interests not only the oculist, but the surgeon, the gynæcologist, and even the physician, since the cysts in the cavities of the body and in the organs may grow to tumors of great size. The cysts on the surface of the body occur by preference in particular localities, depending upon their mode of development, principally about the head and neck, and in greatest number in the neighborhood of the eye ball.

The cysts in the neighborhood of the eye fall into two categories: first, those situated in the orbit, displacing the ball when attaining any considerable size—the so-called orbital dermoid cysts; and second by, dermoid cysts of the margin of the orbit. The latter category may be divided again into those for the most part within the orbital margin—dermoid cysts of

the lids; and those for the most part outside the orbital margin, mostly situated upward and outward,—cysts of the region of the brow. The latter, however, in rare cases, lie below the orbit, so the designation, cysts of the brow, is not suitable for all extra-orbital cysts.

The dermoid cysts of the lids may exceptionally extend backward forming a secondary tumor in the orbit, such cases having been described by Spencer Watson and others.

Berlin found the position of predilection to be to the nasal side of the ball, 53 per cent. of 51 cases examined having this situation. In the cases which I observed the cyst was on the temporal side; the location of 24 per cent. of these growths according to Berlin.

The cysts of the orbital margin, of which I observed 17 cases, were 14 times—82 per cent.—within the bony margin, 12 of them at the outer and 2 at the inner commissure; in 2 cases the tumor was outside the orbital margin and below the brow; and in one case the tumor lay below the external commissure at the margin of the zygoma.

REPORT OF CASES.

CASE 1.—A. S., a boy æt. six months, had a dermoid cyst the size of a pea in the right upper eyelid, above the outer commissure. The cyst being removed, the contents were white, friable, and almost dry, showing hairs visible macroscopically. Microscopically numerous flattened layers of horny epidemic scales were found, among which were round fat globules and many lanugo hairs. The greatest thickness of the cyst-wall was 0.25 *mm.*, the least 0.1 *mm.* Microscopically it showed the ordinary structure of the external skin with some modifications, consisting in an altered thickness of some of the layers at particular points, and in the variable size of the cells. Everywhere there is a thick corium lined internally with an epidermic layer. The corium shows its usual constitution of fibrillar connective tissue, with a varying number of flattened connective-tissue cells with spindle-shaped nuclei. The nuclei are fusiform in the superficial layers, shorter and thicker in the deeper layers. The cells are most numerous about the vessel walls, and here their nuclei are not so flattened. The corium cannot everywhere be separated into distinct layers corresponding to the pars papillaris and pars reticularis of the

external skin, and this is particularly the case in those portions of the cyst-wall in which the adnexa of the skin are wanting. In those portions where there are hair follicles, acini of sebaceous glands, and coils of sweat glands, the corium is readily divided into a closely woven inner layer, and a coarser outer layer containing follicles and glands. The inner surface of the corium is smooth in almost its entire extent, showing only a few elevations covered with epidermis. There are no papillæ. An outer fatty layer is wanting, except in some parts, where it is seen to be a continuation of the subcutaneous adipose tissue. The epidermis differs from that of the outer skin first in its variable thickness. In some parts it is only 15-20 μ deep, and consists of a few layers of flattened germinal-layer cells, covered with an indistinct corneous layer; in other parts the epidermis has a thickness of 50 μ and more, consisting of a germinal layer of vertically or obliquely placed basal cylindrical cells, a middle layer of polyhedral cells, and a superficial layer of flattened cells. The hair follicles are scattered over the entire surface of the cyst, some having no hairs. The hairs, hair follicles, and glands are flattened, running parallel to the cyst-wall.

CASE 2.—A cyst the size of a pea above the left inner commissure in a child æt. three. Histology as usual.

CASE 3.—A cyst the size of a bean above the left outer commissure.

CASE 4.—A cyst the size of a bean above the right outer commissure in a boy æt. six. (Illustrated in Fig. 1.)

CASE 5.—A cyst larger than a chestnut above the left outer orbital margin and within the linea semicircularis.

The cyst was flattened. The frontal bone showed a fairly deep depression where the cyst was adherent, and it was removed entire only after having been emptied of its contents. The contents were of a dirty-white color, soft and atheromatous, containing numerous cast-off epidermic scales and fat needles. The cyst-wall showed a considerable number of vessels, the smaller ones surrounded with small-celled infiltrations, the larger arteries showing thickened walls as the result of an arteritic process.

CASE 6.—A cyst the size of a hazel-nut below the outer end of the right eyebrow.

The entire cyst-wall showed the usual structure except in a place 1-2 *mm* long, where the epidermis was completely wanting, and the inner layer of the cyst-wall was formed of granulation tissue rich in epithelioid and giant cells. The other layers were composed of fibrillar connective tissue. Our interest centres in the tracts lying in the inner two thirds of the wall (Fig 3), composed of cells stained yellow, with one or more nuclei. The most of these form a sort of sheath about capillary or precapillary vessels.

At one particular spot about 2 *mm* in diameter in the deepest portion of the corium we find tissue composed of round and typical giant-cells with innumerable nuclei. This is pervaded by vessels of small calibre, about which the giant-cells seem to be arranged (Fig. 4). This structure corresponds exactly to that of a giant-celled sarcoma, and, occurring in the outer layers of a dermoid-cyst wall, is remarkable.

CASE 7.—A boy, æt. thirteen, having a cyst the size of a hazel-nut situated beneath the left outer commissure on a level with the zygoma.

The contents were friable and without fatty matter or hairs. Part of the wall was lined with epidermis (corium), part with hypertrophic granulation tissue (Figs. 5 and 6). Along the longitudinal diameter of the cyst was a system of folds and furrows which, in transverse sections, appear as glandular formations (Figs. 5 and 6). It is remarkable that the granulation tissue does not contain the usual blood-vessels.

CASE 8.—F. D., æt. seventy-three, with a cyst the size of a small apple above the outer third of the right orbital margin.

The cyst was removed entire. There was a considerable depression in the bony margin of the orbit. Its contents were soft, like butter, of whitish color, leaving a grease-spot on paper, coagulating in low temperature, not affected by alcohol, giving up its fat with ether, and the latter evaporating, precipitating to a fine friable, half transparent, fatty mass. Melted over a flame a quantity of clear fat was obtained, thickly fluid at the temperature of the room, solidifying at 2° C. This was found to consist for the greater part of oleate and stearate of glyceril. Microscopic examination showed many fat globules and flat dermic cells.

The examination of the cyst-wall showed for the most part dermoidal structure covered in some places with a hyaline membrane (Fig. 8). A smaller portion showed granulation tissue (Fig. 7); one small spot (0.4 *mm*) presented the appearance of fibro-cartilage.

CASE 9.—L. W., æt. twenty-four, having a cyst the size of a pigeon's egg above the right outer commissure, which at the clinical examination was seen to be transparent, indicating oily contents.

The cyst was adherent to the frontal bone. Within the cyst was a colorless glycerin-like fluid with white flocculent masses, which coagulated when exposed to the air. A chemical analysis showed the oily mass to be composed of oleate and palmitate of glyceril.

The structure of the cyst-wall is shown in Figs. 9, 10, and 11.

CASE 10.—A girl, æt. sixteen, having a cyst the size of a hazel-nut above the left outer commissure.

The cyst was removed entire and hardened in alcohol. The contents were white, fatty, and contained many hairs. In this cyst we find two types of the extension of the granulation tissue; the first consists in the development of connective tissue at the expense of both the corium and the epidermis (Fig. 12); the second, in its development at the expense of the epidermis alone. (Fig. 13).

CASE 11.—A boy, æt. eighteen, having a cyst the size of a pigeon's egg above the left outer commissure. Structure as usual.

CASE 12.—A girl, æt. twenty, having a cyst the size of a hazel-nut above the left outer commissure.

The cyst was transparent. The contents consisted of a pure yellow oil mixed at the bottom of the cyst with a creamy mass containing short black hairs. The oil coagulated when exposed to the air. The structure of the cyst wall is shown in Fig. 14.

CASE 13.—A woman, æt. thirty-seven, had a cyst the size of a pigeon's egg lying beneath the inner and upper quadrant of the left orbital margin, pressing the inner half of the

left upper lid forward and filling the space between the inner upper wall of the orbit and the eyeball, without dislocating the ball.

The cyst could not be removed entire, and the contents escaped as a fluid colorless oil, coagulating at 33° C. Chemically it consisted of oleates and palmitates of glyceril.

At the bottom of the cyst was a white creamy mass containing many hairs. This was another of the so-called oil cysts. In the middle layers of the connective tissue making up the cyst-wall are many large masses of hypertrophic unstriped muscle, and also some bundles of medullated nerve fibres. The larger vessels show a great thickening of the tunica media, and in the neighborhood of the smaller vessels there are circumscribed small-celled infiltrations, giving the whole the appearance of a granuloma. These collections of round cells are often of considerable size, thus giving some resemblance to a small-celled sarcoma. In the inner layers of the cyst-wall are a few lanugo hairs.

CASE 14.—A case of cyst of the orbit, the size of a hen's egg, offering so many clinical and anatomical peculiarities that it will be described in detail.

September 17, 1868, a woman, æt. thirty-three, came to Professor Schöbl's clinic with the following history. From childhood her left eye had been slightly prominent, a fact which her parents attributed to a blow. She had always seen well with the eye until two months before, when she noticed a dull pain to the outer side of the eye, which gradually increased, the sight becoming affected at the same time and the ball becoming more prominent. The right eye is normal. The left eye protrudes, and is also displaced downward and inward. The palpebral fissure is narrowed, the inner commissure displaced inward, downward, and anteriorly. The lids cannot be closed. The motility of the ball is interfered with, particularly upward and inward. T — $1\frac{1}{2}$. The entire conjunctiva is in a condition of chronic catarrhal inflammation. The fundus shows the picture of papillo-retinitis with hemorrhages. $v = \frac{1}{60}$. The lachrymal gland is dislocated forward by the tumor, which is of cartilaginous consistency, with a smooth surface.

An absolute differential diagnosis between a dermoid and an echinococcus cyst was not possible.

I made an incision 4.5 *cm* long through the entire thickness of the lid below, and after the removal of the lachrymal gland the surface of the tumor presented itself to view. The cyst lay outside the muscular pyramid, filling the entire orbit and being attached to the optic nerve. Owing to the great difficulty in removing the tumor it was punctured, and a turbid fluid like soapsuds with some flocculent masses escaped. The cyst was now readily detached, except at the apex of the orbit, where it was necessary to remove also a portion of the optic nerve 1 *cm* long. The ball was replaced, a drainage tube inserted, and the wound united with sutures. The wound healed readily, and the patient was discharged on the ninth day, at which time the ball was somewhat prominent, the upper lid drooping. T − 2. The conjunctiva was slightly reddened, the cornea showed a superficial opacity at the seat of the previous ulceration, the anterior chamber was shallow, the pupil moderately dilated. The media were clear, the details of the fundus indistinct.

Eight months later the eyeball was normal in appearance, but had sunk somewhat into the orbit, motility much restricted; v = 0.

The contents of the cyst, the fluid and the masses did not leave traces of grease on paper. No hairs were found. The masses showed cholesterine crystals and flattened horny cells.

The cyst-wall was on an average 3:4 *mm* thick, but irregular and furrowed; at one spot there was a plate of bone. No hairs were found.

One half was hardened in alcohol, the other in Müller's fluid.

Microscopic Examination.—Only in the posterior inferior quadrant of the cyst does the wall show traces of an epidermic lining. This consisted of a typical germinal layer with basal cylindrical cells, over which were polyhedral, and finally flat cells which did not stain and approximated a horny layer (Fig. 15, *a*). At both sides this epidermis becomes thinner, and the horny portion continues a short distance as a thin smooth layer which is detached from the underlying tissue and wrinkled.

In the cyst-wall two layers of connective tissue may be separated, an internal dense, close-meshed layer, and an external with wide meshes and depositions of fat.

This connective tissue contains a varying number of connective-tissue cells and a quantity of infiltration cells.

The internal layer of the cyst-wall is a dense, almost tendinous

layer showing no cells. Outside this layer the tissue is infiltrated with round cells often arranged like follicles (Figs. 15, 16). In some portions the cyst is lined with a system of glistening membranes 20-40 μ thick (Fig. 16, *a*), next to this a dense fibrous tissue, and outside this a looser tissue with infiltrations (Fig. 16, *b*) joining here and there the follicular structures. There is no doubt but that the round cells here form the connective tissue. At one spot the inner surface of the wall contained in its coarse meshes polynuclear cells. Similar cells projected into the interior of the cyst, but were more or less degenerated.

The circumscribed infiltrations (Figs. 15 and 16) surrounding each a blood-vessel, have in their substance no marked connective-tissue framework, and resemble a follicle or lymph gland.

The plate of bone mentioned above shows a structure half-way between spongy and compact, containing some marrow spaces with vessels and supporting tissue. Near the bone are a number of ossifying foci, some showing the structure of hyaline cartilage.

There are some peculiarities of structure in the neighborhood of the plate of bone. At one side there is a soft cellular tissue with no connective tissue or blood-vessel. At the periphery this tissue becomes myxomatous, and one ganglion cell was found in it. In the cellular tissue is a distended and œdematous sweat gland. The arteries show changes which consist usually in a thickening of the media, sometimes of the adventitia, and rarely of the intima, causing occlusion of the vessel (Fig. 18, *a*). The adventitia of the veins contains many round cells. A number of bundles of medullated nerve fibres were found.

REMARKS.

The physiological structure of the dermoid cysts varies within wide limits. In all the varieties the wall is composed of a connective-tissue corium and an overlying layer of epidermis, the variation consisting in the presence or absence of papillæ, muscle, and the various adnexa of the skin.

That variety showing hairs and glands is the most common, making up 85 per cent. of my cases. In one case only did I find sweat glands alone, and only in one were all the adnexa absent. Most of the cysts have an epidermis similar to that

of the external skin; some have a rudimentary epidermis; the hair follicles in the latter case, however, produce normal hairs. Occasionally both varieties of epidermis may be present in the same cyst.

In some portions of the wall in our first cyst the epidermis is reduced to a single or double layer of cells, having here and there horny excrescences of degenerated cells.

The corium also presents variations. Rarely are papillæ found regularly distributed over the cyst surface. These are mostly present at particular points only, where hair follicles are found. On the contrary, there are many cysts having hair follicles, but no papillæ. The papillæ, when present, are rarely regularly formed, but are, as a rule, flattened. Often there is no trace of papillæ, and the surface of the corium is then smooth, or there are projections of varying size and form which may be considered as microscopic fibromata. The folds of the inner layer of the corium are also interesting.

The hair follicles vary only in so far as they are formed either of normal epidermis, or of that with but one or two layers of cells. In some follicles one wall in the sections is seen to be lined with one variety of epithelium, and the second wall with the other. The hairs are sometimes cilia-like and sometimes lanugo-like in the same cyst. The sebaceous and sweat glands vary with the cyst.

As to the development of the cyst, we find that the nearer it is to fœtal life, the smaller it is, and the more regular its structure and the distribution of the adnexa. The first enlargement of the cyst occurs with the distension of its lumen by the secretion from the sebaceous and sweat glands, and the increase in the number of cast-off epidermic scales. This enlargement may then proceed in two ways: either the distension of the cyst-wall is uniform and the adnexa are separated uniformly and distributed regularly over all portions of the cyst-wall, or particular portions of the wall yield to the pressure and cause the further enlargement of the cyst, while other points retain their original structure and their original relation to the adnexa present. In the latter manner cysts develop which at particular points

show hairs and glands in their primary relation to the wall, while other portions have no trace of them.

The distended parts become thinner and the original perpendicular direction of the hair follicles, the hairs, and the excretory ducts of the glands take on an oblique direction and finally become parallel to the wall. All the structures of the cyst-wall become altered in the distension.

Through these changes a series of characteristic pathological processes are brought about. With the changed position of the hair follicles and the glands emptying into them, it becomes impossible for the secretion to reach the cyst cavity, and this leads to inflammatory interstitial processes in the acini of the sebaceous glands. The principal change in the sweat glands consists in a simple passive dilatation of the gland, with which may be associated the active development of the polypoid excrescences in the gland.

In a minority of the cases more or less extensive portions of the cyst-wall have no epidermoidal lining, and in place of this show a new-formed tissue composed of round, formative, and giant cells. This condition can only be explained by supposing that in the superficial layers of the corium there has been a plastic pathological process, which after the destruction of the epidermis leads to ulceration of the corium, in which granulation tissue appears and later cicatrizes. This granulation tissue differs from the ordinary chronic granulation tissue in its great number of giant-cells and in the presence of hairs. In the beginning it has no blood-vessels but is nourished by the vessels of the corium. Most of the vessels that develop are of the precapillary variety, and their walls are formed of a single layer of cells which elongate into short fibres.

The granulation tissue shows an exquisite progressive character and develops principally below the epidermis, gradually destroying the hair follicles and glands of the part. The hairs after the destruction of their follicles lie in the granulation tissue as unirritating foreign bodies. The hyperplastic granulation tissue may cover the deeper layers of the cyst-wall, in which the glands and hair follicles are long preserved but ultimately they are destroyed.

Hildebrandt[1] (" On the Secondary Implantation of Hairs in Dermoid Cysts." Ziegler and Nauwerk; *Beiträge zur path. Anat. u. allg. Path.*, vol. vii., p. 2) and Goldmann[2] (" A Case of Oil-Cyst, Containing Giant-Cells," *ibid.*, p. 3) thought the development of giant-cells in dermoid cysts to be dependent entirely upon the presence of hairs. We do not find, however, that the giant-cells are only in connection with the hairs, but they are scattered throughout the granulation tissue and are often found in those portions where hairs are completely wanting. In the cicatricial tissue, furthermore, hairs are found imbedded with no trace of giant-cells about them. We must therefore regard this excessive development of giant-cells as a peculiarity of the ulcerations in dermoid cysts, for there is no other granulation tissue excepting the tubercular which shows so many giant-cells. The development of these giant-cells may be dependent upon a particular irritation, probably that of the cyst contents on the open ulcer. The development of the sarcomatoid and giant cells in the corium near the granulation tissue, which cells are found mostly about the small blood-vessels, is also due to the irritation produced by the cyst contents.

We suppose that the beginning of the granulation tissue is a small-celled infiltration arising partly through diapedesis, partly through division and proliferation of fixed connective-tissue cells. This infiltration becomes organized and finally cicatrizes. In the dermoid cyst the cicatrization of the ulcer takes place through organization of the granulation tissue, the epidermis showing no tendency to proliferate and cover the cicatrix. Thus we find the cicatrized ulcers in a dermoid cyst without epithelium, and in those cases in which the ulcerative process has involved the entire inner surface of the cyst no trace of epidermis is found.

The ulcerative process stands in no definite relation to the age of the individual. We can only say that the younger the individual the more probable it is that there has not yet been ulceration. The oldest individual in whom the ulcerative process was wanting in the cyst, was over fifty years of age.

Where the position which the cyst had occupied could be

determined it was found that chiefly the anterior more exposed portions were involved in the ulcerative process, while the portions adherent to the bone, being more protected, preserved their epidermis longest.

Of secondary pathological changes were found the formation of hyaline cartilage, calcareous degeneration, and ossification; a degeneration into a peculiar cellular tissue containing ganglion cells; hyperplastic arterial changes with a remarkable endarteritis polyposa; and finally collections of lymphoid cells, resembling follicles, in the neighborhood of the altered vessels.

As to the cyst contents. The clinicians have made a distinct variety of the oil cyst, not recognizing their true nature. They overlooked the atheromatous portion of the contents, which lies mixed with a greater or less quantity of hairs at the bottom of the cyst. There are no dermoid cysts without atheromatous material, and some epithelium is always present.

We distinguish two sorts of oil which occur in the contents of these cysts. One is of a saturated yellow color, differing little in appearance from any other yellow organic oil, and composed of various oleates; the other is colorless, like glycerine mixed with water, and consists chemically of oleate and palmitate of glyceril. Both oils coagulate at the temperature of the room. In the manipulation of removing an oil cyst the white atheromatous masses with the hairs are detached from the bottom of the cyst and are suspended in the oily contents. Seven of our cysts had atheromatous contents, where the cast-off epithelium exceeded the fatty masses. In one the fat was found in a fluid state in vacuoles; in three the contents were fluid with small atheromatous masses; in two the contents were semi-fluid from the product of the sweat glands; in one case the entire contents consisted of atheromatous masses, fat and hairs being completely wanting.

The designations "dermoid cysts" and "atheroma" have been frequently confounded. The dermoid cyst is congenital, the atheroma is acquired and occurs mostly in adult life. The dermoid cyst begins with the dipping in and

cutting off of a portion of the epithelium in the embryo, and is a distinct bit of skin provided with the usual adnexa. The atheroma arises from the plugging and distension of a hair follicle or a sebaceous gland, and includes only a single follicle with its glands. Clinically the dermoid cysts are covered with a movable skin and lie close to the bone, although they may be movable above it; often, however, they are adherent to the periosteum and fixed. The atheromata are retention tumors of the adnexa of the skin, and as such move with the skin, except in cases of excessive growth. The dermoid cysts have positions of predilection; the atheromata develop rather on the forehead, brow, and cheek, places where the follicles have the longest course and become most easily affected. The cysts with oily contents are transparent, the atheromata are always opaque. In anatomical structure the dermoid cysts resemble the skin in every particular, and like this are subject to various pathological processes. The atheromata show a very simple structure, consisting of a thin connective-tissue layer lined with laminated layers of flattened epithelial cells which become dry and horny, and being cast off help to make up the contents of the cyst. The relation of the various constituents of the contents of the dermoid cysts has been spoken of above; the contents of the atheromata consist for the most part of concentrically arranged layers of horny epithelial cells, with which is mixed at first some fatty material from the sebaceous glands, but after these are destroyed no fatty material is discovered. Hairs may be found in an atheroma, but they are few and of one size and structure, as they must develop from a single papilla. In differentiating these two varieties of cyst, the presence of many hairs or hairs of different appearance is in favor of it being a dermoid, as does also the presence of much fatty material or particularly fluid oil.

We shall now pass to a *résumé* of the more important literature of the subject. Cruveilhier[1] reported two cases, one being a man of twenty-five, with a cyst above the outer commissure, which Dupuytren operated. An oily fluid escaped which did not mix with the blood, nor did it leave

a grease-spot; at the bottom of the cyst was a white, pulpy mass. The second case was a child of three, with a cyst above the outer commissure. Its contents were like butter, and left traces of grease on paper. Many fine hairs were found in the cyst-wall.

Demours[2] in his *Ophthalmology* is not so clear. Under "tumeurs enkystées ou loupes des paupières," he includes atheromata, melicerides, steatomata, hydatids, and even lithiasis of the lids, confounding various benign tumors with dermoids. In another place he says that one variety of these "loupes" may develop in the orbit causing displacement of the ball. Rosas[3] is much clearer. Under the cystic tumors of the lids, he gives meliceris, atheroma, and steatoma, saying that the first has contents similar to curds, and is almost always situated in the upper lid, particularly to the temporal side, and may reach the size of a dove's egg, or a small hen's egg. The atheroma is a pulpy and sometimes gritty encapsulated mass containing short, white hairs which spring from its entire surface, but have no bulb and are readily pulled out; its situation is the same as that of the preceding variety. The steatoma contains a white tallow, and is situated in the neighborhood of the eyelids, sometimes near the tear sac, and rarely exceeds the size of a hazel-nut. Rosas saw cystic tumors of the orbit, but gave no details from which we could conclude that they were dermoids. Rosas recognized dermoids as a well-marked, distinct group of tumors, and his great clinical experience gave him so clear a clinical and anatomical picture that we must conclude that by the old name which he used he understood dermoids.

Jüngken[4] recognized cystic tumors of the lids, orbit, eyeball, and commissures. He includes under Rosas' designation all the subconjunctival cysts, and the so-called epibulbar open haired cysts. Only the clinical description of the orbital cysts, which he describes in a special chapter under the name "Steatoma Orbitæ," is more complete than that of Rosas.

Lawrence[5] described two cystic tumors containing hair in the neighborhood of the eye, the contents of one being

oily, and of the other fatty. He adds that when the sac is not completely shelled out, the operation wound does not heal. In one such case he was obliged to divide the fistula resulting and remove from the bottom of the wound a bit of the cyst-wall from which hairs were growing, after which the wound healed.

Cunier[6] reported two such cases. One cyst was situated in the upper lid, and one in the lower. Both showed red hairs, and the contents were oily.

Ryba[7] believed that hair follicles deep under the skin, growing in an unusual direction, were the cause of these hairy cysts.

Cramer[8] and Kerst[9] added further reports; the cyst described by the latter was the size of a chestnut, and was situated near the lachrymal gland, projecting into the orbit.

Ruete[10] gives under cystic tumors, meliceris, atheroma, and gumma, and remarks that the organized cyst at times is similar to the cutis or mucous membrane, and shows granulations and glands on its inner surface.

The contents consist of cell formations of various sorts, fatty matter, extractive material and salts, and at times bone and hairs. All these forms are found in the lids, in the orbit, etc. Some of these cystic tumors that contain cells and fat probably develop from the sebaceous glands of the skin; but for the greater number the cause is doubtful.

Hasner[11] in his chapter on "Cystic Tumors of the Eyelids" says that atheroma is frequently found here. Of 16 cases, 10 were in the upper lid, 8 in the outer half, 2 in the inner, and 4 in the lower lid, three of these just above the tear sac. In one case a tumor the size of a walnut was situated at the root of the nose, and in another 3''' external to the outer commissure.

Walther[12] gave a good description of these tumors, particularly those of the orbit, calling them cysts.

Schuh[13] speaks of these tumors under the title atheroma. He understood their anatomical structure, and said that he had found them three times in the outer portion of the upper lid in young women.

Paget[14] described these cysts, and remarks that those which contain oil or fat without any other substance of higher organization, are rare.

While formerly the true nature of these cysts was not appreciated, Lebert[15] added much to our knowledge, and to him we are indebted for the name "dermoid cysts," he finding their walls similar in structure to the skin. He wrote his first papers in 1847 dealing only with the dermoid cysts of the subcutaneous cellular tissue; in 1852 he published an extensive monograph in the memoirs of the Paris Society of Biology on dermoid cysts of the various regions of the body. In 1858 he wrote again on the same subject in the *Prager Vierteljahrschrift*. Lebert was the first who gave us an almost classic description of the anatomical structure of the tumors of the hair follicles. He distinguished these from other cystic tumors, and made a precise differential diagnosis between them and atheroma. He based his views on 4 observations of his own and 17 of others, 10 tumors being situated in the superciliary region above or in the neighborhood of the upper lid, 4 at the root of the nose near the glabella, and 1 in the cheek. The rest were in other portions of the body. Lebert called attention to the fact that these tumors are frequently congenital. He described one dermoid three fourths of the inner wall of which was smooth, having layers of flat epithelial cells here and there, and the remainder of the wall being simply free connective tissue.

The differentiation which Lebert made between dermoids and atheromata was unfortunately soon overlooked. Förster,[16] on the ground of his histological studies, counted atheroma with the dermoids. His description was good, except for this one blunder, which still appears in the text-books.

Gaillard[17] reported 20 cases of dermoids in the neighborhood of the orbit.

Heschl[18] blindly followed Förster in including atheroma in the dermoid cysts. As the epidermic layer makes up the principal mass of the tumor in the atheromata and the cutis is less important, Heschl calls them atheroma-epider-

moids. In his opinion they make up the first variety of the dermoids, and are produced by the same cause.

In the second variety Heschl includes only simple dermoid cysts, of which he reported 4; 2 of which were situated in the neighborhood of the orbit. Heschl rightly believed that all dermoids originate in intra-uterine life, and only become larger in extra-uterine life. He followed Remak's explanation of their origin, who believed that pathological formations of epidermis which appear beneath the surface of the skin are due to a separation of cells from the epidermis which occurs in early fœtal life (*Deutsche Klinik*, No. 16, 1854).

Lücke[19] gave a good description of dermoid cysts, and remarked that horny material sometimes rests on the papillæ of the cyst-wall.

Spencer Watson[20] described three cases occurring in the neighborhood of the eye, and pointed out that cysts originally lying at the margin of the orbit may gradually extend into the orbit and displace the eyeball. It is therefore advisable to remove the cysts at the outer orbital margin before such consequences occur. He often found the bone beneath them excavated or uneven, and from the continuous pressure a tumor originally outside the orbit may be found within it. The enlargement of the cyst is brought on by an accidental inflammation in the neighborhood. A cyst above the outer commissure forming an abscess, caused a marked exophthalmus.

Lamps[21] reviewed the papers already published on the subject, and reported nine new cases.

A very interesting paper by Mikulicz[22] treated only of the genesis of the dermoid cysts in the head.

Verneuil[23] published a description of three cases of congenital dermoid cysts, all near the inner commissure, and containing an oily fluid. They varied in size from that of an almond to that of a cherry. Verneuil believed that he had made a discovery and called the tumors "Kystes prélacrymaux."

The work of Vassaux and Broca[24] treated only of dermoid cysts with oily contents, and gives an accurate statistical

account of the publications on the subject. Besides this the authors examined histologically the wall of a small, transparent oil-cyst from the brow of a man æt. twenty-six, extirpated by Panas. The wall consisted of two different portions, one small and circular, where the cyst was adherent to the periosteum, showing a typical skin structure, and the remainder of the wall consisting only of connective tissue containing fat. At the points where there were small furrows seen microscopically, the deep connective-tissue cells were unchanged, but nearer the surface they were larger and contained often a number of nuclei, while the fibres were few. The process consisted in the development of connective-tissue cells and fat-cells into giant-cells, which undergo an albuminous degeneration.

For a considerable time the work of Vassaux and Broca was the only one in which the want of an epidermoidal structure in particular portions of the cyst-wall was regarded not as artificial but as pathological, although their explanation was not altogether correct. The works of Hildebrandt and Goldmann next following, called attention to the presence of granulation tissue in the portions of the wall which lacked epidermis, and to the finding of numerous giant-cells.

Berlin, in *Graefe und Saemisch*, speaks only of dermoid cysts of the orbit. He regards the dermoids as different from the atheromata. "Dermoid cysts are fœtal formations arising from the inversion of the epiblast." "The atheromatous contents of some cysts cannot be differentiated microscopically from the contents of true atheromata. Therefore the designation 'atheroma' should be given up and 'steatoma' and cholesteatoma adopted." In De Wecker-Landolt, dermoid cysts of the orbital margin are described among diseases of the lids under the name "Atheroma (Kystes sébacés)." In the beginning of the chapter atheroma is used in the true sense of the word, meaning retention cysts of the hair follicles. It is stated that their point of predilection is the upper outer margin of the orbit, but that they also are found above the inner commissure. In speaking of their location, atheroma in its proper sense is confused with dermoid cyst, and the two are considered

identical both here and in the portion treating of dermoid cysts of the orbit. De Wecker still uses the old terms atheroma, steatoma, cholesteatoma, and meliceris, which were invented when the contents of the tumor were alone taken into consideration and not the structure of its walls.

Berlin in *Graefe und Saemisch* reviewed the literature of 73 cases of dermoid cysts of the orbit reported before 1879, since which time the reports have been few. One case described by Cornwell [25] had an interesting clinical course. A patient æt. thirty-three was operated on for a cystic tumor of the orbit, the contents of which and so much of the wall as could be grasped with the forceps were removed. This caused a panophthalmitis, for which the eyeball was enucleated, after which he discovered a second cyst deep in the orbit. This was incised and the contents, as before, squeezed out and a bit of the cyst-wall removed. A week later Cornwell was surprised to find a third cyst at the upper inner angle of the orbit, which he operated in his own manner as in the case of the other two. It is not clear whether there was a single cyst or three communicating ones, and no attention was given to the character of the cyst-wall. A simple dermoid cyst operated in such a primitive fashion would readily return.

In the case reported by Lopez [26] a dermoid cyst beneath the upper outer roof of the orbit, which he calls a "Kyst sébacé," had by its presence caused a neuro-retinitis, and for this was removed.

Pfalz [27] observed a cyst the size of a pigeon's egg in the inner upper portion of the orbit in a woman æt. fifty-four. The histological examination showed it to be of dermoid structure. This was probably a cyst of the orbital margin which had extended inward.

Kuntzen [28] described a cyst of the inner upper portion of the orbit which he had extirpated. It had a dermoid structure. The vessels were partly surrounded with masses of granulation tissue which made the internal layers of the wall project inward. The latter showed no epithelial covering.

The last case that I have found was reported by Lichar-

evsky.[29] This cyst was the size of a pigeon's egg and was situated in the upper outer portion of the orbit. It was excised with preservation of the ball.

In conclusion, I would express my thanks to Professor Schöbl for putting thc clinical material at my disposal.

Explanation of the Figures.

FIG. 1 (Case 4).—*a*, rudimentary epidermis ; *b*, corium ; *c*, hair follicle, cut obliquely, showing a large and two fine hairs, and at the side of the latter a degenerated acinus of a sebaceous gland ; *d*, fat-cells.

FIG. 2 (Case 6).—Section through the periphery of the ulcer. New-formed granulation tissue composed of round, epithelioid, and giant cells ; the two ends of the germinal layer and the horny layer still preserved and one hair cut obliquely.

FIG. 3 (also Case 6).—Section through a portion of the cyst-wall near the granulating surface, but still covered with thickened epidermis. The yellow epithelioid cells are seen arranged for the most part in tracts, and in places the relation of these cells to the blood-vessels, that has been spoken of, is recognized.

FIG. 4 (Case 6).—A giant-cell resting on a precapillary vessel.

FIG. 5 (Case 7).—Shows the thickened end of the epidermis growing over the connective tissue.

FIG. 6 (Case 7).—Shows a sac-formed structure filled with granulation tissue.

FIG. 7 (Case 8).—The end of the epidermis and beneath it the acinus of a sebaceous gland. The remainder represents the peripheral portion of the granulation surface, with numerous giant-cells and hairs. *a*, a giant-cell inclosed in a connective-tissue capsule ; *b*, the fungus-shaped giant-cells projecting inward ; *c*, hairs.

FIG. 8 (Case 8).—Section tangent to the granulation surface. The epidermis is partly replaced by a vitreous membrane. In the entire thickness of the wall are groups and layers of yellow cells with one or several nuclei.

FIG. 9 (Case 9).—Showing the papillary projections of the corium, the formation of the atheroma (*a*) from a hair follicle, and the interstitial inflammation of the acini of the sebaceous glands (*b*).

FIG. 10. (Case 9).—A portion of the wall with hyperplastic

changes in the misformed sweat glands (*b*, *c*), and the ectatic normally formed sweat-gland convolute (*d*) with its probable excretory duct (*a*).

FIG. 11. (Case 9).—In the middle of the cyst-wall of the portion without epidermis are, in the connective tissue, the remains of acini of sebaceous glands (*a*) with their excretory ducts and hair follicles (*b*).

FIG. 12. (Case 10).—The transition between the portion with epidermis and that without; in the granulation tissue hairs have grown; *a* is the swollen epidermis end with hyperplastic granulation tissue; *b* is a microscopic atheroma with a neighboring acinus of a sebaceous gland covered with granulation tissue.

FIG. 13. (Case 10).—Another section. Here the hyperplastic granulation tissue takes the place of the epidermis, and covers the still unchanged corium with its adnexa.

FIG. 14. (Case 12).—The periphery of the island of skin, recognizable by the epidermic covering ending there and by the sebaceous gland, passes over into the portion of the wall lacking epidermis, where sarcomatoid cells appear.

FIG. 15. (Case 14).—Here the island of epidermis is shown resting on the wall; and besides this, about the middle of the cyst-wall an artery (*b*) about which is a follicle-shaped accumulation of round cells (*c*).

FIG. 16. (Case 14).—The internal surface of the cyst is covered with a vitreous membrane (*a*), beneath which is a fine-fibred connective tissue formed from the underlying round cells (*b*). *d* is a large artery, the walls of which show inflammatory thickening; about the vessel a follicle-shaped accumulation of round cells (*c*).

FIG. 17. (Case 14).—Here is shown the cystadenoma papilliferum arising from the sweat-gland convolute.

FIG. 18. (Case 14).—A vessel with polypoid endarteritis: *a*, adventitia; *b*, media; *c*, thickened intima; *d*, the polypoid tumor springing from the intima.

BIBLIOGRAPHY.

1. *Essai sur l'anatomie path. en général.* Paris, 1816, vol. i., p. 303.

2. *Précis theorie et pratique sur les maladies des yeux.* Paris, 1821, p. 171, *et seq.*, and p. 528.

3. *Handbuch der theor. u. prakt. Augenheilk.* Vienna, 1830, vol. ii., p. 111., *et seq.*, and p. 433.

4. *Die Lehre von den Augenkrankheiten.* Berlin, 1836, 2d edit., p. 614, *et seq.*

5. *London Med. Gazette*, 1838, vol. xxi., p. 471.
6. *Annales d'Oculistique*, 1839, vol. ii., p. 163.
7. *v. Walther's and v. Ammon's Jour.* N. F., vol. ii.
8. *The Lancet*, 1844.
9. *Archives d'opht.*, vol. xii., p. 41.
10. *Lehrbuch der Ophth.* Brunswick, 1845, p. 701, *et seq.*
11. *Entwurf einer anatom. Begründung der Augenkrankheiten.* Prague, 1847, p. 244, *et seq.*
12. *Lehre von den Augenkrankheiten*, 1849, vol. ii., p. 821 *et seq.*, and p. 827 *et seq.*
13. *Ueber die Erkenntniss der Pseudoplasmen.* Vienna, 1851, pp. 136 and 143.
14. *Lectures on Tumors*, 1853, p. 31.
15. *Mémoires de la Société de Biologie*, 1852, vol. iv. *Prager Vierteljahresschr. für die prakt. Heilkunde*, 1858, vol. lx., total series, p. 25.
16. *Handbuch der allgem. path. Anatomie*, 1855, 2d edit., 1865.
17. *After Schmidt's Jahrbücher*, vol. xcii., p. 109.
18. *Ueber die Dermoidcysten. Vierteljahresschr. f. prakt. Heilk.* Prague, xvii., p. 36.
19. *Handbuch der Chirurgie von v. Pitha-Billroth*, 1869, vol. ii.
20. *Les kystes dermoïdes intraorbitaires.* London Congress, 1873, Report, pp. 151–154. *Lancet*, 1872, vol. ii., p. 118.
21. *Sur les cystes dermoïdes du sourcil. Thèse de Paris*, 1874.
22. *Beitrag zur Genese der Dermoide am Kopfe. Wiener med. Wochenschr.*, 1876, No. 39.
23. *Bull. et Mém. de la Soc. de Chir.*, 1877, vol. iii., p. 1.
24. *Contribution à l'étude des kystes a contenu huileux. Arch. d'oph*, 1883, p. 318.
25. "A Compound Dermoid Cyst of the Orbit." ARCH. OF OPHTH., vol. xi., p. 338.
26. *Kyste sébacé volumineux de l'orbite ayant amené une neurorétinite. Receuil d'Oph.*, 1885, p. 103.
27. *Beitrag zur pathol. Anatomie der Orbitalcysten. Klin. Monastsbl. f. Augenheilk.* 1885, pp. 271–277.
28. *Ueber maligne Tumoren der Orbita. Inaug-Dissert.*, Munich, 1885.
29. *Dermoidnaja Kysta glaznici. Vjestnik Oftalm.*, vol. iv., p. 129.

FIFTY-FOUR CASES OF CATARACT EXTRACTION.

By J. H. WOODWARD, M.D., Burlington, Vermont,

PROFESSOR OF OPHTHALMOLOGY AND OTOLOGY IN THE MEDICAL DEPARTMENT OF THE UNIVERSITY OF VERMONT.

THESE operations were performed between September 8, 1887, and December 10, 1891. Seven were performed in private houses, forty-seven were performed at the Mary Fletcher Hospital. In every instance an attempt was made to secure asepsis. The method practised in most of the cases was as follows: The eyelids and eyebrows were washed with $\frac{1}{5000}$ solution of bichloride of mercury and the conjunctival sac thoroughly irrigated with saturated solution of boric acid several times during the day preceding and on the morning of the day of operation. Just prior to the operation, after the anæsthesia was complete, the same disinfection and irrigation were repeated. The instruments were plunged for a moment into boiling hot water and laid upon a clean napkin in the instrument tray. The corneal incision was made at the junction of the clear cornea and the limbus. Great pains were taken to make a smooth wound. A moderately large iridectomy was then made. Of course I am aware that it is rather old-fashioned, in these days, to prefer the combined operation. Possibly, had my single simple extraction given me less trouble, I should have repeated the operation on other patients. But my patient unfortunately sneezed about two hours after the extraction. Inasmuch as he experienced no pain or discomfort in the eye, I did not examine it until the fifth day, when I found a prolapse of the iris firmly healed in the wound. Subsequently I met with more difficulty in making a satisfactory iridectomy, of which, being necessarily through another

region of the cornea (downward), considerable irregular astigmatism was the unavoidable consequence.

For the capsulotomy, I prefer the Knapp cystotome, and I am confident that the best results follow when the capsule is cut transversely near the upper margin of the lens as well as vertically through the middle of the pupillary region. All cortical detritus in the anterior chamber was removed as thoroughly as possible (or advisable) with the scoop or by irrigation. In one case I irrigated the anterior chamber with a saturated solution of boric acid; in the remaining cases, I used a warm 1 % solution of common salt, sterilized by boiling. The irrigating instrument resembled a very large medicine dropper, the nozzle of which was brought close to the corneal wound, but never introduced into the eye. I think irrigation of the anterior chamber may cause iritis. Such was the effect in two of my cases, 29 and 45. The irrigating fluid in No 29 was saturated solution of boric acid—too strong; in No. 45, I used the 1 % saline solution, and I have since thought that possibly the solution was not sterile. My experience, therefore, cannot be considered unfavorable to the practice of washing the anterior chamber. Certainly irrigation removes cortical detritus more thoroughly than the scoop. In these cases I instilled sterile atropine drops after the operation, as I have done in other cases in which, for one reason or another, I feared an attack of iritis. No doubt this in some cases was an unnecessary precaution.

Both eyes were covered after a final irrigation with saturated solution of boric acid, with a combined dressing of $\frac{1}{5000}$ bichloride gauze and absorbent cotton. The eyes were not examined for 48 hours or longer, if the patients were comfortable. Whenever I have been anxious respecting the possible advent of iritis, or whenever the eye has been uncomfortable, the eye has been dressed more frequently.

My patients were confined to bed, as a rule, one or two days, on a light diet in a moderately darkened room. On the third day, sometimes on the second, I have permitted most of them to sit up in a chair. This is always a great comfort to these patients, and has never proved harmful in

my experience. The unoperated eye was uncovered on the fourth or fifth day, and dressings were removed from the operated eye about the seventh day. After a day or two more with dark glasses, the patient was permitted to leave his room.

Case 1. Mrs. Isaac Morse, æt. seventy-nine, Ext. R. E., September 8, 1887. Anterior chamber filled with blood. Wound healed in one week. Three weeks later paracentesis for removal of unabsorbed blood. Pupil clear after this operation. Patient a chronic invalid from cardiac disease and chronic bronchitis. Able to read newspaper with glasses. No other test made.

Case 2. Mrs. Ruel Thomas, æt. sixty-two, Ext. R. E., May 4, 1888. Healing in about 10 days. $V = \frac{20}{40}$; Jaeger No. 4, rapidly. One year later no deterioration of sight.

Case 3. Mrs. S. O'Neil, æt. sixty-five, Prelim. iridectomy R. E., July 2, 1888. Severe plastic iritis with large hypopyon; later large iridectomy and extraction. V = p.l.

Case 4. Mrs. S. O'Neil (continued). Ext. L. E., February, 1889. Normal healing, 10 days. Does not know letters. Vision satisfactory.

Case 5. Mr. Kinsman, æt. eighty-three, Ext. R. E., October 25, 1888. Healing normal. Able to get about without glasses. No record of V preserved. Capsule too thick. Intended to make a discission later. Have not seen him since.

Case 6. Mr. Ralph Moore, æt. sixty-four. Ext. L. E., December 31, 1888. Cataract hypermature. February, 1889, obliged to open anterior chamber to remove cortical detritus. Iritis. Could see to read for a brief time. Finally pupil occluded. Iridectomy. Fresh iritis and final occlusion of pupil, several (3) months later. V = p.l.

Case 7. Mr Ralph Moore (continued). Ext. R. E., May 4, 1889. Operation smooth, pupil clear. Iritis 5th day. Under control in three weeks. Discharged with eye only slightly irritable. Iritis relapsed. V = p.l.

Case 8. Mr. Isaac Stafford, æt. seventy. Ext. L. E., March 6, 1889. Healing in about 10 days. $V = \frac{20}{50}$; and newspaper. April 29, 1890, unable to read his paper. Secondary cat. discission. Restored, reading V.

Case 9. Mrs. A. C. Baldwin, æt. sixty. Ext. R. E., May 3, 1889. Ptosis, hence iridectomy downward. Heart's action very feeble. Discharged in 3 weeks. $V = \frac{6}{6}$; Jaeger No. 1.

Case 10. Mrs. P. Wynn, æt fifty (?). Ext. R. E., April, 1889. Cortical detritus removed from anterior chamber with scoop. $V = \frac{20}{200}$. Capsule thick. October 1, 1889, discission. Capsule tough. Irido-choroiditis, very severe. Eye recovered with very good vision. No further record of it. July, 1890, while menstruating V in R. E., suddenly failed. Ophthalmoscope revealed detachment of retina.

Case 11. Mrs. P. Wynn (continued). Ext. L. E., April 28, 1890. Discharged May 10. $V = \frac{20}{40}$; Jaeger No. 2.

Case 12. Mr. R. Arnold, æt. sixty. Nuclear cataract in each eye. Iridectomy R. E., by another surgeon in 1888. Nebula over centre of both corneæ. Ext. R. E., August 3, 1889. Discharged September 1. $V = \frac{20}{100}$; Jaeger No. 6.

Case 13. Mr. R. Arnold (continued). Ext. L. E., April 28, 1890. Iridectomy downward. Discharged May 10. V = $\frac{6}{60}$. Since the operation, has resumed his work, harness-making.

Case 14. Mr. H. E. Sheldon, æt. sixty-nine. Ext. L. E., November 7, 1889. Discharged November 12, owing to serious nostalgia. V = $\frac{20}{40}$; Jaeger No. 1, with difficulty.

Case 15. Mr. Frazier, æt. seventy-seven. Mature senile cataract in R. E., immature cataract in L. E. Suppuration of r. lachrymal sac. Treated sac two weeks, when, discharge being very slight, decided to operate, hoping to prevent infection of the wound. November 26, 1889, Ext. R. E.; November 27, eye doing well; November 28, profuse discharge from lachrymal sac. November 29, commencing keratitis at the wound. Panophthalmitis, eye lost. V = 0.

Case 16. Mr. T. S. Snow, æt. thirty-five (?). Traumatic cataract in L. E. Injury about one year ago. Foreign body visible in the cataractous lens. Ext. L. E., December 26, 1889. Fragment of steel found in the cataract. Discharged in about 10 days. V = $\frac{6}{20}$; Jaeger No. 2.

Case 17. Mr. P. Sherwood, æt. sixty-two. Ext. L. E., July 4, 1889. Discharged July 25. V = $\frac{20}{20}$; Jaeger No. 1.

Case 18. Mr. P. Sherwood (continued). Ext. R. E., October 3, 1890. Discharged November 5. May 30, 1891, R. V = $\frac{6}{20}$; L. V = $\frac{2}{50}$. Secondary cataract. Discission. Improved. No further record.

Case 19. Mrs. S. E. Smith, æt. sixty. Ext. L. E., January 23, 1890. Healing in 10 days. Discission March, 1890. V = $\frac{6}{20}$ +; Jaeger No. 2.

Case 20. John Sheahy, æt. sixty (?). Ext. R. E., February 17, 1890. Discharged February 25. Patient removed dressings from eye first night. Does not know letters. V good.

Case 21. Mrs. Kendricks, æt. fifty-two. Ext. R. E., April 23, 1890. Discharged May 5. V = $\frac{6}{20}$: Jaeger No. 2.

Case 22. Mr. Washburn, æt. sixty-eight. Ext. R. E., April 22, 1890. Discharged May 5. V satisfactory. Have not seen him since discharged, but learn that his distant V is good and that he can read some.

Case 23. Mr. C. E. Donovan, æt. thirty (?). Traumatic cataract R. E. Injury one year before. Dark spot near front capsule of cataract. Ext. R. E., May 31, 1890. Foreign body found in cataract. Discharged about tenth day. V = $\frac{6}{10}$. One year later V = $\frac{6}{10}$; complained of diplopia, especially with glasses.

Case 24. Mr. P. V. Manwell, æt. seventy-three. Ext. R. E., June 18, 1890. Discharged June 30. V = $\frac{6}{30}$; reads newspaper.

Case 25. Mrs. McGaffany, æt. sixty-seven. Ext. L. E., May 7, 1890. Discharged May 19. Operation smooth. Very slight iritis during healing. Prior to operation, patient appeared to locate light correctly, but could not be certain that her answers were reliable, owing to her stupidity. Detachment of retina and p.l. found after operation. Nothing in healing or operation to account for these facts.

Case 26. Mr. L. Fairbanks, æt. sixty. Simple ext. R. E., July 25, 1890. Operation smooth. Sneezed two hours after. No pain. Examined eye five days later, longer prolapse of iris. Discharged August 11. Subsequently performed iridectomy downward, also made discission. V = $\frac{6}{20}$. Irregular astigmatism.

Case 27. Mrs. Fletcher, æt. seventy-two. Ext. R. E., August 13, 1890. Discharged September 4. V = $\frac{4}{20}$; Jaeger No. 1.

Case 28. Mrs. Chambers, æt. sixty-five. Cataract in both eyes, complicated by high degree of myopia. Ext. R. E., October 5, 1890. Patient unmanageable, disturbed dressings. Panophthalmitis. October 10, evisceration. V = 0.

Case 29. Mrs. Mary Courteney, æt. sixty-five. Ext. R. E., January 14, 1891. Washed anterior chamber with 5 % solution boric acid. Plastic iritis. Discharged January 26. Readmitted to hospital February 16, 1891, for iritis. Discharged cured in about three weeks. Patient does not know letters. Eye perfectly clear. Vision good.

Case 30. Mr. A. Abbott, æt. sixty-eight. General health very feeble. Ext. L. E., February 13, 1891. Washed anterior chamber with warm sterilized 1 % saline solution. Discharged February 23. V = excellent. Precise record lost. Discission July 23. V improved. General health much improved since extraction.

Case 31. Mr. G. H. Pilling, æt. seventy-four. Ext. R. E., February 28, 1891. Discharged March 17. Organic disease of heart which troubled him some. V = $\frac{6}{20}$ +; Jaeger No. 2.

Case 32. Mrs. J. M. Hoyt, æt. sixty-four. Ext. R. E., April 27, 1891. Discharged May 4. General health very feeble. V = $\frac{6}{20}$; Jaeger No. 1.

Case 33. Mrs. Crimmins, æt. sixty-five. Ext. R. E., April 24, 1891. Ether anæsthesia. Discharged May 9. Old nebula of both corneæ. Does not know letters.

Case 34. Mrs. Crimmins (continued). Ext. L. E., November 16; discharged November 24. Ether. V very good in each eye.

Case 35. Mr. L. B. Soper, æt. fifty-nine. Ext. L. E., April 28, 1891. Prolapse of vitreous. Rupture retinal artery at midnight, May 2, while asleep. Died, May 15, in uræmic coma. See detailed history of this case.

Case 36. Mr. Henry Marston, æt. fifty-four. Ext. L. E., May 1, 1891. Discharged May 11. Media perfectly clear. Does not know letters. V satisfactory.

Case 37. Mr. A. Ketcham, æt. seventy-seven. Ext. R. E., November 15, 1890. Discharged December 2. R. V = $\frac{6}{12}$; Jaeger No. 2.

Case 38. Mr. A. Ketcham (continued). Ext. L. E., May 4, 1891. Discharged May 16. L. V = $\frac{6}{30}$; Jaeger No. 2.

Case 39. Mrs. N. R. White, æt. sixty-eight. Ext. R. E., May 8, 1891. Discharged May 21. Washed anterior chamber with warm sterile 1 % saline solution. Slight iritis. Discission in July; V = $\frac{6}{20}$; Jaeger No. 2.

Case 40. Mrs. Tower, æt. seventy-five. General health feeble. Ext. R. E., July 18, 1891. R. V = $\frac{6}{20}$; L. V = $\frac{6}{20}$.

Case 41. Mrs. Tower (continued). Ext. L. E., July 28. Discharged about August 10. Jaeger No. 3.

Case 42. Mr. John Martin, æt. seventy (?). Ext. L. E., July 18, 1891. Discharged July 28. V = $\frac{6}{9}$; Jaeger No. 2.

Case 43. Mr. John Sarachon, æt. sixty. Ext. R. V = p.l.; L. V = $\frac{6}{30}$. Ext. R. E., July 23, 1891. Washed anterior chamber with warm sterile 1 % saline solution. Discharged August 2. R. V = $\frac{6}{20}$; Jaeger No. 2. Some diplopia with glasses.

Case 44. Mrs. Shepardson, æt. sixty-seven. Ext. L. E., July 28, 1891. Discharged August 11. V = $\frac{6}{20}$; Jaeger No. 2.

Case 45. Mrs. Birchmore, æt. forty-four. Ext. R. E., July 27, 1891. Cataract soft. Washed anterior chamber with warm sterile 1 % saline solution. Very severe plastic iritis. Discharged, August 25, with pupil occluded, to return. Readmitted December, 1891. Iridectomy, leaving large pupil. Capsule of lens covered with pigment. Discharged, to return for discission. Can see large objects.

Case 46. Mr. Beers, æt. seventy-nine. Ext. L. E., August 3, 1891. Iritis. Discharged August 26. Have not seen him since. R. requires an iridectomy.

Case 47. Mrs. A. J. Meeker, æt. seventy-two. General condition not good; very nervous; insomnia; thirst. Urine contains 12½ % sugar; total quantity of urine in 24 hours, 48 oz. Senile cataract. Ext. R. E., August 19, 1891. Discharged September 1. No reaction. November 11, 1891. R. V = $\frac{6}{30}$; Jaeger No. 2.

Case 48. Mr. W. Felch, æt. fifty-nine. Ext. L. E., October 15, 1891. Discharged October 27. V = $\frac{6}{15}$; Jaeger No. 1.

Case 49. Miss Steinhour, æt. sixty-four. Ext. L. E., October 28, 1891. Discharged November 7. V = $\frac{6}{9}$; Jaeger No. 1.

Case 50. Mrs. H. Thomas, æt. sixty-nine. Ext. R. E., October 28, 1891.

Case 51. Mrs. H. Thomas (continued). Ext. L. E., November 12, 1891. Discharged November 19. Eyes perfectly clear. Have not seen her since. Reports that with her glasses she can see as well as she ever could.

Case 52. Mr. Jacob Flint, æt. seventy-five. Ext. L. E., November 3, 1891. Cornea unusually collapsed, but anterior chamber filled in 24 hours. Diarrhœa on second day due to the drinking-water. November 7, patient very homesick and worried about his condition. Tongue parched. Discovered that he had been trying to get on without water and food. Insisted upon his taking iced Apollinaris water and more nourishment. November 10, condition much better. Wound healed. Removed dressings. Slight conjunctivitis. Discharged, owing to serious nostalgia, November 19. Attack of iritis, December. Requires an iridectomy, which will be made later.

Case 53. Mr. J. W. Mills, æt. seventy-two. Ext. R. E., November 18, 1891. Ether. Discharged November 25. Eye clear excepting extravasation of blood into vitreous from some deep vessel. Cannot make out source of the hemorrhage. December 18, hemorrhage came from a vessel at the macula. Cleansing rapidly. Chorio-retinitis at macula. Central V = $\frac{3}{60}$. Improving.

Case 54. Mr. Roscoe, æt. seventy-five. Ext. R. E., December 10, 1891. Cataract soft. Cleaned anterior chamber with scoop, leaving pupil clear. Fearing iritis, redressed. December 11, pupil not clear owing to swelling of some cortical detritus left in anterior chamber. Eyes very prominent. While wiping lower eyelid, I accidentally touched eyeball with cotton; patient winked violently, upper eyelid caught corneal flap and opened wound. Instilled cocaine, intending to clear the anterior chamber of swollen detritus. While raising upper eyelid patient again winked violently and expelled some vitreous. Cut off prolapse. Brought wound into good coaptation. Five days later wound bulging. After six weeks wound healed; pupil semi-dilated; ophthalmoscopic image pretty clear. Can see large objects very well without glasses. Discharged, to return in six weeks for spectacles.

EXTRACTION ON LEFT EYE, PROLAPSE OF VITREOUS, HEMORRHAGE FROM EYE ON THIRD DAY, DEATH FROM BRIGHT'S DISEASE TWO DAYS LATER.

CASE 35.—Mr. Lafayette B. Soper, Morrisville, Vt., aged fifty-nine years, consulted me April 15, 1891. He stated that two years before an extraction had been made in his right eye by Dr. Buller, of Montreal, and ten days after that operation was followed by a discission. His vision had been satisfactory for both far and near until recently, when his reading vision had failed. I found the eye clear, and no evidence of disease in it was visible to ophthalmoscopic examination. His left eye contained a mature cataract and the light-sense was normal. I advised an extraction of this cataract.

Patient stated that he had been under the care of his family physician for what he regarded as a slight ailment, that he had recovered from his illness, but was still rather weak. I inquired whether he had ever suffered from disease of the kidney, to which he gave a negative answer. I did not examine his urine, for, under the circumstances, it seemed to me superfluous to do so.

April 28, Mr. S. appeared at my clinic for operation, accompanied by his family physician. His general appearance was fairly good.

Cocaine anæsthesia; patient apparently calm. After section of cornea noticed that a prolapse of vitreous was threatening; directed my assistant to hold speculum away from the patient's eyeball. Immediately and quickly made the iridectomy and capsulotomy. As the cataract was presenting, patient by sudden and powerful spasm of the orbicularis drove the speculum upon his eyeball, causing prolapse of about one third of the vitreous; cataract expelled at the same time. Cut away vitreous, cleansed the wound, and secured good coaptation of the flaps. Very slight shrinking of eyeball. Dressed antiseptically. Absolutely no hemorrhage. About 7 P.M., some pain in the eye, lasting about half an hour.

April 29 and 30.—Dressed wound, eye in good condition; no inflammation.

May 1.—Union of wound, vision satisfactory, told him he might sit up the next day.

May 2, 12.30 A.M.—Notified by hospital that patient's eye was bleeding. Saw him about 1 A.M., found eye filled with blood and large clot protruding through the wound. Patient stated

that he had been awakened from a sound sleep by severe pain in left temple and eye and in a few moments felt blood running down his cheek. Redressed lightly and applied ice-bag.

May 2, 9 A.M.—Hemorrhage had recovered since last visit. Eye evidently lost as the blood came from a retinal artery. Found that patient's arteries were atheromatous; that he had a mitral insufficiency. Pulse rapid, marked nausea, and very nervous.

May 3.—Urine contained 50% albumen by volume. Slight oozing from the eye. Decided not to enucleate the eye, as it was not inflamed, not very painful, and the loss of blood was not endangering patient's life. For a few days his condition seemed to improve slightly. He then began to show more marked symptoms of uræmia, his strength failed gradually, and he died in uræmic coma two weeks after the artery burst in his eye. No autopsy. During all this period there was not the slightest suppuration in the vicinity of the eye.

This in my opinion was a case of sudden congestion of the brain such as occurs in chronic Bright's disease, which was relieved by rupture of an artery in the operated eye, rather than by a cerebral apoplexy.

SUMMARY.

Suppuration ensued in three of these 54 operations—Cases 3, 15, and 28. In Case 3, after the preliminary iridectomy, which was performed at patient's home among very unfavorable surroundings, a severe iritis with production of considerable pus in the anterior chamber became manifest after a few days. In Case 15, the wound became infected from the lachrymal sac. I performed this operation with full knowledge of all the dangers attending it, and to give my patient his last chance, hoping that I might ward off infection. The operation was very satisfactory; but after 48 hours pus was pouring into the eye from the lachrymal sac and the wound hopelessly infected. In Case 28 the patient was unmanageable, disturbed the dressings, and undoubtedly infected the eye with her fingers.

I am unable to account for the irido-choroiditis in Cases 6 and 7.

In this series appear two cases of traumatic cataract, in both of which a foreign body was in the lens.

There were 17 patients of 70 years or over. The oldest patient was 83.

The following table will show the result in these 17 cases:

NO.	DISTANT VISION.	READING VISION.
Case 1	No record.	Newspaper.
" 5	Able to go about.	Capsule too thick, discission required.
" 8	$\frac{20}{60}$	Newspaper.
" 15	0	0
" 24	$\frac{6}{30}$	Newspaper.
" 27	$\frac{4}{30}$	Jaeger No. 1.
" 31	$\frac{6}{20}$*	" No. 2.
" 37	$\frac{6}{12}$	" No. 2.
" 38	$\frac{6}{30}$	" No. 2.
" 40	$\frac{6}{20}$	" No. 3.
" 41	$\frac{6}{20}$	" No. 3.
" 42	$\frac{6}{9}$	" No. 2.
" 46	Iritis, iridectomy required	
" 47	$\frac{6}{30}$	" No. 2.
" 52	Iritis, iridectomy required	Iritis due to his journey home; he was discharged because home-sickness had become a serious symptom.
" 53	$\frac{3}{60}$	Hemorrhage at macula.
" 54	Able to get about without glasses. Too early to determine ultimate result.	

In all cases, with three exceptions, the anæsthetic was 4% solution of the hydrochlorate of cocaine. Ether was required in three cases, owing to the nervousness of the patients. In one of these cases a hemorrhage into the vitreous from a vessel at the macula was found as soon as an ophthalmoscopic examination was made after the dressings were finally removed. The operation was perfectly smooth and the healing prompt. During the first two or three days subsequent to the operation the patient was not perfectly rational and was found at night wandering about his room. Is it fair to conclude that the hemorrhage was a consequence of the method of anæsthesia?

SYSTEMATIC REPORT OF THE PROGRESS OF OPHTHALMOLOGY DURING THE SECOND QUARTER (CONCLUSION), AND DURING THE THIRD AND FOURTH QUARTERS OF THE YEAR 1891.

By P. SILEX, Berlin; ST. BERNHEIMER, Heidelberg; and C. HORSTMANN, Berlin.

WITH THE CO-OPERATION OF

S. M. Burnett, Washington; Dantone, Rome; and Deus, Berlin; Hirschmann, Charkow; E. Marckwort, Antwerp; P. v. Mittelstädt, Metz; L. Werner, Dublin; C. H. A. Westhoff, Amsterdam; Schiötz and Ole Bull, Christiania.

Translated by Dr. Jas. A. Spalding, Portland, Me.

Sections XII.–XXI. Reviewed by Dr. P. SILEX.

(Concluded from p. 325 of this volume.)

XVIII.—RETINA AND FUNCTIONAL DISTURBANCES.

230. Baquis. Fatti istologici consecutivi ad anemia temporanea della retina. *Ann. di ottalm.*, vol. xx., 3, p. 161.

231. Brown, J. F. Glioma of the retina, with a history of three cases in one family. *Jour. Ophth., Otol., and Laryng.*, April, 1891.

232. Fischer, R. Cure of a case of embolism of the central retinal artery by rubbing the eye. *Deutsche med. Wochenschr.*, No. 23.

233. Hirschberg, J. Spontaneous recovery in a case of detachment of the retina in myopia. *Centralbl. f. Augenhk.*, vol. xv., p. 168.

234. Hoche, A. Binocular hemianopsia inferior and other sensory disturbances in a case of functional psychosis. *Arch. f. Psych. u. Nervenkrankh.*, vol. xxiii., 1, p. 70.

235. Kramer, L. On hysterical stammering. *Prager med. Wochenschr.*, No. 14, 1891.

236. Noyes, H. D. Hemianopsia. *N. Y. Med. Rec.*, April 4, 1891.

237. Simi. Ambliopia nicotino-alkoolica. *Boll. d'ocul.*, vol. xiii., 12.

238. Specht, C. A critical review of the methods for detecting simulation or aggravation of visual disturbances. *Inaug. Diss.*, Bonn, 1891.

239. Spierer. Complete recovery in a case of hemiamblyopia homonyma dextra, due to fright during a severe earthquake about the middle of September, 1883, in Smyrna. *Zeh. klin. Monatsbl. f. Augenhk.*, vol. xxix., p. 218.

240. Thompson, J. T. A case of retinal hemorrhage showing scotoma. Embolism of a branch of the retinal artery. *Ophth. Rev.*, vol. x., p. 161.

241. Wilbrand. On typical defects of the visual field in functional disturbances of the nervous system. *Jahrb. d. Hamburg Staatskrankenanstalten*, vol. i., 1889.

The experiments of Baquis (230) on rabbits are intended to show that karyokinetic changes take place when the supply of blood to the retina is suddenly checked but restored after a time. He made them by compressing the optic nerve and the ciliary blood-vessels near it with a loop and forceps for ¼ to 4 hours. After 4 to 10 days the eye was enucleated and the retina examined under the microscope. He came to the following conclusions: when the temporary anæmia of the retina lasts less than half an hour, it leaves none or only slight traces, which are confined to a slight karyokinetic reaction in the ganglion cells. When the exclusion of the blood lasts more than half an hour, more marked changes take place, which do not disappear, but progress and gradually lead to atrophy of the retina. In these cases a reaction sets in in all the nervous elements of the membrane, which manifests itself in the form of beginning division of the nuclei.

Brown (231) reports two cases of glioma retinæ in the same family, one a boy of three and a half years, which was successfully removed; the other, also a boy of twenty-nine months, who remained healthy eighteen months after the enucleation. An older child died from what was probably the same disease. The other children are healthy. Burnett.

Hirschberg (233) reports three cases of recovery in high degrees of myopia, which had been under observation for eleven,

two and a half, and one and a half years. Iodide of potassium was given; the patients lay on their back and perspired, and a compressive bandage was applied.

KRAMER'S (235) patient after an attack of hysteria had aphasia for a short time, followed by stuttering, which lasted several days. Besides other symptoms such as hemianæsthesia, ovarian pain, etc., there was amblyopia and concentric contraction of the visual field.

After a very thorough study of the literature of the subject NOYES (236) comes to the following conclusions:

1st. A want of uniformity in the just location of the boundary between the seeing and non-seeing fields in hemianopsia. 2. The continuance of a small central area in each eye in certain cases of double homonymous hemianopsia. 3. Sectorial defects—homonymous—are most likely to have their origin in the cortex of the occipital lobe, usually in the neighborhood of the cuneus. In these cases there may be an absence of other significant symptoms, except possibly, agraphia, mental blindness, alexia. 4. Sectorial defects may originate in the subcortical substance of the occipital lobes, but the defective portion of the fields is not so likely to be well defined in boundary as in 3; there may even be irregular spaces where the light is recognized, mingled with blind spaces. Hemiplegia, hemianæsthesia, etc., if present, signify proximity of the lesion to the anterior part of the visual radiation of Gratiolet. 5. Sectorial defects, quadrants, and other figures can arise from lesions of the tractus, but will be accompanied by other symptoms pointing to the temporal lobes or the base, such as paralysis, anæsthesia, etc. Here, as in all tract lesions, the blind region includes loss of light, color, and form-sense. 6. Loss of either color-sense or form-sense, with preservation of light-sense implies lesion of the cortex of the visual centre, either direct or indirect. 7. Hemianopic pupillary inaction signifies that the lesion is at the middle ganglia of the brain, or in front of them, viz., along the tractus, chiasm, or optic nerve. 8. It is certain that a topographical correspondence exists between the central visual centres and the retina, and that it is precise and extends to details. BURNETT.

SIMI (237) saw in a case of amblyopia from the abuse of tobacco and alcohol, besides a slight diminution of vision (V $\frac{18}{20}$), a central scotoma of 20 to 25°, which was absolute for blue, and relative for yellow, red, and green. The power of accommoda-

tion was also disturbed, varying between 1, 1½, and 2 D. A third remarkable symptom, which according to the author has never been observed before, was a kind of xanthopia, which lasted from twilight to sunrise. Total abstinence from tobacco and alcohol soon brought about a cure.

SPECHT (238) has carefully compiled all the different methods for discovering the simulation of uniocular blindness, and emphasizes the fact that in judging this question of simulation the general impression made must be considered, and that the diagnosis of simulation must be based on some positive result of the examination.

SPIERER (239) assumes a slight hemorrhage (therefore not hemiopia, but hemiamblyopia) in the left visual centre : recovery in a few months.

THOMPSON (240) reports a case of hemorrhage into the retina with a corresponding scotoma, followed by detachment of the retina. In a second case there was a scotoma corresponding to a triangular hemorrhagic spot in the retina. The spot disappeared in twenty-four hours, but that part of the retina did not regain its full sensibility.

WILBRAND (241) distinguishes several kinds of anomalies of the visual field in functional disturbances : 1. Limitations due to exhaustion. *a.* To the complete disappearance of the visual field. *b.* To a certain degree of concentric contraction. *c.* An "oscillating" visual field, *i. e.*, with transient zonular and insular scotomas. 2. Equal concentric contraction of the visual field. *a.* Temporary. *b.* Permanent and equal. 3. Uniocular hysterical and binocular temporary amaurosis. 4. Temporary reduction of central visual acuteness with only slight exhaustion of the visual field or none whatever without any demonstrable central scotoma. 5. Concentric contraction of the visual field in organic diseases of the brain, and the influence of distant cerebral foci upon the extent of the visual field. 6. Toxic amblyopias (except when they have existed long enough to have led to interstitial neuritis). 7. The scintillating scotoma.

XIX.—OPTIC NERVE.

242. BERNHEIMER, ST. On changes in the optic nerve in high degrees of sclerosis of the cerebral arteries. *v. Graefe's Arch. f. Ophth.*, vol. xxxvii., p. 37.

243. DE WECKER. Les indications de la resection simple du nerf optique. *Ann. d'ocul.*, vol. cv., p. 101.

244. FOX, L. WEBSTER. Resection of the optic nerve. *Med. and Surg. Rep.*, May 30, 1891.

245. GARNIER. A case of myxosarcoma of the optic nerve. *Zeh. klin. Monatsbl. f. Augenhk.*, vol. xxix., p. 208.

246. HIRSCHBERG, J., and G. CIRINCIONE. On hyaline globules in the papilla. *Centrabl. f. prakt. Augenhk.*, vol. xv., p. 166.

247. LIEBRECHT. Retrobulbar neuritis after the use of arsenic. *Zeh. klin. Monatsbl. f. Augenhk.*, vol. xxix., p. 181.

248. LIEBRECHT. Partial division of the optic nerve. *Ibid.*, p. 179.

249. MANZ. Anatomical description of a coloboma of the optic nerve. Meeting of the neurologists and alienists of south-western Germany. *Arch. f. Psych.*, vol. xxii., p. 517.

250. PAUW, W. En geval van acut vorloopende dubbelzydige opticus-atrophie. *Geneeskunde Tijdschrift voor Nederlandsch-Indie*, Deel xxxi., p. 19, Batavia, 1891.

BERNHEIMER (242) has found aneurismatic enlargement and deposits of bone in the carotid and ophthalmic arteries, and thinks that in those cases in which the latter runs tangentially to the direction of the fibres of the optic nerve it may cause atrophy by compression in old people.

When sympathetic ophthalmia has begun WECKER (243) performs enucleation followed with thorough disinfection of the wound, and if this operation is refused, he makes resection of the optic nerve or injects sublimate according to Abadie. As a prophylactic measure against sympathetic ophthalmia he performs resection of the optic nerve. MARCKWORT.

FOX (244), in this second communication, reports the case of a woman who in infancy was injured by a fork in the left eye. The sight of the right was lost by sympathetic ophthalmia, the sight of the originally injured eye remaining good. Years after, the left became sympathetically inflamed, and finally a section of the nerve in the right was done, causing the disappearance of all sympathetic symptoms. He cuts the nerve as close to the ball as possible. BURNETT.

The examination of GARNIER'S (245) case of myxosarcoma of

the optic nerve showed three kinds of cells: 1, with a round nucleus and one or more nucleoli; 2, spindle-shaped cells with an oblong nucleus; and 3, cells with an oval nucleus and usually stellate offsets. The nerve was atrophic; the tumor must be considered a gliosarcoma.

HIRSCHBERG and CIRINCIONE (246) found a large cavity in the optic nerve near the papilla filled with amorphous organic substance resembling elastin, and deposits of lime.

MANZ (249) gives an anatomical description of a case of coloboma of the optic nerve, the development of which he ascribes to imperfect closure of the fœtal cleft. Opaque nerve fibres he thinks are found more frequently in congenital psychic disturbances.

In a drunkard who had taken quinine for malaria, delirium tremens developed according to PAUW (250), with sudden decrease of vision. Six days later atrophy of the optic nerve was found $V = {}^{1}/_{60}$. WESTHOFF.

XX.—INJURIES, FOREIGN BODIES (PARASITES).

251. GUERENGHI, F. Clinical contribution to the physiology of the optic ganglion. *Arch. d'opht.*, vol. xi., No. 3, p. 242.

252. SANTOS FERNANDEZ. Loss of sight following a gunshot wound in the periorbital region. *Chronica med. chir. de la Habana*, 1891, March.

253. SCHANTZ, F. Injury to eye by shot wound. Recovery with complete vision. *Correspondzbl. des allg. ärztl. Vereins Thüringen*, 1891, No. 6.

254. ASTENGO. Enormous stone in the orbital cavity. *Boll. d'ocul.*, vol. xiii., p. 8.

255. CHIBRET. De l' aspiration appliquée à l'extraction du cysticerque du corps vitrée. *Soc. d'opht. de Paris*, 1891, Jan. 6.

256. CASEY A. WOOD. Electro-magnetic extraction of piece of steel from the vitreous chamber of the eye. *Amer. Jour. of Ophth.*, April, 1891.

257. F. B. EATON. Fracture of base of the skull causing total paralysis of both sixth cranial nerves and partial paralysis of the sensory root of both fifth cranial nerves. Tenotomy. Advancement of Tenon's capsule. *Med. Record*, May 30, 1891.

GUERENGHI (251), nine months after a contusion in the region of the left brow noticed the following appearances about the pupil

of the corresponding eye. On looking straight ahead, both pupils are of equal size and contract readily both from light and in convergence. But when the right eye is covered, the pupil of the left, looking in the distance, dilates to a width of 6 *mm* and remains immovable to light as well as in fixation on an approaching object, so long as the object remains in the direct line of vision. But immediately that the latter leaves this position so that the eye must converge, the pupil contracts and becomes almost a pin hole. The cornea has perception of touch but no pain, and the associated reflex palpebral contraction is somewhat tardy. These pupillary symptoms were observed in the case of a young man of twenty-three who, two days before, had received a severe contusion of the left brow, followed by a considerable exophthalmos, in consequence of intraorbital hemorrhage. After disappearance of the latter, some divergent strabismus and amblyopia still remained. The strabismus disappeared, and the sight, as result of the optic-nerve atrophy, remained $\frac{1}{4}$ with $+ 5.0$ D. A second case of more serious injury (contusion and fracture) of the orbital bones showed altogether the same changes, though less pronounced, which the author regarded as a lesion of the ciliary ganglion. Through this ganglion the nerve fibres pass which supply the muscle of accommodation, as well as those which preside over reflex contraction of the pupil from light entering the same eye, whereas those fibres, which convey reflex impressions from the other eye, as well as those influencing contraction of the pupil in convergence, do not pass this ganglion.

V. MITTELSTÄDT.

FERNANDEZ (252), describing a number of cases, comes to the following conclusions: (1) Bullets do not always produce injuries to the eyeball and to the brain. (2) They may injure only the deep-lying parts of the visual apparatus. (3) Injury to the optic nerve or retina. (4) In the nerve these lesions consist of degenerations or neuritis. (5) Detachment of the retina may be brought about by contusion or choroiditis.

CHIBRET (255) in three cases of cysticercus attempted unsuccessfully extraction by the section according to Alfred Graefe. He thus hit on the idea of sucking out the cysticercus. In the third case, which had been previously operated on by the Graefe method unsuccessfully, he reopened the wound on the third day, and, by means of an "Anel" syringe with large canula, succeeded in aspirating the cysticercus and removing it.

ASTENGO (254) removed a stone, 28 *mm* long, 18 *mm* wide, and 9 *mm* thick, from the orbit of a fourteen-year-old boy. The foreign body was shot out of a little cannon and pierced the cornea and penetrated the entire globe without in any way injuring the lids. In spite of the severity of the injury, the enucleation consequent on removal of the stone was followed by no complications and the boy was discharged in thirteen days, comparatively well.

In WOOD'S (256) case a piece of steel had entered the eye through the cornea at its upper inner edge. The foreign body was not seen, but an incision was made in the sclera down and out, and the needle of a steel magnet introduced, and a piece of steel brought away. It weighed 17.7 milligrams. There was no loss of vitreous during the operation. In spite of lens opacity V = fingers at 1 *m*. BURNETT.

In EATON'S (257) case the paralysis of the fifth was only partial, the lips and eyelids and a part of the cheeks remaining sensitive. The converging strabismus of both eyes was treated by an advancement of Tenon's capsule. The condition was very much improved, though the patient passed from observation before the result was fully known. BURNETT.

XXI.—AFFECTIONS OF THE EYE IN GENERAL DISEASES.

258. FRIEDENWALD, H. Report of ophthalmological examination of Dr. Preston's cases of arterial sclerosis. *Jour. Am. Med. Assoc.*, 1891, May 2.

259. BATTEN, R. O. Some points on the relationship of the eye to the cardio-vascular system. *The Lancet*, 1891, pp. 970 and 1035.

260. SIMI. Ophthalmia and the spring. *Boll. d'ocul.*, vol. xiii., p. 7.

261. SPIERER. Kerato-malacia of the left and neuro-retinitis of the right eye in course of a meningitis. *Zehender's Monatsbl.*, vol. xxix., p. 222.

262. MÜLLER. Two cases of aneurism of the aorta. *Correspondenzbl. für Schweizer Aerzte*, 1891, p. 291.

263. DEBIERRE. A case of acromegaly with tabic symptoms and bilateral hemianopsia. *Rec. gén. d'opht.*, 1891, p. 12.

264. KAST. With regard to the symptomatology of Basedow's disease. *Jahrb. der Hamburger Staats-Kranken Anstalten*, 1889.

265. LIEBRECHT. Paresis of convergence in Basedow's disease. *Zehender's klin. Monatsbl.*, vol. xxix., p. 183.

266. SPENDER. On points of affinity between rheumatoid arthritis, locomotor ataxy, and exopthalmic goitre. *Brit. Med. Jour.*, 1891, p. 1169.

267. GULDENARM, C. WINKLER. Contribution to Surgery. *Weekblad van het Nederlandsch, Tijdschrift voor Geneeskunde*, 1891, vol. ii., p. 217.

268. BERNHARD. Regarding the nuclear paralyses of the eye muscles and their components. *Berliner klin. Wochenschr.*, 1891, No. 43.

269. BORDECKER. A case of chronic progressive paralysis of the eye muscles in a paralytic from tabes. *Berliner klin. Wochenschr.*, 1891, p. 573.

270. KÖHLER. A case of fracture of the base with unilateral paralysis of the abducens. *Berliner klin. Wochenschr.*, No. 18, p. 1891.

FRIEDENWALD (258) examined the fundus of 40 eyes in patients who were under treatment by Dr. Preston for general arterial sclerosis. Out of these he found in 12 cases local or general contraction of the arteries with abundant tortuosities; in 10 cases moderate contraction of the same nature. In 4 cases the vessels had whitish borders; 1 case showed hemorrhage at the disk and 7 seemed normal. BURNETT.

BATTEN (259) has observed that optic neuritis is very rare with myopia, and concludes from this observation that hypermetropia and myopia are not essentially local conditions but may be parts of the general condition of the vascular system. He concedes, though, that in some cases the refraction depends on local relations, for example, in persons with myopia in one eye and hypermetropia in the other.

SIMI (250) discusses the coincident outbreak, so often noticed in the springtime, of inflamed eyes, affections of the nasal mucous membrane, and skin of the face, and accepts as the ground for it an irritation of the branches of the trigeminus, which makes itself known through trophic disturbances in the corresponding nerve area. This increased vulnerability of the nervous system the author conjectures to be due to the thermo-clinical influence which the increasing intensity of the sun's rays in the spring has on plants and animals, and therefore in changes in the atmosphere. DANTONE.

MÜLLER'S (262) cases were distinguished by the fact that, in addition to the ordinary symptoms due to paresis of the sympathetic, the accommodation of the affected eye was also paralyzed.

DEBIERRE (263) describes a case of acromegaly from the clinic of Meyer. The nose, lower jaw, hands, and feet, excepting the nails, were markedly developed pathologically. This condition had gradually developed during the past six years. Besides this there was atrophy of the optic nerves. V R = could not perceive movement of hand. V L = $\frac{1}{10}$. Both sides well pronounced temporal hemianopsia. In addition were many tabic symptoms. According to Debierre the hemianopsia may be referred to an enlargement of the sella turcica, which has been demonstrated by sections in acromegaly. MARCKWORT.

KAST (264) found in 20 cases of Basedow's disease, in addition to symptoms already known, a contraction of the visual fields, in some of considerable degree, in others less pronounced.

SPENDER (266). In this paper attention is drawn to the occurrence in rheumatoid arthritis and exophthalmic goitre of the following similar symptoms—pigmentation of the skin, tachycardia, tremors, and spasms, etc., etc., also a few uncommon symptoms.

WERNER.

GULDENARM (267). A soldier twenty-five years old fell from his horse and received a kick on the skull. He had headache and vertigo but was not senseless. A swelling over the right side of the vertex. Gradually there came progressive disturbance of motility in the left arm. Since January, 1891, complete paralysis of left leg and left arm. Contraction of the visual field. Paresis of convergence. Diplopia. Vision each eye $\frac{1}{3}$. A point of tenderness on pressure over the right parietal bone, opposite the anterior central convolution. *Operation:* Release of a blood cyst in connection with the sagittal sinus. Separation of adhesions between the dura and pia mater. Removal of the Pacchionian granulations. Subsequent improvement: almost complete restoration of the visual fields and range of hearing; perfect recovery from paresis of convergence, and diplopia, and of the visual acuity.

In BORDECKER'S (269) case there existed at first a bilateral paresis of the abducens, followed very shortly after by immobility of the pupils. Several years later, symptoms of tabes and paralysis appeared. *Opth.*: blanching of the temporal half of the disk and later of the entire disk. On part of the eye muscles, the

nuclei, and emerging fibres of the trochlearis, especially of the abducens, were found microscopically degenerated; the central nucleus, and the anterior lateral nuclei, and also the peripheral eye nerves distinctly degenerated. The degeneration of the optic nerves resulted from an interstitial neuritic process.

In 97 cases of fracture of the skull which KÖHLER (270) was enabled to follow the history of at the Charité, there was present paralysis of the abducens in only one, and that of one side only, whereas of the facial it was encountered 22 times. This paralysis can appear most frequently in those cases of fracture which involve a rupture of the internal carotid in the cavernous sinus with resultant pulsating exophthalmus.

SYSTEMATIC REPORT ON THE PROGRESS OF OPHTHALMOLOGY DURING THE THIRD AND FOURTH QUARTERS OF THE YEAR 1891.

Sections I.–V. Reviewed by DR. ST. BERNHEIMER.

I.—GENERAL OPHTHALMOLOGICAL LITERATURE.

TEXT-BOOKS, MONOGRAPHS, TREATISES ON GENERAL BIBLIOGRAPHICAL AND HISTORICAL SUBJECTS.

271. Eighth report of the eye clinic at Amsterdam.

272. DAVIS, A. E. Contagious eye diseases with statistical remarks. *New York Med. Record*, July, 1891.

At the Amsterdam hospital (271) 8,305 patients were treated. Of these 643 were admitted to the wards; 302 operations performed, amongst the latter 42 for extraction.

DAVIS (272) has collected all the statistics of the eye institutions in the United States, and found that out of 511,807, 27.50 % (140,755) were affected with contagious diseases. They were subdivided as follows: Conjunctival catarrh, 21.25 %; Granular conjunctivitis, 4.5 %; Pannus, 0.82 %; Purulent conjunctivitis, 0.52 %; Ophthalmia neonatorum, 0.42 %; Croupous conjunctivitis, 0.017 %; and Diphtheritic conjunctivitis, 0.052 %,

II.—GENERAL PATHOLOGY, DIAGNOSIS, AND THERAPEUTICS.

273. STILLING. On the experimental production of exophthalmus. *France méd.*, Jan., 1891.

274. SYM, W. G. Albinism, a curious family history. *Trans. Ophth. Soc. U. K.*, vol. xi., p. 218.

275. JESSOP, W. H. On the consensual pupillary light-reflex in cases exhibiting the Argyll-Robertson pupil symptom in one eye. *Trans. Ophth. Soc. U. K.*, vol. xi., p. 179.

276. JUNG, P. Contribution to the differential diagnosis of the tuberculous and gliomatous diseases of the eye. *v. Graefe's Arch.*, vol. xxxvii., part 4, p. 125.

277. AUBERT, H. On the accuracy of ophthalmometric measurements. *Arch. f. d. ges. Physiolog.*, vol. xlix., p. 626.

278. DARESTE. On the mode of formation of cyclopia. *Ann d'ocul.*, vol. cvi., p. 176.

279. RINDFLEISCH. Contributions to the developmental history of congenital anomalies of the eyes. *v. Graefe's Arch.*, vol. xxxvii., part 3, p. 192.

STILLING (273) experimented on rabbits with regard to the artificial production of exophthalmus. Whilst Boddaert for the same purpose ligated the four jugular veins, and divided the two cervical bundles of the sympathetic, Stilling limited himself to the ligation of the two external jugular veins, and to dividing the cervical bundle of the sympathetic on one side only. Directly after the operation, œdema of the face appears, then swelling of the nasal mucosa, lachrymation on both sides, and a marked degree of exophthalmus on both sides which persists for from two to eight days. MARCKWORT.

The parents of SYM's (274) patient were brunettes, and had no blond relatives. Nevertheless their first, third, fifth, and seventh children were albinos, whilst the rest were brunettes. WERNER.

JESSOP (275) communicates five cases in which the Argyll-Robertson pupil symptoms were present on one side only. The consensual perception of light was only present in the healthy eye. This clinical observation seems to show that the pupillary fibres of the optic nerve, as Darkschewitsch also seems to think, run along the visual pedicles. WERNER.

JUNG (276) describes a case each of chronic tuberculosis of the choroid and glioma of the retina. Both of them show how

readily the pathological anatomical examination makes the correct diagnosis possible. "The thickening of the optic nerve discovered after the enucleation of the case of tuberculosis made us suspect a glioma in contradistinction to the originally correct idea. In the case of glioma, on the contrary, a deposit resembling hypopyon in the anterior chamber suggested that the case was one of tuberculosis of the eye." The mass resembling hypopyon was discovered under the microscope to be a collection of glioma cells.

The author doubts the theory advanced by Gama Pinto of a combination of glioma and tuberculosis, and thinks that Pinto's case (No. 11, *Untersuchungen u. intraoculaere Tumoren*, Bergmann, Wiesbaden) was one of genuine chronic tuberculosis of the choroid, and not at all of glioma.

DARESTE (278) gives a good description (supplemented with sketches) of cyclopia. The first modification exhibited by the development of the cyclopia is the premature closure of the orifice of the first cerebral cyst. If the closure of the abnormal fissure is very premature a rounded excavation is formed, of varying form, and the single eye is formed by the coalescing elements of the two. Dareste also describes the formation of the olfactory groove which never unites with the oral cavity. The premature closure of the first cerebral cyst in cyclopes also retards the development of the cysts of the cerebral hemispheres.

MARCKWORT.

RINDFLEISCH (279) notes a case of bilateral microphthalmus with high degree of retinal ectasia in a young human fœtus, which exhibited further curious peculiarities; the extreme hydrocephalus internus as well as externus of the seven months' fœtus is drawn upon to explain mechanically (pressure on the orbit) the origin of the microphthalmus with cystic ectasia posterior.

The second part of the paper is devoted to a description of the pathological anatomy and origin of congenital absence of the iris. The anomaly in question is proved histologically to be the sequence of violent inflammatory processes.

III.—INSTRUMENTS AND REMEDIES.

280. DARIER. Subconjunctival injections of sublimate in ocular therapeutics. *Arch. d'opht.*, xi., No. 5. *Ibid.*, *Cong. franç. d'opht.*, May, 1891.

281. ABADIE. Therapeutic value of medicamentous and subconjunctival injections. *Cong. franç. d'opht.*, May, 1891.

282. PFLUEGER. Subconjunctival injections of trichloride of iodine. *Cong. franç. d'opht.*, May, 1891.

283. GOLOWIN. On the use of hydrogen peroxide in ophthalmic practice. *Kaukas. med. Ges.*, xxviii., No. 2.

284. LEROY. A micrometic ophthalmoscoptometer. *Rev. gén. d'opht.*, 1891, p. 438.

285. COUETOUX. Bicycle spectacles. *Ann. d'oculist.*, cvi., p. 340.

286. MEGRIER. A new optometer. *Prog. méd.*, 1891, No. 39, p. 235.

287. SNELLEN. Skiascopy. *Ned. Tydschrift v. Genees.* Part i., p. 201.

288. PARENT. Optometric and phakometric ophthalmoscope. *Cong. franç. d'opht.*, May, 1891, and *Arch. d'opht.*, xi., p. 4.

289. RIED. Pocket astigmometer. *Cong. franç. d'opht.*, May, 1891.

290. OSWALT. Clinical ophthalmometry. *Cong. franç. d'opht.*, May, 1891.

291. PARENT. Models of mirrors for ophthalmoscopic examination in the erect image. *Arch. d'opht.*, xi., No. 4, p. 320.

292. PRENTICE. The prismometric scale. *Amer. Jour. of Opht.*, 1891, No. 10.

293. WUERDEMANN. A simple skiascope. *Amer. Jour. of Ophth.*, July–Aug., 1891.

294. BARTHOLOW. A few observations on the mydriatic alkaloids. *Med. News*, Dec. 12, 1891.

295. WOOD. Mixture of homatropin and cocaine as a substratum for atropin and duboisin in the determination of refractive disturbances. *Am. Jour. of Ophth.*, 1891, No. 6.

296. SIMI. Asepsis in ophthalmic surgery. *Boll. d'ocul.*, xiii., p. 21.

297. CRITCHETT. A capsulotome knife. *Trans. Ophth. Soc.* U. K., xi., p. 247.

298. BRITISH MEDICAL ASSOCIATION. Discussion on the vision of railway servants. *Brit. Med. Jour.*, Aug., 1891, p. 406.

299. PERCIVAL. The action and use of prismatic combinations. *Ophth. Review*, x., p. 285.

300. STORY. The ophthalmometer in practice. *Ophth. Rev.*, x., p. 193.

DARIER (280), supported by a large amount of material from Abadie's clinique, recommends the subconjunctival injection of sublimate in all cases in which mercurial treatment is indicated, and in which active procedures are imperatively demanded. The best effect is witnessed in kerato-iritis, and in parenchymatous or punctate keratitis. The treatment is very valuable in central chorio-retinitis, but useless in optic atrophies. The injections were in vain in four cases of irido-choroiditis, in which one eye had already been destroyed. The injections are made with a Pravaz syringe furnished with a canula resembling a cataract needle, which is kept in a 5 % solution of carbolic acid, and $\frac{1}{20}$ *mgr* of a 1-1000 solution is injected at a sitting. The pain is very slight, if cocaine has been previously employed. Later the eye smarts a great deal, and the artificially produced œdema feels very uncomfortable for a considerable length of time. If the injections are well borne, four can be tried in the space of eight or ten days, to one side or the other of the cornea. If then there is no noticeable improvement, the injections may terminate. The author has seen inflammatory chemosis, violent pain, photophobia, and even hypopyon follow the treatment, but thinks that these may have been due to a foul syringe, or to an idiosyncrasy.

ABADIE (281) having, as he thought, perceived good results from intraocular injections of sublimate in case of sympathetic ophthalmitis, experimented with the same in other eye diseases, and with alleged good results. One drop of a 1-1000 solution was employed in old rebellious syphilitic affections, in microbic infiltration of the cornea, in macular chorio-retinitis, and in choroiditis disseminata.

He also employed successfully ergotinin Parent in hemorrhagic glaucoma and hydrophthalmus.

PFLUEGER (282) has also tried sublimate in this manner, but now prefers trichloride of iodine in a physiological salt solution (1-2000). Experimental subconjunctival injections of fluorescin demonstrate that the tinting extended to the cornea, uvea, aqueous, vitreous, and to the superficial layers of the lens.

A long discussion followed the reading of these three papers, on intraocular and subconjunctival injections. Wecker regards transition from the intraocular to the subconjunctival injections as a decided advance, since the vitreous cannot be compared with

a subcutaneous tissue. He reported a case in his practice in which the injection was useless. Venneman asserted that he had cured a case of infection after cataract by subconjunctival injections. Galezowski has seen but moderate results from these injections. Motais regards the intraocular injections as much more rational than the subconjunctival. Chibret believes that the sublimate injections will be badly borne. MARCKWORT.

GOLOWIN (283) recommends peroxide of hydrogen in all cases of corneal and conjunctival ulcerations, as well as in impure wounds. With a minimum of irritation is here combined a maximum of antisepsis. HIRSCHMANN.

A skiascope is now used at the Utrecht Clinique (284) with glasses on each side which by combinations make a series of plus and minus D from 1 to 10. The distance has been decreased from 1 *m* to 60 *cm.* The glasses are held with the left hand in front of the patient's eye, whilst the right hand holds the mirror. 1,25 D has then to be added to the discovered M, and the same amount to be deducted from the H. WESTHOFF.

PARENT (288) has a new ophthalmoscope constructed on the design of Cooper's. It has (1) the combination of glasses from + 20 D to — 26 D, at intervals of 0.5 D ; (2) cylindrical lenses from 0.5 to 6.0 D, with axial arrangement ; and (3) movable mirrors of varying foci for convergent, divergent, and parallel rays. The instrument can be employed not only to determine the refraction, but after removal of the mirrors it can be used as an optometer, phakometer, and axiometer. A description is impossible without a diagram. v. MITTELSTÄDT.

OSTWALT (290) had previously asserted that the astigmatism discovered with Javal's ophthalmometer is ¼ greater than the actual corneal astigmatism. The topic was again brought forward at the French Ophthalmological Congress. Pflueger, Javal, and Leroy attempt to prove in the discussion that the assertion is not true. In Chibret's opinion the total astigmatism is generally somewhat greater than that discovered by the instrument in question. MARCKWORT.

PARENT (291), in order to have at hand either convergent, divergent, or parallel light in the determination of the refraction, has devised a mirror with interchangeable foci (at Giroux's, 58 Quai des Orfevres, Paris). It consists of a movable mirror, in front of which are a concave lens of 25 D and a convex lens of

the same strength. The latter is slightly bluish, and can be removed in the direction of the axis from the former, so that at a distance of 20 to 25 *cm* the source of light can obtain any desired sort of rays.

PRENTICE (292) goes into details in regard to the theory of refraction by lenses, and demonstrates by numerous drawings, that, in order for the refraction of a prism to agree with the laws laid down in the text-books, the bundles of rays must be parallel. If the cone diverges, the extent of the deviation is not the same, and at the same time we get a decided spherico-astigmatic action. He concludes from this, that all tests for prisms must be made with parallel rays, except in the slighter degrees (up to 4 prism dioptries or Grads). He gives a very simple scale for such measurements up to a distance of 6 *M*. He also shows how the prismatic action of a spherical lens can easily be determined with the same apparatus, and asserts that the deviation of a prism is not alike at base and summit. BURNETT.

WUERDEMANN'S (293) skiascope consists of an oblong blade of hard rubber, in which are fitted 12 plus and 12 minus glasses. The board has a handle, and by this the patient holds it before the eye to be examined, and moves it up and down as requested by the examiner. BURNETT.

BARTHOLOW (294), from his experiments as to the peculiar quality of the mydriatics, concludes that homatropin is best for eye operations and refractive work, and atropin for inflammations. BURNETT.

WOOD (295) found that the combination of cocaine and homatropin increases the cycloplegic action of the latter, and is as reliable as atropin itself. He has caused Wyeth of Philadelphia to prepare tablets containing of each drug 1–50 grain (0.0012), and so produces the desired effect in adults in 60 minutes. In young people a second tablet can be advantageously employed in 15 minutes after the insertion of the first. BURNETT.

SIMI (296) emphasizes the success of his operations due to careful production of asepsis before, during, and after the operation. He warns against the use of too strong solutions of sublimate, which cause exfoliation of the corneal epithelium, and thus produce a surface capable of infection. DANTONE.

In the discussion in regard to the sight of railroad employés (298) BEAUMONT, HARDY, MCKAY, and BRAILEY took part, show-

ing that the tests employed in testing the sight of these public servants were very unsatisfactory, especially because so often utilized by the ignorant laity. They all agreed that a committee should present the question to the Government for some legal action. WERNER.

In a paper on combinations of prisms, PERCIVAL (299) mentions the circumstances under which prisms can be practically employed, and presents a table which contains the value of the prismatic deviations, spherical combinations, or decentration of lenses. WERNER.

STORY (300) describes the practical value of the ophthalmometer in the determination of astigmatism. He uses Javal and Schiötz's apparatus. In all the cases in which the ophthalmometric investigation and the subjective determination of the astigmatism differed, examination in the erect image and retinoscopy were employed. In 67 out of 139 eyes the subjective astigmatism was less than that discovered by the ophthalmometer. The variation was generally about 0.5 D. In 9 cases it was still more. The instrument did not reveal any astigmatism in 96 cases, and astigmatism was nevertheless present in only two of all this number.

The author's opinion in regard to the practical value of the instrument is consequently extremely favorable. WERNER.

IV.—ANATOMY.

301. COLLINS. On the development and abnormities of the zonula of Zinn. *Royal London Ophthal. Hosp. Rep.*, vol. xii., p. 86.

302. COLLINS. The glands of the ciliary body in the human eye. Two plates. *Trans. Ophthal. Soc. U. K.*, vol. xi., p. 55.

303. HOSCH. Ehrlich's methylin blue method. *v. Graefe's Archiv.*, vol. xxxvii., part 3, p. 37.

304. PRICE. Persistent hyaloid artery. *Ophthal. Record*, Aug., 1891.

COLLINS (301) was able in an eye that had been enucleated from a child of three months on suspicion of a neoplasm, to study the development and abormities of the zonula of Zinn. He found a mass of cells and fibres extending from the lens, through which a persistent hyaloid artery coursed. The lens was shrivelled, the capsule collapsed, and the fibres of the hyaloid membrane could

easily be studied in all stages of development. In comparing this case with the results obtained in examination of the fœtal eye, he is forced to assume that the suspensory apparatus of the lens in formed in the following manner: Whilst the lens is still surrounded with the vascular membrane, adhesions form between it and the inner layers of the secondary ocular cyst. But as the globe grows faster than the lens, these adhesions are gradually drawn out into fibres with nuclei, which at a later stage entirely disappear.

Other alterations, such as ectopia and coloboma of the lens, can be explained in the same way. WERNER.

COLLINS (302) interestingly describes the results of his examination of the secretory portion of the ciliary body after bleaching it with chlorine water and muriatic acid. The iris pigment consists of two layers, the outer one of which is furnished with flat cells, which are united with the pars ciliaris retinæ. The outer layer remains pigmented, and in this shape extends into the ciliary processes and their folded portions. It exhibits small processes composed of groups of cells, which are partly arranged in parallel rows, and on flat sections exhibit a central orifice. The tubular character is best recognized when enlarged by pathological alterations. Serous iritis is, in the author's opinion, a primary catarrhal inflammation of these glands, as the microscopic examination demonstrates. In cyclitic membranes, these tubular structures have no pigment, as Alt has already shown. Collins also examined two tumors of the cilary body of an epithelial type. One of them he regarded as a melanotic carcinoma. WERNER.

HOSCH (303) reports the results of his examinations of rabbits' eyes with Ehrlich's method. The animals were first chloroformed to death, and then the thoracic aorta injected. The injection is ready in five minutes later. The fixation of the tint, the most delicate affair in the whole process, is best done by a saturated solution of picric acid ammoniac.

The corneal substance remains untinted, but the nerve twigs can thus be better than ever before followed out. Flat preparations exhibit beautifully the dichotomously branching nerve filaments, which course toward the centre of the cornea and form at that point the basal plexus. The anastomoses are interspersed with nodules. The iris of albinotic rabbits exhibits an abundant ramification of nerves, but there was no means of determining the relation in which the fine fibres stand to the smooth muscular

fibres, and their nuclei. The important question whether there are ganglion cells in the iris, the author does not hesitate to answer by asserting that in the nervous meshwork of the sphincter zone, there are cells which are to be regarded as nerve cells. They are spindle-shaped or triangular, but measure only 12 to 15 micromillimetres. He was also able in a single case to demonstrate an actual connection of the one or the other offshoots with medullated nerve fibres.

PRICE reports (304) an interesting case of persistent hyaloid artery in which the vessel could be followed from the art. cent. retinæ to the posterior capsule of the lens, where it spread out regularly into branches, not unlike the retinal vessels on the optic papilla. A remnant of the hyaloid artery was also seen in the other eye. BURNETT.

V.—PHYSIOLOGY.

305. MOTAIS. On the refraction of animals. *Cong. franç. d'opht.*, May, 1891.

MORAT and DOYEN. On the rôle of the cervical sympathetic in the accommodation for vision of distant objects. *France médical*, June, 1891.

307. LANDOLT. New investigations into the physiology of the movements of the eye. *Arch. d'opht.*, vol. xi., No. 5, p. 385.

308. SULZER. The form of the human cornea and its influence on vision. Part 1. The form of the cornea. *Arch. d'opht.*, vol. xi., part 5, p. 419.

309. QUERENGHI. Two cases of total achromatopsia. *Ann. d'Ottal.*, xx., part 4, p. 351. *Ann. d'Oculist.*, cvi., p. 333.

310. SCHMELEW. On the influence of cocaine in the imbibition from the conjunctival sac into the anterior chamber. *Russ. Medic.*, 1891, No. 41.

311. BERRY. Critical remarks on the theories of fundamental color-sensation. *Royal London Ophthal. Hosp. Rep.*, xii., p. 1.

312. STADERINI. On the exits of the aqueous humor. *v. Graefe's Archiv.*, xxxvii., part 3, p. 86.

313. HERING. Examination of a case of total color-blindness. *Archiv. f. d. Ges. Physiol.*, xlix., p. 63.

314. GREEF. Investigations on binocular vision, with the use of Hering's test. *Zeitsch. f. Psychol. und. Phys. d. Sinne.*, iii., p. 1.

315. ELBRIDGE-GREEN. A review of the tests for color-blindness. *Brit. Med. Jour.*, Aug., 1891, p. 470.

MOTAIS (305) observed in animals that imprisonment carried out through several generations transformed the hypermetropic refraction of the eye into myopic. He further relates that a cataractous lioness gave birth to two successive sets of cataractous cubs. MARCKWORT.

MORAT and DOYEN (306) detected a flattening of the lens after irritation of the cervical sympathetic. The curvature of the lens was determined by observation of Purkinjé's images, which increased in size during the irritation of the sympathetic.

MARCKWORT.

Starting out with the observation, that the eye at a certain distance can singly count any number of similarly shaped objects arrayed in regular rows, but at a greater distance can only count the same objects by groups, LANDOLT (397) endeavored, in company with three other experimenters, to determine the smallest angle which the movement of the eye can embrace. They discovered after many tests that this amounted to about five minutes—that is to say, five times as great as the smallest angle of vision.

Another set of experiments demonstrated that when the eyes are to follow an uninterrupted line from beginning to end, *the movement of the eyes is not uniform, but by jerks.* These brief interruptions of movement were either observed directly, or perceived in the observer's own eye by the form of the after images of the line. They follow one another at distances of from 7° to 8°.

On reading a series of printed but disconnected words (yet such as were easily to be comprehended) the eyes made fewer interruptions than the number of the words, but more than when the words made an actual sentence. The same thing occurs in reading a foreign tongue and one's own. The more frequent the interruptions, *i.e.*, the smaller the angle, the easier the eyes tire. Perhaps this is the reason why children bring the book so near to the eyes, and thus fix each one of the words, and finally in this way enlarge the angle of the movement of the eyes, whilst with their good accommodation and convergence they easily enlarge the retinal images. V. MITTELSTÄDT.

SULZER (308) endeavored to measure the form of the cornea by repeated tests with Javal's ophthalmometer, and from the diagrams

attached, we learn: 1, that the central portions of the cornea (leaving aside astigmatism) differ but little from the segment of a concave sphere; 2, that at a distance of 15° (about two *mm* linear) from the intersection of the visual line and the corneal axis, the corneal radius increases with great rapidity, and the surface approaches the ellipsoidal form; 3, that the curvature from the summit of the cornea, or the intersection does not decrease, *uniformly in one and the same meridian.* The author calls this dyssymmetry, in contradistinction to the asymmetry in astigmatism. In the latter the dyssymmetry of the single meridian is slight. He also found that the curvature decreases upward and toward the nose more rapidly than in opposite directions. There is no foundation for the idea that muscular action is the cause.

The author further describes corneæ with irregularly curved surfaces, amongst which there are those with central flattening, and others with discontinuous curvatures. V. MITTELSTÄDT.

QUERENGHI (309) observed two cases of total achromatopsia. In addition to the lack of color-perception both patients exhibited a loss in vision ($S = \frac{1}{10}$), nystagmus, and extreme photophobia. The refraction was normal and there were no alterations in the fundus. In one case the field was concentrically contracted.

DANTONE.

SCHMELEW (310) instilled into the eyes of rabbits (the right eye being previously cocainized) equal quantities of eserin or atropin solutions, with the result that the action of the respective drugs appeared earlier and with greater intensity in the right eye than in the left. Directly afterward the aqueous was carefully withdrawn from the posterior segment of the eye with a syringe, and instilled into the eyes of other animals, the aqueous of the right eye into the right eye of the experimental rabbits, and that of the left into the left eye. Thereupon the action of the eserin or atropin regularly appeared more quickly and more actively in the right eye. Hence the author concludes that the aqueous of the *cocainized* eye invariably contained more eserin or atropin (as the case may be), than in the left eye.

Fluorescin tests gave the same result. The author concludes that the absorption from the conjunctival sac is more rapid in the cocainized eye. HIRSCHMANN.

BERRY (311) affirms, that the theories of color-perception do not explain the physiological color-blindness of the peripheral

portions of the retina, nor acquired color-blindness. He adds, that the defect does not lie in the retina, but in the central organ.

WERNER.

STADERINI (312) has made careful investigations concerning the excretory passages of the aqueous. He operated mostly with India ink, the finest carmine, and a Pravaz syringe. The best results were secured by the use of the India ink. He comes to the conclusion that Schwalbe-Waldeyer's opinion, that there is an open connection between the anterior chamber and the blood-vessels, is decidedly erroneous. Fontana's canal contains anatomical arrangements and physical conditions which assist and abundantly secure under normal conditions the outflow of the aqueous by filtration into the venous blood-vessels at the margin of the cornea.

Nor can we deny that the iris takes part in the resorption of corpuscular elements from the anterior chamber. Finally he was able to prove, that physostigmin greatly hastens resorption from the anterior chamber, whilst atropin retards it.

GREEF (314) experimented with an apparatus modified somewhat from Hering's. He was able to decide that the perception of depth is correct at every distance, just as well when we converge with unarmed eyes upon the point, as when the visual axes are made parallel by prisms. So long as the prisms could be overcome by divergence of the eyes, the result remained the same, *i.e.*, the answers were correct.

2. The falling test, at distances in which convergence and accommodation are no longer to be considered, is still possible so long as the balls are visible, and the difference in depth of the two balls is sufficiently large.

3. When one eye had less vision than the other, binocular vision was still present so long as the defective eye possessed a vision of from $\frac{6}{12}$ to $\frac{6}{18}$.

4. Binocular vision is never seen in squinters, either before or after the operation.

The author objects (315) to examinations: 1. With colored lights, because we cannot obtain varying atmospheric conditions. 2. Holmgren's test is erroneous, because founded on the Young-Helmholtz theory. If partially red and green blind are rejected, many competent persons would be rejected. If only the completely red and green blind are rejected, many incompetent men will pass.

WERNER.

Sections VI.-XI. Review by PROF. C. HORSTMANN.

VI.—ANOMALIES OF REFRACTION AND ACCOMMODATION.

316. FERDINANDS. Investigations into the eyesight of children attending some of the Aberdeenshire Board schools. *Brit. Med. Jour.*, Sept., 1891, p. 585.

317. GOULD. Statistics and results of 1,500 cases of refraction. *Jour. Am. Med. Ass.*, Sept. 19, 1891.

318. RAMOS. Errors of refraction in Mexico, compared with those of Europe. *Verhandl. d. X. Int. med. Cong.*, 1890, iv., p. 79.

319. JAVAL. On the heredity of myopia. *France méd.*, 1891, No. 34, p. 536.

320. VACHER. Treatment of progressive myopia and prophylaxis of detachment of the retina, by extraction of the transparent lens. *Soc. d'opht. de Paris*, Nov. 3, 1891.

321. BRISTOWE. The opthalmoscopic appearances of hypermetropia and their significance. *Ophthal. Rev.*, p. 321 ; and *Brit. Med. Jour.*, Sept., 1891, p. 591.

322. DE SCHWEINITZ. One hundred cases of stigmatism against the rule and the associated symptoms. *Jour. Amer. Med. Ass.*, Sept. 5, 1891.

323. CHISOLM. The value of weak cylinders in the cure of spasm of the ocular muscles. *Jour. Am. Med. Ass.*, Sept. 12, 1891.

324. SAVAGE. The harmonic, symmetrical action of the obliqui, in all cases of oblique astigmatism. *Ophthal. Rec.*, July, 1891.

325. BERRY. On some points with reference to the connection between accommodation and convergence. *Trans. Ophthal. Soc.*, U. K., xi., p. 156.

326. BURNETT, S. M. Further contributions to keratometry. *Jour. Amer. Med. Assoc.*, Sept. 5, 1891.

327. BURNETT, S. M. The prism dioptry *vs.* the centrad. *Jour. Amer. Med. Assoc.*, Aug. 10, 1891.

328. CHISOLM. Homatropia in refractive cases. *Amer. Jour. Ophthal.*, July–Aug., 1891.

329. JACKSON. The full correction of ametropia. *Jour. Amer. Med. Assoc.*, Sept. 2, 1891.

330. MITTENDORF. One thousand cases of ocular headache and the different states of refraction connected therewith. *Med. Rec.*, July 18, 1891.

331. RANDALL. The reformed numeration of prism and the centrad as a unit. *Jour. Amer. Med. Assoc.*, Aug. 29, 1891.

332. STARKEY. An experimental study of the comparative mydriatic effect of atropia and homatropia. *Jour. Amer. Med. Assoc.*, Sept. 16, 1891.

333. VAN FLEET. The normal refraction of the eye. *N. Y. Med. Rec.*, Dec. 5, 1891.

FERDINANDS (316) examined the refraction of 3,000 school children in the erect image and with Snellen's type. No child was under 7 years of age. Four hundred and four myopes and 498 hypermetropes were found. The bad types of myopia prevailed in the lower schools, and in the higher schools the percentage of myopia increased. There were very few myopes in the country schools. The degree of hypermetropia increased with the age. In the children of 7 years, the myopia varied between 1 and 5 D. WERNER.

GOULD (317) has tabulated 1,500 cases of refraction with exception of cases of pure presbyopia ; all of the determinations of refraction were made under atropine. More than a third of all hyperopes, or a fourth of the eyes, exhibited a defect of 0.5D or more. He *undercorrects* all forms of refraction, and is especially polemical against the full correction of myopia. He has never seen a case of heterophoria independent of ametropia of some sort, and he recommends tenotomy only when the degree is more than 12°. BURNETT.

RAMOS (318) found in 2,000 Mexican school children, 88 cases of myopia, 60 of hypermetropia, and 10 of astigmatism. He thinks that the ethnological influence plays a great part in the development, and increase of myopia. Pure Mexicans rarely show any defect of refraction, though it occurs in the mixed races, but very rarely in comparison with its frequency amongst Europeans.

According to Javal (319) myopia is not hereditary, only the disposition thereto. Astigmatism is hereditary and must be corrected early, because, if not corrected, the work has to be brought close to the eye, and myopia is excited.

MARCKWORT.

VACHER (320), having operated seven times by extraction of the transparent lens in high progressive myopia, recommends it generally. It is his opinion, that the operation stops the advances of the myopia, and tends to prevent subsequent detachment of the retina. Wecker and Galezowski, in the discussion, remarked that there was no theory according to which the operation would help to prevent the progress of the myopia, to say nothing of acting as prophylaxis against a future detachment. On the contrary, the eye was much more likely to suffer from a detachment after the lens was removed than when it was *in situ*. In order to show that the extraction did not prevent the progress of the myopia, a patient was introduced by Wecker, in whose eyes discission of a congenital cataract had been performed. He was gradually obliged to reduce the strength of his convex glasses, so that he no longer needed them for distance, and for near used + 2 D, a decided proof that the myopia had advanced despite the removal of the lens. MARCKWORT.

BRISTOWE (321) examined 225 cases of hypermetropia, in 71 of which the fundus was normal. In 29 there was a pseudo-retinitis, or a so-called hypermetropic papilla; 15 times the retina appeared watery and shining. A concentric striation near the papilla was observed in 9 cases, all of which were in children. WERNER.

DE SCHWEINITZ (322) reports 100 cases of astigmatism against the rule, from which we learn that the symptoms are worse or different from those of other forms of ametropia. He believes, however, that the astigmatism should never be completely corrected, even in the lowest degrees. BURNETT.

CHISOLM (323) believes that headache, on using the eyes when the vision is good, indicates astigmatism. In every case of asthenopia with normal vision he prescribes the proper cylinder, with axis against the rule, and finds relief. BURNETT.

SAVAGE (324) renews his assertion of four years since, that in astigmatism the oblique muscles endeavor to unite the oblique meridians with the horizontal and vertical. This takes place by the so-called harmonic, symmetrical action of the obliqui. The work is illustrated with sketches intended to represent the author's idea of how this takes place. BURNETT.

BERRY (325) tested the latent position of the eyes at various distances. The axes in emmetropia, for a distance, are mostly parallel. Divergence is rarer than convergence. In myopia, parallelism is less frequent. Divergence and convergence are observed with the same frequency, but, on the whole, more slight

degrees of divergence. In hypermetropia, parallelism is as often seen as in emmetropia, but latent convergence is more frequent. Correction of the refraction has but little influence upon the latent position for distance. In cases of exertion of the accommodation, the divergence is slightly increased or the convergence diminished by the use of concave lenses, but not in proportion to the exertion of the accommodation. WERNER.

BURNETT (326) advocates the prism dioptry as proposed by Prentice, in the numbering of prisms, and points out its superiority to the centrad system.

BURNETT (327) confirms his formerly expressed opinion of the great practical value of the ophthalmometer of Javal in the determination of astigmatism, and reports some cases of changes in the form of the cornea due to inflammatory disease.

CHISOLM (328) has found homatropia most satisfactory in producing paralysis of accommodation in refractive cases. He uses it six grains to one ounce of water. BURNETT.

JACKSON (329) claims that all forms of ametropia, including myopia, should be corrected in full, except in some very special cases. BURNETT.

MITTENDORF (330) found that in 1,000 cases of asthenopia, 2 % had m.; comp. m. astig., 1 %; simpl. m. astigmatism, 10 %; h. 8 %; h., with presbyopia, 3.5 %; comp. h. astig., 7 %; simple h. astig., nearly two thirds of the whole number; anisometropia, 3 %; mixed astig., 2 % = emmetropia with muscular faults, 1 %. He uses weak cylinders very often, the 0.25 D in many cases giving relief to pronounced asthenopia. BURNETT.

RANDALL (331) points out the need of a revision in our methods of numbering prisms, and advocates the centrad, proposed by Dr. Dennett as a unit. BURNETT.

What STARKEY (332) really studied and reported upon was not the mydriatic effect of homatropine and atropine, but their power of paralyzing the accommodation, and from the 25 cases tabulated it would seem that for this purpose homatropine is quite as reliable as atropine. The homatropine was a one-per-cent. solution, instilled every five minutes for fifty minutes. BURNETT.

VAN FLEET (333) concludes from a study of numerous statistics that there are only two refractive conditions of the eye, viz.: hypermetropia, or the normal; and myopia, the abnormal. Emmetropia, as generally understood, has no existence, except as a beginning of myopia.

VII.—LIDS.

334. WAGNER. Rodent ulcer of the eyelids. *Wjest. Ophthal.*, 1891, No. 3, p. 214.

335. SCHAPRINGER. A second case of vaccine blepharitis, *N. Y. Med. Monthly*, Nov., 1891.

336. VALUDE. Epithelioma of the inner angle of the eyelids. *Arch. d'opht.*, xi., 5, p. 439. BENNETT.

337. LAGRANGE. Melanosarcoma of the lids. *Rec. d'opht.*, No. 6, p. 328, 1891.

338. MOAURO. Granuloma of Moll's glands. *Ann. d'Ottal.*, xx., 4, p. 324.

339. CARL THEODOR, Duke of Bavaria. A case of cornu cutaneum of the right superior eyelid. *Festsch. Helmholtz*, 1891.

340. MINNEY. Transplantation in minor degrees of entropium. *Ophth. Rec.*, 1891, Part i, p. 34.

341. WAGNER. The operation of entropium. *Wjestnik. Ophthal.*, 1892, 3, p. 214.

342. BLICKHAHN. A case of chancre of the right upper lid. *Amer. Jour. Ophthal.*, July–August., 1891.

WAGNER (334) calls as a rodent ulcer of the eyelids, a peculiar form of ulceration appearing at the palpebral portion of the conjunctiva, and rapidly increasing in depth and extent, which he has seen twelve times, and for which he recommends careful cauterization of the floor with a 75-per-cent. solution of acetic acid.

SCHAPRINGER (335) reports a fourth case of vaccine pustules on the lids, the result of infection, which he has lately seen. The case was that of a man of forty-two, with two pustules on the lower lid, accompanied with a superficial ulceration of the cornea.

BURNETT.

VALUDE (336) emphasizes the extreme malignancy of certain cancroids at the inner angle of the eye. Whilst those on the lids or at the outer angle have but little tendency to extend deeply, those at the inner angle not infrequently do so extend into the tear-sac and passage. The treatment must be operative, and demands that the tissues be freely opened. In order to see that there is no relapse, it is better not to cover with an early flap. If we wait, the flap may be made much smaller. It is worth noting that the tumors removed proved to be cylindromata.

V. MITTELSTÄDT.

LAGRANGE (337) describes a melanotic sarcoma of the left eyelid after an old injury. The tumor lay between the cartilage and the skin, was as large as a nut, and six months later showed no traces of a relapse. MARCKWORT.

MOAURO (338) gives the anatomical description of a small lid-tumor, which proved to be a granuloma of Moll's glands, with giant cells. DANTONE.

CARL THEODOR (339) removed from the upper lid of a woman of seventy-eight a cuticular horn which arose from the outer and middle third. The microscopical condition resembled that of an ordinary wart of the skin.

MINNÈY (340) transplants from the forearm in cases of partial entropium, to fill out the space left open by the retraction of the skin after the portion containing the reversed eyelashes is wholly loosened. He holds to the most modern rules in regard to transplantation of skin, and does not use any sutures for fixing the portion transplanted. BURNETT.

WAGNER (341) operated according to Pfalz's suggestion in 32 cases of entropium and trichiasis, in which the intermarginal space was lost, and the hairs grew from the sharpened eyelids as well as in cases of relapse after other methods. He had good results in all of these cases, and at the end of the year no relapses. HIRSCHMANN.

The patient of BLICKHAHN (342) was from Alt's clinique, and had a sore on the penis which was phagedenic. Soon after the appearance of this, a lump was discovered on the right upper lid, and that eye was red. The diagnosis of hordeolum was first made, but when it was at last laid open it was found to be an ulcer which was also phagedenic. It was cauterized with nitric acid, and the case as a whole treated antisyphilitically, and he recovered. BURNETT.

VIII.—LACHRYMAL APPARATUS.

343. FUCHS. Simultaneous affection of the lachrymal and parotid glands. *Beiträge z. Augenheilk.*, 1891, part 3.

344. v. SCHROEDER. A case of acute dacryoadenitis in epidemic parotitis. *Zehender's Monatsbl.*, vol. xxix., p. 404.

345. GUTMANN. Acute double dacryoadenitis. *Verhandl. d' X. Int. Med. Cong.*, 1890, vol. vi., No. 10, p. 159.

346. DE WECKER and MASSELON, Symmetrical tumors of the

lachrymal, palpebral, and parotid glands. *Soc. d'opht. de Paris*, Dec. 1, 1891.

347. TROUSSEAU. Fluxion of the lachrymal gland. *Soc. d'opht. de Paris*, June 2, 1892.

348. TERSON. Report on the treatment of affections of the lachrymal passages. *Cong. franç d'opht.*, May 4, 1891.

349. GUAITA. Operative treatment for the rapid cure of dacryocystitis. *Annal. d'Ottal.*, vol. xx., No. 5, p. 375.

350. DESPAGNET. Curettage of the lachrymal sac. *Rec. d'opht.*, 1891, p. 275.

351. DE WECKER. Scraping of the lachrymal sac. *Arch. d'opht.*, vol. xi., No. 6, p. 492.

352. PETERS. On the so-called lachrymal blennorrhœa of infants. *Zehender's Monatsbl.*, vol. xxix., p. 376.

353. CROSS. Blood-stained tears. *Trans. Ophth. Soc. Unit. Kingd.*, vol. xi., p. 312.

354. WILMER. A new lachrymal drill. *Medical Rec.*, Sept. 26, 1891.

According to FUCHS (343) double disease of the lachrymal glands may make its appearance as a swelling, either acute or chronic. Acute swelling of the tear-glands and of the parotid is seen in mumps. Chronic swelling of the lachrymal and various salivary glands are caused by lymphoma and lymphosarcoma, then follows chronic swelling of the lymphatic glands of the head and neck.

A woman of twenty-seven was affected according to SCHROEDER (344) with double parotitis and dacryoadenitis. The swelling departed in a fortnight after the constant use of warm borated fomentations.

GUTMANN (345) reports two cases of acute dacryoadenitis following a case of gonorrhœa of long standing.

DE WECKER and MASSELON (346) describe a case of tumor of both lachrymal and both parotid glands. The palpebral portion of the lachrymal gland was removed. The preparations were examined by Lateaux, and proved to be an epithelial tumor of the gland. The operation was performed in September, and by December the patient was cured. Kalt believes that the drawings of the tumor resemble lymphoma. MARCKWORT.

TROUSSEAU (347) saw with his own eyes the region near the

lachrymal gland suddenly swell inside of two hours to an enormous size, as the result of mental shock or of intense illumination, or of bit of dust flying into the eye. Suddenly there would be a gush of tears, and the swelling would at once disappear.

MARCKWORT.

GUAITA'S (349) new operation for chronic inflammation of the lachrymal sac consists in splitting open the sac in the old fashion, then in scraping the walls with a sharp spoon, next in probing the nasal portion, and finally in inserting into the latter a decalcified turtle's thigh bone. The idea is, that the bone shall carry off the exudation in the sac and finally be absorbed. The author has performed the operation 31 times successfully. The recovery is very rapid. DANTONE.

DESPAGNET (350) acts as follows in cases of closure of the lachrymal duct and sac: The sac is split open externally, and if very much swollen, a portion of the anterior wall is removed. After evacuation of the sac and syringing with sublimate (1-1000) it is energetically scraped with the sharp spoon. Large and projecting granulations are abscised with the scissors. Finally the walls of the sac are washed with a solution of sublimate in glycerine (1-2000) and a light pressure bandage is applied. The swabbing with the sublimate-glycerine is continued until the external wall closes, or for about ten days. The treatment concludes with a few instillations through the lachrymal canaliculi.

MARCKWORT.

DE WECKER (351) recommends scraping of the sac instead of extirpation or obliteration. After splitting the upper punctum and canaliculus as far as the caruncle, a sharp bistoury is passed into the lachrymal sac, and by turning the blade forward, and simultaneous tension on the external commissure, the anterior wall of the sac is split about 1 *cm* in length. After abundantly sprinkling the sac with sublimate (1-4000), the mucosa is freely scraped with a sharp spoon, and after the hemorrhage has ceased the incision is sutured and a bandage applied. The incision generally unites in three or four days, even if the operation were done at the height of the inflammation. The operation is indicated in cataractous patients in whom we desire to stop the suppuration rapidly and in patients belonging to the working classes or who live far from a specialist. V. MITTLESTÄDT.

According to PETERS (352) there is a class of cases of so-called blennorrhœa of the sac in infants and children which are not due to

any disease of the mucosa, and do not deserve the name of a blennorrhœa. The real trouble is a defective resorption of the tissue at the orifice of the canaliculi and retarded escape of the material in the hollow of the canaliculus. In other words, there is a genuine atresia of the lachrymal punctum or canaliculus. In such cases we have only to press out the sac or thoroughly cleanse the eyes to bring about a rapid cure. There is no need of syringing the tear sac or of the application of astringents to the conjunctiva.

Cross' (353) patient was a woman of twenty-one, rather anæmic, but healthy otherwise and free from hysteria. The vision was normal, and there was only a slight follicular catarrh. The left eye occasionally evacuated bloody tears. When the eyes were closed there would be found a small coagulum under the upper lid. This condition persisted without any amelioration. There was no tendency to epistaxis or philhæmia. Werner.

Wilmer (354) has devised a steel drill with a protecting canula, which he uses for opening up bony occlusions of the nasal duct. He reports one case of its satisfactory use. Burnett.

IX.—MUSCLES AND NERVES.

355. Roberts. Topographical anatomy of the external angle of the eye, from the point of view of strabotomy. *Arch. d'opht.*, vol. xi., No., p. 435.

356. Berry. Note on the individual differences in the degrees of latent lateral deviations of the eye on looking upward and downward. *Trans. Ophth. Soc. Unit. Kingd.*, vol. xi., p. 170.

357. Parinaud. General considerations on strabismus. The innervation of convergence. *Ann. d'Ocul.*, vol. cvi., p. 161.

358. Parinaud. Ætiology of convergent strabismus. *Ann. d'Ocul.*, vol. cvi., p. 321.

359. Juler. The operative treatment of strabismus. *Brit. Med. Jour.*, Sept., 1891, p. 590.

360. Bronner. Fifty cases of strabismus in which the rectus muscle was advanced according to the method of Schweigger. *Trans. Ophth. Soc. Unit. Kingd.*, vol. xi., p. 143.

361. Wray. Suggested technique to prevent strain on the supra- and infra-corneal sutures during the re-attachment of the advanced muscles. *Ophth. Rev.*, vol. x., p. 328.

362. ARGYLL-ROBERTSON. On a modification of the ordinary method of operating for advancement of the tendon of the rectus muscles. *Brit. Med. Jour.*, Aug., 1891, p. 471.

363. WILLIAMS. Modification of the ordinary operation for the advancement of the tendon of the rectus muscles. *Brit. Med. Jour.*, Sept., 1891, p. 574.

364. FERNANDEZ SANTOS. Spontaneous disappearance of an accident of strabotomy; exophthalmos. *Ann. d'Ocul.*, vol. cvi., p. 18.

365. COLLINS and WILDE. The pathology of the ophthalmoplegiæ. *Brit. Med. Jour.*, Aug., 1891, p. 474.

366. THOMPSON. Miner's nystagmus among the South Wales colliers. *Trans. Ophth. Soc. Unit. Kingd.*, vol. xi., July, p. 87.

367. SNELL. On miner's nystagmus. *Brit. Med. Jour.*, July, 1891, p. 61.

368. DRANSART. Miner's nystagmus in the north of France. *Cong. franç. d'opht.*, May 5, 1891.

369. SNELL. Case of nystagmus in a compositor. *Trans. Ophth. Soc. Unit. Kingd.*, vol. xi., p. 103.

370. MORTON. Bilateral paralysis of external recti following diphtheria. *Trans. Ophth. Soc. Unit. King.*, vol. xi., p. 107.

371. WUERDEMANN. Fibro-sarcoma of the neck with temporary opthalmoplegia externa and sympathetic paralysis. *Jour. Amer. Med. Assoc.*, Sept. 26, 1891.

ROBERTS (355) explains the relations of Tenon's capsule and its connections with the globe, the tendon of the external rectus muscle, and the ligamentum palpebrale. v. MITTELSTÄDT.

BERRY (356) tested fifty cases in regard to the degree of lateral divergence in gazing upward and downward, and found in nine the convergence the same in looking both upward or downward; in twenty-eight, the convergence was greater on looking downward, and in the remaining thirteen it was greater when looking upward. WERNER.

According to PARINAUD (357) there is an especial innervation of the eye muscles for convergence. The relations between the convergence and the accommodation are maintained by this innervation. MARCKWORT.

PARINAUD (358) affirms that the theory of congenital muscular insufficiency rests upon an error. That which others call insuffi-

ciency of the interni, Parinaud, in unison with Krenchel and Hansen Grut, call insufficiency of the innervation of convergence. The good results from the use of prisms with the base inward militates against the muscular insufficiency theory.

MARCKWORT.

JULER (359) describes 174 squint operations. He operates on children, no matter at what age, if the strabismus is actually permanent. In all cases of amblyopia, he combines the advancement of the antagonist with the division of the opposite tendon.

WERNER.

BRONNER (360) carries the suture through the superficial layers of the sclera near the cornea. He tenotomizes both interni, in case the deviation measures from 25° to 40°, in case there is no amblyopia, and makes the double tenotomy with advancement if the deviation is more than 40°. He does advancement alone, with a deviation of 30° and amblyopia ; and finally advancement and tenotomy in squint above 30°.

In advancement WRAY (361) uses a third suture between the infra- and supra-corneal suture, which unites the tendon hanging on the globe to the posterior portion of the muscle.

WERNER.

In advancement of the recti, ROBERTSON (362) passes the suture with two needles through the tendon to be advanced, and then pushes the needles through the conjunctiva, the one above and the other below the cornea. WERNER.

WILLIAMS (363) claims priority in the preceding operation.

WERNER.

SANTOS FERNANDEZ (364) reports a case of exophthalmos after an operation for squint. The operation had passed off well in a youth of seventeen, excepting that, owing to the narcosis, there was much emesis with subconjunctival hemorrhage. On the following day, convergence in the operated eye had ceased, and instead a corresponding diplopia existed. Twelve days later the diplopia had disappeared, and the motions of the eyeball were normal. Two months later, exophthalmos ensued, and persisted for eight years, when it again disappeared, and did not return.

MARCKWORT.

COLLINS and WILDE (365) subdivide the ophthalmoplegiæ into cortical, basal, and orbital. The cortical are to be divided further into the genuine cortical, the cortical peduncular, the nuclear, and radicular. The basal are divided into those arising

from the region of the pons, the pedunculi, the sinus cavernosus, and the fissura sphenoidalis. The authors report 141 cases, of which 73 were men. The cause in 30 % was syphilis. WERNER.

THOMPSON (366) is of the opinion that nystagmus in miners is due to the poor illumination. Over-exertion as well as errors of refraction may increase the predisposition to nystagmus. WERNER.

According to SNELL (367) miners' nystagmus is due to the constrained position of the workmen. The light has but little to do with the defect. WERNER.

DRANSART (368) discusses miners' nystagmus. There is a slight and a severe form. The slight is only seen directly after working in the mine. The severe is accompanied with functional disturbances, especially paresis of accommodation. Of 100 patients with this disease in its most severe form, 90 worked in a recumbent position in passages less than 1*m* in height. MARCKWORT.

SNELL (369) watched the appearances of nystagmus in a typesetter of twenty-one, who had for several months worked a long time by night. Snell believes that the nystagmus is the result of the continuous looking from the manuscript to the type and back. WERNER.

MORTON (370) records three cases of paralysis of the externi after diphtheria, occurring five, four, seven weeks respectively after the sore-throat. In one case there was also defective action of internal and superior rectus. Pupils acted to light and convergence in all cases; the accommodation was affected in two. Loss of the patellar reflex in all three. A fourth case is recorded in a child of five. In all the cases the loss of the patellar reflex continued after other symptoms had disappeared. WERNER.

In WUERDEMANN'S (371) case, a boy of fourteen had a large swelling on the right side of the neck, which on microscopic examination was decided to be a fibro-sarcoma. There was, when Wuerdemann first saw him, ptosis and paralysis of the internal rectus on the same side. The pupil was contracted, and did not respond to light. There was some slight tortuosity of the retinal veins. $S = \frac{6}{12}$. Under hot baths and rest, these symptoms disappeared, and the vision was increased to normal. The tumor has not been interfered with. BURNETT.

X.—ORBIT AND NEIGHBORING CAVITIES.

372. AXENFELD. On the development of lymphoma in the orbit. *v. Graefe's Arch.*, iv., xxxvii., part 4., p. 102.

373. COLLINS. On a case of tumor in each orbit; death, Necropsy. *Royal Lond. Ophthl. Hosp.*, rep. xiii., p. 245.

374. SGROSSO. Contribution to the casuistic of osteoma of the orbit. *Naples Pasquali*, 1891.

375. POOLEY. Intraorbital cyst, probably of a dermoid nature. *Ophthal. Rec.*, 1891.

376. WILLIAMS, R. A case of arterio-venous anastomosis communication in the orbit. *Trans. Oph. Soc. Unit. Kingd.* xi., p. 32.

377. LE FORT. Pulsating exophthalmus, *a propos* of a case of ligation of the two carotids for this disease. *Rev. Chirurg.*, x., pp. 369, 457.

378. ISRAEL. Pulsating exophthalmus. *Deutsch. Med. Wochensch.*, 1891, No. 51.

379. PHILLIPEN. Note on a case of pulsating exophthalmus in a new born child. *Ann. d'Ocul.*, cvi., p. 420.

380. CHENEY. A case of retraction of the eyeball. *N. Y. Med. Rec.*, 1891, Nov. 7.

381. LAMY. Exophthalmic goitre. *Mercredi. Med.*, 1891, No. 12. p. 141.

382. SHARKEY. On Graefe's lid-sign. *Trans. Ophthal. Soc. Unit. Kingd.*, xi., p. 304.

383. BULL, C. S. Tumors of the orbit, secondary or consecutive to tumors of the neighboring bony cavities. *N. Y. Med. Jour.*, 1891, Dec. 19.

384. LAWFORD. A case of recovery from Graves' disease. *Trans. Ophth. Soc., Unit. Kingd.*, xi., p. 211.

AXENFELD (372) reports the case of a man of sixty-two from whose eyelids four small lymphomata had been removed. Two months later exophthalmus appeared, originating from a growth in the orbit. There were simultaneous enlargements in other parts of the body, and in the neck. The largest portion of the tumor lay to the left beneath the external half of the orbital roof near the lachrymal gland. It was extirpated with preservation of the globe, and proved to be a lymphoma. After several months the patient returned with the tumor enormously enlarged. Arsenic was administered, and later the tumor decreased in size.

COLLINS' patient (373) was fifteen months old, with tumors in both orbits, histologically resembling the tissue of the lymphatics.

General symptoms ensued shortly before death. The internal lymphatics were enlarged, but not the externals. WERNER.

SGROSSO (374) reports the successful removal of a spongy osseous tumor on the inner orbital wall. The globe and vision were preserved. DANTONE.

POOLEY'S patient (375) was a man of twenty-three, who had noticed on his left upper lid for more than ten years a small tumor. A soft fluctuating tumor was discovered in the orbit just over the superior rectus. An attempt was made to enucleate it through the retro-tarsal fold, but it simply evacuated itself. As it continued to fill and evacuate in turn an attempt was made to enucleate it through the skin. This also miscarried, the tumor collapsed as before, and its walls could no longer be determined. A drainage tube was inserted, and the sac regularly syringed with sublimate. This treatment finally produced a cure. The globe was not affected. From the nature of the contents Pooley is of the opinion that the tumor belonged to the dermoid group. BURNETT.

WILLIAMS' patient (376), a boy of fourteen, exhibited well-pronounced proptosis with pulsating tumor and aneurismic murmur. The refracting media were transparent, the vision was $\frac{1}{15}$, the papilla was normal, the veins enlarged and tortuous. Cure, after ligation of the common carotid. Ptosis and contraction of the lids remained. The veins appeared unaltered. WERNER.

ISRAEL (378) tells of a patient with pulsating exophthalmus which was caused by a retrobulbar cavernoma.

PHILLIPEN (379) saw in a new-born child a unilateral exophthalmus which was observed by the parents a few days after the birth of the child. The eye deviated *1cm* downward. The movements upward were limited. There was a small, slightly fluctuating tumor between the upper orbital wall and the globe. Under expectant treatment the exophthalmus disappeared in a few months. The author believes that a subperiosteal hemorrhage at birth, and situated on the upper orbital wall, was the cause of this peculiar case of exophthalmus. MARCKWORT.

CHENEY (380) reports a case of retraction of the globe, in which there was probably an ophthalmoplegia externa, in which the lateral muscles of the right eye were chiefly affected. When convergence is attempted the eye falls from 3 to 4 *mm* into the orbit. Vision normal after improvement of a slight ametropia. The retraction, according to the author, is due to the action of the

inferior and superior recti, which exert themselves to support that of the internus in convergence. BURNETT.

SHARKEY (382) tested 613 patients and found in 12 the well-pronounced v. Graefe phenomenon. In only one of these he found an undoubted case of Basedow's disease. He is of the opinion that the phenomenon in question can no longer be regarded as a diagnostic point in the detection of the disease. It is actually due to weariness of the orbicularis. WERNER.

BULL (383) considers in succession the tumors of the sphenoid, ethmoid, frontal sinus, and maxillary antrum, which are likely to affect the orbit. The subject is treated in a general manner, and no cases are given. BURNETT.

XI.—CONJUNCTIVA, CORNEA, SCLERA, AND ANTERIOR CHAMBER.

384. CHIBRET. Pathogeny of affections of the conjunctiva in a bacteriological point of view. *Cong. franç. d'Ophthal.*, 1891, May.

385. MUTTERMILCH. Anatomy of the chronic inflammations of the conjunctiva. *Soc. d'Ophthal.*, Paris, 1891.

386. VALUDE. Anatomy of the chronic inflammations of the conjunctiva. *Ann. d'Ocul.*, cvi., p. 241.

387. HOLMES-SPICER. An analysis of 158 cases of acute purulent ophthalmia. *Royal London Ophthal. Hosp.*, rep. xiii., p. 221.

388. VALUDE. Prophylaxis of the ophthalmia of the new-born by the use of pulverized iodoform. *Ann. d'Ocul.*, cvi., p. 96.

389. NIEDEN. On a case of blennorrhœic conjunctivitis in a child born in the membranes. *Zehender's Monatsbl.*, xxix., p. 353.

390. DE SCHWEINITZ. A case of persistent hemorrhage from the conjunctiva of an infant, following the instillation of a solution of nitrate of silver. *N. Y. Med. Rec.*, 1891, April 18.

391. OATMAN. The treatment of diphtheritic conjunctivitis by constant antiseptic irrigations. *Med. Rec.* 1891, Oct. 10.

392. HODGES. Iodide of silver in the treatment of trachoma. *Ophthal. Rec.*, vol. i., No. 3, p. 84.

393. SCOTT. Perchloride of mercury in the curative treatment of trachoma and other conjunctival diseases. *Trans. Ophth. Soc. Unit. Kingd.*, xi., p. 39.

394. DARIER. Presentation of cases in which brossage had been performed. *Soc. d'Ophthal. de Paris*, 1891, July 7.

395. MARPLE. Grattage for trachoma. *N. Y. Med. Record*, 1891, No. 28.

396. MANOLESCU. Brushing of conjunctival granulations combined with parasiticides. Constantinople, 1891.

397. WEEKS. Surgical treatment of granular eyelids. *N. Y. Med. Jour.*, 1892, No. 17, p. 451.

398. KEYSER. Conjunctivitis granulosa. Pumice stone. *Ophthal. Record*, i., p. 8.

399. SMITH, E. A new method for operating on frog-spawn-like oculo-palpebral folds. *Ophthal. Rec.*, i., No. 8.

400. COUÉTOUX. On kerato-conjunctivitis of rhino-pharyngeal origin. *Ann. d'Ocul.*, cvi., p. 401.

401. GASPERINI. Diffuse lymphoma of the conjunctiva. *Ann. d'Ottal.*, xx., 4, p. 356.

402. CRITCHETT and JULER. Epithelioma of the cornea and conjunctiva. *Trans. Ophth. Soc. Unit. Kingd.*, xi., p. 47.

403. SAJESCHKO. Clinical contributions to the question of transplantation of conjunctiva. *Wjestnik. Ophth.*, 1891, Nos. 4 and 5, p. 299, and No. 6, p. 471.

404. BURNETT, S. M. Recent views on the pathology of trachoma. *Ophthal. Rec.*, Sept., 1891.

405. CHEATHAM. Trachoma and its treatment. *Ophthal. Rec.*, Aug., 1891.

406. DE SCHWEINITZ. A note on fluorescin coloring, and the actual cautery in corneal ulcers. *Med. News*, Aug. 15, 1891.

407. FELLOWS. Ocular Massage. *Jour. Ophthal., Otol., and Laryngol.*, July, 1891.

408. FULTON. Pathology and ætiology of trachoma. *Ophthal. Rec.*, Aug., 1891.

409. THOMPSON, J. T. Emphysema of the conjunctiva. *Trans. Ophth. Soc. Unit. Kingd.*, vol. xi., p. 122.

410. DUNN. Some remarks upon the ætiology and treatment of the phlyctenular eye diseases. *N. Y. Med. Jour.*, Sept. 19, 1891.

CHIBRET (384) describes the various conjunctival affections from a bacteriological standpoint. In the first part the conjunctiva

is discussed in a healthy and diseased condition as a soil for bacilli. In the second, the various species of bacilli, and the diseases that they cause. Panas, in the discussion, thinks that there is a malignant form of blennorrhœa neonatorum, in which we find the gonococcus, and a benign form in which a bacillus, studied by Weeks, is discovered. In Coppez' opinion, follicular and granular conjunctivitis are identical.

HOLMES-SPICER (387) studied 158 cases of purulent ophthalmia (exclusive of ophthalmia neonatorum), amongst which were 126 men; 111 men, and 16 women were infected from the gonorrhœal secretion. Perfect restoration, or with but little injury, occurred in 110 cases. In every patient older than thirty-eight, with one exception, the eye was lost. Where the gonorrhœa had lasted four months, a cure was every time observed. In 98 cases in which the cornea had become involved, silver nitrate was employed; in 70 %, 55 % of these eyes were destroyed. Gonorrhoic rheumatism was present in 16 cases. In 5 the diseases began with the formation of a membrane. WERNER.

VALUDE (388) recommends the insufflation of iodoform instead of the instillation of silver nitrate as a prophylactic in blennorrhœa neonatorum. After the use of silver nitrate in the Hospital St. Louis, 7 % to 8 % of the children suffered from the blennorrhœa; whilst after the use of iodoform only 5 % were affected. In the Hospital Parnier the prophylactic treatment with the silver showed about 6 % of cases, whilst the iodoform only permitted 2 %. The iodoform should be dusted into the eyes before division of the cord. MARCKWORT.

NIEDEN (389) observed a case of blennorrhœa in a new-born child that was enveloped in the membranes. He thinks that the amniotic fluid, owing to diffusion of the membranes, was infected with noxious material, and so excited the inflammation.

OATMAN (391) treated a case of violent bilateral diphtheritis of the conjunctiva with canthotomy and incessant instillations of borated liquid for over four days. The result was successful. BURNETT.

HODGES (392) recommends iodide of silver in trachoma, and uses it thus: He first passes a solution (4 to 12) of silver nitrate over the lid, and then washes it over with a solution of iodide of potassium (pot. iodide, 8.00; aquæ, 8.00; glycerine, 16.00) whereby a precipitate of iodide of silver is formed. This treatment he has followed successfully for years. BURNETT.

SCOTT (393) has had good results from brushing a four-per-cent. solution of mercuric chloride over the ectropionized lid.

BURNETT.

DARIER (394) and Abadie recommend that in granular conjunctivitis the fold should be vigorously brushed under chloroform narcosis. Darier presented to the Soc. d.'Opht. of Paris seven cases alleged to be cured in this manner. Despagnet and Vignes, on the contrary, express themselves to the effect that the society were not unanimously able to convince themselves of the cure. Vignes suggests massage of the granulations with boric acid. Valude and Despagnet speak of the indifferent results in patients who had been brushed in Algiers by Abadie.

MARCKWORT.

MARPLE (395) describes grattage as practised by Darier in Paris, and reports two cases in which the operation was successfully performed. BURNETT.

MANOLESCU (396) again recommends the energetic brushing of granulations. After this has been done, the conjunctiva is irrigated with carbolic acid and sublimate solutions. After the hæmorrhage has ceased, the iodoform salve is applied. A sublimate bandage is renewed for ten days. One hundred and ninty-seven cases have been thus treated, with asserted good results. MARCKWORT.

After a short *résumé* of the various mechanical procedures resorted to for expressing the trachomatous substance from the conjunctiva, WEEKS (397) gives an account of the prevailing grattage, which is used in Abadie's clinique with the accompaniment of a strong aseptic. He reports twenty-one cases, most of which were cured. BURNETT.

In cases of hard and dry granulations, KEYSER (398) employed a piece of fine pumice stone. He has also employed Manolescu's brushing treatment with good results. BURNETT.

SMITH'S (399) method is a sort of squeezing and shelling out. He fixes the fold firmly with a smooth forceps with a long curve, incises the conjunctiva along the margin of the tissue embraced, and then forcibly squeezes out the contents. BURNETT.

COUÉTOUX (400) is of the opinion, that a considerable number of eye diseases are the sequence of diseases of the naso-pharynx. To this cause are especially due all sorts of phlyctenulæ, and vernal conjunctivitis. Adenoid vegetations are the foundation of all. We must treat these if we expect to cure the eye disease. The two characteristics of eye diseases with this ætiology are the

periodicity and the *localization at the margin of the cornea.* Five cases are appended. MARCKWORT.

CRITCHETT and JULER (402) observed in a man of sixty-six an epithelioma of the cornea, where formerly a pterygium had stood. The nodules were hard and cauliflower-looking, about an inch long, and embraced the entire outer circumference of the cornea. The surface was rough but did not bleed. The globe was enucleated and the tumor was discovered to resemble a malignant papilloma. WERNER.

SAPJESCHO'S (403) conclusions are as follows: That mucous membranes taken from animals do indeed heal in transplantation, but they sooner or later atrophy, as we can always observe by following the case long enough. Human mucosas heal nicely, when transplanted upon the eye. The mucosa of the mouth well supplies the place of the conjunctival mucosa. The successful introduction of a bit of mucosa into the split margin of the lid, is in the author's opinion the best cure in trichiasis and entropium. The lid must be split throughout its entire length for a depth of 5 or 6 *mm.* From the ends of the fissure two vertical incisions embracing the upper fold of the lid, and 3 to 4 *mm* long must be made in order that the opening may be covered over, and not left like a pocket. Total loss of the conjunctiva in symblepharon, xerosis, and hopeless cases of trachoma can be successfully replaced by mucosa from the mouth. The permanent effect is seen here as in other cases of transplantation in from one to two months.

BURNETT (404) thinks trachoma the manifestation of a dyscrasia primarily, and asks for a clear differentiation between trachoma and follicular conjunctivitis, which recent histological examinations seem to justify. He thinks the treatment should be constitutional as well as local, and recommends residence in high localities. He also again calls attention to the fact that he pointed out in 1876 that the negro is not liable to the disease, and quotes others as having since made the same observation.

CHEATHAM (405) treats some cases of severe trachoma with pannus, with pulverized jequirity, making from three to six applications. He watches the patient very closely during the jequirity inflammation. BURNETT.

DE SCHWEINITZ (406) has used fluorescin coloring of the cornea as a guide to the application of the actual cautery in serpent and other ulcers with much satisfaction. BURNETT.

FELLOWS (407) has used a gentle massage of the eye for some inflammatory troubles, particularly trachoma, and leucoma of the cornea, and also for simple "weak" eyes, where nothing could be found to account for the asthenopia. BURNETT.

FULTON (408) regards follicular conjunctivitis and trachoma as pathologically the same disease, and believes in the direct contagiousness of both. He recognizes the influence of race in the development of the affection. BURNETT.

THOMPSON'S (409) patient who had been operated on ten or eleven years previously for orbital exostosis, suddenly got emphysema of the conjunctiva and lids whilst blowing his nose. It disappeared in forty-eight hours after using a light pressure bandage. WERNER.

DUNN (410) from a study of phlyctenular diseases, particularly among the negroes, concludes that the origin of the disease can generally be found in the nose and naso-pharynx, and that the treatment should be directed to those parts primarily, and in particular, should adenoid vegetations be removed. BURNETT.

411. CHIBRET. Tincture of iodine in infectious ulcers of the cornea. *Rec. d'Ophth.*, 1891, No. 8, p. 513.

412. SEDAN. A word on the employment of tincture of iodine in ulcers of the cornea. *Rec. d'Ophth.*, No. 12, p. 710.

413. CAPEI. The tincture of iodine in infectious ophthalmia. *Boll. d'Ocul.*, xiii., p. 24.

414. SIMI. The tincture of iodine in infectious ophthalmia. *Boll. d'Ocul.*, xiii., p. 20.

415. SUAREZ DE MENDOZA. Treatment of ulcerations of the cornea with acid in a deliquescent state. *Rec. d'Ophth.*, 1891, No. 8, p. 474.

416. CHEVALLEREAU. Gouty keratitis. *Soc. d'Opht. de Paris*, 1891, March 2.

417. COLLINS. Two cases of staining of the cornea by blood pigment. *Trans. Ophth. Soc. Unit. Kingd.*, xi., p. 43.

418. DUBOIS DE LAVIGERIE. Hyperplastic epithelial plaque of the cornea. *Soc. d'Ophth. de Paris*, Oct. 6, 1891.

419. AVRES, S. C. Papilloma of the cornea. *Ophthal. Rec.*, vol. x., p. 257.

420. VALUDE. Epithelioma of the sclero-corneal limbus. *Soc. d'Ophth. de Paris*, Dec. 1, 1891.

421. PORYWAJEW. Epibulbar sarcoma. *Wjestnik. Ophth.*, Nos. 4 and 5, 1891.

422. CRITCHETT. A case of conical cornea, treated with the galvano-cautery with perforation of the cornea. *Trans. Ophth. Soc. Unit. Kingd.*, vol. xi., p. 150.

423. SILEX. Corneal transplantation. *Verhand. d. X. Int. Med. Cong.*, 1890, iv., 10, p. 157.

CHIBRET (411) is not much pleased with the galvano-caustic treatment of the infectious ulcers. He prefers to touch them with the tincture of iodine, which is applied every day or two by means of cotton. He sees fewer cases of staphyloma of the cornea with this method, and the cornea clears up more by this than by any other treatment. MARCKWORT.

SEDAN (412) reports that he used the tincture of iodine ten years ago in ulcerations of the cornea. MARCKWORT.

CAPEI (413) describes two cases of corneal infiltration in which the tincture of iodine produced a decided antiseptic action.

DANTONE.

SIMI (414) reports three cases of purulent keratitis in which the tincture of iodine proved to be an excellent antiseptic.

DANTONE.

SUAREZ DE MENDOZA (415) touches the corneal ulcers with pure, just soluble carbolic acid. At first he treated in this way only the severe cases, in which Sæmisch's operation or the cautery are the usual means employed, but now he uses the acid in the simpler forms. MARCKWORT.

CHEVALLEREAU (416) gives an account of a case of gouty keratitis with irregular white spots, with a diameter of 1½ *mm*, in both eyes on the centres of the cornea. Lateral illumination showed that the spots were situated in the lamina elastica and in the real corneal tissue. A bit of the tissue removed, proved to consist of crystals of urate of soda. The operative removal of the spots had to be abandoned in the fear of increasing the corneal opacity.

MARCKWORT.

COLLINS' (417) patients were fifty-six and forty years old, with serious injuries of the eyes. There were numerous blotches in the cornea in the form of reflecting granules, which extended through the whole cornea. They were yellowish, not orange. Descemet's membrane showed no abnormity.

DUBOIS (418) observed a peculiar tumor of the cornea which had been operated on by two physicians. It was situated on the

anterior margin, and measured 4 *mm* in breadth, and 1 *mm* in thickness. It was vascularized but extremely white. Dubois removed the tumor and cauterized the wound energetically with the galvano-cautery. It seemed to be a callosity. Kalt and Gillet de Grandmont were of the opinion that it was a case of epithelioma. MARCKWORT.

After a brief retrospect of the literature of the subject, AYRES (419) gives a clinical history of a case which he calls a papilloma of the cornea. The case was that of a woman of fifty with a tortuosity of the blood-vessels on the outer margin of the cornea for several years. There was also an elevation of the adjacent sclera, which gradually increased and extended to the cornea. The growth was repeatedly removed, but as often returned. When Ayres first saw the patient, the tumor covered the entire surface of the globe, which was finally enuncleated. The examination showed that the tumor consisted of very fine papillæ, which seemed to spring from the anterior portion of the surface of cornea. BURNETT.

VALUDE (420) publishes three cases from which he affirms that the epitheliomata of the limbus corneæ have the exclusive tendency to develop outward, but not toward the interior of the eye. MARCKWORT.

PORYWAJEW (421) describes a tumor which rested upon the medial side of the limbus corneæ of a man of seventy-five, covered the medial half of the cornea, and had slowly developed from a spot of pigment in the course of ten years. The tumor was abscised with scissors, the base scraped with a sharp spoon, and the defect covered with a conjunctival flap. The tumor consisted of a delicate connective-tissue framework, of large round and spindle-shaped cells and of numerous pigment cells. The benignity and slow growth of the epibulbar primary melano-sarcomata induces the author in all cases in which the vision is still satisfactory and even in relapses of the tumor, to remove it rather than to enuncleate the globe. HIRSCHMANN.

SILEX (423) has transplanted, after v. Hippel's method, the cornea of a guinea-pig upon the cornea of a dog, with good results. In nine attempts in man he had but one satisfactory result, in a boy, in whom the sight was increased from $\frac{1}{48}$ to $\frac{1}{16}$.

424. JOHNSTON. Notes of a case in which five eyelashes were carried into the interior chamber through a wound in the cornea,

Removal by an operation. *Trans. Ophthal. Soc. Unit. Kingd.*, vol. vi., p. 124.

425. CLARKE. Eyelash in anterior chamber. *Ibid.*, p. 125.

426. LAWFORD. Eyelashes in the anterior chamber. *Ibid.*, 126.

427. ARGYLL-ROBERTSON. Case of wound of the sclerotic with penetration of eyelashes into the anterior chamber. *Brit. Med. Jour.*, Aug., 1891, p. 473.

428. McHARDY. Cyst in anterior chamber of aqueous humor. *Trans. Ophthal. Soc. Unit. Kingd.*, vol. xi., p. 53.

429. COLLINS. On the pathology of intraocular cysts. *Royal Lond. Ophth. Hosp. Rep.*, vol. xii., 41.

430. STRAUB. A case of corneal fistula and traumatic astigmatism cured by an operation. *Weekbl. v. Ned. Tydsch. v. Genes.*, 1891, No. 22, p. 740.

In ROBERTSON's case (427), eyelashes fell into the anterior chamber through an incision in the sclera three *mm* from the corneal margin. They were later extracted. WERNER.

COLLINS (429) describes amongst others, a case of cyst of the cornea. WERNER.

A hussar injured his right eye. Three months later STRAUB (430) discovered a circular cicatrix of the conjunctiva close to the lower margin of the cornea. There was a shiny black spot in the centre of the cicatrix. A little blister filled with fluid, is often seen just above this point. The iris, close to the citratrix, forms a very fine fold in the direction of the black spot. The latter is a defect in the sclera through which the aqueous is constantly filtering beneath the conjunctiva. Hence, the well-marked hypotony. At the operation the cicatrix was split vertically to the margin of the cornea, and the fistula laid bare. It was impossible to suture the minute scleral incision, and therefore a triangular bit of conjunctiva with the base at the corneal margin was removed. After the conjunctiva was sutured, there was a linear cicatrix directly over the defect in the sclera. The cicatrix adhered closely to the sclera, closed the scleral opening, and formed a transparent, white, hard cord in the locality of the fistula. Tension normal. The astigmatism decreased and vision formerly $\frac{1}{3}$ increased to $\frac{1}{2}$. WESTHOFF.

(To be concluded in the next number.)

BOOK REVIEWS.

Diseases of the Eye. A Handbook of Ophthalmic Practice for Students and Practitioners. By G. E. De Schweinitz, M.D., Prof. Philadelphia Polyclinic, Lecturer University of Penn., etc. W. B. Saunders, Philadelphia, 1892.

This text-book is a handsome large octavo volume of 641 pages, very well printed, on good paper, and illustrated with 216 neatly executed drawings in the text, many of which are original, and two chromolithographic plates with seven ophthalmoscopic pictures, all reproductions. The work is conscientiously written, and represents, as far as the limits of a text-book permit, the actual standpoint of practical ophthalmology with remarkable completeness and attention to details. It is a medium between the smaller text-books of Nettleship, Swanzy, Schmidt-Rimpler, and others—so admirable for their conciseness and the strict adaptation to the needs of the student—and the more elaborate treatise of Noyes, Fuchs, Wecker-Masselon, and others, which are more calculated for the special student and practitioner of ophthalmology. De Schweinitz's book may very well be used by the college student as an introduction to eye surgery and serve him later as a book of reference in his practice. The functional diseases of the eye, methods of examination, etc., are very well presented (partly with the help of Drs. J. Wallace and E. Jackson), but not at the expense of the organic diseases. The book is remarkable for the harmony of its parts, no pet subjects of the author encroaching upon the space of other parts. The experienced and older ophthalmic practitioner also will read the book with advantage, for repetition, the well-known mother of all studies, is most conveniently and satisfactorily done by the reading of a diligently written modern text-book. H. K.

The Diagnosis of Diseases of the Nervous System. A Manual for Students and Practitioners. By Dr. C. A. HERTER, New York. G. P. Putnam's Sons, New York and London, 1892. Price, $3.00.

No department of medicine is more closely allied to ophthalmology than neurology. Every oculist must have a working knowledge of neurology, and Dr. Herter's book is exactly what he wants to assist him in acquiring such knowledge. It has 628 small octavo pages, well printed, with numerous illustrations in the text. Acquaintance with the systematic anatomy and physiology of the nervous system is presupposed.

The first chapter, 68 pages, describes the *structure and functions of the nervous system* only with a view to their practical importance in diagnosis.

The second chapter (pp. 69–212) is exceedingly useful. It treats of the *symptoms of nerve disease in general and in particular;* for instance: paralysis, convulsions, tremor, fibrillation, rigidity, contraction, catalepsy, athetosis, inco-ordination, conjugate deviation of the eyes and head, strabismus, diplopia, nystagmus, ptosis, pupillary symptoms, abnormal reflex action, sensory symptoms, headache, olfactory symptoms, visual symptoms, amblyopia, defective field of vision, hemianopsia, opthalmoscopic changes, auditory symptoms, vertigo, trophic symptoms (altered electrical irritability of nerves and muscles, etc.), vaso-motor symptoms, mental symptoms, disturbances of speech (excellent, 12 pages), general symptoms (temperature, pulse, respiration, etc.).

The third chapter, *localization of the lesion,* is a corollary to the second, describing the symptoms to which the different lesions of the special parts of the nervous system give rise; for instance, the cortex cerebri, the white substance and centrum ovale, . . . optic thalamus, internal capsule, corpora quadrigemina, . . . medulla oblongata, the base of the brain, the spinal cord, the nerve roots, etc.

The fourth chapter treats of the *nature of the lesion,* hyperæmia, anæmia, hemorrhage, softening, thrombosis of sinuses, meningitis, abscess, tumor, degeneration. Half of this chapter is devoted to the *etiology of nervous disease,* heredity, abuses and excesses, toxic influences, infective diseases (tuberculosis, syphilis, diphtheria, etc.), reflex influences (rather short).

The fifth chapter, the *diagnosis of clinical types,* describes the special forms of disease from a clinical standpoint, particularly

dwelling on differential diagnosis, for instance, of intracranial tumor, nuclear ophthalmoplegia, disseminated sclerosis, general paralysis of the insane, hydrocephalus, diseases of the spinal cord and special nerves, all of which are described systematically and in detail.

The sixth chapter, the *distinction of functional and organic disease*, describes hysteria, traumatic neurosis and psycho-neurosis, neurasthenia, epilepsy, migraine, chorea, paralysis agitans, neuralgia, etc.

The seventh chapter treats of the *examination of the patient*, and

The eighth gives fifteen *illustrative cases*, with critical remarks, to drill the student.

If the reviewer adds to this enumeration of the contents of the book the statement that the subject is presented with the greatest precision and clearness, in an easy style, frequently as attractive as a novel, and brought up to the latest standpoint of this eminently interesting and progressive branch of medical science, he need not particularly recommend it to the readers of these ARCHIVES, for it seems to be specially designed for their need.

H. K.

MISCELLANEOUS NOTES.

538 BROAD ST., PROVIDENCE, R. I.

H. KNAPP, M.D., ED. ARCHIV. OPHTHAL.

DEAR SIR :—I enclose a copy of a law recently passed by our legislature relative to Ophthalmia. It is, I think, the third State to adopt it. Yours, truly,

F. T. ROGERS, M.D.

STATE OF RHODE ISLAND AND PROVIDENCE PLANTATIONS.

CHAPTER 1056.

AN ACT FOR THE PREVENTION OF BLINDNESS.

Passed April 19, 1892.

It is enacted by the General Assembly as follows :

SECTION 1. Should any midwife or nurse, or person acting as nurse, having charge of an infant in this State, notice that one or both eyes of such infant are inflamed or reddened at any time within two weeks after its birth, Duties of midwife or nurse.

it shall be the duty of such midwife or nurse, or person acting as nurse, so having charge of such infant, to report the fact in writing within six hours to the health officer, or some qualified practitioner of medicine, of the city or town in which the parents of the infant reside.

Duties of health officer.

SEC. 2. Every health officer shall furnish a copy of this act to each person who is known to him to act as midwife or nurse in the city or town for which such health officer is appointed, and the Secretary of State shall cause a sufficient number of copies of this act to be printed, and supply the same to such health officers on application.

Penalty.

SEC. 3. Every person who shall fail to comply with the provisions of this act shall be fined not exceeding one hundred dollars, or imprisoned not exceeding six months, or both.

SEC. 4. This act shall take effect July 1st, 1892.

OFFICE OF THE SECRETARY OF STATE.
PROVIDENCE, R. I., May 11, 1892.

A true copy, Attest:

GEO. H. UTTER,
Secretary of State.

DR. AYRES' CHALAZION FORCEPS.

These forceps are made to facilitate the operation for chalazion. The ring is thin, and the plate fits into it so as press the tumor out and control all hemorrhage, while it is incised and curetted. The instrument is light and easily held by the left hand. Made by Max Wocher & Son, Cincinnati, O.

The HEIDELBERG OPHTHALMOLOGICAL SOCIETY will meet Aug. 7th–10th.

The meeting of GERMAN NATURALISTS AND PHYSICIANS will be held at Nürnberg from Sept. 12th–16th. Section of Ophthalmology Dr. v. Foster, Pres., Dr. Giulini, Sec'y.

Dr. SULZER has been appointed lecturer on ophthalmology at the University of Geneva, Switzerland.

MR. PRIESTLEY SMITH has been appointed professor of ophthalmology at Queen's College, Birmingham.

Fig. 1.

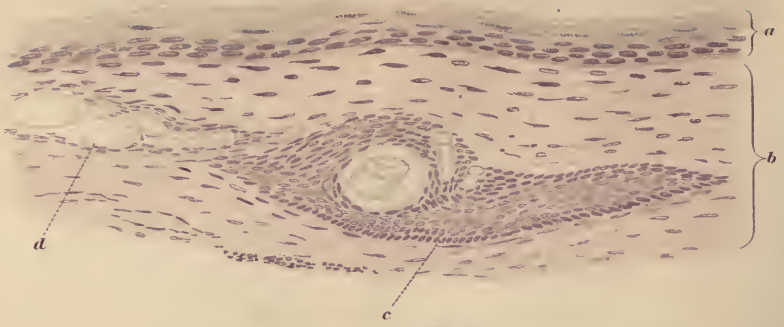

Fig. 2.

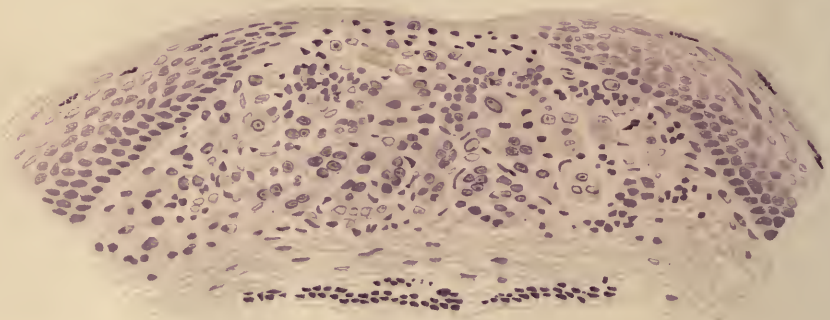

Fig. 8.



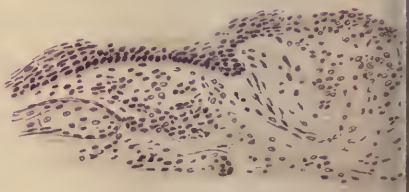

Fig. 6.

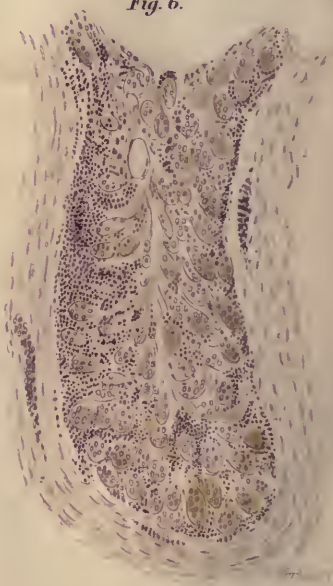

J. Rejsek ad nat. del.

Fig. 3.

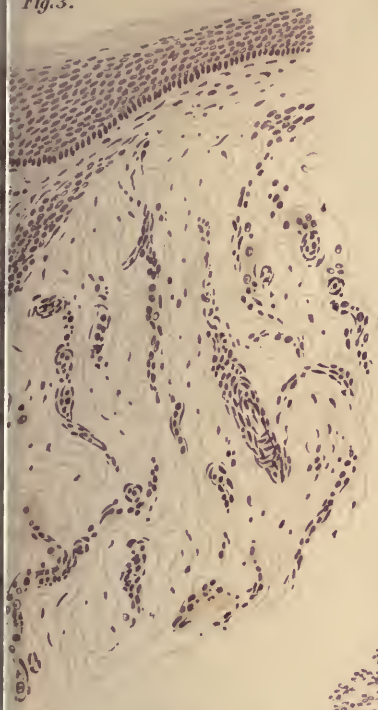

Fig. 4.

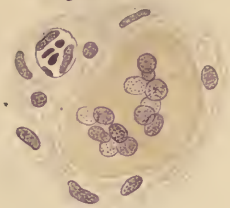

Fig. 13.

Fig. 7.

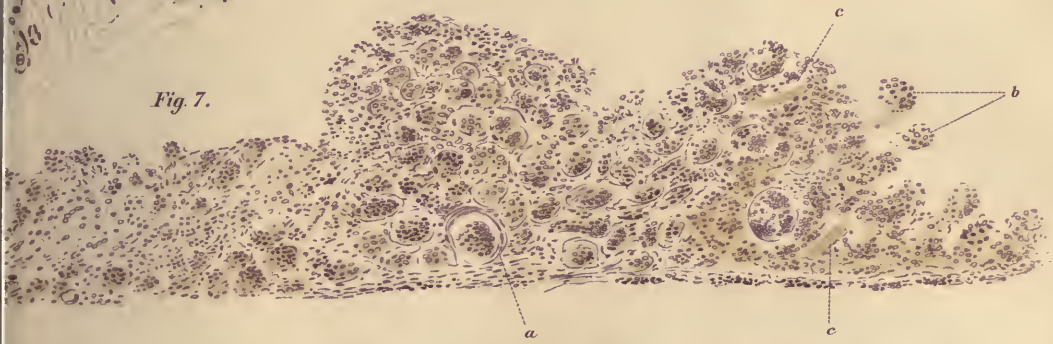

Fig. 5.

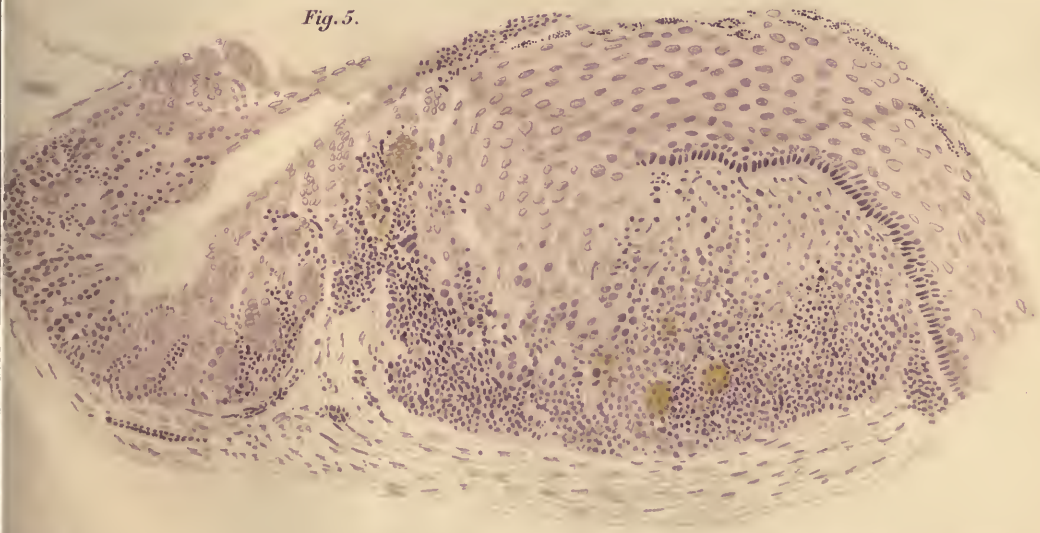

Lith Anst. v. C. Erst. Leipzig.

Fig. 9.

Fig. 17.

Fig. 15.



Fig. 11.

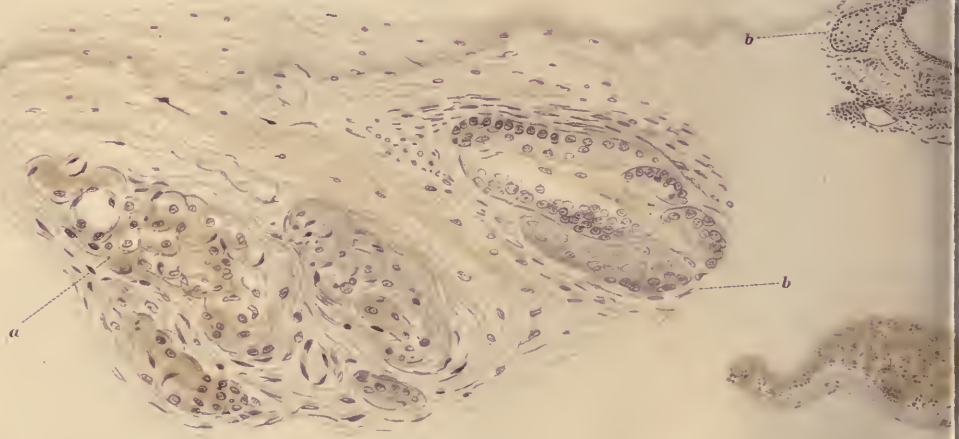

Fig. 18.

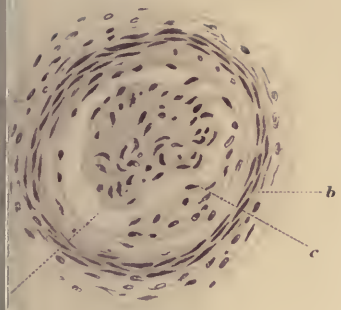

Fig. 16.

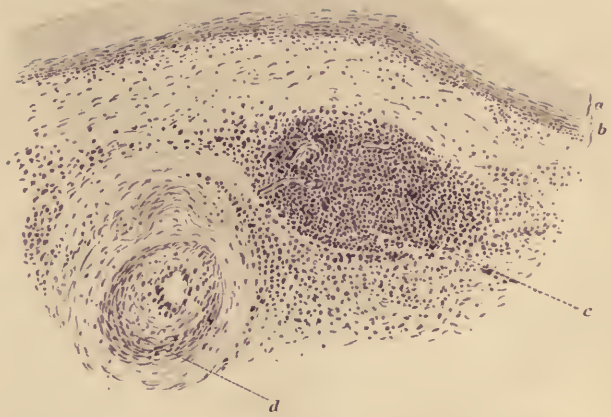

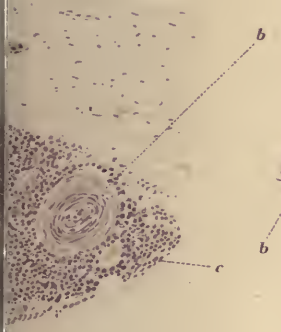

Fig. 10.

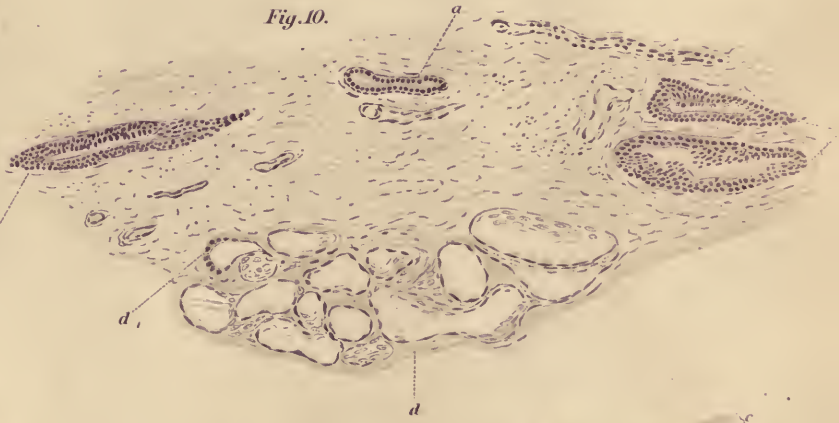

Fig. 12.

Fig. 14.

CONTENTS OF VOLUME XXI., NUMBER 4.

1. Penetrating Wounds of the Eyeball—Histological and Bacteriological Researches and Considerations Regarding the Pathogenesis of Sympathetic Ophthalmia. By C. E. Finlay, M.D., Habana, Cuba. (With six drawings, two in the text, and four on a plate at the end of the paper.) 457

2. Embolism of Arteria Centralis Retinæ. By Jno. M. Foster. (With two figures in the text.) 497

3. Microscopic Examination of a Case of Typical Inferior Coloboma of the Iris. By Ward A. Holden, M. D., New York. (With six figures—one in the text, and five on the accompanying plate.) . 499

4. A Remarkable Case of Pseudo-Trachoma. By Dr. Richard Greeff. Translated by Dr. Charles Zimmerman, Milwaukee. (With plate i., of vol. xxiv., Germ. ed.) 505

5. Sharp-Cut Ectasia at the Posterior Pole in High-Grade Myopia. By Dr. Leopold Weiss, Heidelberg. Translated by Dr. B. Alex. Randall, Philadelphia. (With five figures on plate viii. of vol. xxiii., Germ. ed., and one in the text.) 511

6. Remarks on Immature Cataract and the Best Method of Hastening Maturity. By Joseph A. White, A.M., M.D. 516

7. A Case of Sarcoma of the Choroid and Ciliary Body. Clinical History, by David Webster, M.D.; Microscopical Examination, by Ward A. Holden, M.D. (With a figure in the text.) . . 528

8. A Case of Homonymous Superior Hemianopsia. By Dr. F. Boé, Paris 533

9. Five Cases of Kerato-Conus Treated with Galvano-Cautery. By H. Knapp. (With a drawing.) 540

10. Systematic Report on the Progress of Ophthalmology during the Third and Fourth Quarters of the Year 1891. By Dr. St. Bernheimer, Vienna; Prof. Dr. Horstmann, Berlin, and Dr. Silex, Berlin. With the co-operation of Dr. S. M. Burnett, Washington; Dr. Dantone, Rome; Prof. Dr. Hirschmann, Charkow; Dr. E. Marckwort, Antwerp; Dr. P. von Mittelstädt, Metz; Dr. Werner, Dublin; Dr. C. H. A. Westhoff, Amsterdam; Dr. Schiötz and Dr. Ole Bull, Christiania; and Dr. Deus, Berlin. Translated by Dr. Jas. A. Spalding, Portland, Me. 548

    A.—Dr. P. Silex. Iris, 548; Choroid, 550; Glaucoma, 552; Sympathetic ophthalmia, 554; Vitreous, 556; Lens, 557; Retina and functional disturbances, 563; Optic nerve, 567; Injuries, foreign bodies (parasites), 570; Ocular disturbances in constitutional affections, 571.

11. Miscellaneous Notes 578

    Obituary.
    Errata.

12. Index 579

ARCHIVES OF OPHTHALMOLOGY.

PENETRATING WOUNDS OF THE EYEBALL—HISTOLOGICAL AND BACTERIOLOGICAL RESEARCHES AND CONSIDERATIONS REGARDING THE PATHOGENESIS OF SYMPATHETIC OPHTHALMIA.

By C. E. FINLAY, M.D., of Habana, Cuba,
RESIDENT ASSISTANT SURGEON AT THE NEW YORK OPHTHALMIC AND AURAL INSTITUTE.

(*With six drawings, two in the text, and four on a plate at the end of the paper.*)

THE following paper is based on the examination of thirty eyes. The investigations were conducted both with regard to the pathological lesions present and to their etiological factor considered from a bacteriological standpoint. In the first eleven cases, which were old, only a histological examination was made, the next fourteen were studied both from histological and bacteriological points of view, the remaining five bacteriologically.

HISTOLOGICAL CONSIDERATIONS.

The lesions met with in penetrating wounds of the eyeball vary greatly, depending on the structures directly involved, on the nature of the subsequent inflammation, and on the presence or absence of a foreign body.

We find perforating wounds of the cornea, with and without incarceration, prolapse or other injury of the iris, with and without injury to the lens, with and without penetration into the vitreous. The wound may be situated in the sclerotic, in the ciliary region, and then we may have incarceration or prolapse of the choroid and ciliary body, possibly even of the retina. The traumatism may be still

further complicated by large extravasations of blood into the substance of the different structures or into the spaces between them, bringing about an unnatural separation of the parts. These hemorrhages may be due either to a direct injury or to the accompanying contusion. Out of the thirty eyes examined histologically, in twenty-five the wound was situated in the cornea, in six of them at the sclero-corneal margin; the lens was injured in ten cases and had escaped in nine others; the iris had prolapsed in twelve cases, the ciliary body in two. There were six cases of scleral wounds (one, Case 10, presenting both a corneal and a scleral wound); they are all situated immediately behind the ciliary body; in only one case did the ciliary body and choroid prolapse. With regard to the hemorrhagic extravasations complicating the traumatism, there were three cases, Cases 2 and 3, where the enucleation was made in the first days after the injury and where there were only slight inflammatory changes, and Case 9, where the enucleation was made somewhat later and these changes were already marked. In Cases 2 and 9 the posterior extremity of the ciliary body and the anterior portion of the choroid were detached from the sclerotic by the extravasated blood; in Case 3 the retina was detached from the choroid, and the choroid from the sclerotic; in Case 9 there was, moreover, an extravasation of blood into the intervaginal space of the optic nerve.

The condition of the wounds and scars and of the prolapsed and injured structures will be found described in detail in the reports of the cases. Special attention is called to Cases 1 and 6, in each of which there is an organized band of fibrous tissue passing back from the corneal scar, *through the lens*, into the vitreous; to Case 18, where a defect in the cornea and lens is filled by densely infiltrated and escaping vitreous; to Cases 9 and 15, where the ciliary body is fastened in a corneal wound, whereas in Case 23 it is incarcerated in a scleral wound.

NATURE OF THE INFLAMMATION.

The nature of the changes found depends in a great measure on the time which had elapsed from the injury to

the enucleation. Thus we find that a very few of the eyes with severe and destructive injuries had been enucleated before any marked inflammation had set in. See Cases 2 and 3, with large intra-ocular extravasations of blood, where there was only slight inflammation, but quite distinct changes in the optic-nerve sheath; Case 19, where there was a perforating wound of the cornea with prolapse of iris and lens capsule, the lens proper having escaped; and Case 10, where the eyeball was enucleated after an ineffectual attempt to extract a foreign body lodged in the vitreous.

Four of the twenty-five eyes examined histologically were enucleated for an incipient panophthalmitis. In those the lesions consisted in an intense purulent infiltration of all the tissues of the eye especially of the uveal tract, dense deposits of pus cells on both surfaces of the iris, on the ciliary processes, and the retina; both chambers and the vitreous were, as a rule, nothing but one mass of lymphoid cells. In all these cases there was cellular infiltration of the optic nerve and its sheath. (See Cases 4, 15, 18, and 25.)

We come now to the most numerous as well as to the most important group of cases, as regards the greater danger of sympathetic ophthalmia—the irido-cyclitides. Sixteen out of the twenty-five eyes examined histologically belong to this group. They can be divided into three classes: (1) recent cases —where no organization of the exudation has as yet taken place; (2) cases of fully developed, chronic irido-cyclitis with the formation of new connective tissue in the shape of cyclitic bands and membranes; (3) a later stage—phthisis bulbi.

In the first stage we find, apart from the lesion directly due to the traumatism, a general lymphoid infiltration of the uveal tract chiefly in its anterior portions, a more or less abundant cellular deposit on the surfaces of the iris and ciliary processes; there may or may not be an infiltration of the optic nerve or its sheath. See Cases 12, 14, 20, 21, and 23. In Cases 12 and 23 only, was there infiltration of the optic nerve.

In the second stage we have the most important and characteristic lesions. We have to differentiate the cases where

the lens is injured or has escaped, or where the iris prolapses, from those where the lens and iris are *in situ.* Apart from the local differences, they present certain features in common, such as a more or less pronounced infiltration of the uveal tract, an organization of the exudation on the surfaces of the iris and ciliary processes, and in the interior of the vitreous the optic nerve or its sheath is, as a rule, infiltrated with round cells. If the case is far advanced, we find some atrophic changes in portions of the uveal tract. The connective-tissue formation in the vitreous brings about by its contraction certain mechanical changes in the structures which afford attachment to the newly formed bands and membranes; hence the difference alluded to above. In a typical, well developed case of irido-cyclitis we have the following changes: a total adhesion between the posterior surface of the iris and anterior lens capsule, a pushing forward of the lens and attached iris by the exudation in the vitreous, and at the same time a retraction of the iris angle by the connective-tissue bands in the posterior chamber and ciliary region of the vitreous. These, by their contraction, cause a total detachment of the retina, and later a detachment of the posterior portion of the ciliary body and anterior portion of the choroid from the sclerotic. Such typical conditions are found in Cases 5 and 16. In Case 7 we find an earlier stage of the process, the newly organized tissue having as yet only produced a detachment of the anterior portion of the retina and an elongation and backward inclination of the cells of the pars ciliaris retinæ (the wound was in the sclerotic). Should the iris prolapse or the lens be injured or lost, the picture is somewhat complicated, the mechanical problem being different. Thus in Case 1 there is an organized band of connective tissue extending from a corneal scar, *through the lens*, into the vitreous, and there dividing into two bands, which pass to the ciliary processes above and below respectively. Here the traction has only been sufficient to bring about an elongation and forward inclination of the cells of the pars ciliaris. In Case 11 where we find prolapse of the iris and lens capsule, with an escape of the lens, the traction of the cyclitic membranes

has brought about a detachment of the posterior portion of the ciliary body and of the anterior portion of the choroid. In Case 16 there is prolapse of the iris, and the connective-tissue contraction has as yet only produced an elongation of the cells of the pars ciliaris. In four of the six eyes belonging to this group, marked changes of an inflammatory nature are found in the optic nerve. In the two others, no sections involving the optic nerve were available. In one of these, however (Case 5), the infiltration of the choroid and retina towards the posterior pole of the eye is so marked that an implication of the optic nerve can be inferred. In this case there occurred, eighteen days after the enucleation, six weeks after the injury, an acute iritis or irido-cyclitis in the other eye, which was cured in six weeks.

In the third stage—phthisis bulbi—we find more advanced changes. The cellular infiltration has gradually disappeared. If present at all, it is only in the most anterior portion of the uveal tract. The cyclitic membranes and bands are much denser, the interior of the eyeball being one mass of connective tissue. This is pervaded by blood-vessels of new formation, and in many cases in the neighborhood of the ciliary processes we find the so-called "tubular excrescences of the uveal pigment,"[1] on the nature of which there has of late years been so much controversy. The most acceptable view as to their origin is that expressed by Alt,[2] and more lately by Treacher Collins,[3] who applied his method of bleaching of the uveal pigment in his studies. Both authors consider them as proceeding from the pigment epithelium, and as having a glandular nature. I can in no way agree with Berger,[4] who considers them as blood-vessels. The traction on the neighboring structures is much more pronounced than in the second stage; the retina is totally detached from the choroid; the posterior four fifths of the ciliary body and anterior portion of the choroid are separated from the sclerotic. The traction bears, moreover, on the

---

[1] See Case 8, Fig. 3.

[2] *Lectures on the Human Eye.* By Adolf Alt. New York, 1884.

[3] "The Glands of the Ciliary Body in the Human Eye." E. Treacher Collins. *Transactions of the Ophth. Soc. of the United Kingdom*, xi., 55.

[4] *Beiträge zur Anatomie des Auges.* Emil Berger. Wiesbaden, 1887.

external coats of the eyeball, especially on the insertion of the tendon of the ciliary muscle at the sclero-corneal junction, causing an alteration in its shape—a shrinking. The whole uveal tract becomes atrophic, there being at the same time an interstitial growth of connective tissue. The optic nerve also is atrophic. The lens, if present, is cretaceous; the cornea vascularized; the sclera thickened. Examples of this stage are to be found in Cases 6, 8, 13, 17 and 24. In Case 8 sympathetic ophthalmia had broken out in the other eye.

At a still later period we have a deposit of lime salts and formation of bone in different structures. None of these eyes show these changes.

INFLUENCES OF FOREIGN BODIES.

The influence of foreign bodies, lodged in the interior of the eye, in determining an inflammation, depends greatly on their septic or aseptic condition. Infected foreign bodies differ as to the virulence of the infection. If this virulence is pronounced a panophthalmitis quickly results, if it is moderate an irido-cyclitis of a more or less purulent or plastic character develops, whilst in cases in which the infection is very slight a localized inflammation may be the result, terminating in an encapsulation of the foreign body without the process advancing any farther. Aseptic foreign bodies are generally those which have been brought to a high degree of heat prior to their entrance into the eye[1]; such as pieces of guncap, etc. These, although not liable to produce either purulent or sympathetic inflammation, may bring about a plastic or puriform inflammation in the neighboring tissues either through mechanical irritation or their chemical action.[2] If the foreign body be of any size,

---

[1] Knapp: "Fermentation, Putrefaction, and Suppuration." *N. Y. Medical Record*, December 25, 1886.

Leber: *Ueber die Wirkung vom Fremdkörpern im Innern des Auges.* International Congress, London, 1881.

Leber: "Beobachlungen über die Wirkung Auge eingedrungener Metallsplitter. *Gr. Arch.*, xxx., p. 243.

[2] Leber: *Die Entstehung der Entzündung und die Wirkung der entzündungerregenden Schädlichkeiten.* Leipzic, 1891.

Kostenitsch: "Pathologisch-anatomische Untersuchungen über die Zündhütchenverletzungen des menschlichen Auges." *Gr. Arch.*, xxxvii., 4.

the plastic inflammation may be so extensive, as in the end to bring about a phthisis bulbi as in 13. In eleven of the thirty eyes examined the trouble originated in a foreign body. In Case 10 the eyeball was enucleated after an ineffectual attempt to extract it; in Cases 27 and 28 for an incipient panophthalmitis; in 20 and 21 for a cyclitis in its primary stage; in Cases 5, 7, 16, and 26 there was a well marked irido-cyclitis (in Case 5, as already mentioned, sympathetic ophthalmia broke out eighteen days after the enucleation); in Cases 6 and 13 (Figs. 2 and 4) the foreign body was capsulated and the process had gone on to phthisis.

BACTERIOLOGICAL INVESTIGATIONS.

Nineteen eyes, from Case 12 to 30 (inclusive) were examined from this standpoint.

METHOD.—The method employed in all these investigations was as follows: the eyeball at the time of the enucleation was placed in a sterilized and closely stoppered jar. As soon as feasible, inoculations were made into gelatine and agar, from the intervaginal space of the optic nerve and from the interior of the eyeball. In making the former, the cut end of the optic nerve was first scorched with the blade of a red-hot knife; the point of a carefully sterilized platinum needle was then introduced into the intervaginal space, withdrawn, and the desired tube inoculated, repeating the process as often as desired. An opening was then made through the sclerotic with a red-hot knife, the lips kept opened with the blades of sterilized forceps, the platinum needle introduced, moved around a little, and the tubes inoculated in the ordinary way.

At first the inoculations were made in the shape of puncture cultures (both into glycerine agar and into gelatine), and if these yielded positive results pure cultures of the different microbes present were obtained by means of plate cultures or Esmarch tubes. This method was found a little too complicated, so that in the later investigations the Esmarch's were inoculated directly from the intervaginal space of the optic nerve and from the interior of the eyeball.

Cover-glass specimens were made in some, but not all the cases. The search for the microbes in the tissues was only made in a few of the cases, due to a lack of time; some of the specimens, moreover, were overgrown by budding and fission fungi, notwithstanding the fact that the eyes had been hardened in alcohol, thus rendering the examination invalid.

RESULTS.—As can readily be seen, the methods just described would, if anything, favor a negative result. As the platinum needle could only come into contact with a very limited portion of the intervaginal space it would perhaps have been better to have excised a piece of the nerve, to have carefully sterilized its external surface, then to have placed it into sterilized broth, and to have broken it up into small pieces in its interior, and then if a positive result was obtained to have isolated the different microbes by means of Esmarch tubes or plate cultures. With regard to the cultures from the interior of the eye, it would perhaps have been also better, as more likely to yield a positive result, to have, as practised by others, opened the eyeball with sterilized instruments under some neutral and sterilized liquid, and to have made the cultivations from the points where the exudation was most marked—from the neighborhood of foreign bodies, as it is a well-known fact, that in the latter case the bacteria are, as a rule, only found in their immediate surroundings, especially if the inflammation be not far advanced. These faults in the process will explain the almost uniform negative result of the optic-nerve sheath cultures, and of those from the interior of the eye where a foreign body was lodged in the vitreous—thus in a way detracting from their importance; they however only increase the value of the positive results obtained.

The detailed account of these investigations will be found in the reports of the cases. I will, however, now give a general *résumé* of the results obtained.

In Case 19, where the eyeball was enucleated before the outbreak of any inflammation, there was, as one would expect, a negative result. There were five cases of incipient

panophthalmitis[1]; in three the results were positive (Cases 15, 18, and 25). Among these are counted two where the tube cultures proved negative, but where numerous cocci, irregularly arranged in groups, were demonstrated in the cover-glass specimens prepared directly from the exudation in the vitreous. In the other case (Case 15) a bacillus was cultivated both from the intervaginal space and from the interior of the vitreous. This bacillus was thoroughly worked up, as can be seen in the report of the case, and its pathogeneity and ability to produce suppuration fully established. Its characters do not tally with any of those described in the text-books. It seems to belong to the proteus group.

Out of six eyes which were enucleated during the first stage of a cyclitis,[2] positive results were obtained only in three cases (12, 14, 23). All these were obtained from the interior of the vitreous, those from the intervaginal space being all negative. The microbe found was invariably the staphylococcus pyogenes aureus (Rosenbach).

In the three cases where there was a full developed iridocyclitis, the staphylococcus pyogenes aureus was isolated in two from the interior of the eyeball (Cases 22 and 30); in one (16) from the intervaginal space. In this case a non-pathogenic coccus was cultivated from the interior of the eye, but no staphylococcus pyogenes.

The results were negative in the four phthisical eyes examined (Cases 13, 17, 24, 27). In Case 13 a large piece of gun-cap was embedded in the vitreous (Fig. 4), and although over fifty sections were examined, no microbes of any kind could be discovered in the tissues. This bears out Leber's and Kostenitsch's investigations[3] on the subject of gun-cap injuries. No tests were made as to the presence of copper salts in the different tissues.

We therefore have 9 positive results from the interior of the eyeball and 2 from the intervaginal space, in a total of 19 cases.

---

[1] Cases 15, 18, 25, 28, and 29.

[2] Cases 12, 14, 20, 21, 23, 26.

[3] *Ueber die Entstehung der Entzündung und die Wirkung der entzündungerregenden Schädlichkeiten.* Theo. Leber, Leipzig, 1891.

"Pathologisch-anatomische Untersuchungen über die Zundhütchenverletzungen des menschlichen Auges." Kostenitsch. *Gr. Arch.*, xxxvii., 4.

CONCLUSIONS.—The conclusions to be drawn from these investigations, taking into account the methods employed and the results obtained, especially in the fully developed cases of irido-cyclitis and panopthalmitis, are:

(1) The inflammation following injuries is due to an infection with pyogenic germs. In only exceptional cases can it be attributed to purely mechanical or chemical influences.

(2) The germ bringing about this inflammation is in by far the greater majority of the cases the ordinary staphylococcus pyogenes aureus, my experience in no way agreeing with that of Haab and Poplawska, who in cases of panophthalmitis find a peculiar bacillus.[1] In only one case (Case 15) was a bacillus found. This differed essentially from Haab's, as anybody can see who compares both descriptions. That inflammation of a suppurative character can be produced by microbes other than the staphylococci is universally acknowledged, but it is the exception, and not the rule. Dr. Knapp, about two years ago, enucleated an eye for an intensely severe and rapidly developing panophthalmitis, and in the cover-glass specimens prepared from the pus in the vitreous he found Fraenkel's pneumococcus.[2] Limbourg and Levy have also found the pneumococcus in cases of panophthalmitis.[3]

(3) On account of the method employed, no conclusions can be drawn from the almost uniformly negative results obtained in the inoculations from the intervaginal space.

CONSIDERATIONS WITH REGARD TO SYMPATHETIC OPHTHALMIA.

The danger of sympathetic ophthalmia in the healthy eye is always a source of great anxiety to the oculist in every case of traumatic irido-cyclitis; hence the assiduity with which the master minds in ophthalmology have devoted themselves to the solution of the dark problem of its production and the manner in which the inflammation

---

[1] Haab, *Fortschritte der Medecin*, ix., p. 781.
Poplawska, ARCH. OF OPHTH., xxi., 1.

[2] This case has not yet been reported, and I mention it with Dr. Knapp's kind permission.

[3] Limbourg and Levy, *Arch. f. experiment. Path. und Pharmak.*, xxviii., 153.

is transmitted to the second eye. The literature on the subject is most extensive. Mackenzie, who in the second edition of his work on *Diseases of the Eye*, in 1844, first gave a complete clinical picture of the disease (which to this day has not been improved upon), declared himself for a direct propagation of the inflammation along the optic nerves through the chiasm. Then came the era of reflex neuroses, and the ciliary nerve theory made its appearance, this being first advocated by Heinrich Müller in 1859. This theory held sway till modern times, some of its advocates believing in a direct transmission of the inflammation up the ciliary nerves to the brain, and down the ciliary nerves of the other side; some in a sympathetic reflex irritation in the peripheral terminations of the ciliary nerves of the healthy eye, which brings about first vasomotor disturbances in the uveal tract, and which gradually develops into an inflammation of a more or less plastic character. The advocates of the ciliary nerve theory to-day are believers in this last mode of transmission. Then came the discovery of bacteriology and of the microbic origin of suppuration. The minds of ophthalmologists were immediately directed towards a transmission through the lymphatics of the optic nerve. Colsman, in 1877, is the first, I believe, who, in a description of a case of sympathetic neuro-retinitis after the enucleation of the first eye, revived the theory of a transmission through the lymphatics of the optic nerve.[1] Knies,[2] Leber,[3] McGillavry,[4] Berlin,[5] Snellen,[6] Poncet,[7] came out in defence of this theory, especially after Knies' classical case of double-sided iritis serosa. To Deutschmann, however, belongs the glory of first attempting to produce an *experimental* proof of the theory.[8] Hitherto all had been surmise. The problem was now carried into the field of experimental science.

---

[1] *Berliner klin. Wochenschrift*, 1877, No. 12.
[2] Knapp's ARCHIVES, ix., 2, 125 (English edition).
Ophth. Beiträge als Festgabe Friedrich Horner's. Wiesbaden, 1881.
[3] *Arch. f. Ophth.*, xxvii., 1, 325.
International Med. Congress, London, 1881.
[4] International Congress, Amsterdam, 1879. *Ann. d'Oculistique*, *t.* 82, p. 172.
[5] *Volkmann's Sammlung klin. Vorträge*, No. 186, 1880.
[6] International Congress, London, 1881.
[7] International Congress, London, 1881.
[8] *Arch. f. Ophth.*, xxviii., 2, 291.

Anatomical investigations, conducted in eyes removed to avert the danger of sympathetic ophthalmia or, in cases where it had already broken out, to influence its course favorably, all tend to show that in every well marked case of cyclitis there is a tendency for the optic nerve to be implicated. See the statistics of Alt [1], Berger [2], and those here published. In fifteen of the twenty-five eyes which I examined histologically, there existed some cellular infiltration of the optic nerve or its sheaths, and if we consider only the cases of panophthalmitis or fully developed irido-cyclitis, there is scarcely an exception. The ciliary nerves are also involved in a good proportion of the cases; Berger found them affected in nine out of fourteen cases; I found changes in ten out of twenty-five. These changes have not, however, in my mind, the importance that the inflammation of the optic nerve or its sheaths has, being mostly limited to a moderate cellular infiltration of their sheaths, especially in their passage through inflamed areas; this is no more than one would expect.

The ciliary-nerve theory rests on purely hypothetical grounds—not being supported by any experimental fact—those of Rumpf and Mooren not having been confirmed by Ker, the results claimed being due, as pointed out by Knies, in Prof. Horner's *Festgabe*, to a non-differentiation between the symptoms of sympathetic irritation and those of sympathetic inflammation. Moreover, this theory cannot hold its own even on theoretical and clinical grounds. Nowhere else in the body can we find any similar affection; there is no other example of a reflex neurosis being converted into an inflammation; wherefore then should this new function be invented in a certain set of nerves to explain this affection? It would seem more rational to fall back on a peculiarity which another set of nerves connected with the eyes present, and which is not found elsewhere in the body—*i. e.*, the crossing and mingling of the fibres of the optic nerves at the chiasm—allowing us to explain the transmission of the inflammation by direct continuity of tissue through the

[1] *Arch. of Ophth. and Otology*, v., 3 and 4.
[2] *Beiträge zur Anatomie des Auges.* Emil Berger. Wiesbaden, 1887.

lymphatics of the optic nerve proper or through those of its sheath. It must be admitted, however, with regard to this view, that no very satisfactory explanation has been given for the non-occurrence of a basilar meningitis. There are certain clinical facts which are utterly unexplainable under the ciliary-nerve theory: (*a*) why is not every case of sympathetic ophthalmia preceded by a period of irritation? (*b*) cases where large aseptic foreign bodies, like pieces of gun-cap, are imbedded in the interior of the eye for years without causing any sympathetic trouble (see Case 13, and Leber's and Kostenitsch's investigations)—one could scarcely imagine anything more likely to irritate the ciliary nerves; (*c*) cases of sympathetic ophthalmia occurring after enucleation.[1] We must therefore conclude that *the ciliary-nerve theory is utterly devoid of proof and altogether insufficient to explain the transmission of the inflammation from one eye to the other.*

With regard to the carrying over of the microbes, or their products from one eye to the other, three routes have been advocated: (1) Berlin[2] in 1880 held that the microbes or their ptomaïnes were taken up into the general circulation and distributed all over the body, finding however a suitable soil in the uveal tract of the healthy eye; (2) Deutschmann[3] supports in his different communications the intervaginal space of the optic nerves as the path pursued by the micro-organisms in their passage from the injured to the healthy eye: (3) Gifford[4] advocates an exit of the microbes along

[1] Mooren, *Ophthalmiatr. Beobachtungen*, 1867.
Colsman, *Berliner klin. Wochenschrift*, No. 12, 1877.
Steinheim, *Arch. f. Augenheilkunde*, English Edition, ix.
Nettleship, *Brit. Med. Journal*, April 17, 1880.
White, *Brit. Med. Journal*, April 16, 1881.
Frost, *Transactions of the Ophth. Soc. of the United Kingdom*, ii., p. 21.
Critchett, *Royal London Ophth. Hosp. Reports*, x., 322.
Bower, *Brit. Med. Journal*, May 26, 1883.
Gunn, *Royal London Ophth. Hosp. Reports*, xi.
Schmidt, *Arch. f. Augenheilkunde*, 1877, p. 177.
[2] *Volkmann's Sammlung Vorträge*, No. 186.
[3] *Arch. f. Ophth.*, xxviii., 2, 291.
Arch. f. Ophth., xxix., 4, 261.
Arch. f. Ophth., xxx., 3, 77.
Arch. f. Ophth., xxx., 3, 331.
Ophthalmia Migratoria. Hamburg, 1889.
Arch. f. Augenheilkunde, xxii., 119.
[4] ARCH. OF OPHTH., xv., 2, 153.
International Med. Congress, Washington, 1887.

the perivascular lymphatics of the central blood-vessels, thence with these into the orbit, through the sphenoidal fissure to the base of the brain, and down the intervaginal space of the healthy nerve.

Deutschmann's explanation is undoubtedly the most probable. Gifford's objections are based on the directions of the lymph currents. Apart from the difficulty in determining these accurately (Gifford himself has lately modified his old views somewhat)[1], there is good reason to believe that the lymph currents are not the same in cyclitic as in healthy eyes.

It must, however, be admitted that whilst Deutschmann's theory is the most rational and explains in the most satisfactory manner the conditions under which sympathetic ophthalmia makes its appearance, it still lacks full experimental confirmation, for in the greater number at least of his cases of experimental sympathetic ophthalmia the inoculated rabbits died either from a purulent meningitis or from a general systemic infection, thus in a way marring the result. This, I believe, is due to the production of a too violent inflammation in the first eye; it would be more desirable to induce a slow-going form of irido-cyclitis such as is mostly seen producing sympathetic ophthalmia in man; this can be obtained by diluting the culture four to five times before making the inoculation. This method would of course entail a large number of negative results, as it is by no means in all but only in a small percentage of cases of chronic irido-cyclitis that sympathetic ophthalmia occurs. In a rabbit which I inoculated in this manner with the staphylococcus pyogenes aureus I brought about such a chronic inflammation, but no sympathetic ophthalmia developed in the other eye although the rabbit was kept several months.

Another point which is not quite definitely decided is whether the inflammation in the second eye is due to a direct action of the pyogenic germs, or whether only their ptomaïnes have been carried over from the first affected eye. Every-

---

[1] Arch. of Ophth., xxi., 2, 181.

thing points to a carrying over of the micro-organisms themselves; and the few experiments made by Deutschmann tend to confirm this view; they are, however, not numerous enough to warrant a definite conclusion.

REPORT OF CASES.

CASE 1 (Fig. 1).—A. B. "Cyclitis after injury." Enucleation on April 4, 1883, by Dr. H. Knapp.

Anatomical Examination; The cornea presents a large scar running across its inferior half. The condition of the scar is most interesting. Its surface projects beyond the level of the cornea and is covered with epithelium. Superficially it is mostly made up of spindle cells, more or less regularly arranged, with their long axes parallel to each other and to the surface

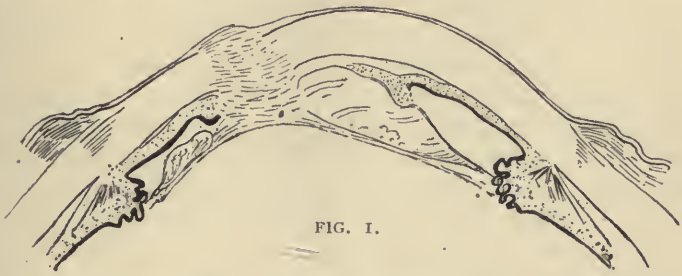

FIG. 1.

of the scar—thus simulating in a manner the lamellar structure of the cornea. Deeper the spindle cells are no longer so regularly parallel; several blood-vessels, proceeding apparently from the periphery of the cornea, are found among them. Still deeper the cells assume an antero-posterior direction. This new-formed connective tissue is directly continuous with a fibrous band which passes back, through the pupil and *through the periphery of the lens,* dividing it into two segments. At the level of the posterior surface of the lens, it splits into a superior and inferior band, which proceed to the ciliary processes above and below respectively. The structure of this band is densely cellular; its bulk is constituted by spindle cells having a more or less antero-posterior direction, their arrangement being much closer than that of those entering into the formation of the corneal scar; numerous lymphoid cells are also to be found among them, as well as a few scarce blood-vessels. The surfaces

of the band are very irregular; the lower is loosely connected with the lower half of the iris, but much more intimately with the lower segment of the lens, portions of the lens capsule being involved in its fibrous tissue; the superior is loosely connected with the upper segment of the lens. Of the two bands into which the one just described divides, the lower is the much more distinct; they are likewise made up in their greater part of spindle cells, which follow the directions of the bands. We find the angle at the point of subdivision filled with spindle cells, not so thickly nor so regularly arranged as in the bands proper; their direction is more or less vertical.

The cornea shows the usual round-cell infiltration in the neighborhood of the scar and at the periphery. The circumcorneal blood-vessels are dilated and surrounded by round cells. The sclera is normal. Near the ciliary region we find some slight infiltration of the sheath of one or two of the ciliary nerves as they pass through it. The iris is not involved in the wound. The lower half is loosely connected with the lower surface of the fibrous band passing back from the corneal scar. The upper one forms a broad synechia with the upper segment of the lens. The iris is applied to the posterior surface of the cornea though not adherent to it; it is atrophic, there being at the same time a relative increase in its connective-tissue elements; in its greater portion it is only very moderately infiltrated; where, however, it forms the synechia with the lens, it is spread out fan-shaped and is markedly infiltrated. The ciliary body is atrophic. The cells of the pars ciliaris retinæ are little if at all altered in the upper half, there being, however, some cellular deposit on their surface and some organization of the neighboring vitreous; in the lower half they are elongated and inclined forwards, on account of the greater traction on them. The choroid shows a relative increase in its connective-tissue elements and some dilatation of its blood-vessels. These changes are most marked near the optic-nerve entrance. The retina is normal. The lens is divided completely into two segments by the fibrous band proceeding backward from the corneal scar. Its central portion is distinctly marked off from the remainder: it is most disorganized; its fibres are more swollen; there are more vacuoles, filled at places with round cells, at others with myeline globules. In the neighborhood of the synechia with the iris large numbers of lymphoid cells are to be found among the lens fibres. This

synechia takes place by a growth of connective tissue springing from the iris, which interlaces with the broken and swollen fibres. The lens capsule is normal, that of the upper segment being lost in the synechia between the iris and lens, that of the lower in the corneo-vitreal synechia. In the zonula and anterior portion of the vitreous there is some connective-tissue organization.

CASE 2.—H. H., æt. fourteen years. "Perforating wound of globe," L E.

History: Patient was brought to the Dispensary on *November* 6, 1884, the left eye having been struck by a stone the day before.

Condition: There was a wound extending entirely across the cornea into the ciliary region—no perception of light—enucleation advised. Eyeball enucleated on November 8, 1884, by Dr. T. R. Pooley.

Anatomical Examination: A wound extending across the cornea obliquely from above downwards. Through it iris and lens capsule prolapse and most of the lens has escaped. The iris in the wound is very much swollen and infiltrated with lymphoid cells, as well as extravasated blood. In the wound, or rather just outside it, there is some swollen lens matter. The gap contains blood and numerous round cells seemingly thrown out from the edges of the wound. Posteriorly there is a large extravasation of blood on the external surface of the sclerotic, near the optic-nerve entrance; the loose tissue in the situation is also markedly infiltrated with round cells. The ciliary nerves as they pass through the infiltrated areas of the sclerotic show, at places, some cellular infiltration of their sheaths. The non-prolapsed half of the iris is applied to the posterior surface of the cornea; it is intensely pigmented and it is difficult to make out its histological details; it is thickened and there is some lymphoid-cell infiltration. The posterior extremity of the ciliary body and the choroid are totally detached from the sclerotic by a large extravasation of blood into the supra-choroideal space. The ciliary body is not much altered; posteriorly and externally, where the choroid commences to be detached, there is some cellular infiltration; it is deeply pigmented. The choroid has 5-6 times its normal thickness, due to an extravasation of blood into its substance; it is also moderately infiltrated. The retina is mostly healthy; at places there is some slight cellular infiltration, at others some hemorrhage into its substance; a moderate cellular deposit is scattered over its surface. There is some infiltration of the lymph channels of the optic-nerve.

The anterior portion of the vitreous and both chambers are filled with blood and *round* cells.

CASE 3.—M. M., æt. twenty-five. "Perforating wound of ciliary region," L E.

History: On *June* 22, 1883, patient presented himself at Dr. D'Oench's private office. He had been struck in the left eye with a stick, and showed a vertical cut in the ciliary region about ½ inch long, also two smaller wounds at the inner canthus and on the bridge of the nose. The iris had prolapsed through the ocular wound. Prolapsed iris abscised, wound cleansed, atropine. *June* 23*d*, pain, chemosis of ocular conjunctiva; towards evening, muco-purulent discharge. *June* 24*th*, chemosis increased; patient referred to New York Ophthalmic and Aural Institute, where eyeball was enucleated.

Anatomical Examination: This revealed the injuries attendant on a profound injury to all parts of the eye. The lens had escaped through the wound, the corneal lip of which overlaps the scleral considerably. There has been a large intra-ocular hemorrhage, which has brought about a detachment of the choroid from the sclerotic, and of the retina from the choroid. The whole uveal tract is infiltrated with blood, rendering its structure scarcely recognizable. Large masses of blood are found in the anterior and posterior chambers, as well as in the little vitreous left. Schlemm's canal and Fontana's spaces are on the side opposite the wound, distended with blood. The optic nerve shows a slight degree of inflammatory infiltration. There is some lens capsule in the wound.

CASE 4.—C. D., æt. fourteen years. "Perforating wound of globe—panophthalmitis."

History: December 27, 1883, patient came to Dr. H. Knapp's office. He had been struck in the eye two days before, whilst working in a factory. Condition: A horizontal wound along inner half of cornea, through which pus escaped; whole anterior chamber filled with pus, only outer margin of iris visible; visual field narrowed. Sent to Institute. *December* 28*th.*—Considerable pain during the night. *December* 30*th.*—Free from pain during the night; pus in anterior chamber diminished, but still escaped through wound. *January* 1*st.*—Condition about the same; has had pain at times; T increased. *January* 3*d.*—Pain at night; perception of light almost entirely gone. *January* 5*th.*—Enucleation by Dr. H. Knapp.

Anatomical Examination: There is a perforating wound of the cornea and lens with the lesions of a subsequent panophthalmitis; in the centre of the cornea a scar deeply infiltrated with round cells, to which a portion of the iris is loosely adherent. The neighboring cornea as well as the region of Schlemm's canal is deeply infiltrated. The circumcorneal blood-vessels are very much dilated and surrounded by an abundant cellular exudation, which also pervades to a greater or a less degree the loose episcleral tissue. The sclerotic is moderately infiltrated, especially near the optic-nerve entrance and anteriorly near the sclero-corneal junction. The ciliary vessels passing through it are distended and surrounded by round cells. The ciliary nerves, also, at places, show some cellular infiltration of their sheath. The iris is immensely swollen and pervaded by an enormous number of lymphoid cells; a portion is loosely connected with the corneal scar. The anterior and posterior surfaces, especially the latter, are covered by a thick layer of round cells; this exudation occupies the whole posterior chamber, pushes the iris forward, more or less obliterating the iris angle This is still further enhanced by the intense swelling of the parts which enter into its formation.

The ciliary body is markedly infiltrated with leucocytes. The inflammation shows itself in this region in a very abundant deposit on the surface of the ciliary processes, which is continuous with that on the posterior surface of the iris, filling the zonula completely. There is some tendency towards organization of this exudation—some cells having acquired a distinct spindle shape. The blood-vessels of the choroid are distended with blood; there is abundant cellular infiltration, especially in their neighborhood; at places there is some extravasation of blood. The retina is, at one or two places, partially detached from the choroid, this being produced by an extravasation of blood between them It is very much infiltrated, its structure being at places scarcely recognizable. There is a large accumulation of round cells on its internal surface, especially near the optic-nerve entrance, where they are accumulated in enormous numbers.

The optic nerve is also very much infiltrated with lymphoid cells, these being mostly found between the bundles of nerve fibres and in the intervaginal space. They are accumulated in large numbers on the surface of the papilla.

A wound is in the centre of the lens. The structure of the lens is greatly altered; its fibres are separated and swollen, and between

them we find large numbers of pus cells, which pass through the opening in the capsule and mingle with the round and spindle cells in the posterior chamber and pupillary area. The anterior chamber is occupied by a cellular exudation, which is mostly deposited on the anterior surface of the iris; a portion of it is partially organized and connects a portion of the iris to the scar. The pupillary area and posterior chamber are filled by the same exudation. The vitreous is also very much infiltrated. On the posterior surface of the lens there is an abundant cellular deposit which is partially organized.

CASE 5.—C. B. "Cyclitis after injury; foreign body (right eye); sympathetic ophthalmia (?) in the other eye coming on after the enucleation."

History: Injury received on *July* 4, 1884, enucleation *August 1st* by Dr. H. Knapp. Healing smooth, patient discharged from Institute on *August 7th*. *August 18th* patient came to Dispensary. L E: Iris dull, slight circumcorneal injection, fundus veiled, venous congestion of the retina, no neuro-retinitis $V = \frac{20}{60}$.

Diagnosis: Irido-choroiditis sympathica (?). Readmitted *August 20th*. Some opacity of fundus and slight pericorneal injection. *August 25th*, injection disappeared, pupil *ad max.* dilated, sees well. Improved steadily. Discharged *September 7th*, cured.

Anatomical Examination: There is a wound in the periphery of the cornea, penetrating through the iris and zonula into the vitreous. A piece of steel $2''' \times 4'''$ (rectangular in shape), was found imbedded in a mass of exudation in the ciliary region of the vitreous.

The cornea is moderately infiltrated. The circumcorneal blood-vessels are widely dilated and surrounded by numerous round cells. Some cellular infiltration of the sclerotic. The ciliary nerves, in their passage through it, show a moderate infiltration of their sheath. The iris presents the usual condition met with in cyclitic eyes—*i. e.* a total adhesion between its posterior surface and the anterior lens capsule, with the consequent obliteration of the posterior chamber; a retraction of its angle, caused by the traction of the cyclitic membranes; and a marked, but not excessive, round-cell infiltration. The posterior extremity of the ciliary body is detached from the sclerotic by the cyclitic membranes, the ciliary processes being drawn forward and inward. There is an abundant infiltration of its substance. The choroid participates in the general cellular infiltration of the uveal tract, which is here more marked than elsewhere; at places the round cells form large foci. The retina is totally detached, and shows

the usual degenerative changes. No sections involving the optic nerve were available, the eyeball not having been preserved as perfectly as one would desire; but from the marked infiltration of the posterior portion of the choroid, it is more than probable that it participates in the general inflammation. The lens with the adherent iris is displaced forwards by the exudation in the ciliary region. The whole ciliary region of the vitreous is occupied by newly formed membranes, which, by the traction they exert on the structures to which they are attached, have brought about a detachment of the retina, of the posterior portion of the ciliary body, and a retraction of the iris angle. Besides the connective tissue cells making up these membranes, they are found abundantly infiltrated with round cells. The number of blood-vessels of new formation is remarkable. Near the surface of the ciliary processes they show some slight diffuse pigmentation.

CASE 6 (Fig. 2. See plate at end of paper). J. H., æt. twelve years. "Irido-cyclitis traumatica—phthisis." Enucleation on *June* 2, 1883, by Dr. H. Knapp.

Anatomical Examination: There is a penetrating wound of the cornea, near the sclero-corneal margin, which involves the lens and the vitreous. The corneal wound is filled with spindle cells having an antero-posterior direction. Mingled with them are numerous round cells, scattered and in clusters. This tissue is somewhat vascularized. From the posterior surface of the cornea, the connective-tissue continues *through the lens* into the vitreous; a portion of the iris is loosely attached to it; the round and spindle cells constituting it are very numerous and closely arranged; as the band passes between the two segments of the lens, we find some lens capsule and broken ends of lens fibres involved in it. The whole anterior portion of the vitreous is converted into a mass of fibrous tissue in the shape of bands, which pass in different directions, and which have produced a detachment of the retina, the posterior portion of the ciliary body, and the anterior portion of the choroid. Lymphoid cells are scattered throughout this mass of tissue, which, as usual, is in its greater part made up of spindle cells. It is permeated by numerous blood-vessels. Just behind the lens there is a vesicle, distinctly encapsulated, at least posteriorly; its contents consist of numerous round cells, blood, and broken-down matter; it may contain a foreign body, although none was found.[1] There is a marked cellular infiltra-

[1] Only one half of the eyeball was cut, the other being mounted in gelatine after the method of Priestley Smith, by Dr. W. A. Holden (Fig. 2).

tion, as well as some vascularization of the cornea. The sclerotic is likewise infiltrated at the point where the detachment of the choroid commences. One half of the iris is folded and attached to the fibrous band. The whole uveal tract is densely infiltrated. The retina is totally detached and is lost in the mass of connective tissue filling the vitreous. The lens is broken up.

CASE 7.—J. S., æt. sixteen years. "Irido-cyclitis traumatica—foreign body (?)," right eye.

History: February 15, 1882, patient brought to Dr. R. O. Born's office; foreign body in right eye. Eye seemed to improve for several days;—T., but not tender to the touch; pupil wide. Rest; atropine; bandage. *February 19th.*—Considerable pain during the night; eye very much injected, but no tenderness on pressure; V = 0. *February 20th.*—Injection less; no pain. Towards night severe pain; six leeches to temple, after which pain subsided and patient fell asleep. *February 22d.*—No pain for two days; injection somewhat less; T. slightly decreased; no pain on pressure; some perception of light has returned. *March 9th.*—Enucleation by Dr. R. O. Born.

Anatomical Examination: There is a wound through the posterior portion of the ciliary body, behind the ciliary muscle. It is filled with very irregularly arranged new-formed connective tissue, in which spindle cells greatly predominate, their long axes being mostly at right angles to the lamellæ of the sclerotic. The connective tissue passes through the breaks in the sclerotic and ciliary body into the vitreous, where it expands into a large mass of newly organized tissue. We find evidence of the traction exerted by this new tissue posteriorly in a detachment of the anterior portion of the retina, anteriorly in a backward inclination of the cells of the pars ciliaris and of the processes supporting them. Internal to this new connective tissue, there is a large extravasation of blood. The cornea is moderately infiltrated, especially around the region of Schlemm's canal; the latter is filled with blood. The sclerotic is infiltrated with round cells clear back to the optic nerve entrance. Here and there we find some infiltration of the sheaths of the ciliary nerves as they pass through it. The iris only shows a more or less pronounced cellular infiltration, most marked at its angle. The posterior portion of the ciliary body, which was involved in the wound, is lost in the fibrous tissue filling it, there being besides some connective-tissue proliferation in the substance of the ciliary body itself. On the

opposite side it is abundantly infiltrated with round cells. The choroid is likewise profoundly infiltrated, especially near the wound and near the optic-nerve entrance. The anterior detached portion of the retina and the nerve-fibre layer near the optic-nerve entrance are permeated with lymphoid cells.

The optic nerve proper is also pronouncedly implicated. Round cells are found in the intervaginal space—when there is some proliferation of the endothelium. The lens is normal.

CASE 8 (Fig. 3, on plate, end of paper).—E. B., æt. thirteen. "Phthisis bulbi," sympathetic ophthalmia (R).

History: L E injured many years before and treated at this Institute—warning being given at the time of discharge of the possible danger of sympathetic ophthalmia. Not seen again until October, 1883. Enucleation on *October* 27, 1883, by Dr. H. Knapp.

Anatomical Examination: The eyeball is typically phthisical, almost every structure being invaded by a new growth of connective tissue. The cornea is completely vascularized. A broad band of connective tissue springs from its internal surface at the sclero-corneal margin, passes along the anterior surface of iris, across the pupil to a corresponding point on the other side; it is made up of spindle cells and contains numerous blood-vessels. The iris is completely atrophic, only a remainder of the uveal layer being recognizable; the remainder is lost in the mass of connective tissue filling up the anterior chamber. The ciliary body shows a large interstitial growth of connective tissue with atrophy of the ciliary muscle. The pigment layer is greatly hypertrophied and the shape of the processes much altered by the traction of the cyclitic bands which fill up the whole anterior portion of the vitreous. These are very dense and contain numerous blood-vessels, as well as the pigmented or partially pigmented tubules, which, springing from the uveal layer, go by the name of "tubular excrescences of the ciliary body" (Fig. 3). The choroid is also atrophic.

In the optic nerve we find proliferation of the interstitial connective tissue with atrophy of the nervous element. The lens is cataractous.

CASE 9.—R. R., æt. forty-five years. "Ruptured wound of the ciliary region" (R).

History: The patient came to the Dispensary on *November* 3, 1883. He had been struck by a chair whilst trying to separate

two combatants. There was a curved wound about 1″ long, along the zygomatic process, which was stitched up. The globe was ruptured in the ciliary region, the whole iris apparently lying in the wound—the whole anterior portion of the globe was filled with blood—eye bandaged and patient put to bed. The blood absorbed slowly and the prolapse was incised on *November* 10*th.* Enucleation on *November* 17*th* by Dr. H. Knapp.

Anatomical Examination: There is a wound in the ciliary region through which the lens has escaped in its entirety. The gap is filled by the ciliary body which prolapses through it and by some extravasated blood. The iris is gone. The ciliary body is markedly infiltrated with round cells; opposite the wound, it is detached from the sclerotic posteriorly by the hemorrhage between them. The choroid is also almost totally detached by the large extravasations of blood into the supra-choroideal space; being at the same time infiltrated with round cells and blood. The retina is totally detached and folded up—it is drawn towards the wound. There is a moderate infiltration of the optic nerve and a large extravasation of blood into its sheath. Near the wound the ciliary nerves are infiltrated with round cells. The vitreous is filled with blood—a large portion having been evidently lost.

CASE 10.—G. F., æt. fifteen years. "Corpus alienum in oculo" (L).

History: May 19, 1883. The injury being recent, an opening was made into the sclerotic 4–5 *mm* behind the wound, where the vitreous seemed most opaque; an electro-magnet introduced, but failed to bring out chip of iron; eyeball then enucleated by Dr. H. Knapp.

Anatomical Examination: There are only slight changes and limited to the uveal tract. The iris is moderately infiltrated, at one point being united to the anterior lens capsule. There is a cellular deposit on the ciliary processes around the place where the foreign body was lodged—the ciliary body itself is unaltered. The anterior portion of the choroid is infiltrated with lymphoid cells. The optic and ciliary nerves are normal.

CASE 11.—M. R. "Irido-cyclitis traumatica" (L).

History: July 21, 1883. Eye struck with a beer bottle. *September* 5*th*, enucleation by Dr. H. Knapp.

Anatomical Examination: There are two wounds—one in the cornea and another more internally in the sclerotic, behind the

ciliary body. The iris and lens capsule prolapse through the corneal wound, the greater part of the lens having escaped. The gap in the cornea is filled, besides, with a densely cellular mass, in which round cells greatly predominate. This cellular tissue is directly continuous with some tensely infiltrated newly organized tissue, which fills the whole ciliary region, and which is likewise continuous with that filling the gap in the sclerotic. This mass of new tissue also fills the anterior and posterior chambers, lining both surfaces of the half of the iris not involved in the wound. It contains in its interior the little that is left of the lens. It is partly vascularized.

The cornea in the neighborhood of the wound is very densely infiltrated and filled with blood-vessels of new formation, which are surrounded by numberless round cells. The scleral wound is filled with connective tissue, having a direction perpendicular to the lamellæ of the sclerotic. The cut ends of the retina and choroid posteriorly and of the ciliary body anteriorly are lost in this tissue. The ciliary nerves near this scar are infiltrated with lymphoid cells. Apart from the cellular deposit on both its surfaces, the iris shows a most pronounced infiltration with round cells. Opposite the scleral wound the posterior extremity of the ciliary body is detached from the sclerotic by the contraction of the mass of connective tissue in the ciliary region—the cells of the pars ciliaris show the usual elongation and forward inclination. There is a pronounced infiltration of the ciliary body (on both sides); as well as of the suprachoroideal space, with round cells. An abundant deposit is on the surface of the ciliary processes. The anterior portion of the choroid, opposite the scleral wound, is, like the adjacent ciliary body, detached from the sclerotic. This portion of the choroid shows some cellular infiltration; elsewhere its structure is not much altered. The whole anterior portion of the retina is detached and degenerated; posteriorly it is in situ and only shows a moderate cellular deposit on its surface.

The optic nerve is moderately infiltrated.

Case 12.—W. K., æt. twelve years. "Perforating wound in the ciliary region" (L).

History: Oct. 3, 1890, patient brought to the Dispensary; he had been hit in the eye with a stone five days before. Condition: L E, wound in the ciliary region; iris congested, a portion incarcerated in the wound; pupil distorted, details of fundus not

recognizable, V = $\frac{5}{200}$. No pain. *Oct. 6th*, fundus dimly visible, disk veiled but less than before, V = $\frac{10}{200}$, inflammation diminished. *Oct. 31st*, V = $\frac{3}{200}$. Tn, fundus hazy, blood-vessels seen, disk not found (eye too unsteady). *Nov. 7th*, T1, indrawn scar in ciliary region (below and outwards), V = $\frac{3}{200}$. Other eye healthy in sight, iris and fundus. Enucleation, *Nov. 8th*, by Dr. H. Knapp.

Bacteriological Examination: According to the methods described above, three gelatine and one agar tubes were inoculated from the intervaginal space of the optic nerve ; and five gelatine and one agar tubes from the interior of the vitreous. The four cultures from the intervaginal space proved negative. Of those from the interior of the eye, the agar and one gelatine tube proved negative, four gelatine tubes positive. Of the latter, in two only, the staphylococcus pyogenes aureus was isolated, in two, the staphylococcus pyogenes aureus and a non-pathogenic bacillus.

Anatomical Examination: There is a wound in the ciliary region in which the iris is incarcerated. The scar is, as usual, made up of more or less irregularly arranged connective tissue, which is very much infiltrated. The iris tissue in the wound is one mass of round cells. The cornea in the neighborhood of the wound and at the sclero-corneal junction shows the usual cellular infiltration. The anterior portion of the uveal tract—iris, ciliary body, and choroid—are markedly infiltrated ; the infiltration is not marked in the iris and ciliary body. There is a slight cellular deposit on the surface of the ciliary processes. The optic nerve is moderately infiltrated with round cells, which occupy the lymph channels between the nerve fibres, as well as the intervaginal space. There is some proliferation of the pial endothelium.

Case 13. (Fig 4. end of paper.)—L. W., æt. nineteen years. " Phthisis bulbi " (R).

History: Patient came to Dispensary on *Nov.* 18, 1890. He had received a wound in the upper portion of the ciliary region, on *July 20th* of the same year, in an explosion of a gun-cartridge. There was no pain in the healing. The eye had been painful for three or four days. Condition : Indrawn scar in the ciliary region, eyeball shrinking,—T3, eye sensitive on pressure, V = 0. Other eye (L), V = $\frac{20}{20}$. *Nov. 22d*, edges of scar infiltrated, eyeball red and irritable. Enucleation by Dr. H. Knapp.

Bacteriological Examination : A plate culture and an Esmarch tube were inoculated from the intervaginal space ; and a plate culture from the interior of the eyeball. All proved negative. Over thirty sections, stained after Gram, Loeffler, and Weigert, were carefully examined and no trace of any micro-organisms were found. No tests were made as to the presence of copper in the different tissues.

Anatomical Examination : The eyeball is phthisical ; there is a scar at the sclero-corneal margin. Embedded in the centre of the eyeball is a gun-cap which lies under a portion of raised choroid ; where it protrudes into the vitreous it is surrounded by a mass of exudation (See Fig. 4 from a Priestley Smith gelatine preparation, prepared by Dr. W. A. Holden).

The scar occupies a good portion of the cornea ; and is made up of a mass of very closely arranged round cells, and some spindle shaped. Near the posterior surface of the cornea, we find the torn ends of Descemet's membrane involved in this tissue. The cornea is markedly infiltrated in its whole extent.

A large portion of the iris has been carried in with the gun-cap and its structural changes could only be studied in a few sections ; in these it showed a pronounced cellular infiltration, the round cells being at places accumulated into clusters. There is an organized deposit on its anterior surface.

The ciliary body only remains attached to the sclerotic by its anterior extremity, its posterior $\frac{4}{5}$ with the greater portion of the choroid being detached from the sclerotic, being drawn inwards by the contraction of the connective tissue in the vitreous. The supra-choroideal space is occupied by a reticular tissue, containing in its meshes numerous round cells, diffuse pigment, and extravasated blood. The ciliary body itself is densely infiltrated. The choroid in its whole extent is infiltrated with round cells. Both its surfaces are at different places covered with a hemorrhagic exudation. The retina is totally detached, being mostly converted into a mass of more or less infiltrated connective tissue.

The optic nerve is atrophic and shows a very slight degree of round-cell infiltration, which soon disappears as we proceed centripetally.

The whole ciliary region is occupied by newly organized connective tissue, which is most densely infiltrated, the round cells being accumulated here and there into foci. Numerous red blood corpuscles also are to be found. In the midst of this

mass of tissue we find the greatly disorganized remnants of the lens.

CASE 14.—E. B., æt. thirty-one years. "Cyclitis after injury" (R).

History: Nov. 22, 1890, patient came to Dispensary; the eye had been injured two weeks before, the patient running his eye into a wire fence. L E myopiai with -3.5 D $= \frac{20}{60}$; od. pale; F normal; color perception good; no congestion; no irritation. R E always weak. Enucleation by Dr. H. Knapp.

Bacteriological Examination: Immediately after the enucleation one Esmarch tube was planted from the intervaginal space, and two from the interior of the eyeball. The former proved negative, the two latter positive, both yielding pure cultures of the staphylococcus pyogenes aureus.

Anatomical Examination: There is a wound at the sclerocorneal margin, through which the iris prolapses in its entirety, and through which the lens has totally escaped. The anterior chamber and anterior portion of the vitreous is filled with blood, mixed with an abundant fibrinous exudate. The remaining changes are limited to the anterior portion of the globe; the iris, ciliary body, and anterior portions of the choroid and retina being markedly infiltrated. There is a fibrinous deposit on the surface of the ciliary processes and anterior portion of the choroid.

CASE 15.—J. D. "Panophthalmitis incipiens."

History: Patient received a perforating wound in the ciliary region in the early part of November, 1890. Healing without pain. Patient states that he could see with the injured eye till November 21st, when the eye became irritable, tender, and painful. V = 0. Prolapse of iris. Enucleation on November 26th by Dr. H. Knapp.

Bacteriological Examination: Cover-glass preparations, prepared directly from the intervaginal space and the interior of the vitreous, showed nothing.

Puncture cultures, made both from the intervaginal space and from the interior of the eyeball, yielded positive results, and a peculiar bacillus was isolated. Its characters do not correspond with those of any of the microbes found described in the text, nor with those of Haab's panophthalmitis bacillus; hence I will describe them somewhat in detail. The bacillus was about 7 μ long, being rather slender. In cover-glass preparations, made from the growths in gelatine, they were arranged in zoogleic

masses. The bacillus was cultivated in gelatine, agar, and potatoes. In *gelatine* it developed with the utmost readiness, liquefying it with extreme rapidity almost as soon as it made its appearance; when planted in second and third generations the gelatine would be totally liquid in twenty-four hours. In a partially anaërobic culture (made by pouring a layer of sterilized oil on the surface of the gelatine after making the puncture), the liquefaction took place much slower, not commencing for months, the growth being somewhat peculiar; from the central stem four peculiar processes were given out, which were arranged crosswise; gradually, however, the growth was totally liquefied. In *agar* the bacillus thrived both in its interior and on its surface; in the latter situation it had a peculiar white, waxy appearance. On *potatoes* the growth at first was yellowish, but ultimately acquired a chocolate-brown color, resembling somewhat that of the glanders bacillus.

In order to prove the pathogenicity of this bacillus, an inoculation was made from a pure culture into the healthy vitreous of a rabbit, the usual precautions being observed; the eye went to ruin as the result of the purulent panophthalmitis set up.

From twenty-five to thirty sections were examined, after staining according to Gram, Loeffler, and Weigert, and in only two (stained after the latter's method) could two or three very faintly stained bacilli be demonstrated in the vitreous.

Anatomical Examination: There is a wound in the ciliary region through which both iris and ciliary body largely prolapse. The wound gap, where not occupied by those portions of the uveal tract and the surface of the prolapse itself, are one mass of pus cells, directly continuous with those filling up the anterior and posterior chambers and the vitreous. All the structures of the eye are intensely infiltrated with pus cells. Of special note is the infiltration of the sclerotic, of the sheaths of the ciliary nerves passing through it, of the loose tissue on the external surface of the sclerotic, around the optic-nerve entrance, and of the optic nerve itself (its sheath being more or less free).

CASE 16.—E. S., æt. seven years. "Irido-cyclitis traumatica," foreign body (?), (R).

History: December 5, 1890, patient brought to Dr. Knapp's office. About three weeks before a spark had flown into his right eye whilst playing on the street; since then the eye had been inflamed and red; it was noticed five days before admission that he could not see out of the eye. Condition: Irido-cyclitis with a scar

at the sclero-corneal margin. Enucleation the same day at the Institute by Dr. H. Knapp.

Bacteriological Examination : Cover-glass preparations from the intervaginal space and from the interior of the vitreous were negative. Two Esmarch tubes were inoculated from the intervaginal space and two others from the interior of the vitreous One of each proved positive ; in that from the intervaginal space the staphylococcus pyogenes aureus was isolated ; in that from the interior of the eye, a non-pathogenic coccus. The search for bacteria in the tissues proved valueless on account of the overgrowth of the specimen by a budding fungus.

Anatomical Examination : The cornea and sclera are normal. The iris is moderately infiltrated ; there is a total adhesion between its posterior surface and the anterior lens capsule, with a consequent obliteration of the posterior chamber, and a retraction of the iris angle by the cyclitic membranes in the vitreous. The posterior portion of the ciliary body is detached from the sclerotic. The anterior portion is moderately, and the posterior markedly, infiltrated with round cells. The whole ciliary region of the vitreous is occupied by new-formed connective tissue, which drags on the neighboring structures. The anterior portion of the choroid is detached from the sclerotic with the ciliary body and is markedly infiltrated. The retina is totally detached and completely degenerated. There is a dense cellular deposit on its internal surface. An abundant accumulation of round cells is in the cup of the optic nerve. There is a slight degree of infiltration around the walls of the central blood-vessels. The nervous elements are greatly degenerated, more so than one would expect at such an early date.

Case 17 (Fig. 5).—Mrs. R. "Phthisis after injury" (R).

History : Consulted Dr. Knapp at his office on December 2, 1890. R E had been injured seven years before. Patient could see for two years, and the eye was of its natural size till six weeks ago, when it inflamed. Condition : scar in the upper part of the cornea, cornea small, iris bulging, eyeball very painful ; S lost. *December 22d.*—Enucleation by Dr. H. Knapp at the Institute ; optic-nerve shrunken, atrophic.

Bacteriological Examination : Two cover-glass preparations and two Esmarch tubes were made from the intervaginal space and two others from the interior of the eye—all proved negative.

Anatomical Examination: The eye is typically phthisical. There is an old scar in the upper part of the cornea, a loss of continuity in the adjacent iris, and some disorganization of the upper part of the lens. The sclero-corneal junction is drawn inwards, giving evidence of the traction bearing on it. The iris is completely atrophic, and adherent to the posterior surface of the cornea, there being only a small free space between them below which is filled with an amorphous material. Its posterior surface is totally adherent to the lens. The posterior four fifths of the ciliary body and the choroid are completely detached from the sclerotic by the contraction of the cyclitic bands. There is some cellular infiltration of the ciliary body proper. The supra-choroideal space is filled with coagulated matter and extravasated blood-

FIG. 5.

corpuscles. The retina is detached in a funnel shape and shows the usual degenerative changes. The optic nerve is atrophic. The whole ciliary region of the vitreous is filled with organized connective tissue, which, by its contraction, brings about the mechanical changes just described.

CASE 18.—R. H. "Panophthalmitis incipiens." Enucleation on January 19, 1891, by Dr. H. Knapp.

Bacteriological Examination: Cover-glass specimens from the interior of the eye and four Esmarch tubes inoculated from the intervaginal space and interior of the eye proved negative.

Anatomical Examination: There is a perforating wound through the cornea and lens, the defect in both being filled by densely infiltrated and escaping vitreous. The wound in the cornea occu-

pies more or less its centre; no iris prolapses through it. The neighboring cornea shows only a very moderate degree of infiltration. The whole uveal tract is very much swollen and infiltrated with round cells; these changes are more pronounced anteriorly, especially in the iris. Both its surfaces are covered by a thick deposit of a fibrino-purulent character. A similar deposit is found on the surface of the ciliary processes. The retina is infiltrated, there being also a dense cellular deposit on its internal surface. The optic nerve is moderately infiltrated. The lens is more or less disorganized, and is partially divided into two segments by the escaping vitreous; the lens fibres are swollen, and between them a moderate number of lymphoid cells are to be found. The vitreous, especially in its anterior portion, is one mass of pus cells.

CASE 19.—A. B. "Perforating wound of the cornea" (L). Enucleation on January 21, 1891, by Dr. H. Knapp.

Bacteriological Examination: Two Esmarch tubes were inoculated from the intervaginal space, and two from the interior of the eye—all proved negative.

Anatomical Examination: There is an open wound in the cornea, extending across it from one ciliary rigion to the other, through which the lens has escaped. In the wound gap lie iris, lens capsule, and vitreous. The injury must have been very recent, for there are as yet no inflammatory changes, except in the prolapsed iris, which shows a more or less marked cellular infiltration. The other structures are normal.

CASE 20—D. T. "Purulent cyclitis; foreign body" (R).

History: December 12, 1890, whilst hammering a piece of steel something struck the patient's right eye. Lachrymation and pain for several days. *December 22d*, great swelling and discharge, which gradually subsided. *January 19th*, patient brought by Dr. A. Duane to Dr. Knapp's office. Condition: ciliary injection; iris greenish-brown; posterior synechiæ—T½; no tenderness on pressure. Dr. Duane had at first noticed a wound in the ciliary region (lower portion) surrounded by a gray substance; vitreous hazy; disk normal, though veiled. *January 23d*, enucleation at Institute.

Bacteriological Examination: Negative.

Anatomical Examination: A chip of iron irregular in shape, was found imbedded in the ciliary region, surrounded by a mass of exudation. There is a perforating wound through the sclerotic,

choroid, and retina just posterior to the ciliary body; the wound is filled by densely infiltrated vitreous. The iris is intensely swollen and very much infiltrated with round cells; there is a dense fibrino-purulent deposit on both its surfaces. The ciliary body is likewise very much infiltrated, there being a deposit of a similar nature on the surface of the ciliary processes. The choroid is markedly infiltrated; the supra-choroideal space is at places occupied by a cellulo-fibrinous exudation. The retina is detached and deeply infiltrated. The optic nerve shows no marked changes The lens is normal. The whole anterior portion of the vitreous is most densely infiltrated with round cells.

CASE 21.—C. M. "Cyclitis after injury" (R).

History: May 27, 1891, whilst working on a piece of iron a chip entered the patient's right eye. No immediate inflammatory reaction followed, S being preserved till June 1st. *June 6th*, came to Dispensary. Condition: wound in the ciliary region (below and outwards); iris dull and swollen; anterior chamber dull, hypopyon; V = $\frac{1}{20}$. Enucleation by Dr. R. O. Born.

Bacteriological Investigation: Negative.

Anatomical Examination: There is a wound just posterior to the ciliary body, with the usual inflammatory changes in the neighborhood. The cornea and the sclerotic (except at the wound) are normal. The iris is swollen and somewhat infiltrated. The ciliary body is moderately infiltrated and there is an abundant cellular deposit on the surface of the ciliary processes near the wound. The choroid is abundantly infiltrated with round cells, which mostly occupy its internal layers. Half-way between the optic nerve and the wound there is a large, partly cellular, partly hemorrhagic exudate, between the sclerotic and choroid, which completely raises up the latter. The retina is densely infiltrated; there is an abundant cellular deposit on its internal surface. Optic nerve and lens normal. The anterior chamber is filled with a fibrino-purulent exudate with round cells and blood.

CASE 22.—A. M., æt. nine years. "Cyclitis after injury" (L).

History: May 19, 1891, patient brought to Dispensary; four days before he had been cut in the eye by a piece of tin thrown by another boy. Condition: Perforating wound at sclero-corneal margin (temporal side); iris impacted, some mucus hanging from it: blood in anterior chamber; V = $\frac{1}{20}$; comparatively free from pain and discomfort till the beginning of June, when the eye became inflamed. *June 10th*, patient returned, presenting a typi-

cal picture of irido-cyclitis; intense ciliary injection; iris dull; purulent mass, filling the pupillary area; eyeball very tender; other eye still normal; enucleation urgently advised. *June 11th*, enucleation by Dr. R. O. Born.

Bacteriological Examination: Two Esmarch tubes inoculated from the intervaginal space; two from the interior of the vitreous. The former proved negative; from one of the latter the staphylococcus pyogenes aureus was isolated.

Anatomical Examination: There is a perforating wound at the sclero-corneal margin, in which the iris is incarcerated; the neighboring cornea and sclerotic show a most pronounced cellular infiltration. The iris, both in the wound and elsewhere, is densely infiltrated with round cells; it is applied to the posterior surface of the cornea; the iris angle is retracted. The posterior four-fifths of the ciliary body and anterior portion of the choroid are detached from the sclerotic by an abundant exudation into the supra-choroideal space, aided by the contraction of the ciliary bands and membranes; they are both intensely infiltrated, especially the choroid near the optic-nerve entrance. The retina is totally detached, and participates in the general cellular infiltration. The optic nerve is markedly infiltrated with round cells; there is only a slight infiltration of its sheath. The ciliary nerves, in their passage through the sclerotic, show here and there a slight infiltration of their sheaths. The lens is displaced forward. The anterior chamber is obliterated by the pushing forward of the lens and iris. The posterior chamber and zonula are filled with a partially organized cellular exudation. The vitreous is most abundantly infiltrated—there being in its anterior portion some organization into bands, which drag on the neighboring structures. There is also an abundant exudation between the retina and the choroid.

CASE 23 (Fig 6, on plate at end of paper).—B. M., æt. thirty-one years. "Cyclitis after injury" (L).

History: June 20, 1891; patient received a wound in the eye with a prong. Dr. Fenfield was called in, and he sutured the wound; the sutures were removed four days later. Hitherto there had been no signal discomfort; the eye then inflamed, S being gradually lost. *June 27th*, came to Dispensary. Condition: perforating wound about $\frac{1}{3}''$ long in the ciliary region (below), running in an antero-posterior direction; intense circumcorneal injection; some chemosis; iris dull, sluggish; withstands atropine; anterior chamber a little hazy; by oblique illu-

mination white flocculent masses could be seen floating in the vitreous; S = $\frac{1}{\infty}$; eyeball very painful; a good deal of lachrymation. *July 1st*, enucleation by Dr. J. H. Shorter.

Bacteriological Examination: One agar and two gelatine Esmarchs; each was planted from both the optic-nerve sheath and from the interior of the eye. The former proved negative; from one of the gelatine tubes from the latter a pure culture of the staphylococcus pyogenes aureus was obtained.

Anatomical Examination: There is a perforation posterior to the ciliary body, passing through the sclerotic, choroid, and retina into the vitreous. In the wound gap there is an incarceration of the most anterior portion of the choroid and of the posterior extremity of the ciliary body. These, as well as the neighboring sclerotic are richly infiltrated with round cells; the ciliary nerves passing through this region show, here and there, some lymphoid exudation into their sheaths. The whole uveal tract is markedly infiltrated, and in the substance of the choroid near the optic-nerve entrance there are several hemorrhagic extravasations. The choroid is partially separated from the sclerotic by an abundant cellular exudation into the supra-choroideal space. The retina is enormously infiltrated; it is, at places, partially detached from the choroid by an exudation into the subretinal space; this has here and there partially organized, reuniting both structures in a mass of connective tissue. The optic nerve is moderately infiltrated. The lens is normal. The anterior and posterior chambers are filled by a fibrous exudate, in the meshes of which we find numerous red and white blood corpuscles. The zonula and lower portion of the posterior chamber are occupied by an abundant accumulation of lymphoid cells. There is a partially organized exudation on the surface of the ciliary processes. The internal surface of the retina is likewise the seat of a dense cellular deposit. The vitreous is profoundly altered; it is split into numerous fibrillæ, especially towards its periphery (Fig. 6); between them round cells are found in moderate numbers, excepting in one or two places, where they are accumulated into foci. We also find the formation of open spaces in the interior of the vitreous.[1]

CASE 24.—J. R., æt. twenty-five years. "Phthisis after injury" (R).

History: October 30, 1891: eye injured nine years before in an explosion of a gun cartridge. Since then repeated attacks of

[1] See *Beiträge zur Anatomie des Auges.* Emil Berger, Wiesbaden, 1887.

inflammation. Condition: ciliary injection; hypopyon; tenderness on pressure; S = o. Enucleation by Dr. H. Knapp.

Bacteriological Examination: Two Esmarch tubes each were inoculated from the intervaginal space, from the vitreous, and from the exudation in the anterior chamber. All proved negative.

Anatomical Examination: No evidence of a scar can be made out. The cornea is partially vascularized. The iris and ciliary body show a relative increase of their connective-tissue elements; the ciliary muscle is very much atrophied; they are both richly infiltrated with round cells. The pupillary margin is adherent to the anterior lens capsule; the iris angle obliterated. The choroid also is atrophic, with a relative increase in its connective tissue elements. The retina is totally detached, and shows the usual degenerative changes. The optic nerve is atrophic. The lens is cretaceous. In the vitreous there is some formation of cyclitic membranes.

CASE 25.—A. G., æt. twelve years. "Panophthalmitis incipiens" (R).

History: November 1, 1891: patient brought to Dr. Knapp's office; eighteen hours before, the right eye had been struck by a piece of glass. Condition: vulnus corneæ perforans suppurativum; corneal wound infiltrated; no chemosis; pain less than the day before; S = o. *Nov. 2d,* swelling of conjunctiva; slight protrusion of eyeball. Other eye (L), V = $\frac{20}{20}$. Sent to Institute, where the eye was enucleated the same afternoon.

Bacteriological Examination: Two Esmarch tubes each were inoculated from the intervaginal space, from the vitreous, and from the exudation in the anterior chamber; all proved negative. Cover-glass preparations from both the exudation in the vitreous and that in the anterior chamber showed numberless cocci.

Anatomical Examination: There is a perforating wound of the cornea with prolapse of iris; the lens has escaped. All the structures of the eyeball are most densely infiltrated with pus cells, showing an intense purulent panophthalmitis. Especially noticeable is the infiltration of the ciliary muscle and of the suprachoroideal space. An enormous cellular deposit on both surfaces of the iris and on the ciliary processes. The optic nerve is moderately infiltrated around the central blood-vessels. The vitreous is one mass of pus cells.

CASE 26.—P. M., æt. thirty-seven years. "Purulent cyclitis; foreign body" (R).

History: November 3, 1891, three weeks before, patient injured by a piece of iron which entered his right eye. Since then the eye has been inflamed. Condition: there is a wound running transversely across the cornea; traumatic cataract; purulent cyclitis. Enucleation by Dr. H. Knapp.

Bacteriological Examination: Two Esmarch tubes were inoculated from the interior of the vitreous. Result, negative.

Anatomical Examination—Macroscopical Appearance: After the inoculation of the Esmarchs the eyeball was opened by an equatorial section. The ciliary region was filled with creamy pus; the retina around the optic-nerve entrance was swollen and infiltrated. A piece of iron, 2''' in length was found at the bottom of the eye, surrounded by pus. No microscopical examination was made.

CASE 27.—A. B., æt. ten years. "Cyclitis after injury" (R).

History: November 13, 1891, injury four months before; no inflammation; S lost; traumatic cataract; total detachment of the retina; eyeball shrinking. Enucleation by Dr. H. Knapp.

Bacteriological Examination: Two Esmarch tubes each were inoculated from the intervaginal space and from the interior of the vitreous. Result, negative.

CASE 28.—W. M., æt. eighteen years. "Panophthalmitis incipiens" (L).

History: December 8, 1891, eye injured by a piece of steel, which flew into the patient's eye whilst he was walking through the workshops at Cornell University. A local physician immediately removed some protruding iris. *Dec.* 10*th*, seen by Dr. Knapp at his office. Condition: traumatic cataract; chemosis; exophthalmos; cornea and iris clear. Sent to Institute. *Dec.* 11*th*, same condition; besides, anterior chamber full of blood, masking iris; yellowish reflex from the lens. Enucleation by Dr. H. Knapp. Orbital tissues much inflamed; cut end of optic nerve congested.

Bacteriological Examination: Two Esmarch tubes each were inoculated from the intervaginal space and from the interior of the eyeball; all proved negative. In cover-glass preparations from the vitreous, however, groups of cocci were demonstrated.

Anatomical Examination—Macroscopical Appearance: The eyeball was opened by an equatorial section (immediately after making the cultures). The vitreous was full of flakes of pus and blood; the pus was thicker toward the posterior pole of

the eye, where a wedge-shaped piece of iron, $\frac{1}{2}'' \times \frac{1}{8}''$, was found imbedded in the sclerotic

CASE 29.—O. I., æt. twelve years. "Panophthalmitis incipiens" (R).

History: March 9, 1892, patient had been shot in the eye with bird-shot a week before. Condition: a wound in the upper portion of the ciliary region; iris prolapsed; wound suppurating; picture of incipient panophthalmitis. Enucleation by Dr. H. Knapp.

Bacteriological Examination: Two puncture cultures made from the exudation in the vitreous. Negative result.

Anatomical Examination—Macroscopical Appearance: The eye was opened by an equatorial section. The vitreous was full of blood; along its upper portion there was a streak of exudation marking the track of the foreign body. This was not found but was evidently imbedded in a mass of exudation at the posterior pole (this was not disturbed, so as not to alter the relations of the different structures. (No microscopical examination was made.)

CASE 30.—F. B., æt. thirty-six years. "Purulent cyclitis" (L).

History: Dec. 12, 1890, patient struck in the eye by some portion of a harrow which he was repairing. Seen by Dr. Knapp half an hour later. Condition: irregular wound in the cornea; in the anterior chamber, at the periphery of the iris, there was a black foreign body, 1 *mm* in length. Sent to Institute and put to bed. *Dec.* 23*d*, pain all night; at 2 P.M., circumcorneal injection; foreign body at lower edge of the iris partially covered by pus; fundus dull. At 5 P.M., iris distinctly tremulous and sunken back; fundus still to be illuminated, but very dull; Tn; F good; $V = \frac{4}{200}$. Operation by Dr. H. Knapp. Section of cornea with a lance-shaped knife as for iridectomy; foreign body removed from the iris with a blunt, curved hook; iris replaced; prolapse of vitreous, cut off. No reaction followed. *Jan* 11*th*, Tn; F normal; $V = \frac{5}{200}$. Discharged. Eye remained free from inflammation but a cataract developed. *April* 25, 1892, after much hesitation Dr. Knapp finally decided to attempt the extraction of the lens. The extraction was difficult and accompanied by considerable loss of healthy vitreous, the lens being finally delivered by external manipulation, after the introduction of instruments had proved ineffectual. No imme-

diate reaction. On the fifth or sixth day, however, a slow-going form of inflammation broke out, which after an insidious course of five to six weeks, with temporary improvements and exacerbations, gradually developed into a typical case of irido-cyclitis purulenta. *June 2d*, enucleation by Dr. H. Knapp.

Bacteriological Examination: One gelatine tube inoculated from the intervaginal space, two from the exudation in ciliary region. The former proved negative; in one of the latter developed a pure culture of the staphylococcus pyogenes aureus.

Anatomical Examination—Macroscopical Appearance: Eyeball opened by an equatorial section; lower portion of ciliary region occupied by a purulent exudation; posterior portion of globe normal.

Before laying down my pen I beg to express my gratitude to my esteemed teacher, Prof. H. Knapp, for his kindness in allowing me the free use of his laboratory and in supplying me with the greater part of the material on which these investigations were conducted. I am still further indebted to him for the invaluable advice and sound criticism which he was always ready to bestow on my work. My thanks are also due to my colleagues at the N. Y. Ophthalmic and Aural Institute, for the material with which they supplied me,—Drs. Born, D'Oench, Shorter, and especially to Dr. W. A. Holden, for the drawings with which he has illustrated this paper.

SUPPLEMENT.

Since the handing in of the preceding paper, a negative experiment with regard to the infectious origin of a cyclitis in an injured eye, sympathetic ophthalmia having broken out in the other, has been reported in these ARCHIVES (xxi., 3), by Dr. Randolph, of Baltimore. This, together with the negative results previously obtained by himself and other observers, leads him to conclude against the bacteriological origin of the affection, as advocated by Deutschmann. I can find no reason in his paper to alter my conclusions as to the infectious origin of the cyclitis in question. The value of this negative result is somewhat lessened by the following facts: (1) The length of time which had elapsed since the injury

—the eyeball being enucleated two and a half months later, it being very possible that the micro-organisms had already been destroyed by their own products, notwithstanding the fact that the process was still active at the time of the enucleation; (2) the limitation of the bacteriological investigation to the iris and aqueous chambers; (3) the absence of a histological or of a histo-bacteriological examination.

The series of negative results of different observers, quoted by Dr. Randolph, are of undoubted value, but positive results, even if fewer in number, have a much greater importance. In dealing with these, Dr. Randolph only mentions Deutschmann's, ignoring those of Secondi (*Annali di Ottalmologia*, xx., 3), and of Schiess-Gemuseus (*Bericht der Augenheilanstalt in Basel*, 1891); he also fails to take into account the experiments of Knapp and Leber, quoted above, on the septic or aseptic condition of wounds and the instruments producing them, and of foreign bodies lodged in the interior of eyeballs, in relation to their liability to produce inflammation and sympathetic ophthalmia.

With regard to the purely theoretical arguments advanced by Dr. Randolph against the staphylococcus pyogenes aureus in particular, they fall to the ground before the positive results quoted, as well as those detailed in this paper.



Fig. 4.

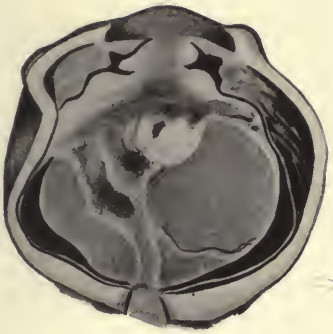

Fig. 2.

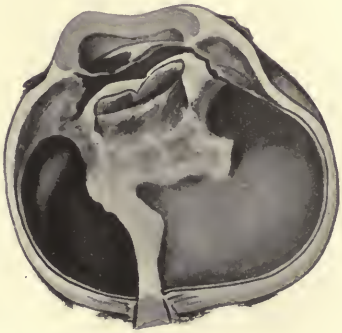

Fig. 3.



Fig. 6.

Holden, del.

HELIOTYPE PRINTING CO., BOSTON.

EMBOLISM OF ARTERIA CENTRALIS RETINÆ.

By JNO. M. FOSTER,

CLINICAL INSTRUCTOR OPHTHAL. AND OTOL., MED. DEPT. UNIVERSITY OF DENVER.

(*With two figures in the text.*)

THE following is quite an interesting case of embolism of the arteria centralis retinæ which occurred in a gentleman 29 years of age who gave a history of inflammatory rheumatism accompanied by endocarditis, which resulted in mitral stenosis and regurgitation.

At the time of the stoppage of the artery the patient was making his toilet, and immediately noticed that he had lost the sight of his left eye. There was no pain or any sensation whatever. The sight was reduced to the bare perception of light; the pupil reacted in sympathy with the right, but when the latter eye was covered, it dilated immediately and remained passive. An ophthalmoscopic examination was made within two hours of the occurrence of the embolism, and presented the picture shown in Fig. 1. Particularly noticeable was the dense grayish-white effusion that marked the macula lutea and optic disk, rendering all details of this portion of the fundus invisible. The arteries were extremely attenuated and almost invisible when they emerged from behind the cloudlike veil. There was no indication of interruption of current or pulsation, but a short distance below the effusion the blood-vessels were again interrupted for a small space by the grayish covering. On the third day following the embolism, the effusion became more pronounced, and whitish striations radiated from the region of the macula in a particularly striking manner. At this time it was found that there was absolutely no perception of light, even the strongest rays thrown into the eye not being recognized.

This increase in the already dense effusion suggested the absorbent treatment that was undertaken, *viz.*, iodide of potash internally and the application of the artificial leech to the left temple every fourth day, with confinement to a darkened room. In ten days clearing commenced at upper and outer edge of disk and continued without change in vision until the thirty-third day, at which time there was a faint but unmistakable perception of light, and the cloud has become so thin that the veins could be distinctly traced to the centre of the disk. The effusion over the macula had assumed a pinkish cast, but no details could be made out. Fig. 2 represents the appearance of the fundus on April 2d,

FIG. 1.

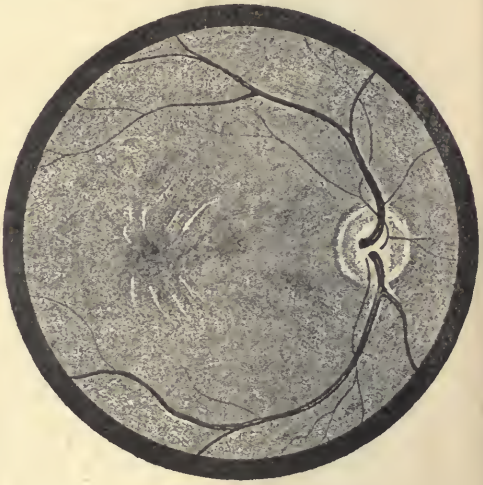

FIG. 2.

the forty-ninth day. Vision improved to differentiation between fingers closed or held apart near the eye. Since this time the sight has not improved.

The points that attract the attention are the rapidity with which the cloud formed, its great opacity and subsequent increase in density, its absorption, and the silvery-like lines and reddish mottling around the macula that remains, and the question with it, as to whether or not the condition was influenced by the treatment.

MICROSCOPIC EXAMINATION OF A CASE OF TYPICAL INFERIOR COLOBOMA OF THE IRIS.

By WARD A. HOLDEN, M.D., New York.

(*With six figures.*)

THE specimen in Müller's fluid was sent to the laboratory of the Ophthalmic and Aural Institute through the kindness of Dr. Geo. F. Carey. It was obtained at the autopsy of E. V., æt. fifteen months, dead of broncho-pneumonia. Besides the fact that an inferior coloboma of the iris was noticed in each eye, there was no record of a clinical examination.

The ball was of regular form and normal size. It was first divided by an equatorial section. There was a narrow coloboma of the iris reaching apparently to the ciliary body, but no other macroscopic abnormalities. The anterior segment was cut with a microtome in sections in and parallel to a plane passing obliquely from below upward through the head of the ciliary body and the centre of the ball, so that transverse sections of the ciliary body and the margins of the coloboma were obtained. The posterior segment was cut partly in frontal sections, partly in sagittal sections through the nerve.

Anatomical Description.—There was no coloboma of the nerve sheath, and the vessels ran in the middle of the nerve, dividing in the centre of the papilla. The retina, pigment epithelium, and choroid showed no cleft In the posterior portion of the ciliary body a cleft was seen in the pigment epithelium and the pars ciliaris retinæ, and this cleft continued along the apex of a ciliary process, being continuous anteriorly with the coloboma of the iris (Figs. 2–6.) The connective-tissue, mesoblastic portion of the ciliary process filling the space, showed no signs of previous in-

flammation. At the ciliary margin of the iris the cleft in the uveal layer was wider but was bridged over by the mesoblastic layer for some distance, when this latter failed also. The zonula was continuous and well developed, showing a considerable number of nuclei. Just at the head of the ciliary body where the cleft was wide, branched cells of the mesoblastic layer were in connection with similar cells among the fibres of the zonula. No trace of the sphincter pupillæ was found in the walls of the coloboma. In the pupil proper the sphincter was well developed, and running from the minor circle, which here only was marked, were nucleated fibres and tracts of spindle cells extending out upon the lens capsule (persistent pupillary membrane). The posterior capsule was normal.

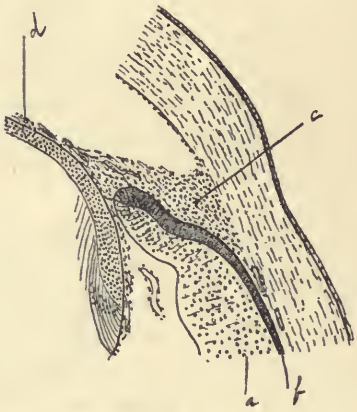

FIG. 1.

BEGINNING OF IRIS DEVELOPMENT IN PIG EMBRYO.

a, retina; *b*, pigment epithelium—together forming epiblastic fold; *c*, mesoblastic layer of iris; *d*, pupillary membrane.

Examining the two epiblastic layers more closely, it is seen that the pigment epithelium is very thin near the cleft. The pars ciliaris retinæ is normal over the ciliary body. In the iris, however, its continuation, the posterior layer of the uveal portion, is unpigmented for some little distance from the margins of the coloboma. The ciliary process in which the cleft lies is larger than the others. The margins of the cleft in most sections are turned outward.[1]

[1] A few elementary statements in regard to development may be admissible here. The primary optic vesicle is an epiblastic layer several cells deep. With the involution of the lens, the anterior and inferior wall of the primary vesicle

In our case the cleft in the secondary optic vesicle has closed normally in the posterior half of the ball, but from near the æquator forward there has been an interruption, possibly due either to the persistence of mesoblastic tissue in the cleft or to an inflammation in the mesoblastic tissue without, which has prevented the junction. No evidences of inflammation, however, can now be found. The cleft in the anterior portion of the vesicle from which the iris develops has been bridged for a short distance by the mesoblastic tissue that pushes out here. This tissue not having the supporting epiblastic layers along which to extend, has ceased to develop. The fact that at the periphery of the coloboma the mesoblastic layer of the iris is continuous with mesoblastic cells beneath it (Fig. 3) shows that the mesoblastic portion of the iris has pushed out here and has united with the vascular sheath of the lens in front of the epiblastic portion as is usual. The epiblastic portion not developing in the cleft, the mesoblastic portion has remained without forming a complete pupillary membrane here, and no remains of pupillary membrane are found in the coloboma, although they appear in the pupil proper.

The ciliary processes are probably produced by an excessive development of the walls of the secondary optic vesicle which throws them into folds, which latter become filled

---

is pushed inward until it lies in contact with the posterior wall, thus forming the secondary optic vesicle, which has a circular opening anteriorly, occupied by the lens, and a cleft below, the margins of which are formed on either side by the fold in the vesicle wall. Through this cleft pushes vascular tissue from the mesoblast without. This vascular tissue forms the vitreous, the fibro-vascular sheath of the lens, and later the suspensory ligament, and the vessels of the retina.

The folded margins of the cleft close from behind forward, each layer becoming continuous, leaving no trace of the junction.

The anterior portion of the secondary vesicle lies in contact with the lens, and as the ball enlarges faster than the lens, the epiblastic fold turns inward, and a layer of mesoblastic tissue covers its anterior surface and becomes continuous with the anterior vascular sheath of the lens, forming the pupillary membrane; the epiblastic fold and mesoblastic covering making up the iris (Fig. 1).

In the posterior portion of the ball the two layers of the secondary vesicle wall, being each several cells deep, differentiate, and the outer (lateral), diminishing to a single layer, becomes pigmented, forming the pigment epithelium, which lines the entire uveal tract. The inner (medial) layer becomes thicker in the posterior portion of the ball, forming the retina. In the ciliary body which develops later it forms the single layer of unpigmented cells called the pars ciliaris retinae. On the posterior surface of the iris it forms a single layer identical with the pars ciliaris, except that it becomes pigmented.

with mesoblastic tissue. The development in an antero-posterior direction produces the iris, that in a transverse direction produces the meridional folds of the ciliary processes.

In our case the apex of the ciliary process is formed by the cleft, the weak point in the epiblastic layers, and this ciliary process is higher than the others, probably for the reasons that the margins of the cleft have been freer to develop than the continuous portion of the wall.

The inferior coloboma of the iris, with which is often associated coloboma of the ciliary body, choroid, and nerve sheath, was for a long time considered simply the result of arrested development. Coloboma in other directions, which is never associated with coloboma of the choroid, was explained in various ways. Recently the process in coloboma not downward has been considered to be the same as that producing total absence of the iris, the coloboma being called atypical, or properly, a partial irideremia.

Attention was again called to this subject when Deutschmann[1] described the eye of a rabbit with coloboma of the choroid, showing the results of severe inflammation which had occurred in the mesoblastic tissue at a time when the retinal cleft was closing, the signs of inflammation being particularly marked at the sclero-corneal margin, causing a coloboma of the iris.

Some of the cases studied since this time have shown evidences of intra-uterine inflammation, some have not. Manz,[2] in an eye with lateral coloboma, found a thin, poorly developed choroid. Rindfleish,[3] in eyes with irideremia, found signs of inflammation and ulceration at the sclero-corneal margin, and he supposed an adhesion between the lens and the cornea to be the cause of the partial non-development of the iris. Plange[4] assumes an obstruction in the vascular sheath of the lens or a partial adhesion between the lens and cornea as the cause of atypical coloboma. Hess[5] has found in several cases of coloboma a fine bundle of connective tis-

---

[1] *Zehender's klin. Monatsbl.*, xix., p. 101.
[2] *Report Seventh Internat. Oph. Congr.*, Heidelberg, 1888.
[3] *Graefe's Archiv*, xxxviii., 1, p. 191.
[4] *Archiv f. Augenheilk.*, xvi., p. 205.
[5] *Zehender's klin. Monatsbl.*, xxx., March; and *Graefe's Archiv*, xxxiv., 3.

FIG. 2.

Post. portion of ciliary process.

FIG. 3.

Ant. portion of ciliary process.

FIG. 4.

Periphery of iris.

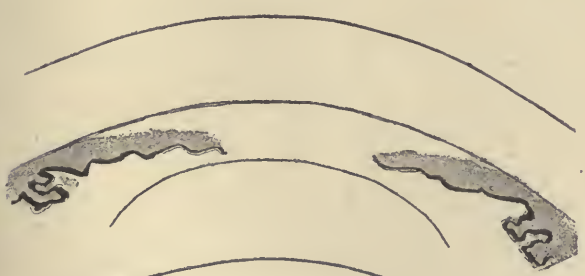

FIG. 5.

Coloboma of iris.

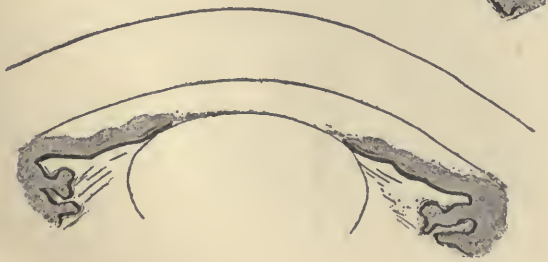

FIG. 6.

Pupil proper.

sue running from the optic disk to the posterior pole of the lens and then toward the equator, being finally inserted into the choroid at the sclero-corneal margin. This, in his opinion, furnished a mechanical obstruction to the growth of the iris.

In many colobomatous eyes there are remains of mesoblastic tissues which have not undergone the usual absorption, such as deposits on the lens capsule, persistent hyaloid artery, or pupillary membrane, etc., but their relations to the coloboma are not clear.

By some the genesis of atypical coloboma is thought to be different from that of typical. By others the process is thought to be the same in both, but occurring more frequently downward since there being already a cleft here, a coloboma is produced much more readily than in other locations.

In our case the fœtal cleft did not close completely in its anterior half, but the cause of its non-closure is not revealed by microscopic examination. If the cause were an inflammation of the mesoblastic tissue, this was so slight that after fifteen months of extra-uterine life no trace of it can be discovered.

A REMARKABLE CASE OF PSEUDO-TRACHOMA.

By Dr. RICHARD GREEFF,

ASSISTANT TO THE UNIVERSITY EYE-CLINIC IN BERLIN.

Translated by Dr. CHARLES ZIMMERMANN, Milwaukee, Wis.

(*With Tab. I., of vol. xxiv., Germ. Edit.*)

BEFORE and at the time of the last international medical congress at Berlin, a peculiar and especially marked case of a conjunctival affection was treated at our policlinic. Prof. Schweigger intended to show it to the section of ophthalmology at the session, in which the discussion on *Trachoma* was in order, thinking that a living case with a doubtful diagnosis, despite its marked clinical features, would serve best to elicit the opinion of our colleagues and lead to subsequent discussions of the subject. Unfortunately the demonstration could not take place for want of space. The case, interesting at that time, became still more remarkable by its course and its speedy, complete, and spontaneous recovery. I took a photographic picture of the diseased eye by flashlight before and after recovery.

Our case is as follows: A. N., fourteen years old, of Berlin, came into the policlinic on July 22, 1890, stating that his left eye had been swollen for several months and had become "smaller," with lachrymation and a burning sensation in the eye. His eyes had always been healthy, and none of his family members nor any of his schoolfellows had had any eye disease (as proven by later inquiries). He never had left the city. Lately his condition had become worse. He never noticed anything on his right eye. Otherwise he feels perfectly well. Both lids of the left eye,

especially the upper one, show a moderate thickening and redness, and it hangs farther down than the right one and covers the upper corneal margin even when he opens his eyes wide. Cornea and the parts around it perfectly clear and normal. Refract. E. V = $\frac{6}{9}$. Slight injection of ocular conjunctiva, no pericorneal injection. The sclero-corneal junction without any changes. Moderate lachrymation and photophobia. On eversion of the upper and lower lids the retrotarsal fold bulges as an intensely swollen and red mass. *The conjunctiva of both lids from fornix to ciliary border is totally and densely covered with numerous miliary granulations, projecting in the form of hemispheres from the swollen conjunctiva.* The conjunctiva at the middle portion of the upper tarsus shows also very many such granulations. The granules often are of considerable size, to *3mm* in diameter, and form horizontal chains like frog-spawn. They are grayish-red and very little transparent; the mucous membrane between them is reddened.

Right eye perfectly normal. Retrotarsal fold not in the least swollen, conjunctiva smooth and of normal lustre. Only at the temporal corner of the lower lid are a few small papillæ of the size of a pin's head, as often found in the normal mucous membrane. The lymphatic glands of the body are not diseased, but the left pre-auricular gland is moderately swollen. No pathological changes of other organs, especially no trace of tuberculosis. The boy is of robust, healthy appearance. His hygienic conditions at home are good.

The diagnosis was doubtful. Although it looked at first like a typical case of trachoma, as we seldom see it in Berlin, it had some different features. Trachoma is chiefly an endemic infectious disease, and occurs only in certain regions. Trachoma is not at all a common affection in Berlin. Among the great number of patients of our clinic, recent trachoma is very rare, and can be traced almost always to a direct importation from Eastern Prussia, Poland, Russia, etc. This was not possible in our patient, neither his relations nor schoolmates being affected, and it was remarkable that neither they nor his other eye became infected, as the affection had existed for quite a long time, without any precautions being taken.

Foerster and others doubt the infectiousness of trachoma; on the other hand Schmidt-Rimpler proved the transportation of trachoma from patient to patient, from house to house

in Hesse. Besides, the eye trouble and inflammatory appearance were too slight for trachoma. It could not be follicular conjunctivitis on account of the clinical aspect. Schmidt-Rimpler, distinguishing sharply both forms, characterizes follicular conjunctivitis as follows[1]:

"The follicles are never as numerous as the granulations, a few are found mostly in the external corner, or in the anterior portions of the fornix; they hardly ever reach the anterior tarsal portion. At the upper lid they are entirely wanting. Occasionally a few small follicles are seen at the posterior portion or external angle of the tarsal mucous membrane. The prominences in follicular conjunctivitis frequently are transparent, have a vesicular appearance, and have the size of a pin's head." Foerster[2] expresses himself in a similar manner. The follicular prominences never attain the size of large trachoma-granules, are not gray, but transparent, reddish, often very numerous at the lower retrotarsal fold, which is their place of predilection, and they never occur on the upper lid. Both descriptions are inapplicable to our case. The so-called spring catarrh (Saemisch) may be excluded, since the corneal margin did not show the least changes. The course, the absence of relapses up to date, completely confirm this assertion. The first appearance suggested the diagnosis "Trachoma." I have seen large *and numerous granulations only in trachoma regions*, in the eye-clinic of my former teacher Schmidt-Rimpler in Marburg, and in the policlinic of Prof. Gama Pinto in Lisbon, where the granulations become wonderfully exuberant under the southern sun.

A small piece of retrotarsal fold with a few trachoma-granules on it was excised under the influence of cocaine for microscopical examination, hardened in absolute alcohol and cut in sections at right angles to the surface (Fig. 3). Each section contains 2–3 large trachoma follicles, which might be called "lymphomas." They are pretty sharply differentiated from the loose surrounding tissue, and show a well marked membrane of connective tissue. The folli-

[1] *Augenheilkunde und Ophthalmoscopie*, 5th edition, p. 415.
[2] *Breslauer Aerztliche Zeitschrift*, 1888, p. 3.

cles are composed of closely crowded large lymph-cells and have a very tender and hardly noticeable stroma. The peripheral lymph cells are smaller and more densely crowded. In the neighborhood of the follicles there is a moderate infiltration of the tissue with leucocytes. According to Saemisch[1] the follicle is separated from the stroma of the conjunctiva by a membrane of connective tissue, which is wanting in trachoma granules. This anatomical difference, however, does not always hold good (Schmidt-Rimpler, Mandelstamm,[2] Raehlmann[3]).

No examination for micro-organisms was made, since we are not yet able, to determine the diagnosis from a bacteriological standpoint. In order to keep the clinical picture for a demonstration, the treatment was expectant and very mild : cold applications, instillation of a $\frac{1}{8}$ % solution of sulphate of copper, and hygienic measures. After several weeks the inflammatory symptoms not having abated and the follicles remaining unchanged, the attempt was made in the policlinic, to remove the contents of the follicles by squeezing the lid between the thumb and forefinger. The patient being very obstinate, very little was effected. The boy had so little taste for this kind of treatment that he did not return, even when asked to do so. In April, 1891, I finally succeeded in seeing him again. His mother stated that she put the drops into the boy's eyes for a while, morning and night, and that the disease had gradually subsided after causing only moderate trouble for a few weeks. Externally nothing abnormal could be seen on the eye. The lids of both eyes appeared perfectly normal upon eversion, so that it was impossible to say which had been the affected one. In the outer angles of the lower lids of both eyes there were a few small prominences of the size of the point of a blunt pin,—the physiological small papillæ. There was no further trace of the enormous granulations.

The photographic picture taken in August, 1890, exhibited the condition at that time (Fig. 1). Fig. 2 shows the present state (April, 1891); Fig. 3 is the micro-photograph of a section perpendicular to the surface of the excised conjunctiva. Another picture (not given here), taken with an especially sensitive plate, showed

---

[1] *Handbuch der Augenheilkunde.*
[2] *Von Graefe's Arch.*, xxix., 1.
[3] *Von Graefe's Arch.*, xxix., 2.

the interesting phenomenon, that in the picture now lighter spots, not noticeable with the naked eye, were found in places on the smooth conjunctiva, where formerly the granules were situated. This fact is known from other parts of the body, that *e. g.* exanthema of measles, freckles, etc., are easily discernible in the photographic picture, even when hardly or not at all observable with the naked eye.

In this case we have a conjunctival disease presenting the picture of acute trachoma, with unusually large and numerous granulations, but moderate irritation. The clinical features did not admit of the diagnosis of follicular conjunctivitis. The granulations disappeared after about half a year without treatment and without leaving any traces. If we consider scars after cure as characteristic of trachoma, we can only make the diagnosis of follicular conjunctivitis in our case. Here we have to do with an atypical case: the spreading and great size of the granulations and the rapid disappearance are striking.

If we are allowed to draw conclusions from a special case, I would assert that follicular conjunctivitis and trachoma are to be considered as different forms of disease, and that the former is not, as some authors think, a milder and less marked kind of the latter. If this were a fact our case must be taken for trachoma and hardly for a mild and less marked species of it. But then such large and numerous trachoma granules would hardly ever spontaneously have disappeared so rapidly and completely. Our case thus shows that there are cases of follicular conjunctivitis without the usual clinical characteristics, presenting at first the aspect of acute trachoma, differing, however, very much from it by their course. Both eye diseases are so different in their effects, inasmuch as the former, even in the most severe degrees, is innocent, and disappears without leaving any traces, while the latter is obstinate, leading to shrinkage of the tissues, often with the most destructive consequences. It is probable that they are caused by entirely different morbid agents, the isolation and culture of which we have not yet been able to secure. At least this question is not yet definitely determined. Considering the similarity of the clinical picture of

both diseases at first, we might here take occasion to warn against the too early diagnosis of "Trachoma" and its too energetic treatment. "Trachoma," or Egyptian ophthalmia, unfortunately is diagnosed too often by physicians, especially when epidemics appear in barracks, schools, etc. If the innocent follicular catarrh is then wrongly treated with such energetic remedies as lunar caustic, it is no wonder that they produce violent reactions and perhaps scars. Special consideration ought to be given to the essay of Foerster,[1] who will not believe in the occurrence of epidemics of trachoma. He says: "There are no epidemics of trachoma any more; it does not seem to be improbable that formerly the spread of trachoma was of a more epidemic character. Very likely it was chiefly trachoma which raged among the Prussian troops and caused the most cases of blindness in the army. At present trachoma is an endemic disease, which in Silesia at least is becoming extinct. Even in the later stages of trachoma a too energetic treatment is out of place. Each trachoma-granule leaves a scar, and the abundance of granules easily leads to shrinking of the conjunctiva. Therefore everything ought to be avoided which might create such a shrinking process, especially Heisrath's method of excising and scraping the diseased mucous membrane." We saw several times in our clinic cases which had been operated on in this manner at Koenigsberg, exhibiting the saddest picture imaginable. In follicular conjunctivitis we have applied for quite a long time a two-to-three-per-cent. solution of biborate of sodium, according to Foerster's suggestion.

Our views in regard to conjunctival diseases with the formation of "granules" being at present rather confused and unsettled (almost every author has a different opinion), I thought it worth while to communicate this atypical, and for us very remarkable, case to my colleagues as a small contribution to the trachoma question. Its explanation and classification I prefer to leave to the ophthalmologists practising in trachoma regions.

---

[1] *Breslauer Aerztliche Zeitschrift*, 1888, p. 1.

SHARP-CUT ECTASIA AT THE POSTERIOR POLE IN HIGH-GRADE MYOPIA.

By Dr. LEOPOLD WEISS, in Heidelberg.

Translated by Dr. B. Alex. Randall, Philadelphia.

(*With five figures on plate viii. of vol. xxiii., Germ. Ed., and one in the text.*)

THE so-called "posterior staphyloma" which is seen by the ophthalmoscope in such manifold form as a common finding in myopia, is not, as is well-known, an actual staphyloma in the sense that it is the expression of a sharply defined ectasia, the boundaries of which coincide with those of the whitish figure—the "conus"—which borders upon the nerve-head or surrounds it in annular form. When one follows the retinal vessels from the papilla over the so-called staphyloma, he clearly sees that there is no difference of level at the margin of the "staphyloma."

In contrast with this condition, there occurs—seldom indeed—in high-grade myopia a true posterior staphyloma, a pouched, sharp-cut ectasia at the posterior pole. At the margins of this actual staphyloma the retinal vessels are abruptly altered in course, since they must climb from the floor of the depressed area with a strong bend upon the steep wall, to reach the level of the general eye-ground.

In proof of this the following cases are reported, which have come to my notice in recent years.

Case 1.—A man of thirty-one, very near-sighted from earliest childhood, came March 11, 1885, because of a trivial injury. Vision could be raised only to $\frac{6}{60}$ left, and $\frac{3}{60}$ right, by —16 D; and vitreous opacities were found on both sides. The

ophthalmoscopic finding in the right fundus was very striking. Besides the choroidal disturbances and an annular "staphyloma" with most marked development to the temporal side, there appeared on the nasal side, rather more than a papilla-breadth from the white "ring-conus," a distinct dark curved line, broadest in the middle and narrowing up and down until it disappeared gradually temporalwards. With altered position of the mirror this curved line varied in breadth, as the shading of the steep wall of the ectasia became more or less distinct. The retinal vessels passing from the papilla across the area were sharply interrupted at the curved line, and showed marked parallactic movements in the indirect examination. No doubt remained that the dark curved line indicated the boundary of a sharply defined ectasia at the posterior pole of the eye—the shading on the steep nasal wall of the staphyloma giving rise to the dark line.

Case 2.—The second case was that of a young lady of twenty-four coming because of high near-sight, which was dated from early childhood. The vision was raised only to $\frac{6}{24}$ by—16 D. Just as in Case 1, the ophthalmoscope revealed a rather large annular conus, with a dark curvilinear band, doubled by an intervening bright line, rather more than a papilla-breadth to the nasal side of its margin. The retinal vessels passed with broken course and with marked parallax over this curved band. In the direct examination, correction glasses of markedly different strength were needed for focussing the floor of the ectasia from those required for the general eye-ground. On the left the condition was even more outspoken than on the right, as shown in Fig. 2.

Taking the visual field showed the blind-spot considerably enlarged, with an adjacent area, as indicated in Fig. 3, in which the perception was notably reduced. Sharply defined to the temporal side, this area of impaired perception seemed to correspond with the ectatic area to the nasal side of the papilla.

Case 3.—A clerk fifty-eight years of age, myopic and weak-sighted. The better (left) eye saw $\frac{6}{18}$ with concave 11 D; in the diverging right eye the vision was considerably lower. The opthalmoscopic examination gave as the cause of the markedly defective vision, posterior polar cataract, vitreous opacities and extensive choroiditic changes at the posterior pole. A large "annular posterior staphyloma" was bounded on the nasal side by a dark curved line, which diverged from the margin of the ring-conus above and below, being separated from it by a narrow

band of red eye-ground, as shown in Fig. 4. The vessels are markedly interrupted in their course over the dark curved line and showed distinct parallactic movement. The direct examination was difficult by reason of the opacities in lens and vitreous, but a difference of level was recognizable by the various glasses needed for focussing the eye-ground within and beyond the curvilinear boundary.

Here also there was a scleral ectasia, sharply defined to the nasal side and flattening upward and downward; to the temporal side there was a gradual rise of the distended area, with the papilla lying in the ectasia. In contrast to the two preceding cases, the nasal border of the annular conus coincided with the steeply sloping limit of the ectasia, the steepest portion of which was here also nearly in the horizontal meridian. In the visual field of the right eye a large central scotoma, nearly 40° in diameter, was found—its medial border 5°, the temporal 35°, from the fixation point.[1]

CASE 4.—Prof. H. came with the left eye blind and cataractous, and the right highly near-sighted and with much reduced vision. The ophthalmoscope showed vitreous opacities, small central choroiditic changes, a large annular posterior staphyloma, which was defined at the nasal side by a dark curved line, the breadth of which varied with the altered position of the mirror. The course of the retinal vessels traversing this curved line was sharply interrupted, and the parallax was very striking in the distorted portions of the vessels.

Here again, as in the third case, we had a distension at the posterior pole, sharply bounded to the nasal side by a margin coinciding with that of the so-called "ring-conus." The distance from the papilla of this curvilinear margin was about the same in the last case as in the others.

Taking the visual field showed the blind spot considerably enlarged—some 22° in the horizontal diameter—and adjacent to it a narrow zone, especially towards the fixation-point, in which the yellow square appeared "whitish" and the red "gray or grayish blue."

Not uninteresting is the statement of the patient that when admitted in his fourteenth year to the eye-clinic of S——, fear

[1] As the small ivory knob serving as the fixation point of the perimeter was not seen, the patient was directed to touch the ivory knob with his finger during the field-taking, and to look fixedly toward this finger.

was expressed that the eye might suffer from retinal detachment. It may be surmised that perhaps the ectasia already existed at the posterior pole, and that the difference of level was then noted and considered as a commencing detachment. Unfortunately, in the clinic records of the institution no detailed notes have been found bearing upon the cases.

From the foregoing, it is easy to construct a schematic sketch, as shown in the accompanying figure, of what would be presented by a horizontal section of such an eye.

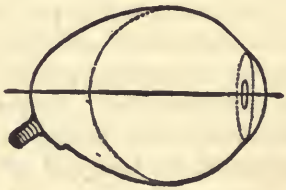

These cases are of rare occurrence. Since seeing the first case in 1885, I have not neglected to search for the condition in every case of high myopia, and I do not believe that I have overlooked a single instance. Among some 20,000 patients seen in the past six years I found the condition only four times. Perhaps other investigators have observed such cases ; but the communication of these seems justified, since no description of the condition, so far as I know, has been heretofore presented.[1]

Whether the sharply defined ectasia developed only in later life, or whether, if only in small degrees, it were already present in youth, is not conclusively shown by the reported cases.

As to the anatomical conditions in such eyes, I can report nothing, since no myopic eye of this character has come to my examination. The concurrence of the ophthalmoscopic appearances in the cases reported justifies the assumption that we here have to do with changes connected with some quite distinct anatomical condition at the posterior pole.

---

[1] The observation reported by Szili ("Zur Morphologie der Papilla Nervi optici." *Centralbl. f. Augenh.*, 1887, 1), has nothing in common with the condition described. How far the findings reported by C. Hess (*Arch. f. Ophth.*, Bd. xxxiv. and xxxvi.) have relation to our subject, remains as yet undecided.

The reported finding has nothing in common with the large or small pouchings of the sclera which one occasionally finds in pathological conditions, especially in staphylomatous, degenerated eyes, irregularly placed in the most various portions of the sclera.[1]

The ophthalmoscopic picture described, brings to my mind the finding in a macroscopic study of the near-sighted eye of a scholar, which I examined long ago. This showed in many respects a similarity, but was in others wholly different. The notes then made state: It is very striking that the sclera is very much softer at the posterior pole (medium myopia). If the eye is placed, cornea down, upon the table, the sclera at the posterior pole, sinks with the nerve in the form of an oval, of which the nerve entrance is not the centre but lies to the nasal side. This oval measures about 17 *mm* horizontally and 12½ *mm* vertically. Above and below this thinned area, the sclera is much firmer, making the boundary between the lax and the firm sclerotic a sharp one: outward and inward the boundary is less sharp. If the eye be lifted by the optic nerve, the sclera forms a fold in the horizontal meridian reaching far forward. A broad horizontal band of the sclerotic, then, in the posterior segment of the bulbus is much more yielding and lax than the remainder; and the softer portion of the sclera surrounding the nerve entrance has taken on a different coloration in the Mueller's fluid. The accompanying sketch (Fig. 5) will indicate the condition described.

---

[1] Occasionally one finds in the case of these diverticular pouchings of the sclera, that the retina does not clothe the distended portion, but stretches across the base of the pouch.

REMARKS ON IMMATURE CATARACT AND THE BEST METHOD OF HASTENING MATURITY.

By JOSEPH A. WHITE, A.M., M.D.,

SENIOR SURGEON TO THE RICHMOND, VA., EYE, EAR, THROAT, AND NOSE INFIRMARY.

THE question of the maturity of cataract is an important one for those whose eyesight is failing from opacification of the lens. It is usually considered a simple matter for an expert ophthalmologist to decide when this opacification has reached the stage of "being ready for operation."

When is a cataract ripe? Probably the answer to this question is one upon which all ophthalmic surgeons agree—*viz.*, when it will leave behind no cortical substance in a condition to swell and set up secondary irritation and inflammation.

The most expert of us is at times deceived in a nice calculation of this condition, and the error is likely to be followed by trouble, sometimes by destruction of the eye, or opacity of the cornea from resulting choroiditis. Schweigger (*Deutsche med. Wochenschrift*, 1890, p. 695) thinks cataract can always be safely removed without leaving large enough remnants behind to be dangerous, as soon as the lens has lost its elasticity, when it has become flatter, and accommodation has disappeared, even if considerable portions are still clear. This occurs usually between sixty and sixty-five years of age. Under this age the clear part of the cortex forms a sticky substance, which is most likely to remain behind, swell, and cause trouble.

Undoubtedly the best safeguard against danger of failure is perfect opacification of the lens substance, and the object

of this paper is to consider which is the best, safest, and surest method of artificially obtaining this result. Apart from the fact that it lessens the risk of cataract extraction it has another aspect of prime importance—it shortens the period of cataract formation, which may extend from a few months to several years, and to a man in moderate circumstances, with a family dependent upon his labor, this might entail ruin and poverty if it be prolonged to any unreasonable extent. Consequently, all suggestions to hasten maturity have been given a trial.

Puncture of the anterior capsule, combined with iridectomy, attributed to Mooren (1858), has for years been a means employed to this, and it often failed in its purpose. Moreover, the danger of resulting iritis from swelling of the lens barred its universal adoption.

When Foerster, of Breslau, at the meeting of the Heidelberg Ophthalmic Society, in September, 1881, suggested his method (see ARCHIVES OF OPHTHALMOLOGY, vol. xi., p. 344, "On the Maturity of Cataract, its Artificial Ripening," etc.) of triturating the lens through the cornea after an iridectomy to hasten the maturity of cataract, it was recognized as a great advance in this direction. It was the outcome of his and others' observations that cataract frequently ripened more rapidly after a preliminary iridectomy. Since then his operation has been the standard one for artificially hastening opacification of the lens.

In 1883 and 1884 I performed it five times, but was dissatisfied with it, because I had unpleasant complications in two out of the five cases; in both there resulted considerable irritation, followed by iritis with posterior synechiæ in one and corneal opacity in the other.

In 1885 (*N. Y. Med. Jour.*, Dec. 26, 1885), I saw a suggestion from Dr. T. R. Pooley, of New York, that the opacification of the lens could be brought about by triturating after a simple paracentesis of the anterior chamber *without iridectomy.* He tried it successfully on rabbits. Within a few days I tried it on a negro patient who presented himself at my clinic in the Richmond Eye, Ear, and Throat Infirmary with a cataract about half ripe. In forty-

eight hours the opacification had so far advanced that no red reflex could be obtained. In three weeks the cataract was successfully extracted. This and another case were reported in a paper read before the Virginia State Medical Society ("Results of Clinical Work at the Eye, Ear, and Throat Infirmary," etc.) in 1886, and as far as I can find they were the first recorded cases of this method of ripening cataract in the human being.

Prior to my report of those cases, and before Dr. Pooley made his experiment on rabbits, Candrou in 1833 ("Maturation artificielle de la cataracte," *Rev. gèn. d'ophtal.* 1883, No. 6), in an article recording six successful cases of ripening cataract by Foerster's method, suggested that it might be done equally well without an iridectomy, but does not mention any cases thus operated on. Gunning of Amsterdam also made the same suggestion of simple puncture and massage in April, 1886, at the Paris meeting of the French Society of Ophthalmologists. As far as I know, Candrou was the first to suggest this method, Pooley the first to perform it, but on rabbits only, and mine were the first successful cases on the human being. The third case I tried gave quite a different result. The patient was an Italian with slight central opacity of the lens. With a contracted pupil, his vision was very bad; dilated with a weak solution of atropia it was fairly good. He could read ordinary type. Still, experimentally, and to test the value of the operation, I did a paracentesis and triturated the lens. A few days after I found to my astonishment the opacity of the lens smaller and thinner. When the resulting injection of the eye had disappeared, I triturated again. A few weeks later, I could find no opacity in the lens. I thought I had made a discovery, *viz.*, that, in the very incipiency of cataract with a small and faint opacity, massage would cause its disappearance. I have tried it several times since with invariable disappointment. My apparent discovery was no discovery. It was an isolated case, interesting as such, unexplainable in its result, but its clinical significance was entirely negative. A very similar case was reported by Tatham Thompson in 1890. (*The Royal London Ophthalmic Hospital Reports*,

vol. xiii., part i., p. 38). Others have thought they had found the way to aborting opacification of the lens in its incipiency, but the methods suggested have not been accepted with much favor, and the results recorded have been regarded as doubtful. The attempt to dissipate early opacities of the lens by the continuous current has been made, and some claims to success set up, but they proved fallacious.

There is no doubt that a method of aborting cataract is ardently to be desired, but it is still one of the problems of the future. Lacking this, the next best is an early and speedy ripening. Besides the old mode of division, and Foerster's method of "iridectomy and trituration," other suggestions have been made to accomplish this result.

Rohmer in 1886 ("Maturation artificielle de la cataracte," *Union Méd.*, 1886, p. 298) suggested a modification of the ordinary method of division with trituration. Two or three little openings are made in the capsule with a division needle, the aqueous is thoroughly evacuated, and the massage is made by the fingers through the upper lid.

Domingo Sasso of Buenos Ayres in 1888 ("Maduracion artificial de la catarata por el massage del cristalino sobre la cristaloidea. Nuevo procidimiento. Inaug. Thesis, 1888) presented an inaugural thesis on a new proceeding for ripening cataract, suggested by Dr. Ricaldi of Buenos Ayres, which consisted in massage of the lens directly on the capsule by means of a spatula introduced into the anterior chamber through a small opening made in the cornea, and reported five cases with brilliant results. This method Dr. Bettmann of Chicago has successfully practised. Dr. Born of New York recently told me he also had tried it, with satisfaction.

The means of ripening immature cataract are therefore:

1st. Simple division of the anterior capsule.

2d. Division combined with iridectomy.

3d. Division and external massage.

4th. Iridectomy and external massage.

5th. Paracentesis of the cornea and internal massage directly on the anterior capsule.

6th. Simple paracentesis and external massage. In considering these methods, it is advisable to choose the one least likely to cause complications provided it accomplishes the result.

The first three in which division of the anterior capsule is performed, including Rohmer's operation, are always attended by the danger of violent inflammation, and loss of the eye, to say nothing of the minor risks of iritis and corneal opacities. The most accomplished ophthalmic surgeon cannot always determine when a dangerous reaction will follow a wound of the lens, even when done with all ordinary prudence and care. The opening in the capsule may be made so small by a timid operator as to fail entirely of its purpose; or a bolder surgeon may make it so large as to result in a too rapid swelling of the lens with its hazardous consequences. Again, even a large opening may be entirely negative, the only result being an oozing out, as it were, of a plug of cortical substance, whitened by contact with the aqueous humor which closes the opening and leaves the lens *in statu quo.*

The fourth method, known as Foerster's, is the one usually done, and all who have performed it know that it is not unattended by danger of serious complications, as iritis is a not infrequent result. Noyes, Bull, Theobald, Moebius, McHardy, and others have reported iritis following their operations, and Mittendorf has even recorded the loss of an eye as a result. Moreover, the iridectomy itself is a grave traumatism and disfiguring in this day of simple extraction.

The fifth method of *internal massage*, as I have denominated it, Ricaldi's operation, I have no experience with. It necessitates, however, an opening in the cornea large enough to manipulate an instrument in the anterior chamber and the introduction of a spatula into the eye, traumatisms of sufficient gravity for consideration, besides massage directly on the surface of the lens, which requires great care to avoid a dislocation of the latter.

The sixth and last operation of "simple paracentesis and external massage" is free from all the objections urged against the other operations. There is no wound of the

capsule or iris, the traumatism of simple puncture of the cornea is very slight, and the cortical substance can be sufficiently disturbed and bruised by the massage through the cornea to mix it up, as it were, so that the clear and opaque parts mingle together, resulting in rapid opacification of the translucent portions. I think the result due to mechanical disturbance, and not to an alteration of nutrition. If artificial ripening of an immature cataract is advisable at all, we have here an operation of slight traumatism, of easy accomplishment, of minimum risk, and of rapid and brilliant results in the majority of cases. Whether artificial ripening of an advancing cataract is desirable in certain cases or not, is a question still in abeyance. Some ophthalmologists object to it, their objection being based on the more or less hazardous character of the proposed operations, and either wait for nature to ripen it, or proceed at once to extract it in its unripe condition. All ophthalmic surgeons have had to do this under certain conditions, but very few care to attempt it, unless circumstances demand it, because of the attending risks to a successful restoration of vision. Some, however, prefer to extract the unripe cataract rather than to do any operation to ripen it, and the means suggested to lessen the risks are peripheral incision of the capsule, so that the retained cortical may rest innocuous in its sac, and irrigation of the anterior chamber to wash them out of the eye through the corneal wound.

Tweedy, of England, is the strongest advocate of removing immature cataracts by the former method, his operation being upward section of the cornea, iridectomy and peripheral capsulotomy. This mode of opening the capsule was first suggested by Gayet, of Lyons, and its best known champion has been Knapp, who has for many years employed it in his cataract operations.

The question of irrigation of the anterior chamber was first discussed by Prof. Horner, of Zurich, at the International Congress of London in 1881. Wicherkiewicz, of Posen (*Klin. Monatsblätter*, Nov., 1885; and also "Sur l'irrigation des chambres de l'œil pour l'extraction de la cataracte," *Soc. française. d'ophtal.*, April 30, 1886), first put it into practice,

especially in regard to immature cataracts. He flooded the anterior chamber with a solution of chloride of sodium (7–1000) boiled and cooled down to thirty degrees Cent.

McKeown (*Brit. Med. Jour.*, Oct. 29, 1888) advocates the same method for extracting unripe cataracts, using simply warm water.

Panas (*Bulletin de l'Académie de Méd. de Paris*, Jan. 1, 1886) irrigates with a solution of biniodide of mercury (1–20,000), and others of the French school follow his methods. Dr. Lippincott, of Pittsburgh, practises irrigation with a solution of boric acid, probably the only safe fluid to use, and has devised a syringe that lessens the risk (*Transac. Am. Ophth.*, Dec., 1891). As nearly all the advocates of irrigation of the anterior chamber in cataract extraction, whether of ripe or unripe cataract, claim two absolute essentials for its successful performance, *viz.*: immobility of the operated eye, and perfect control of the hand of the operator, we may safely say that it is a more or less hazardous addition to the steps of the operation, because while the skilled operator is supposed to have perfect control of his hand, no surgeon can insure immobility or quiet in the operated eye. With Dr. Lippincott's syringe these conditions are not absolutely necessary. We must not take too much for granted even in regard to the hand, for I have seen a shaky hand more than once in accomplished and presumably dexterous ophthalmic surgeons. Hence I conclude that if time is to be saved by early operation for cataract, and if we must decide between removing it in the unripe state, or attempting to hasten its maturity, we should first try to ripen it, unless we can guarantee both hand and patient. This remark carries greater force in view of the success that in my hands has attended the operation I here present, and its comparative freedom from surgical risks. The only objections that can be made to it are that the zonula might be slightly detached by too great violence, and the risk of loss of vitreous in the subsequent extraction increased. I have performed fifteen of these operations in all, and in not one single case was there iritis, corneal opacity, dislocation of

the lens, or trouble in the subsequent extractions, which were perfectly smooth, and resulted in good vision.

Every case of cataract does not need help from the surgeon to hasten its maturity. It is only a small number of the grand total that require it. When cataract has advanced in both eyes equally, and when the patient has reached the stage of no longer being able to read or attend to the work that gives him and his family support, this necessity arises. Even in these cases, some are not suitable for massage, for *unless the zonula is intact and the pupil can be dilated*, this operation should not be attempted. It is most successful when the nucleus has become opaque, as it acts as a base upon which to crush the cortex.

Opacities at the posterior pole, if large enough, serve the same purpose. But I have operated equally on true cortical cataracts as soon as the opaque peripheral striæ had invaded the pupillary area sufficiently to interfere with reading.

The operation is especially called for under sixty years of age, when the cataract has reached the proper stage, because the cortex is then more liable to be sticky and give trouble. I think it would be a prudent precaution to triturate all cataracts under that age (unless hypermature), even when apparently ripe, so as to dislodge the sticky masses of cortex from the capsule and perfect their opacification, thus insuring their easier delivery.

My method of operating is very simple. After satisfying myself that the tension is not below normal, that the zonula is intact, and that the pupil can be easily dilated, I thoroughly evacuate the aqueous humor with the ordinary paracentesis needle, and vigorously rub the lens through the cornea, up and down, out and in, as well as in a circle, varying the direction of the rubber or tortoise-shell spoon I employ to avoid striated opacities of the cornea, which may result from constant friction in one direction. I usually continue this until the irritation of the eye warns me to desist. Atropia is instilled immediately, and cold applied to the eye, the patient holding a piece of ice, rolled in a thin layer of absorbent cotton, against the closed lids until the eye aches; after the aching subsides, it is reapplied. An

hour or so of this treatment, followed by instillation of atropia every hour or two the same day, is all that is done. No bandage is used. Sometimes considerable irritation is manifested, and slight pain is occasionally complained of, but I have never seen any unpleasant complication. In the majority of my cases the lens showed increased cloudiness the next day, and I have seen cases that could make out large letters become perfectly blind in forty-eight hours. In some the opacification proceeds more slowly, taking several weeks to become complete. Even where it is seemingly very rapid, I think it advisable to wait two weeks for the extraction. In two of these cases I had to repeat the operation four weeks after the first trituration because of the tardy result. In one of them opacification was complete forty-eight hours after the second attempt at ripening the cataract.

The last two cases of cataract ripened by this method will serve as illustrations of the operation and its results.

Case 1 (Nuclear Cataract).—W. B. Goodwin, of Hampton, Va., æt. forty-two, consulted me on Sunday, March 27, 1892. He had cataract developing in both eyes. In the right eye it was in its incipient stage, and vision was $\frac{20}{40}$. The left eye had an opaque nucleus and clear cortex free from striæ. Vision with a dilated pupil was $\frac{10}{200}$. He told me the left eye began to fail about seven or eight years before, and had very gradually reached its present condition. He had gone to Philadelphia twice, the last time about Christmas, 1891, and had each time been sent back to wait for a more complete opacification of the lens before it could be extracted. He had come to me to see if something could not be done to hasten matters and end this interminable waiting. I suggested that he allow me to ripen it. He consented. I dilated the pupil thoroughly, evacuated the aqueous humor, and triturated through the cornea with a tortoise-shell spoon for about two minutes. The eyeball became somewhat injected. I prescribed a solution of atropia, cocaine, and boracic acid, ordering it to be used every two or three hours. He left my office to see the city, and returned to Hampton on the afternoon train. Two weeks after, he came back again on Sunday. I found the lens perfectly opaque throughout. He said he had had some slight pain and irritation about the eye the evening following the operation, and

that it was perfectly blind in two days. On the day after his return I extracted the cataract with a simple corneal section, and removal of the anterior capsule with Eugene Smith's modification of Knapp's capsule forceps. The operation was smooth and the healing rapid. On the tenth day he returned to Hampton. On May 29th he came again to have the capsule needled and get his glasses. His condition was as follows:

Cornea, clear; iris, normal in appearance; pupil, round and perfectly black, without a sign of cortical remnants, and freely responsive to the stimulus of light. When I dilated it with atropia to examine the capsule, some remains of cortical substance could be seen in the periphery of the capsule, but the centre was clean and clear. His vision was $\frac{20}{20}$ easy, with $+ 11$ D $\supset + 2.5$ D_c ax. 15°.

Probably this astigmatism will decrease slightly in the next few months.

Case 2 (Cortical Cataract).—P. Whitlock, manufacturer of the world-famed Virginia Cheroots, age 56, had the left eye triturated by this method March 26, 1892. The opacities in the lens were mostly in the cortex, especially in the periphery, though there was a slight central cloud. The reflex was good, the retinal vessels could be made out, and vision was $\frac{8}{200}$. In twenty-four hours I could get no illumination of the fundus, the opacification was generally diffused, and he could not count fingers. Although he had the cataract ripened for an early extraction, his business has kept him so occupied I have not yet operated on him. He was in no hurry, because he had good vision ($\frac{20}{40}$) in the right eye, from which I had removed a cataract September 16, 1891. This eye was one of the two I referred to above where the trituration had to be repeated. On April 23, 1891, I attempted to ripen the cataract, but probably from insufficient massage it progressed so slowly that on June 16th I repeated the operation with resulting complete opacification in forty-eight hours. As the weather was so hot I advised him to wait until the fall for the extraction, which I successfully performed in September as above mentioned. In this case there was slight prolapse of the iris caused by his restlessness, and this retarded the healing, otherwise everything went well. In both cases the delivery was easy and clean, the cortical masses coming away without trouble.

I also present two other cases operated on by Dr. John Dunn, chief of clinic at the Richmond Eye, Ear, and Throat

Infirmary, and which he has reported in his own words, as follows:

CASE 1, *August*, 1891.—Mrs. W., aged sixty-three, says her sight began to fail her several months ago, can now no longer read with any glass. Can distinguish outlines of objects, but can see nothing distinctly. Both lenses show numerous opaque plates, without any general clouding. Lens substance between the plates transparent. Fundus visible, but no details can be made out. Patient declines to have cataract ripened.

November 28, 1891.—Patient returns, lenses in same condition as in July. "White's operation" done on O D. *December* 5*th*: small cloudy areas have appeared throughout the transparent parts of lens, although not sufficient to ripen the entire lens.

January, 1892.—Both lenses extracted without iridectomy, that of O S without previous ripening, and considerable transparent lens substance proves to have been left behind. In O D vision equal ($\frac{18}{20}$) after discission.

Following discission in O S there was iritis with adhesions to the capsule and secondary glaucoma, necessitating an iridectomy.

CASE 2, *February*, 1892.—Mr. L., aged 78 years, sight of O D has been failing him for months. O S has been useless for years owing to a dense corneal scar. Patient can make out indistinctly objects held in front of him. $V = \frac{10}{200}$. Slight general clouding of the lens.

February 6*th*.—"White's operation" done in O D.

February 10*th*.—But little change in the condition of the lens; probably trituration was not thorough enough.

February 14*th*.—"White's operation" repeated.

February 21*st*.—Entire lens opaque and ready for extraction.

This patient did not return for operation until May, when the lens was successfully extracted, the result being all that could be desired.

You will observe in these cases, both over sixty years of age, one sixty-three and the other sixty-eight, that the operation was of considerable service. In the first case in which trituration was done on one eye and not on the other, although both extractions were done by the same method and with equal skill, in the triturated eye the cortical substance was easily evacuated, and there was little or no

subsequent trouble; whereas, in the eye on which trituration was not done, the transparent lens substance was left behind unknowingly, and there has been annoying and dangerous complications, such as iritis, adhesions between capsule and iris, and secondary glaucoma. In the second case, as in two of mine, the operation had to be repeated, probably from insufficient massage, although Dr. Dunn repeated the operation in eight days, a little earlier than I have been in the habit of doing it. The second operation was followed by rapid and perfect opacification of the lens.

This contribution from another operator than myself to the subject of ripening cataract by this method, which Dunn calls "White's operation," although I claim no originality whatever, except in resurrecting and putting into practice the buried suggestions of others, shows that equally good results followed in another's hands. Whilst the number of cases is not very large, they help to prove that it is practically free from surgical risks, and assists materially, as I have already claimed, in shortening the period of waiting for ripening, and lessening the risks of the subsequent extraction, thus improving the chances of success in restoring vision.

A CASE OF SARCOMA OF THE CHOROID AND CILIARY BODY.

Clinical History, by DAVID WEBSTER, M.D.

Microscopical Examination, by WARD A. HOLDEN, M.D.

(*With a figure in the text.*)

CLINICAL HISTORY.

Selah N. J., aged sixty-three, married, clerk, was referred to me by Dr. A. F. Hoag, with a letter, on February 2, 1891. Mr. J. visited my office on February 4th and 5th, being examined at his first visit by my associate, Dr. S. M. Payne, and at his second visit by me. We found a *black* tumor filling the nasal third of his right anterior chamber, and a *white* tumor projecting into the vitreous immediately behind the iris, and apparently springing from the ciliary body (see figure). A portion of the sclera, varying in width from half a line to two lines, adjacent to the nasal periphery of the cornea, and extending around about one fourth its circumference, was *stained black.* The vision was $\frac{20}{200}$ and not improved by glasses.

The patient stated that he had never noticed any trouble with either eye, except that they both would get red when he caught cold, until the 12th of September, 1890, when, while mixing mortar, he got a small portion of lime into his right eye. This caused a severe inflammation from which he recovered without the aid of a physician. From the time of the lime-burn he noticed that the sight of that eye was blurred. In the early part of January, 1891, he noticed the black spot on his eye, and then consulted Dr. Hoag, who treated the eye with atropine, sulphate of zinc, and bichloride washes, but with no benefit. He then advised him to see an oculist, and finally sent him to me.

There is no history of blindness, or of cancer, in Mr. J.'s family. His general health is good. He could see some with the eye until

some time in the fall of 1891, when he gradually lost all but perception of light. Enucleation was advised by Dr. Payne on February 4th, and the advice was concurred in by me when I saw him on the 5th. But for some reason the patient deferred the operation until April 12, 1892, when I saw him again. He had suffered a good deal of pain in and around the eye through February and March, but the pain had nearly all left him when he came to me for the operation. I found perception of light, but very imperfect projection. The tension was slightly increased; a mature cataract covered the posterior portion of the growth. The black anterior portion may have increased a little in size and area, but appeared practically the same.

Assisted by Dr. Achilles E. Davis, and Dr. Mary E. Hennessy, I enucleated the eye and placed it in Müller's fluid.

MICROSCOPIC EXAMINATION.

The eyeball after being hardened and divided by a horizontal section presented the appearance shown in the figure.

Histologically the new growth is a small-celled sarcoma, spindle cells largely predominating. The points of particular interest which it offers are the fact of there being two tumors, the irregularity in the pigmentation of the neoplasm, and the manner of its extension.

The tumor consists of two masses on a common base, one springing from the choroid and one from the ciliary body. The choroidal portion is covered with a capsule consisting of retinal pigment epithelium (the inner layers of the retina being detached), lamina vitrea, and choriocapillaris, and this capsule together with the degenerated pars ciliaris retinæ extends forward over the choroidal portion, nearly to the sclera, separating it from the ciliary portion, which latter has no capsule of any sort but projects uncovered into the vitreous chamber.

Multiple sarcomatous tumors of the uveal tract are rare. I have seen one case only in which two elevated nodules were almost contiguous and the choroid between them was infiltrated with sarcoma cells. In these cases one tumor is always larger than the other, and one may be assumed to be simply an extension of the other.

The ciliary portion of the growth is darkly and diffusely pigmented, the choroidal portion is but slightly mottled. For the purpose of studying the pigmented portion, specimens were bleached in the manner recently described by Treacher Collins.[1]

By this process I have found that the pigment in the posterior portion of the normal eye is readily removed, that from the iris and ciliary body somewhat less readily, and the pigment in the anterior portion of embryonic eyes scarcely at all. The pigment in sarcomata, however, is given up completely in a few minutes, and the cellular structure may

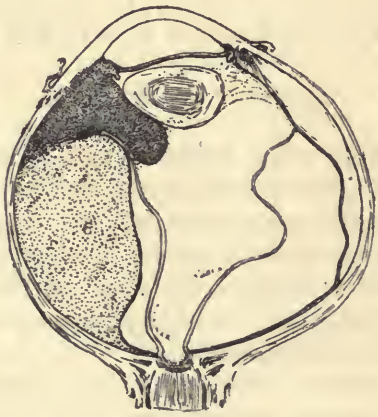

then be studied in an unpigmented sarcoma. In preparations from this tumor as well as from others in which the pigmentation was not uniform, the shape, size, and arrangement of the cells were the same throughout, and in the bleached preparations it was impossible to say which portions had been pigmented and which had not.

The central portion of a sarcoma may be absolutely free from pigment, the capillary walls may show spindle-shaped

[1] This valuable method is as follows. Sections cut from specimens imbedded in celloidin are put for three minutes into water with which chloride of lime has been mixed and which has then been filtered; next into water with hydrochloric acid ♏i–ʒi; then transferred from one fluid to the other until bleached; next placed in water with liq. ammonia ♏i–ʒiv; finally washed three times in distilled water and stained with logwood. *Trans. Ophthal. Soc.*, vol. xi.

pigmented cells, the vessels may have groups of round or spindle-shaped pigmented cells about them, single tracts of cells may be pigmented, or every cell in the tumor may be black. Yet the degree of pigmentation seems to stand in no relation to the histological structure, and in no very marked relation to the point of origin or to the malignity of the growth. The disposition of the autochthogenous pigment in the sarcoma seems to be entirely fortuitous, and such being the case the ordinary classification of sarcomata into melano- and leuco-sarcoma has no pathological significance.

As to the mode of extension. The tumor involving the entire extent of the ciliary body, on the nasal side, with the exception of the anterior portion of some of the ciliary processes, has penetrated into the head of the ciliary body, and pushed forward into the anterior chamber. The iris proper is but slightly involved but is displaced inward and forward. The entire ligamentum pectinatum on the contrary is infiltrated with pigmented cells, and from this part the same cells pass a short distance into the cornea between the lamellæ, and farther along the endothelium on its posterior surface. Even at the opposite side of the cornea the region of the canal of Schlemm is infiltrated and the angle of the anterior chamber filled with pigmented cells, showing that the process has extended in the loose tissue of the ligamentum pectinatum and the head of the ciliary body throughout the entire circumference of the cornea. In another case of sarcoma of the ciliary body of about equal development, the anterior portion of the ciliary processes is free, the head of the ciliary body and the ligamentum pectinatum have been involved and the iris displaced inward, and here also pigmented cells are found about the canal of Schlemm in its entire extent, so that this may be taken to represent a usual manner of extension. In the case under consideration the veins which pass from the canal of Schlemm through the sclera are bordered with sarcoma cells, and some small foci are found on the outer surface of the sclera.

The lens capsule is intact, but the form of the lens has

been changed by the pressure of the tumor. On the opposite side, the ciliary body has a few pigmented sarcoma cells scattered over its surface, and these continue along the hyaloid membrane and the fibres of the zone of Zinn to the lens capsule. These are not the round pigmented cells found free in the vitreous in some cases of sarcoma, but spindle cells which have developed continuously over the hyaloid membrane and the suspensory ligament, and in most instances form a layer on each surface. I have not found this extension of sarcoma cells in cases where there has been no plastic cyclitis.

The extension of a sarcoma is always in the directions of least resistance. In passing out of the eye the paths are along the sheaths of the ciliary vessels and nerves, the vortex veins, and the optic nerve. These extensions may be so small as to be scarcely recognized with the naked eye, so that even a minute pigmented point on the surface of the enucleated ball near the sclero-corneal junction, the vortex veins, or in the region of the optic nerve, should warn the surgeon of the possibility of the local recurrence of the disease.

A CASE OF HOMONYMOUS SUPERIOR HEMIANOPSIA.[1]

By Dr. F. BOÉ, of Paris.

Mr. X., forty-three years old, came to consult me in the month of October, 1890, complaining that for a long time he had not been able to see above the level of his eyes. When he stands in front of a person he discerns clearly the whole lower part of the body and the chin and lips, but the nose, the rest of the face, and head are completely invisible to him. To be able to see them, he is obliged to raise his eyes. What he perceives, however, is clearly seen. The acuteness of sight in the right eye is = 1 ; the eye is E ; the acuteness in the left one = $\frac{3}{4}$; the eye is H, 1.90. When examined with the perimeter, the superior part of the visual field in both eyes is wanting, and the limiting line comes near the point of fixation. Beyond this point it inclines slightly downward on both sides in each eye, but principally the right one, and on the same side[2] it shows in the third part of its course, nearest the fixing point, a slight depression, caused by the scotoma, which encroaches upon the preserved part of the visual field. It is not a mathematical line ; it is rather an intermediate and very narrow zone in which the sight is simply diminished. On the other side, towards the periphery, the two inferior halves of the visual field are in no way affected. The chromatic sense is well preserved, and the patient distinguishes perfectly the lightest shades of color.

Direct examination shows that the mobility of the ocular globes is perfect ; tension, normal ; the pupils react to light and accommodation. At the ophthalmoscopic examination no retinal

[1] This case has been related briefly at the meeting of the Association française pour l'Avancement des Sciences, September, 1891, and the patient was presented, October 29, 1891, at the Société de Médecine Pratique de Paris.

[2] The left side of the patient.

detachment; physiological excavation of both papillæ; vessels have their normal diameter in their entire course.

The patient has a marked diminution of smell; neither taste nor hearing are impaired; cutaneous sensibility is everywhere normal; no hysterical trouble. The knee-jerk is well marked on the right side; it seems weaker on the left. At the beginning of last year the patient had felt, for two months, a dull, persistent ache, with lancinating pains at night in his right leg, the real nature of which is to-day not easy to determine. No trouble in the gait. Three or four years ago Mr. X. felt on the street a giddiness in his head, which lasted but a few minutes, and has not since returned. Nothing in the heart nor in the urine.

The most important point to be mentioned is that six years ago the state of the visual field and acuteness of both eyes was exactly the same as to-day. At that period the disease had declared itself. It seems to have increased rapidly without any assignable cause. The patient consulted several of my Parisian colleagues, who took notes of the state of the field and acuteness of vision, and since that time nothing has changed.

I myself, since the month of October, have prescribed different remedies, and after several examinations I have always arrived at the same result. The right eye is E; V is always normal; the left eye is H, with $+ 1.90$; V is always $= \frac{3}{4}$.

As to his antecedents, it is to be observed that, except syphilis in the year 1879, the patient had never any serious disease. The father and mother died very old. No nervous disease in the family.

One would hardly find, I think, in literature many cases like the one I have just reported.

In the year 1869, Graefe said that occasionally one might see symmetrical contraction of the visual field above or below without any ophthalmoscopic signs, with a line of demarcation well traced, and preservation of the central acuteness. The observations which have been published since that time under the rubric hemianopsia superior are far from meeting these conditions, and even the related cases are also far from similar.

The cases of MM. Russell[1] and Knapp[2] do not fulfil the

[1] Russell, *Medical Times and Gazette*, No. 67, 1873.

[2] Knapp, "Hemiopic and Sector-like Defects in the Field of Vision and their Connection with Diseases of the Heart and Brain," *Archives of Scient. and Practice Med.*, No. 4, New York, 1873.

conditions mentioned. In the first, that of Russell, there was simply loss of the upper half of the visual field in the right eye, with paralysis of muscles. His right eye was first attacked by blindness, and then the left. The patient died, and at the autopsy a tumor was discovered in the bone at the base of the skull. In both of Knapp's cases there was certainly double hemianopsia downward, but with the ophthalmoscope in one case atrophy and in the other an inflammation of the optic nerves was found.

The case of Mauthner[1] met the required conditions: double hemianopsia above; no alterations in the fundus oculi; preservation of the central acuteness. In some points, however, this case is unlike mine. To be certain of this, one should not accept simple reports, but consult the original text of the observation.

A young man about twenty-two years, after having suffered violent pains in his head, swoons. Three days later he is up again. He complained of not seeing in the superior part of the visual field, particularly above and to the right side. His memory is weak; he has headaches frequently; he is often out of temper.

Two years after, the acuteness is still normal. Both the inferior parts of the visual field are preserved; they are separated from the blind parts by a curved line, which passes above the point of fixation. In the right eye, lower on the external side, it reaches the horizontal meridian. Six months after, there was an epileptic fit. These attacks returned every month for two years, and were consecutive during the third year. They then came back only at intervals of three or four months; then again monthly.

Three years and a half after the first perimetrical examination, it is remarked that the visual acuteness is the same, and this time the defects in the visual field are found re-established. The patient lived for two years longer, and one day about seven years after the superior hemianopsia had declared itself, he was found dead in his bed. The

---

[1] Mauthner, *Vortræge aus d. Augenheilkunde*, fasc. vi.–vii. (Gehirn und Auge. S. Hemianopsia).

autopsy, which did not take place under Mauthner's direction, remained without result.

My patient, in the beginning of his disease, never swooned; he never complains now of headache. The limiting line of his visual field of the right eye, as well as of the left, borders upon the point of fixation. The condition has not changed in six years. He never had an epileptic attack. Three years ago he felt a slight giddiness, which lasted but a few minutes.

Both cases of superior hemianopsia mentioned by Schweigger[1] are too briefly described to allow of a comparative study.

In the first case it is said only that by the perimetric examination of both eyes of a patient in the Charité Hospital of Berlin the visual field was found wanting in the superior part. The visual acuteness was almost normal. No ophthalmoscopic alteration. Later, on a new examination, it was found that to some extent there was not really an absolute loss of sight, but amblyopia merely.

The second case was a patient who was treated in February, 1876, for a visual trouble which began in December, 1876, in the left eye, the cause of which was attributed to hemorrhages of the retina near the macula lutea. The acuteness of the right eye has been impaired for three years in consequence of choroidal alterations, also near the macula lutea. At the same time Schweigger repeatedly found a loss of the visual field above, which the ophthalmoscopic alteration was not sufficient to explain.

Easy as it may appear, considering the anatomical and physiological facts, to attribute lateral homonymous hemianopsia to well-defined alterations, just so difficult is it to find the cause of a hemianopsia above or below. Several suppositions have been advanced.

Mauthner supposes that the nerve fibres, which are distributed in the inferior part of the two retinas, are found in the inferior part of the optic nerves, commissure, and tracts. If they are compressed from below upward, superior

[1] Schweigger, "Hemiopia und Schnervenleiden. Eine klinische Studie," *v. Graefe's Archiv*, Bd. xxii., pp. 276–323.

hemianopsia may result. Compression of the superior part of the optic nerves, tracts, and commissure would cause homonymous inferior hemianopsia; however, he says, if really in such hemianopsia the limiting line passed just through the fixed point (which it did not in this case), it would be absolutely impossible to explain the fact by the existence of compression at the base of the skull, because it would be difficult to admit that a tumor compressed the optic nerves from below upward or *vice versa*, so that the fibres which lead to the superior or inferior half would be fully compressed, while all the others remained intact. I have noted in my observation that for six years the limiting line borders upon the point of fixation and that the visual acuteness remains the same.

Schweigger does not admit that the superior hemianopsia was owing to a retinal hemorrhage, in the case of his second patient; he cannot attribute it either, considering the excellent general condition of the man, to a disease of the base of the skull. It is better to suppose, he goes on to say, that the cause of such condition is a disease of the two optic nerves, even when we cannot explain this fact by the existence of a manifest alteration in the fundus.

In support of his hypothesis, he quotes the symmetry with which in any disease of the optic nerves, such as progressive atrophy, alterations with progressive contraction of the visual field, and central scotoma, affect both eyes. I must ask: are such cases, especially the two first, which lead certainly to blindness, to be compared with my patient, in whom in a very short space of time half of the visual field was wanting, and then the disease remained stationary? How would alterations of both optic nerves be intelligent enough to progress with the same rapidity and to stop in the same moment?

It is said also that a superior homonymous hemianopsia could be produced by double symmetrical alterations of both occipital lobes. This may be admitted, but the clinician will accept this theory with diffidence.

There is another hypothesis which I have nowhere heard expressed and which would explain wonderfully well the

fact which I have already stated. If at first I hesitate to advance this, it is because, with my patient, a sensible diminution of smell was noticed at the same time that the superior hemianopsia was observed. The simultaneous appearance of both symptoms does not seem doubtful, and every one knows that the loss of smell is one of the principal signs of a disease of the base of the skull, one which should, especially at first, fix the attention in cases of heteronymous hemianopsia. But it is known that a false hemianopsia has very often an irregular evolution, and can as well recover as produce blindness of the one eye or both. Such hemianopsia is accompanied with other disorders and specially with paralysis of the third and fourth nerves. With my patient, the smell only is impaired. It might happen, indeed, that the specific disease which had attacked my patient, and which by its proteiform nature could cause so many various localizations and clinical peculiarities, had led to alterations producing here loss of smell and there homonymous superior hemianopsia.

One does not attribute to the loss of smell a particular significance.

My hypothesis is as follows: It is known that the optic tract of the right side furnishes a bundle going to the temporal part of the retina of the right eye and a crossed bundle going to the nasal part of the retina of the left eye; thus the optic tract of the left side gives a direct bundle to the temporal part of the left eye and a crossed bundle to the nasal part of the right eye; besides this, each tract is bound to the occipital lobe of the same side, and each occipital lobe is bound consequently to the two retinæ. In the binocular field, it is the left occipital lobe which looks to the right; it is the right occipital lobe which looks to the left. At present, admitting that by a simple anomaly of distribution one tract might send its crossed bundle and also its direct bundle to the superior halves of the two retinæ, and the other tract to the inferior halves, then one of the occipital lobes will look downward and the other will look upward. An alteration of the first lobe will cause superior hemianopsia; an alteration of the second lobe will cause

inferior hemianopsia. A superior or inferior hemianopsia might present, then, all the symptoms of the real hemianopsia; the homonymous, right or left hemianopsia. Such hemianopsias develop rapidly, to remain stationary. The visual acuteness is little or not affected at first; it does not grow worse afterwards; the limiting line of the visual field passes through the point of fixation; it is well known, however, that even in such cases one half may encroach slightly upon the other. Frequently there is no sharp demarcation between the blind and the seeing halves; there is a narrow zone in which the sight is only impaired. The ophthalmoscopic examination is negative. But I have observed all these facts in my patient, and I cannot insist too much upon the fact that he possessed them already six years ago. This case gave me the idea that I had before me a classical homonymous hemianopsia simply reversed, which was caused by an alteration of a single occipital lobe, the cause of which was a specifical disease. Certainly the hypothesis of an abnormal distribution of the nerve fibres to the two retinæ would explain the fact, which I have related, better than a compression of the optic nerves, commissure, or tracts, better than a double symmetrical disease of the optic nerves, or still a double and symmetrical change in both occipital lobes. It is for this reason that I felt myself authorized in presenting it.

FIVE CASES OF KERATO-CONUS TREATED WITH GALVANO-CAUTERY.

By H. KNAPP.

(*With a drawing.*)

IT is not my intention to discuss the different methods of treating kerato-conus, but simply to make public the manner and results of galvano-cautery with which I have operated on six eyes during the last three years.

CASE I.—*Advanced hereditary kerato-conus in both eyes. Galvano-cautery with perforation of the corneæ. Slow healing in the one; formation of cataract, cured by discission, in the other. Result good in both.*

Patient, a healthy young man, seventeen years of age, of Syracuse, N. Y., came to me July 8, 1889. His mother had kerato-conus in both eyes. The left had been operated on by the late Dr. C. R. Agnew, with paracentesis and excision of a piece of cornea. The healing had been very slow, owing to constant relapses of keratitis. The result was unsatisfactory. The son's disease began in his fourteenth year and was steadily progressing. When I saw him there was a marked conicity of both corneæ, the somewhat opaque apex being a little below the centre of the cornea. Fundi normal. He read Sn 1 no farther than 1″ before each eye. With his glasses R $\frac{2}{200}$, L $\frac{7-8}{200}$. Shading his eye he read R with $-\frac{1}{6}\ \frac{20}{200}$, L $-\frac{1}{6}\ \frac{20}{200}$.

The LEFT EYE was operated on at the N. Y. Ophthalmic and Aural Institute, Oct. 3, 1889. The eye, as all the others, was cocainized. A fine loop, brought to a red heat, was passed over the apex of the cone in an area of 2 × 3 *mm.* Then the centre

was pierced. Aqueous spurted forth in a jet. Patient remained in the hospital six weeks.

There never was an intense inflammation, but the wound closed and opened about seven times, the anterior chamber being restored 3-5 days, then empty 2-5 days. Some anterior synechiæ formed several times, but always ruptured again under atropia. In the fifth week the wound closed permanently, with a dense, sharply circumscribed scar below the centre of the pupil, free from synechiæ. Only weak glasses were accepted. There was still a good deal of ophthalmoscopic metamorphopsia. During six months the cornea flattened more and more. Then he read Sn 1 at a distance of 10″ fluently, and $\frac{20}{40}$ — with — $\frac{1}{9}$. In eighteen months his distance glass was — $\frac{1}{10}$; S $\frac{20}{40}$. He had one attack of a transient and mild keratitis eight weeks after the operation, in which the cornea was hazy and somewhat more bulging. Under pilocarpin and compressive bandage the attack soon disappeared without doing any damage.

Right eye. On account of the protracted healing of the left eye, I made only a very small perforation in the right. On Oct. 19, 1889, I cauterized the apex of the right conus in the same manner as I had done in the left, only I applied the point of the electrode repeatedly to the centre of the wound, until I saw the aqueous just ooze out. This more cautious but also more prolonged operation was followed by a severe and protracted reaction: pain in the eye, swelling of the edges of the upper lid, slight chemosis, anterior synechia, swollen and discolored iris, spongy exudation in the anterior chamber, which, when absorbed, left a peculiar yellowish opacity in the lower part of the pupil and behind the iris, opposite the scar from the cauterization.

A hypopyon, 1-2 *mm* in height, was present for three weeks. It had disappeared Dec. 3d. The other irritative symptoms gradually vanished, and the patient was discharged with a white sclera, normally curved cornea, having a sharply defined scar below the pupil. The eyeball, which at times had been soft, had resumed normal tension, and had good perception of light in every direction. The yellowish opacity in the pupil had been replaced by a grayish-white flat cataract, which I needled, Apr. 8, 1891. No reaction. Discharge in ten days. Secondary discission of the capsule, April 30, 1891. Discharge in a week with S $\frac{20}{70}$ +, by + $\frac{1}{34}$ + $\frac{1}{10}$ c 75.

Aug. 26, 1891, the patient's sight was R $+ \frac{1}{3} \frac{20}{60}$, L $- \frac{1}{10} \frac{20}{40} -$. In the autumn he passed his examination for Yale College and has pursued his studies there without any discomfort.

Remarks. I asked myself whether the protracted inflammation, irido-cyclitis, of the right eye, the unusual yellowish exudation opposite the scar, and the subsequent cataract had not been the effect of the heat transmitted from the red-hot electrode to the aqueous humor, iris, and lens. I have read, here and there, some words of warning, in this respect, but can say that I have employed galvano-cautery most extensively for years, and in some cases, for instance in sarcoma of the sclero-cornea, a great deal more intensely than in the above instance, without the slightest reaction. Yet in order to better judge of the effect of heat on the crystalline lens, I made a number of

EXPERIMENTS ON RABBITS.

First eye. Simple perforation in centre of cornea with galvano-cautery. Healing without reaction, leaving a well circumscribed, very small scar (1.5 *mm* in diameter).

Second eye. A strip of 8 × 5 *mm, deeply burned without perforation.* The strip filled up without reaction, leaving a superficial scar of very little intensity.

In burning, with a flat electrode, human corneæ from which I had removed pseudoplasms, I noticed that superficial cauterization left no scar, deep cauterization a thin scar. I found the reaction and cicatrization of these cauterizations surprisingly insignificant.

Third and fourth eyes. Central cauterization with cautious perforation. Healing without reaction. Wound closed in a few days, filling with gray tissue from periphery, leaving a well defined, circumscribed scar.

Fifth eye. Extensive burning, + 5 *mm* in diameter (*until aqueous escaped*). Wound open a week, iris applied to it. In three weeks a large, but well circumscribed scar. No anterior adhesion. Eye, apart from scar, healthy.

Sixth eye. Piercing cornea and lens capsule with galvano-cautery. Wound closed in a few days. Repair without inflammation.

Seventh eye. More extensive burning with piercing of cornea and lens capsule. Marked reaction. In a week the cornea was milky, in upper part vascular. The cauterized spot depressed, white in centre, a band of mucoid tissue, 10 *mm* long, hanging out of it. On fourteenth day cornea sloughing, eye suppurating.

Eighth eye. A round area, of 5 *mm* in diameter, was singed long in order to see whether heat produced cataract. No perforation. In a few days the wound was found clean, the anterior chamber shallow. Then intense iritis and partial suppuration of the cornea set in. On the fourteenth day, when the rabbit was killed, the eye was improving, but severely damaged.

These experiments showed that the reaction and the subsequent scar are proportionate to the extent of the cauterization. Moderate burnings, without or with perforation, healed kindly and left circumscribed scars. Extensive and prolonged cauterizations led to intense iritis, suppuration and sloughing of the cornea. These experiments, which give, so to speak, only a qualitative analysis of the problem, might be continued, determining with more precision and on a large scale the quantitative effect of galvano-cautery, with measurement of the size of the electrode, the influence of red and white heat and of the duration of the application, the depth and extent of the cauterization, and the effect of the perforation. Such experiments might give valuable practical results, not only for the treatment of kerato-conus, which is a comparatively rare disease, but for serpent ulcer, corneal pustule, hypopyon keratitis, and infected wounds.

Case 2.—Miss A. Sch., æt. thirty-two, of Denver, Col., presented herself May 1, 1891. Had had an ulcer in left cornea four years previously. Sight steadily worse ever since. Now marked kerato-conus in the left eye, slight in the right. The apex of the cone in the left eye was a little out and down from the centre of the cornea, and irregularly opaque. Ophthalmoscopic metamorphopsia and all other symptoms marked. Reads Sn 6 at 1″. R with $-18^{c}\ 80^{n}\ \frac{20}{30}\ -$.

Operation, May 8, 1891. Desirous to obviate prolonged and irregular cauterization, I had an electrode with an oval end plate,

3 × 2 *mm* made by E. B. Meyrowitz (see figure), which I applied cold to the apex of the kerato-conus, and withdrew it as soon as it had been brought to a red heat. Then I pierced the centre of

the eschar with a fine-pointed electrode. The operation was followed by no reaction, the wound closed in eight days, broke two days later by disturbance of the bandage, and closed definitely a day after.

The cornea flattened more and more. No synechia. When she left New York, eleven weeks after the operation, the corneal scar was still prominent, only there was but little ophthalmoscopic metamorphopsia. She read, by undilated pupil, Sn 2 at 3″, and with $-4\ \frac{20}{70}$. Later I heard from her oculist in Denver that she continued doing well. The other eye has remained *in statu quo.*

Case 3.—Mrs. Dr. W., æt. forty-six, New York, came in May, 1882, with a conical prominence of the R cornea, read 0.3 (J. 1) at 3″, with $-\frac{1}{4}\ \frac{20}{100}$. L eye normal. In May, 1884, the right eye had become worse and the left showed a slight prominence. with its S $-\frac{1}{18}{}^{c}\ 45^{n}\ \frac{20}{30}$. May 16, 1891, the left eye still had only a slight kerato-conus, but the right was so conical, and the apex in and below the centre so opaque that the vision was virtually abolished.

The operation on July 18, 1891, was performed as in the previous case, *viz.*, cauterization with the slightly convex, oval electrode, then piercing of centre of eschar with pointed electrode. No reaction. Anterior chamber restored in eleven days. During the next four weeks repeated attacks of increased eyeball tension relieved by pilocarpin. Extensive adhesion developed between the lower border of iris and the corneal scar. The scar became scarlet red (teleangiectatic adherent leucoma). The lateral and upper borders of the pupil were tied down to the lens by brown adhesions. Cornea slightly hazy, sight comparatively good, field of vision complete. *Aug.* 30*th.* Intense pain, nausea, + T1, not influenced by eserin and cocain. A hypodermic injection of morphia at the temple brought relief and sleep, and diminished the tension.

Sept. 1*st* I made a downward iridectomy, cutting with a lance-shaped knife from the lower corneal border clear through the

adherent iris, which I detached completely from the cornea. The prolapsed iris was seized and exsected. The operation was followed by no reaction and had the desired effect. The eyeball tension became normal, the pain disappeared at once, the iritis soon, and the red cap of the eschar was converted into a leucoma, the redness having diminished from the centre to the periphery. The cornea cleared up. The patient was discharged Sept. 8, 1891, having been in the hospital fifty-one days. She came to my office six weeks later. There was no irritation, the cornea had flattened, but the sight was only moderate. On my request she came again Sept. 16, 1892. She had had no discomfort from that eye. Central well defined macula corneæ. Natural pupil above and artificial below clear, no synechiæ. No metamorphopsia. Reads No. 1 at 4″; with $\frac{1}{4\frac{1}{2}}$ $\frac{20}{70}$.

The severe reaction in this, and in the second eye of the first case, induced me to operate the two other cases without perforating the cornea. In both the reaction was mild and the result excellent, but in each the cauterization had to be repeated.

Case 4.—Miss M. L., about thirty-six years of age, of New York City, consulted me Febr. 10, 1892. Four years ago both eyes began to fail, the left more rapidly than the right. She had kerato-conus in both. With the right she read J1 at $2\frac{1}{2}$″, with the left barely at 1″. In the left the somewhat opaque cone was slightly below and outward from the centre of the cornea.

Febr. 29, 1892, I applied the oval electrode to the apex of the cone and withdrew it as soon as it had become red. No reaction. The cornea flattened so that she could recognize the time of my watch at 10″. She was discharged three weeks after the operation with a threatening tendency toward a relapse of the conical protrusion of the cornea. At the beginning of April she read No. 1 only at $1\frac{1}{4}$″. The cauterization, repeated in the same place, was followed by no reaction. The patient left the hospital a week later. The cornea flattened and sight improved steadily. May 4th she read No 1 at $3\frac{1}{2}$″. June 14th at 4″; with − 4.5 D $\frac{20}{70}$. The scar is sharply circumscribed. Sept. 17th, 1892, when she came again, she told me that the eye had given her no discomfort. Scar covering lower half of pupil. Semitransparent in ophthalmoscopy, some metamorphopsia through it, none

through upper part of pupil. S No. 1 at 10″; $\frac{20}{60}$ without glasses. With glasses no improvement.

CASE 5.—Miss M. D., æt. twenty, of Tacoma, Wash., consulted me Mch. 8, 1892. Kerato-conus both, L more than R. L J1 at 1″, R J1 at 3″. High degree of OS metamorphopsia, and frequent pain in the depth and the surroundings of the eye.

March 10th, oval electrode applied to apex of cone in left eye, a little below centre of cornea, withdrawn when brought to red-heat. Great pain in eye the first night. Some swelling of conjunctiva and edge of upper lid. Eschar as usual. Cornea and iris unaffected. From second day freedom from pain. No reaction in wound; cornea flattening rapidly. She saw time at watch at 10″ and farther, counted fingers across the room. In the second week, cornea began to protrude again, and S diminished. March 23d, J1 at 2½″. *Cauterization repeated.* Pain the first night. No discomfort later. Healing without reaction. Scar in cornea sharply defined, encroaching on the lower third of the pupil. Ophthalmoscopic metamorphopsia disappeared. Flattening of the cornea and improvement of sight continued for three months. She was discharged from the hospital April 4th, and left the city at the beginning of July. When examined at that time she read with the operated eye J1 at 10-12″, and saw $\frac{20}{30}$ with $-3.D - 1._{c}\,25^{n}$. I am informed by her physician that this good condition has remained.

REMARKS.

These six operations are, it seems to me, not without suggestive value. Galvano-cautery, at the present time, appears to be in greater favor than any other method, particularly in England. Yet, like all other procedures, it has its great dangers. If the cauterization is only superficial, or consists in a mere perforation of the apex, it is insufficient and has to be repeated.[1] If the cauterization is deep, especially with a larger perforation, the closure is slow, and the inflammation and its consequences may be more or less severe, including sloughing of the cornea. Anterior and posterior

[1] See two cases recently operated on in this way by a pupil of mine, Dr. R. D. Gibson, of Youngstown, O. Reported *Jour. Am. Med. Assoc.*, Sept. 10, 1892.

synechiæ are not infrequent, and may require an iridectomy, which also for optical purposes may be desirable in some cases. The removal of a piece of the protruding cornea by excision or trephining may yield good results—I have not learned in what percentage,—but I know, not from my own experience, that eyes have been lost by panophthalmitis following this procedure. The cauterization, which acts by the contraction of the cicatrix, seems to be the safest method. Galvano-cautery is, in my opinion, preferable to the lunar caustic of Von Gräfe. Perforation of the cornea with its consequences, anterior and posterior synechiæ, may be avoided, as our last two cases show. Better to cauterize carefully and, if relapses occur, repeat the operation on the same place. The scar is well circumscribed and an iridectomy useless. The oval electrode seems a good instrument. The last case is a particularly remarkable example of smooth healing and almost perfect success in the treatment of this dreaded disease.

SYSTEMATIC REPORT ON THE PROGRESS OF OPHTHALMOLOGY DURING THE THIRD AND FOURTH QUARTERS OF THE YEAR 1891.

By Dr. ST. BERNHEIMER, in Vienna; Prof. Dr. HORSTMANN, in Berlin; and Dr. SILEX, in Berlin.

WITH THE CO-OPERATION OF

Dr. S. M. Burnett, Washington; Dr. Dantone, Rome; Prof. Dr. Hirschmann, Charkow; Dr. E. Marckwort, Antwerp; Dr. P. von Mittelstädt, Metz; Dr. Werner, Dublin; Dr. C. H. A. Westhoff, Amsterdam; Dr. Schiötz and Dr. Ole Bull, Christiania; and Dr. Deus, Berlin.

Translated by Dr. Jas. A. Spalding.

Sections XII.–XXI. Reviewed by Dr. P. SILEX.

XII.—IRIS.

431. Smith, Eugene. Treatment of irido-dialysis from contusions. Partial iridenkleisis with or without rupture. *Journ. Amer. Med. Ass'n*, Sept., 1891.

432. Purtscher. On a new form of anterior synechia following blunt force. *Centralbl. f. Augenhlkde.*, vol. xv., p. 327.

433. Herrnheisser. On serous cysts of the iris. *Prager med. Wochensch.*, 1891, p. 269.

434. Charnley. A rare tumor of the iris removed by operation. *Brit. Med. Jour.*, Sept., 1891, p. 591.

435. Despagnet. Tubercle of the iris. Spontaneously cured. *Cong. franç. d'Ophtal.*, May 5, 1891.

436. Gillet de Grandmont. Syphilis or tuberculosis of the iris. *Soc. d'Ophtal. de Paris*, 1891, June 2d.

437. Roy. Syphilitic iritis with statistics. *Ophth. Rec.*, Sept., 1891.

438. Schenk. Ice in iritis. *Journ. Ophthal., Otol., and Laryngol.*, Oct., 1891.

439. Bissell. Spasm of the ciliary muscle. *Journ. of Ophth., Otol., and Laryngol.*, Oct., 1891.

440. Cassedy. Congenital corectopia. *Journ. Ophth., Otol., and Laryngol.*, July, 1891.

In cases of detachment of the iris at the periphery as the result of a blow, Smith (431) makes an incision into the cornea above the site of the prolapse, and introducing a pair of iris forceps, draws the detached edge of the iris into the incision, which usually holds it in place; should it not be retained, a delicate suture can attach it to the neighboring conjunctiva. Three cases have been so treated. Burnett.

Purtscher's case (432) was one of an extensive and almost circular, though somewhat irregular, synechia, united with the cornea. The pupillary margin and the periphery of the iris were perfectly free, and the cornea intact.

Herrnheisser (433) reports two clinical cases, and gives a detailed view of all the theories concerning the origin of iris cysts. The original cause of those that appear spontaneously is still obscure.

Charnley's patient (434), a boy of sixteen, had a small unpigmented neoplasm on the interior and inner margin of the pupil. This was removed by an iridectomy, and proved to be a very vascular tumor, which had become sarcomatous. Werner.

Gillet de Grandmont (436) declares that it is impossible, from condylomata of the iris, and, on the whole, from the ocular disease itself, to decide whether the case is one of tuberculous or of syphilitic origin. There are many exceptions to the general law that the syphilitic condylomata lie upon the pupillary margin, and the tuberculous upon the peripheral portion of the iris. He cites a case in which he was sure from the history that syphilis was at work, yet in which the autopsy demonstrated tuberculosis. Marckwort.

In the Charity Hospital in New York, Roy (437) found, among 61 patients admitted for syphilis, from February 15th to April 1st, 14 who had iritis—5 women and 9 men. Burnett.

Schenk (438) has found the constant application of ice most

beneficial, not only in the traumatic but also in the idiopathic form of iritis. BURNETT.

CASSEDY (440) reports a case of corectopia in which the pupil was drawn downward and inward. No coloboma of choroid, or any other bodily deformity. He has a son who is similarly affected in the left eye. BURNETT.

XIII.—CHOROID.

441. SATTLER. A case of bacillus panophthalmitis. *Ber. d. Ophth. Ges. zu Heidelberg*, 1891. *Archiv. f. Augenhlkde.*, vol. xxiv., 2, p. 72.

442. STORY. Detachment of the choroid. *Trans. Ophth. Soc. U. K.*, vol. xi., p. 127.

443. LEBER. On the coincidence of disseminated choroiditis and hemorrhagic retinitis, or retinal hemorrhages, in the same eye. *Festschrift zur Feier von Helmholtz*, 1891.

444. CARPENTER. Tuberculosis of the choroid; a further contribution. *Brit. Med. Jour.*, July, 1891, p. 66.

445. KNAPP. Contribution to the tuberculosis question. *v. Helmholtz Festschrift*, 1891.

446. LEBER. On weakened tuberculosis of the eye. *Ber. d. Ophth. Ges. zu Heidelberg*, 1891. *Arch. f. Augenhlkde.*, vol. xxiv., 2, p. 68.

447. HAAB. Some rare ophthalmoscopic images. (1) Chronic tuberculosis of the choroid. (2) Specific arterial disease of the retina. *Festschrift v. Helmholtz*, 1891.

448. HILL-GRIFFITH. The prognosis of choroidal sarcoma. *Ophth. Rev.*, vol. x., p. 353, and *Brit. Med. Jour.*, Sept., 1891, p. 590.

449. LAWFORD and COLLINS. Sarcoma of the uveal tract, with notes of one hundred and three cases. *Royal London Ophth. Hosp. Rep.*, vol. xiii., p. 104.

450. SAMELSOHN. Metastatic carcinoma of the choroid. *Deutsch. med. Wochensch.*, 1891, p. 927.

451. UHTHOFF. On the doctrine of the metastatic carcinomata of the choroid. *Festschrift Virchow*, vol. ii. Berlin, Hirschwald, 1891.

452. WOOD, T. H. Ossification of the choroid. *Ophth. Rec.*, July, 1891.

STORY'S (442) patient, a man of twenty-seven, reported that when a child he had received injuries on both orbits, but no direct injury of the eyes themselves. Both eyes revealed extensive detachment of the retina, beneath which, with the same convex lens, the stroma of the choroid could be distinctly seen.

WERNER.

LEBER (443) is of the opinion that, in the cases in question, the damage, which is mainly to be sought for in microbic excitation, may have been carried into the eye by means of the blood-vessels or lymphatics. The picture varies, depending upon whether the choroid or the retina is affected. In the latter case we find plugging of the vessels, circulatory disturbances and hemorrhages, whilst in the former, owing to the numerous anastomoses, inflammatory alterations (choroiditis adhæsiva) predominate. Two cases are closely described. Occasionally the extravasations are so extensive that they bear great resemblance to the recurrent vitreous hemorrhages in young persons, in whom he was repeatedly able to establish the seat of the hemorrhage in the retina.

CARPENTER'S (444) cases were two each of general and of localized tuberculosis. The tubercles of the choroid were seated near the papilla and macula, and varied in size, one of them being several papilla-diameters across. They were gray and pale, and slightly elevated. WERNER.

HAAB (447) calls attention to the fact that syphilitic disease of the arteries may be confused with sclerosis of the arteries, with retinal striæ after chronic chorio-retinitis, and with obstruction of an arterial branch by an embolus.

GRIFFITH (448) reports the case of a man of sixty, whose eye was enucleated in a glaucomatous condition owing to an intra-ocular tumor, and who was affected with metastasis in the liver on the sixty-second day, and finally died about one year after the first symptom of failing vision. There have been seen at the Eye Hospital in Manchester in the last eight and a half years 40 cases of choroidal sarcoma ; 25 in men and 15 in women. The percentage of such cases amongst all the eye cases seen in the hospital was 0.03. Fourteen of the 40 cases were alive from 3 to 10 years after the operation of enucleation, and can therefore be regarded as definitely cured (?—H. K.). Six died of diseases of the internal organs, and in 3 the cause of death was a matter of doubt. The remaining cases could not be followed. This gives 60 per cent. of recoveries. Griffith believes that the time at

which the enucleation is performed is of but little, if any, influence upon the metastasis. WERNER.

The cases of sarcoma of the uveal tract collected by LAWFORD and COLLINS (449) were, with a few exceptions, treated at Moorfields. Amongst the 103 cases there were 59 men. The average age was 48 ; the youngest 15, the oldest 84. Fifty per cent. of the cases with increased tension, and 34 with tension not increased died. Six tumors of the ciliary body, 2 of the choroid and ciliary region, and 1 of the iris were observed. There was no constant relation between the form and arrangement of the cells and the further course of the case. Of 79 cases which could be followed, 39 remained alive, 20 for more than 3 years after the removal of the neoplasm, which gives 25 per cent. of recoveries. Eight that were followed up to the time of their death lived more than 3 years after the operation. Of the 26 patients who died from metastasis, the average duration of life after the operation was 2 years and 7 months. Of 79 cases observed for some time after the operation, 7 had local relapses, and all of them died. An injury could be traced in 5 cases, and in 6 the eye was blind from some other cause.

In WOOD's case (452) a woman of twenty-seven had lost the left eye from inflammation when five years old. Eye more or less painful at times ever since. Some symptoms of sympathetic irritation in R, which caused the left to be enucleated. On examination the inner layer of the choroid was found to be replaced by a shell of bone, pierced behind for the admission of the head of the optic nerve. The shell extended forward to near the equator. Retina detached ; lens displaced and calcareous. Sympathetic irritation subsided. BURNETT.

XIV.—GLAUCOMA.

453. CROSS. Hydrophthalmus. *Trans. Ophth. Soc. Unit. Kingd.*, vol. xi., p. 224.

454. JULER. Double congenital buphthalmus. *Trans. Ophth. Soc. Unit. Kingd.*, vol. xi., p. 240.

455. KALT. Pathological anatomy of buphthalmus. *Cong. franç. d'Opht.*, May 5, 1891, and *Ann. d'Ocul.*, vol. cv., p. 225.

456. KNIES. Glaucoma simplex. *Ber. d. Ophth. Ges. z. Heidelb.*, 1891, and *Archiv. f. Augenhlkde.*, vol. xxiv., No. 2, p. 69.

457. RANDOLPH. Hemorrhagic glaucoma, with an analysis of three cases. *Jour. Amer. Med. Assoc.*, Sept., 1891.

458. COLLINS. On the operative treatment of glaucoma. *Royal London Ophth. Hosp. Rep.*, vol. xiii., p. 166.

459. WAGNER. On the question of the curability of glaucoma. *Wjestnik Ophth.*, 1892, No. 3.

460. LLOYD. An acute glaucomatous attack in the right eye of a colored man, æt. twenty-four. Left eye destroyed six years previous by a pistol-ball. Removal of eye. *Amer. Jour. Ophth.*, July–August, 1891.

461. DE SCHWEINITZ. Perimetric observations on the influence of eserine and iridectomy in chronic glaucoma. *Jour. Amer. Med. Assoc.*, Sept., 1891.

CROSS (453) gives profuse literary references, and mentions seven different cases of hydrophthalmus, and one case of glaucoma in a patient aged twenty-seven.

JULER (454) performed paracentesis in an eye, with slight improvement. The cornea of the other eye was already perforated, and enucleation was performed. The results of the examination are detailed. WERNER.

According to KALT'S anatomical investigations (455) buphthalmus is the sequence of a chronic irido-choroiditis, which leads to a gradual obliteration of the vessels of the uveal tract. The obstruction of the largest portion of the choroidal capillaries increases the pressure in the ciliary arteries, from which arises increased transudation of fluid. MARCKWORT.

RANDOLPH (457) reports three cases of typical hemorrhagic glaucoma, which he has treated with iridectomy and paracentesis. The results were so successful that he concludes that iridectomy is not, as is generally held, a *contra*-indication, but, on the contrary, useful in giving temporary, at least, and in many cases a permanent relief. He would follow the iridectomy up with paracentesis for relief of subsequent symptoms. BURNETT.

COLLINS' paper (458) describes the results of the examination of 23 eyes which had to be enucleated after glaucoma operations. Micro-photographic illustrations are appended. In every case of iridectomy the incision was oblique, especially when a keratome was used. In only 2 cases was the ligamentum pectinatum injured by the incision. In every case but 4 there remained a bit of iris standing, which with one exception was adherent to the

cornea. In 2 cases in which sclerotomy had been done, cystoid cicatrices, filled with atrophic iris tissue, were discovered. The author advises an early operation before any adhesion originates between the iris and cornea. WERNER.

WAGNER (459) opposes the pessimistic views of Logetschnikoff, and considers that a carefully performed iridectomy is positively curative, even in glaucoma simplex or hæmorrhagicum.

HIRSCHMANN.

In LLOYD'S case (460) an acute glaucoma developed in an eye whose fellow had been lost six years before. The lost eye was removed, and the glaucoma disappeared with no other treatment than eserine. He considered it due to sympathetic influence.

BURNETT.

DE SCHWEINITZ'S cases (461), four in number, while carefully reported, do not throw a great deal of light upon the question of how to deal with what is called chronic simple glaucoma. In the cases reported, the visual field was somewhat enlarged under the use of eserine or pilocarpine in weak solutions, and in one instance an iridectomy was done. But in nearly all of the cases tonics, and especially strychnia, were used internally. BURNETT.

XV.—SYMPATHETIC OPHTHALMIA.

462. BRAILEY. On sympathetic ophthalmia. *Verhand. d. XI. Int. Med. Cong.*, 1890, vol. iv., 4, p. 109.

463. TROUSSEAU. A case of sympathetic ophthalmia occurring despite resection of the optic nerve. *Soc. Opht. de Paris*, April 7, 1891.

464. HIRSCHBERG. Sympathetic blindness permanently cured. *Centralbl. f. prakt. Augenhlkde.*, vol. xv., p. 289.

465. BOÉ. On sympathetic ophthalmia. *Cong. Franç. d' Opht.*, May 5, 1891, and *Rec. d'Ophtal.*, 1891, p. 336.

466. MANARA. Sympathetic ophthalmia. Rome, Marianie, 1891.

467. SCHMIDT-RIMPLER. A contribution to the origin of sympathetic ophthalmia. *Ber. d. Oph. Ges. zu Heidelberg*, 1891, and *Archiv. f. Augenhlkde.*, vol. xxiv., 2, p. 70.

TROUSSEAU'S case (463), of sympathetic ophthalmia despite a previous resection of the optic nerve, was discussed before the Ophthalmological Society of Paris. Wecker attempts to defend

the resection of the optic nerve. Sympathetic ophthalmia has also been observed after enucleation. Meyer is of the opinion that Trousseau's case is a powerful argument against resection. Despagnet, Gorecki, and Parinaud had seen a favorable influence upon, and even a rapid cure of, the sympathetic inflammation after enucleation, even when the sympathy had already been well marked for ten days or even several weeks before the enucleation. Boucheron also was very emphatically in favor of the therapeutic as well as of the prophylactic value of enucleation. MARCKWORT.

HIRSCHBERG'S patient (464) had suffered with a perforating corneo-scleral injury of the left eye. About six weeks later iridochoroiditis of the fellow eye ensued. Enucleation of the left eye; inunction and darkness treatment; atropine. At one time increased tension; later decrease of the same. Twelve weeks later blindness by increased tension. The blindness gradually diminished, and vision increased to $\frac{1}{8}$. The vision later increased so much that the patient is hard at work as a carpenter. The iris is of course adherent, the optic papilla discolored, and the choroid exhibits patches. Iridectomy was not performed.

BOÉ (465) carried out a series of experimental investigations in regard to panophthalmitis. He also watched to see if sympathetic ophthalmia would appear, but never discovered any trace of the same. Even the optic nerves, when microscopically examined, were quite normal. Boé thinks that Deutschmann's investigations fail to prove that the sympathy is a migratory ophthalmia. Deutschmann's experimental animals all died from general infection. Hence it was a matter of course that micrococci were discovered in the optic nerves. MARCKWORT.

MANARA (466) has made numerous experiments on rabbits to discover the propagation paths of sympathetic ophthalmia, but failed to find any confirmation of Deutschmann's views. Vitreous inoculation of staphylococcus aureus and albus and streptococcus pyogenes, in healthy as well as in eyes irritated by the introduction of an aseptic body, produced the unvarying infectious inflammation. But the healthy eye invariably remained normal, and not a trace of micro-organisms could be discovered in the optic-nerve sheaths of the inflamed eye. The proof was attempted with cultures, as well as with the aid of the microscope. The author therefore believes that the healthy eye will only be affected when a general constitutional effect has been produced by the inoculation. DANTONE.

XVI.—VITREOUS.

468. VAN DUYSE. Persistence of Cloquet's canal. Remains of the fœtal hyaloid system. Coloboma of the optic nerve. *Arch. d'Opht.*, vol. xi., 5, Oct., 1890, p. 404.

469. PRICE. Persistent hyaloid artery. *Ophth. Record*, Aug., 1891.

470. COLLINS. A late epithelial implantation cyst in a shrunken globe twenty-eight years after the receipt of the injury. *Trans. Ophth. Soc. Unit. Kingd.*, vol. xi., p. 133.

471. HIRSCHBERG. Bloody myodesopsia. *Centrabl. f. Augenhlkde.*, vol. xv., p. 242.

VAN DUYSE (468) observed in the left eye of a patient, aged nineteen, the persistence of Cloquet's canal and remains of the hyaloid artery. Whilst all the hitherto reported cases of Cloquet's canal were observed in *both eyes*, and the hyaloid artery in one eye only, here were found both anomalies in the *one eye*, and the other eye was absolutely normal. Together with the canal arising from the neighborhood of the papilla, and enclosing the remnants of the vessel, which passed through the vitreous, but did not attach itself precisely to the centre of the posterior of the capsule of the transparent lens, but a little to one side, there were visible: (1) a white disk covering the papilla and its vessels, which, directed downward and outward, resembles at its lower extremity a choroidal coloboma, and is surrounded with choroiditic patches; (2) a coloboma of the optic-nerve sheath, in the form of a conus upward. The author describes all with many details, and makes comparisons with the cases hitherto reported.

MITTELSTÄDT.

PRICE (469) reports an interesting case of persistent hyaloid artery, in which the vessel could be followed from the central retinal artery to the rear of the posterior lens capsule, where it spread out in ramifications not unlike those of the retinal vessels. The other eye contained traces of a hyaloid artery.

BURNETT.

In COLLINS' case (470) the eye was enucleated twenty-eight years after an injury. A large cyst occupied nearly the whole of the interior of the globe. It was lined with pavement epithelium, and extended as far as a cicatrix in the cornea. WERNER.

XVII.—LENS.

472. BRAILEY. On some points in the development of cataract. *Trans. Ophth. Soc. Unit. Kingd.*, vol. xi., p. 66.

473. FUCHS. On lens precipitates. *Beitr. z. Augenhlkde.*, Heft iii., Hamburg.

474. MULES. Anterior central capsular and pyramidal cataracts; their pathology. *Trans. Ophth. Soc. Unit. Kingd.*, vol. xi., p. 70.

475. RISLEY. Incipient cataract; its etiology, treatment, and prognosis. *Ophth. Rev.*, vol. x., p. 225.

476. SCHIRMER. On the pathological anatomy and pathogenesis of central cataract. *v. Graefe's Archiv.*, vol. xxxvii., 4, p. 1.

477. WILSON, H. Hereditary congenital cataract. *Jour. Ophth., Otol., and Laryngol.*, Oct., 1891.

478. UHTHOFF. Examination of the visual learning of a child of seven, born blind, but successfully operated. *v. Helmholtz Festschrift*, 1891.

479. MACNAMARA. The treatment of infantile cataract. *Brit. Med. Jour.*, Sept., 1891, p. 589.

480. DUB. Contribution to the knowledge of zonular cataracts. *v. Graefe's Archiv.*, vol. xxxvii., 3, p. 26.

481. WRAY. Points in the treatment of lamellar cataract. *Ophth. Rev.*, vol. x., p. 263.

482. COLLINS. Extensive rupture of the posterior capsule of the lens following a blow on the eye from a stone. *Trans. Ophth. Soc. Unit. Kingd.*, vol. xi., p. 126.

483. HAAB. Remarks on cataract operations. *Beit. z. Augenhlkde.*, vol. iii., Hamburg, 1891.

484. CROSS. Iridectomy or no, in cataract extractions. *Brit. Med. Jour.*, 1891, p. 472.

485. BARR. Extraction of incipient cataract. *N. Y. Med. Rec.*, Dec. 12, 1891.

486. MURELL. To what extent are personal restraints essential during healing of corneal wounds? *Amer. Jour. Med. Assoc.*, Aug. 29, 1891.

487. ROSMINI. One hundred and nine simple extractions. *Boll. d'Ocul.*, vol. xiii., p. 13.

488. NIKOLJUKIN. Report of ninety-seven cataract extractions. *Westjn. Ophth.*, May and June, 1891.

489. MACNAMARA. Address in section of ophthalmology at British Medical Association meeting, 1891, on certain points in ophthalmic practice. *Brit. Med. Jour.*, 1891, p. 251.

490. BERRY. Note on an unusual result of cataract extraction. *Trans. Ophth. Soc. Unit. Kingd.*, vol. xi., p. 152.

491. MARTIN. A post-operatory complication of a Morgagnian cataract. *Soc. Opht. de Paris*, Nov. 3, 1891.

492. SANTOS FERNANDEZ. On a possible, but remedial, accident in keratotomy. *Rev. Gén.* 1891, p. 337.

493. GAUPILLAT. New device for bandaging after simple extraction. *Rev. Gén. d'Opht.*, 1891, p. 939.

494. PARINAUD. Prolapse of iris in simple extraction. *Rec. d'Opht.*, 1891, p. 321.

495. GAYET. Essay on the investigation of the acuteness of sight after the operation for cataract. *Festschrift v. Helmholtz*, 1891, p. 62.

496. OSTWALT. A few words on the correction of aphakia with lenses. *Zehender's Monatsblaetter*, 1891, p. 223.

497. KNAPP. The treatment of the capsule during and after the extraction of cataract. *Trans. of the Xth Int. Med. Cong.*, vol. iv., 4, p. 1.

498. SMITH, E. How shall we treat the capsule? A new cystitome forceps. *Jour. Amer. Med. Assoc.*, Nov., 1891.

499. POOLEY. Operation for secondary cataract, with subsequent iridocyclitis and glaucoma. *Amer. Jour. Ophth.*, Dec., 1891.

500. THOMPSON. Note on Foerster's artificial ripening of cataract. *Royal London Ophth. Hosp. Rep.*, vol. xii., p., 33.

501. SEABROOK. The natural course of cataract. *Med. Rec.*, Sept. 12, 1891.

502. RODES. Spontaneous extraction of a cataractous lens. *Jour. Ophth., Otol., and Laryng.*, July, 1891.

503. FROTHINGHAM. Remarks on the need of more efficient protection of the eye after cataract extraction, and an improved apparatus for the purpose. *Jour. Amer. Med. Assoc.*, Aug. 29, 1891,

504. JACKSON. Pressure on the globe after cataract extraction. *Jour. Amer. Med. Assoc.*, Aug. 29, 1891.

BRAILEY'S paper (472) contains statistics derived solely from private practice. He finds that 7 per cent. of patients exhibited lental opacities. In 14 per cent. of all the cataract cases, at least one lens was sufficiently mature for extraction. The majority seem to undergo little change for the worse. Of 30 such cases observed from three months up to eight years, 14 remained absolutely stationary; 4 got slightly better. The slight improvement sometimes remains permanent. Nuclear cataracts progress in spite of any precautions, while peripheral cortical ones may be to a certain extent checked by rest and hygienic measures. The latter form is generally accompanied with distress on using the eyes. WERNER.

MULES (474) concludes that pyramidal cataract is an unabsorbed portion of capsulo-pupillary membrane. He relates an instance in which remains of pupillary membrane adhere to such a cataract, and alludes to the fact that in a great many cases no trace of opacity can be detected in the cornea, which could scarcely be the case if it had been ulcerated. Mackinley observed that in nearly all these cases there was a history of purulent ophthalmia. WERNER.

From a study of his cataract cases RISLEY (475) concludes that, whilst opacity of the lens is a disease of advanced life, it does not in all probability depend upon senile changes, but originates in local pathological conditions involving the nutrition of the eye itself. This disease is usually a form of choroiditis, and it is facilitated by uncorrected ametropia. BURNETT.

SCHIRMER (476) examined five cases of central cataract, *i. e.*, small, knobby, intensely white or yellow, translucent or opaque, centrally situated congenital opacities. Clinically these cataracts are likely to be confounded with thick zonular cataracts. Anatomically it appears that both are undoubtedly zonular cataracts with delicate opacity of the nucleus. Adjacent to the transparent cortical layers, lies an oval band of minute drops, which encloses the sharply defined nodule embracing in its fissures a coarsely granular mass. Central cataract is referred to an unknown intra-uterine influence, which leads to the appearance of drops amid the fresh fibres, around which, later, transparent lens substance is deposited.

WILSON (477) gives the history of hereditary cataracts in the

descendants of one who suffered from this affection. Of the 31 descendants to the fourth generation, 16 were affected with congenital cataract, males and females in equal proportion.

BURNETT.

MACNAMARA (479) expresses the opinion that in children the operation for cataract should be undertaken as soon as the child has finished teething. Needling, with subsequent linear extraction was the method that he invariably employed. McHardy also believed in the early operation, as there was less resulting irritation in young children. He had abandoned suction, as he found it unnecessary. The presence of peripheral striæ in zonular cataract indicated, in his opinion, a progressive tendency. Argyll-Robertson had also abandoned suction. In many cases he performed iridectomy or iridodesis.

After a series of measurements, DUB (480) came to the conclusion that lamellar cataracts, or at least a large majority of the same, originate in the first months of life, or even are of intra-uterine origin.

According to WRAY (481) operation for cataract should not be delayed in infants if a coarse view of the fundus is not possible under atropine. Discission is advisable up to thirty-five years of age. In a large number of cases, uniocular operations suit the patients' requirements best.

In COLLINS' case (482) the eye was enucleated for a perforating wound with prolapsed iris. Although the lens was perfectly clear, a large rent, with protrusion of lens fibres, was found in the posterior capsule a week after the injury. WERNER.

The most important point to be gained from HAAB'S paper (483) is that he operates on cataract patients affected with dacryocystoblennorrhœa, after completely occluding the puncta with the galvano-cautery, and strewing pulverized iodoform into the conjunctival sac. He exercises the greatest precautions to procure the most exact asepsis and antisepsis.

CROSS (484) is convinced that healing takes place more rapidly under simple extraction. In 62 cases iridectomy was performed six times to facilitate the extraction. There were 5 cases of prolapse or protusion of vitreous, 4 prolapses of iris, and 11 anterior synechiæ, 5 of the latter being very slight. No suppuration. Two cases of hypopyon, which recovered. Two slight cases of iritis.

BARR (485) gives statistics of fourteen successful extractions

of incipient cataract. He always removes a large portion of the anterior capsule. BURNETT.

MURELL (486) believes in allowing cataract patients the greatest liberty after the operation. He operates in his office, and allows the patients to walk home. The patient is not confined to bed, nor is the unoperated eye closed. This plan followed for two years has not been interfered with by any serious accidents. BURNETT.

From ROSMINI'S (487) paper we learn that in 109 cataract extractions he has operated, without iridectomy, on 6 that were immature, and with good success.

Fifty-eight extractions with the capsule (13 times with a large and 15 times with a small loss of vitreous) gave NIKOLJUKIN (488) good vision in 31 per cent., moderate in 48 per cent., fingers from 2 to 4 *m* in 17 per cent., and S = 0 in 3½ per cent. In 39 other extractions he had considerable loss of vitreous twice, and slight loss three times, occlusion of the pupil once, panophthalmitis once, and secondary cataract twice. HIRSCHMANN.

MACNAMARA'S (489) address includes remarks on the extraction of immature cataract, and hypermetropia in relation to glaucoma. He mentions 3 cases of optic neuritis as a consequence of the influenza, one patient becoming blind from optic atrophy. WERNER.

BERRY'S patient (490) had an epileptic seizure the first night after the operation, which led to intraocular hemorrhage, pain, nausea, and vomiting. There was an escape of fluid vitreous during the extraction. WERNER.

MARTIN (491) operated upon a Morgagnian cataract in the following manner: section in the limbus, small conjunctival flap, and equatorial opening of the capsule. The moment that this step was accomplished, the lens shot out of the eye with such force that it flew an entire metre. Although after the operation the sphincter was free, three days later a hernia of the iris had to be snipped off. The recovery was extremely slow, with the formation of a large cystoid cicatrix. The explanation of this curious case was not discovered till seventeen years later, when the same patient came for an operation on the other eye, which was totally blind from absolute glaucoma. Martin made an iridectomy on this eye at once, but on the following day found the lens lying in the incision, and thereupon removed it without any difficulty. MARCKWORT.

SANTOS FERNANDEZ (492) describes the routine to be followed when, by an error in cases of extraction, the narrow v. Graefe knife is inserted with the back upward. He urges that the knife should not be withdrawn, but turned around *in loco.*[1]

GAUPILLAT (493) affirmed in the beginning of his paper that prolapse of iris had decreased since the re-introduction of Daviel's extraction without the iridectomy. (He is here in opposition to most of the French oculists, who urge as one of the chief disadvantages of simple extraction the greater frequency of prolapse of the iris.—Reviewer.) The stress of Gaupillat's article is laid on the best way of applying the bandage. The wadding should only be laid upon the upper lid, and upon this only, so far as just to cover the eyelashes. In this way he asserts that prolapse of iris is best avoided. MARCKWORT.

According to PARINAUD (494), the chief arguments against simple extraction are the greater difficulty in removing the cortical masses, the greater percentage of secondary cataracts, and the greater ease with which the iris prolapses. If the iris does not remain perfectly round after the extraction, or after it has been replaced with the spatula, we should not hesitate to make an iridectomy. If there is a secondary prolapse, we can do an iridectomy twenty-four hours after the extraction. But later the prolapse should be destroyed with the galvano-cautery.

MARCKWORT.

OSTWALT (496) urges, with Dimmer, that when we are obliged to order compound lenses after an extraction the cylinder should be placed nearest to the eye.

KNAPP (497) prefers the so-called peripheral opening of the capsule, because in this way the pupillary field continues free of inflammatory products, and the remaining capsule is better suited for the secondary discission. The latter he performs, when necessary for improved vision, just as soon as the globe is free from irritation, anywhere from three to seven weeks after the primary extraction, and he does this with a needle-knife in the form of a T-shaped or cruciform incision of the capsule by artificial illumination. The operation, with proper antisepsis, is free from danger, and generally doubles the amount of vision.

SMITH'S (498) forceps are a modification of Knapp's, there being three or four teeth instead of four to five, and these are

[1] This accident has occurred a few times, and was remedied by simple turning of the knife. No reaction followed. Compare my earlier reports.—H. K.

sharp only at the point, in order that they may sink into the capsule, and tear it, but not cut it. The curving of the blade is such that the teeth may be set down into the pupillary space without tilting the forceps or grasping the iris. BURNETT.

POOLEY (499) reports a case in which an operation for discission of a secondary cataract, which had formed without any inflammation, by means of a Knapp needle-knife, was followed by inflammatory and glaucomatous symptoms. The capsule was tough and rather hard to cut, and some vitreous escaped. The patient made a good recovery. BURNETT.

THOMPSON (500) observed in one case that vision was reduced to fingers at three feet from the increasing opacity after Foerster's method, but that the lens gradually began to clear until the patient could read moderate-sized type. WERNER.

SEABROOK (501) concludes from a study of his own and others' materials: (1) that it is the rule for senile cataracts to show improvement at some time in their course; (2) that it is exceptional for pathological changes to remain absolutely stationary, permanently to improve, or to disappear. He does not believe that any true senile cataract has ever been arrested under the influence of any medical treatment whatsoever. BURNETT.

RODES (502) made a preliminary iridectomy, and the incision healed nicely without inflammatory symptoms. About a month later the lens was found in the anterior chamber, and pressing against the cicatrix. This gradually yielded, and the lens was extruded, leaving, the writer states, very good vision.

BURNETT.

FROTHINGHAM (503), after pointing out the inefficacy of most of the methods of dressing the eye after cataract extractions, describes a new mask, which he has devised for protecting the eye after the operation. It can be used over any kind of dressing. (Used very extensively by Fuchs in Vienna.—H. K.)

JACKSON (504) concludes, from a study of the physics involved, that any pressure on the globe after an extraction tends to cause a displacement of the edges of the wound, and that therefore, in dressing all these eyes, all pressure should be avoided.

BURNETT.

XVIII.—RETINA AND FUNCTIONAL DISTURBANCES.

505. VAN FLEET. Retinitis albuminurica and pregnancy. *Med. Jour.*, 1891, Sept. 26th.

506. OSTWALT. Syphilitic retinitis and its relations with the retinal arteries and with syphilitic arteritis of the encephalon. *Thesis*, Paris, 1891.

507. WAGENMANN. Contribution to our knowledge of the pathological anatomy of retinitis pigmentosa. *v. Graefe's Archiv.*, vol. xxxvii., p. 1.

508. RANSOHOFF. Retinitis pigmentosa. *Zehender's klin. Monatsbl.*, xxix., p. 271.

509. DE BONO. Investigations into the alterations of the retinal epithelium, and particularly on the formation of the so-called colloid excrescences. *Ann. di Ottal.*, vol. xx., 4, p. 329.

510. STEPHENSON. A peculiar form of retinal pigmentation. *Trans. Ophth. Soc. Unit. Kingd.*, vol. xi., p. 77.

511. VAURELLE. Contribution to the study of the etiology of epidemic hemeralopia, and of its relations to scurvy. *Thesis of Bordeaux*, 1891.

512. MANZ. Examination of a case of embolism of the central retinal artery. *Deutsch. med. Wochensch.*, 1891, p. 884, and *Festschrift v. Helmholtz*, 1891.

513. NETTLESHIP. Unusual appearances in a case of retinal embolism about thirty hours after its occurrence. *Festschrift v. Helmholtz*, 1891.

514. BARATZ. A case of embolism of the central retinal artery, with unusual appearances in the fundus of the eye. *Wratsch.*, 1891, no. 29.

515. GUNN. A case of hemorrhagic disease of the retina. *Festschrift v. Helmholtz*, 1891.

516. MUGLICH. Spontaneous recoveries from retinal detachment. *Inaug. Dissertation*, Marburg, 1891.

517. MACKROCKI. On the symptomatology of commotion of the retina. *Archiv. f. Augenhlkde.*, vol. xxiv., 3, p. 244.

518. MEYER. Contribution to the ophthalmoscopic diagnosis of alterations in the vascular walls in the retina. *Festschrift v. Helmholtz*, 1891.

519. PERLES. Glioma of the retina. (Observation in a very early stage.) *Centralbl. f. Augenhlkde.*, vol. xv., p. 240.

520. LAWFORD and COLLINS. Notes on glioma retinæ, with a report of 60 cases. *Royal London Ophth. Hosp. Rep.*, vol. xii., p. 12.

521. HILBERT. Pathology of scintillating scotoma. *Centralbl. f. Augenhlkde.*, vol. xv., p. 330.

522. FISCHER. Contraction of the visual field in traumatic neurosis. *Archiv. f. Augenhlkde.*, vol. xxiv., p. 18.

523. SAMELSOHN. On anæsthesia of the retina. *Deutsch. med. Wochensch.*, 1891, p. 927. (Regards the disease as central.)

524. JESSOP. Two cases of complete blindness with good pupillary reflexes. *Trans. Ophth. Soc. Unit. Kingd.*, vol. xi., p. 227.

525. WILLBRAND. On alterations in the visual field in functional disturbances of the nervous system, and on the oscillating visual field. *Verh. d. X. Internat. Med. Congr.*, vol. iv., 4, p. 101.

VAN FLEET (505) reports four cases of albuminuria in pregnancy, accompanied with retinitis, in three of which the termination was fatal, and in the fourth case a miscarriage fortunately occurred, and saved both the life and the sight of the patient. He strongly recommends the production of abortion in such cases.

BURNETT.

OSTWALT (506) describes the syphilitic diseases of the retina and choroid, and appends extensive literary references. Syphilis of the retina exhibits itself first in the central portions. The never-failing fine vitreous opacities of the authorities, Ostwalt asserts, never or rarely to have seen. If neglected, the eye gradually falls a prey to the usual type of syphilitic chorio-retinitis. Later we see Huebner's disease of the cerebral arteries, which bears great resemblance to the alterations in the retinal arteries. If the treatment is energetically followed up at the time of the central retinitis, the results are likely to be excellent, but if neglected till the later stages the chances are less. For this reason it is of the greatest importance to be able to recognize the incipient stages of the disease. MARCKWORT.

In WAGENMANN'S (507) case of retinitis pigmentosa the retina was enormously thickened, degenerated into connective tissue, and at many spots intimately united with the choroid. The vascular walls and obliterated vessels contained pigment. Pigment-cells issued arc-like from the pigment epithelium into the retina. The greatly thickened choroid showed distinct sclerosis of the vessels. Proof of the hæmatogenous origin of the pigment could not be obtained. He thinks that the pigment originated exclusively from the pigment epithelium.

De Bono (509) investigated in eight eyes that had been enucleated for various diseases, the alterations in the retinal epithelium, and the formations of the so-called colloid excrescences of the choroid. He convinced himself that the latter are of epithelial origin, due to separation of the epithelial cells, or to colloid or hyaline degeneration of the same. He cannot think of these as senile alterations, because he once found them in a child of five. The influence upon the vision is slight, since the structures mostly develop in the region of the ora serrata.

Dantone.

Stephenson (510) records three cases (out of 2,500 eyes) of peculiar spotted pigmentation of the retina similar to that shown in Plate 76 of Jaeger's *Hand Atlas*. The author believes that the condition is a physiological one, that it is not attended with any abnormity in the function of the eyes, such as night-blindness, but that it is merely an exaggerated form of the small isolated pigment spots that he has found in eight per cent. of all healthy eyes. Werner.

Vaurelle (511) made a two-years' sea voyage, and six months after the departure from France there was a great scarcity of fresh meat. Fresh vegetables had long since disappeared. Eight men of the crew were affected with hemeralopia, but were quickly relieved by small doses of cod-liver oil. The same conditions arising later on in the voyage were treated successfully in the same manner. Werner.

The most remarkable point in the case of retinal embolism reported by Manz (512) was the imperfect atrophy extending over the inner layers only of the retina.

The unusual circumstance in the eye of a patient examined by Baratz (514) three days after blindness due to embolism of the central retinal artery, consisted in a movement of the blood in the vessels, distinctly visible in the erect image. It was centripetal in the veins, and centrifugal in the arteries. But in some of the arteries it was centripetal, a circumstance never before described except by Hirschberg. The movement was slow, and by starts. The author endeavors to explain the peculiarity of these movements by the anastomoses of the branches of the central retinal artery with Zinn's Vascular Circle, from which the blood can occasionally penetrate into some of the branches of the occluded artery nearest the capillary anastomosing network, and will then of course move in a centripetal direction.

MUGLICH (516) has collected 136 cases of spontaneous replacement of retinal detachments, in which no operation was performed, and in which the causation was to be referred to myopia, retinitis albuminurica, traumatism, phlegmon of the orbit, loss of vitreous after operations, and choroiditis. He also adds five new cases, and two post-mortem examinations of eyes in which the retina had replaced itself. The essence of the microscopic investigation lies in an excessive connective-tissue degeneration, especially of the external layers of the retina, and disappearance of the nervous elements. Additionally he discovered varicose nerve fibres, enormous pigmentary invasion of the retina, deposits of exudation, formation of cavities, and finely fibrous deposits upon the retina.

LAWFORD and COLLINS (520) collected 60 cases of glioma, of which 30 were males. In most cases the growth was observed before two years of age. Recurrence after operation did not take place within three years in 3 cases. The authors found 25 cases of recovery on record. In the fatal cases, where only one eye was affected, fourteen months was the longest duration of life, and three months where both eyes were involved. In 2 cases one eye shrank. Heredity was not present in any of the cases.

WERNER.

HILBERT (521) saw, during an attack of scintillating scotoma, an arterial retinal pulse extending beyond the margin of the papilla.

Both cases reported by JESSOP (524) were of optic atrophy. In one, tabes was the cause; in the other, a cerebral tumor. The pupils reacted promptly and simultaneously both to light and convergence. WERNER.

WILLBRAND'S (525) oscillating visual field is characterized by the test object along the same meridian at regular intervals appearing, disappearing, then coming again into view, and once more disappearing, and so on so that during the test fleeting scotomata cross various portions of the visual field. Such a field may be seen, though very rarely, in functional disturbances of the nervous system.

XIX.—OPTIC NERVE.

526. BERNHEIMER. A certain condition in the optic nerve. *Verhand. d. X. Internat. Med. Cong.*, vol. iv., 4, p. 148. (Atrophy as a result of atheroma of the ophthalmic artery.)

527. GURWITSCH. Hyaline formation in the optic papilla and retina in Bright's disease. *Centralbl. f. Augenhlkde.*, vol. xv., p. 225.

528. SAEMISCH. Communications from the Bonn Clinic. *Festschrift v. Helmholtz*, 1891.

529. KESSLER. Intra-vaginal fibrosarcoma of the optic nerve. *Weekbl. v. h. Nederland. Tijdsch. v. Geneeskunde*, part ii., p. 781, 1891.

530. SANTOS FERNANDEZ. Clinical note on alcoholic amblyopia during the Cuban war. *Soc. Opht. de Paris*, Nov. 3, 1891.

531. MANOLESCU. Massage of the optic nerve in certain cases of optic atrophy. *Rev. Med. Therapeut.*, June, 1891.

532. KALT. On the resection of the optic nerve as a substitute for the enucleation in sympathetic ophthalmia. *Clin. franç.*, Jan., 1891, p. 125.

533. MARCHAL. Comparison between resection of the optic nerve and enucleation in sympathetic ophthalmia. *Thesis of Nancy*, 1891.

534. TROUSSEAU. Concerning resection of the optic nerve. *Rec. d'Opht.*, 1891, p. 585.

535. COWELL. A case of acromegaly with atrophy of both optic nerves. *Trans. Ophth. Soc. Unit. Kingd.*, vol. xi., p. 34.

536. WEEKS. La Grippe as a cause of retrobulbar neuritis, and other ocular lesions. *N. Y. Med. Journ.*, August, 1891.

537. WEBSTER. A case of "choked disk" with unimpaired vision. *Amer. Journ. Ophth.*, Oct., 1891.

GURWITSCH (527) discovered in the papilla of a patient who had died of Bright's disease, and who had exhibited during life a neuro-retinitis, hyaline formations both in the lamina cribrosa and in the retina. The larger ones showed a concentric stratification.

SAEMISCH (528) delineates and describes (1) cases of congenital coloboma of the optic nerve, and (2) a case of chorio-retinitis striata.

KESSLER (529) reports the case of a five-years-old child with a tumor developing eighteen months previously behind the left eye, and pushing the globe forward. After a while the tumor was laid bare, by Snellen, and seemed to be situated in the muscular conus of the orbit. Later the optic nerve was divided with scissors at the foramen and the tumor removed. The partly fluctuating tumor lay in the dural sheath of the optic nerve which ran through it. The tumor proved to be a fibro-sarcoma consisting chiefly

of bundles of united spindle-shaped cells with interlying large plasma cells, and smaller sarcomatous. A few myxomatous cells were also discovered, but not in sufficient quantity to give the tumor any resemblance to a myxoma. WESTHOFF.

SANTOS FERNANDEZ (530) has had frequent opportunities of observing alcoholic amblyopia. The external halves of the optic papillæ were almost invariably atrophic. Tobacco had nothing to do with this condition, because, in his experience, Havana tobacco never produces amblyopia without producing some preliminary constitutional affection. In the discussion, Despagnet doubts if the outer halves of the papillæ were actually atrophic. In his opinion the pallid appearance is due to an arterial spasm produced by the alcohol. During the recovery from the alcoholic amblyopia the spasm disappears, and the pupil regains its normal appearance. MARCKWORT.

KALT (532) resected the optic nerve in a patient who suffered from constant and exhausting pain due to an irido-choroiditis of apparently spontaneous origin. The pain ceased at once, and a good recovery ensued. In Kalt's opinion resection of the optic nerve is just as safe a prophylaxis against sympathetic ophthalmia as enucleation, and, as an operation, to be preferred to the same.

MARCHAL (533) reports three cases of resection of the optic nerve. In two the indication was pain as a sequence of irido-choroiditis, and in the third incipient sympathetic ophthalmia. The results in all three cases were unfavorable. Marchal urges the abandonment of resection, and the immediate return to enucleation as the only safe prophylaxis in threatened sympathy.

MARCKWORT.

TROUSSEAU (534) reports the further condition of a patient in whom resection had been performed. A short time after performance of the resection of the nerve, sympathetic ophthalmia broke out in the good eye, and the enucleation caused rapid improvement, but unfortunately, as Trousseau now reports, the sympathetic inflammation later renewed its fatal effect, and the patient became nearly blind. MARCKWORT.

WEEKS (536) reports one case of retrobulbar neuritis from La Grippe, from his own practice, and 14 from other sources. In his own case there was a small central scotoma in both eyes with limitation of the color field. The disk was pale on the temporal side. S = R E $\frac{20}{200}$, L E $\frac{10}{200}$. The patient improved under tonics.

BURNETT.

WEBSTER (537) gives a case from Dr. Agnew's practice in which there was a marked papillitis in both eyes, and yet, with correction of a slight ametropia, the patient had normal vision. The cause of the papillitis was obscure. BURNETT.

XX.—INJURIES, FOREIGN BODIES (PARASITES).

538. BUNGE. Siderosis of the globe. *Verhand. d. X. Int. Med. Cong.*, 1890, vol. iv., 4, p. 151.

539. SALZMANN. Observation of the earlier developmental stages of a subretinal cysticercus. *Zehender's klin. Monatsbl.*, 1891, p. 302.

540. WAGENMANN. On the occurrence of giant cells and purulent exudation in the region of an intraocular cysticercus. *v. Graefe's Archiv*, vol. xxxvii., 3, p. 125.

541. DENTI. A very rare reflex pupillary phenomenon, due to tænia. *Boll. d. Poliambul. di Milano*, and *Boll. d'Ocul.*, vol. xiii., p. 17.

542. KOSTENITCH. Pathological investigations of gun-cap injuries of the human eye. *v. Graefe's Archiv*, vol. xxxvii., 4, p. 189.

543. CRITCHETT. Exceptional cases in ophthalmic practice. *Brit. Med. Journ.*, 1891, p. 1116.

By siderosis BUNGE (538) understands those cases mostly resulting from injury, in which the iron dissolved by carbonic acid in the globe is oxidized by the arterial hæmatinic acid, and precipitates itself into all portions of the eye, so that the latter assumes a nut-brown appearance, which is however not to be confounded with a hæmatogenous pigment. If we place sections of both sorts in a 5 per cent. solution of muriatic acid, the brown mass is within 24 hours completely dissolved from out the siderotic space, whilst it remains nearly unaltered in the hæmatogenously colored space.

SALZMANN (539) assumes that the parasite entered through the central artery. The region of the macula showed a slightly elevated opacification, and in the region of the fovea there was a whitish, rapidly moving body about $\frac{1}{3}$ papilla diameter in size. The parasite increased five times in length within the next ten days, when a successful extraction was performed. The hooklets on the head were first observed on the 7th day.

WAGENMANN's case (540) was not accompanied with tuberculosis, as was that reported by Schroeder, but it was a simple instance of giant cells and masses of suppuration produced by the exciting properties of the entozoön.

DENTI (541) observed in a woman of 51, who was under his care for an ordinary conjunctival catarrh, a bilateral and extreme myosis, which did not however cause much visual disturbance. Mydriatics were of no avail. The phenomenon was finally referred to the reflex influence of a tænia solium, for, when the latter was evacuated from the intestines by proper treatment; the pupillary reflexes at once disappeared, and did not return.

DANTONE.

KOSTENITCH (542) examined 20 eyes that had been injured with gun-caps, and found Leber's experimental investigations abundantly confirmed. A suppurative exudation produced by the action of the sulphate of copper, and without the action of micro-organisms, entirely surrounded the foreign body. All of the internal coats of the eye, the nearer they lay to the foreign body, and the longer the latter had remained in the eye, were proportionally inflamed, and the greatest amount of inflammation was discovered in the site of the foreign body in the retina. The inflammatory process occasionally diminishes in amount, owing to a scale-like encapsulation of the deposit. The fibrillary alterations of the vitreous body which extend to the retinal detachment are especially worthy of observation. The retina degenerates or even occasionally necroses, owing to the chemical action of the copper. In the same manner the optic nerve becomes atrophic. In some cases the lens was purulently infiltrated, with thickening of the capsule, and increase of its cells. The absence of micro-organisms in these eyes thus injured gives us the right to act conservatively, and to attempt operative removal of the foreign body.

CRITCHETT (543) cites a few cases of unusual injuries; superficial defects of the cornea produced by scratches, splinters of glass, and curling irons.

WERNER.

XXI.—OCULAR DISTURBANCES IN CONSTITUTIONAL AFFECTIONS.

544. ESKRIDGE. Gun-shot wound at the left cuneus, with right homonymous hemianopsia. *Med. News*, Oct. 17, 1891.

545. FARAVELLI. Right homonymous hemianopsia of traumatic origin. *Ann. di Ottal.*, vol. xx., 5, p. 431.

546. LEYDEN. Hemiopic pupillary reaction, the so-called Wernicke's iridoplegia. *Festschrift Virchow, Deutsch. med. Wochensch.*, 1892, No. 2.

547. HOCHE. Bilateral hemianopsia inferior and other sensory disturbances with a functional psychosis. *Arch. f. Psychiat. u. Nervenkrankheiten*, vol. xxii., 1, p. 70.

548. GROENOUW. Bilateral hemianopsia of central origin. *Ibid.*, vol. xxiii., 2, p. 139.

549. PETERS. Case of fracture of the skull with hemianopsia. *Deutsch med. Wochensch.*, 1891, p. 1097.

550. SWANZY and WERNER. A case of double hemianopsia. *Trans. Ophth. Soc. Unit. Kingd.*, vol. xi., p. 183.

551. STORY. Temporal hemianopsia of the left and blindness of the right eye. *Trans. Ophth. Soc. Unit. Kingd.*, vol. xi., p. 297.

552. PRESTON. Two cases of homonymous hemianopsia. *N. Y. Med. Record*, July 4, 1891.

553. WILLIAMS. A case of horizontal hemianopsia. *Trans. Ophth. Soc. Unit. Kingd.*, vol. xi., p. 190.

554. WILLIAMS, R. A case of alexia. *Trans. Ophth. Soc. Unit. Kingd.*, vol. xi., p. 193.

555. ERB. On the etiology of tabes. *Berlin. klin. Wochensch.*, 1891, pp. 713 and 751.

556. NETTLESHIP. Cases of temporary blindness during lactation. *Royal London Ophth. Hosp. Rep.*, vol. xiii., p. 98.

557. KALT. Arterio-venous aneurism of the carotid in the cavernous sinus due to an injury. *Semaine Méd.*, 1891, No. 29, p. 236.

558. LOMBROSO. The visual field in epileptics and feeble-minded persons, according to Ottolenghi. *Rec. d'Opht.*, 1891, p. 449.

559. MAUTHNER. Polyencephalitis and sleep. *Wiener med. Wochensch.*, 1891, Nos. 26 and 27.

560. COHN. On nystagmus in ear affections. *Berlin. klin. Wochensch.*, 1891, pp. 1052 and 1074.

561. SEGGEL. The diseases of the eye in diabetes mellitus. *Münchener med. Wochensch.*, 1891, p. 754.

562. WEEKS. Influenza as the cause of retrobulbar neuritis and other ocular lesions. *N. Y. Med. Jour.*, vol. liv., No. 6.

563. MORTON. Bilateral paralysis of the external recti following diphtheria. *Trans. Ophth. Soc. Unit. Kingd.*, vol. xi., p. 107.

564. DEBOVE. Associated movements in facial paralysis. *Union Méd.*, 1891, No. 35, p. 421.

565. SNELL. Immediate loss of sight after injuries to head and back. *Trans. Ophth. Soc. Unit. Kingd.*, vol. xi., p. 137.

566. WHERRY. A case of paralgesia and ophthalmoplegia. *Trans. Ophth. Soc. Unit. Kingd.*, vol. xi., p. 118.

567. THOMPSON. Monocular diplopia. *Jour. Amer. Med. Assoc.*, Sept. 22, 1891.

568. BLISS. A curious case of vision dependent on the use of both eyes. *N. Y. Med. Record*, July 4, 1891.

569. DUNN. Four cases of reflex amblyopia. *Amer. Jour. Ophth.*, Oct., 1891.

The man of whom ESKRIDGE reports (544) was shot in the left occipital region an inch and a half anterior to the occipital protuberance, and half an inch to the left of the median line The ball was extracted from about an inch below the cortical substance. There was typical right hemianopsia, but the movements of the eye were good. The pupil was slightly dilated and fundus normal. He died on the fifth day. The cuneus was found to have been completely destroyed. The ganglia and base of the brain and tentorium cerebelli were intact. BURNETT.

FARAVELLI (545) observed in a young man a right-sided sharply defined hemianopsia outward, originating after an injury on the head, lasting six weeks and then disappearing suddenly. As the eye remained with normal vision, and neither defects of speech nor sensorium were observed, the author thinks that the symptom originated in a small hemorrhage of the meninges of the left posterior occipital lobe, or in the cortical substance directly underneath, and the fibres running directly from the same. DANTONE.

LEYDEN (546) gives the clinical history of a woman who was submitted to an autopsy, after showing in life hemiopic iridoplegia after an apoplectic attack. Wernicke had deduced the theory that in such cases the interruption of the reflex paths must have occurred in front of the corpora quadrigemina, resp. in the tractus opticus. Corresponding then to this idea, there was found with the left-sided homonymous hemianopsia, in the right nucleus

lenticularis, a spindle-shaped softened deposit, which extended as far as the crus cerebri, and had partly attacked the tractus opticus.

HOCHE (547) examined a lying-in woman who had begun to suffer from melancholia previous to her delivery. The patient perceived irritating colored phenomena in the visual fields that are entirely abolished to most patients.

GROENOUW (548), after giving the history of sudden cases of blindness in both eyes due to disturbances of nutrition, mostly of an embolic nature in the posterior lobes, reports a new case of bilateral hemianopsia. A man of fifty-nine, with a slight apoplectic seizure in January, 1889, acquired a left-sided hemianopsia, and in November of the same year a right-sided hemianopsia. A small central spot remained unaffected, and vision was normal A portion of the missing fields gradually returned, and those that were absent were not amaurotic. Color sense unimpaired ; sense of locality much affected. (In Schweigger's case of bilateral hemianopsia, which the reviewer had many opportunities of examining, the sense of locality was unimpaired.) The author concludes that, when a portion of the field is retained in bilateral hemianopsia of central origin, it generally embraces the points of fixation. The lesions of the sense of locality appearing in lesions of the occipital lobe, depend on the loss of a large number of optical remembrance-pictures.

PETER'S (549) patient, aged twenty-eight, suffered a fracture of the occipital regions with right hemianopsia when he was an infant. The peculiarity in the case is that in the course of years both the uncrossed and crossed fibres have become atrophic.

SWANZY and WERNER'S (550) patient had an apoplectic seizure which caused monoplegia of left arm, without loss of sensation. The whole of the right half of the field of vision was lost, and also the lower quarter of the left half, the defects being absolute. Ophthalmoscopic appearances normal. His condition remained unaltered for several months. The authors assumed that there was a double cortical lesion. WERNER.

STORY'S (551) patient, who was a young woman æt. nineteen years, was under observation for four years. The chief symptoms were absence of the menses, anæmia, pain in the head, increasing corpulence, and constipation. She always felt sleepy. The right eye was completely blind from optic atrophy. The left eye afterwards began to fail and to become atrophic. The visual field

taken at various times at first exhibited only slight temporal defect for red, subsequently a relative defect for white, which finally became absolute. WERNER.

Of PRESTON'S (552) cases. Case 1 was a man of fifty-one who seemed to be healthy except as to vision. There was right-sided homonymous hemianopsia and double optic neuritis. The treatment with the iodides was tried, but with no result. Patient died suddenly, probably from pressure on the medulla. Autopsy showed a spindle celled sarcoma involving the whole of the cuneus of the left occipital region, and encroaching somewhat on the precuneus. It involved all of the cortex as far as, and probably including, the angular gyrus. Case 2, man of forty-seven; specific history; marked arterio-sclerosis; complete right homonymous hemianopsia; disks pale; arteries and veins narrow. Provisional diagnosis: embolism of left posterior cerebral artery. BURNETT.

In WILLIAMS' (553) case there was a defect of the lower half of the left field and of the upper half of the right field of vision. There was some neuro-retinitis. The patient had some symptoms of ascending myelitis. WERNER.

WILLIAMS (554) reports the case of a man, æt. fifty-seven, who on receiving a letter found that he was unable to read it, although his sight was perfect. Vision $\frac{6}{6}$, and fundus normal. The fields exhibited a right-sided hemianopsia. He was able to write anything from dictation, but he could not read what he had written. He had no other symptoms, but said that his memory was defective. WERNER.

ERB (555) has made prolonged investigations into the subject, and concludes that syphilis is the most frequent and the most powerful cause of tabes, whilst other influences, like heredity, nervousness, cold, fatigue, excesses, overwork, and so on, rarely cause, by themselves alone, tabes, but often do so when combined with a syphilitic basis.

NETTLESHIP (556) records four cases of temporary failure of sight during lactation, in one of which appearances of post-optic neuritis were found many years after. In the remaining cases there were no ophthalmoscopic alterations. WERNER.

KALT (557) observed a case of aneurism of the carotid in the sinus cavernosus, owing to a fall on the occiput. A month later left-sided exophthalmus with immobility of this eye ensued. There was additionally knocking and blowing noises in the head.

Kalt ligated the common carotid without any after symptoms of any consequence, and the head symptoms at once ceased. The exophthalmus gradually disappeared in the course of a fortnight.

MARCKWORT.

OTTOLENGHI (558) examined a large number of cases at Lombroso's Insanity clinique and invariably discovered some field defect in lunatics or feeble-minded people. Partial inferior hemianopsia was often present in the right eye, and partial superior hemianopsia in the left eye. These defects were particularly well developed in the inner portions of the field. He also discovered the very rare homonymous vertical hemianopsia. The color field follows with greater or less regularity that for white.

MARCKWORT.

MAUTHNER (559) regards the sleep disease as a polyencephalitis superior. Slight ptosis is a frequent premonitory symptom. He places the seat of sleep in the central gray substance, and explains it by the interruption of the centripetal and centrifugal nerve conduction.

A nervous patient of COHN'S (560), affected with middle-ear suppuration, suffered with typical attacks of violent nystagmus and vertigo, which could often be produced by pressure on the auricle, and especially upon the tragus. Cohn thought that this act might produce compression of the air in the meatus, and secondary irritation of the nervous elements. In opposition to the general theory of direct irritation of the brain in such cases, he is inclined to view with greater favor the idea of the reflex influences of the labyrinthine irritation or irritation of the semi-circular canals upon a portion of the ocular mobilization apparatus.

SEGGEL (561), like many others, does not consider every cataract in a diabetic as a diabetic cataract. He divides the retinitis in these cases, like Leber, into a central punctate and a hemorrhagic.

WEEKS (562) reports a case of retrobulbar neuritis after La Grippe, and adds a *résumé* of 14 others seen by various observers. In his own cases there was a small central scotoma in both eyes, with contraction of the field. Papillæ pale on temporal side. Vision, R $\frac{20}{200}$, L $\frac{10}{200}$. Tonics brought about recovery.

BURNETT.

MORTON (563) describes three cases of paralysis of the externi, appearing five, four, and seven weeks after the diphtheria. In one

case there was also paresis of the internus and superior. In all, the pupil reacted to light and convergence. The accommodation was affected in two cases. Loss of the patellar reflex in all three cases. A fourth case affected a child aged five years. In all of the cases the loss of the patellar reflex persisted long after all the other symptoms had disappeared. WERNER.

DEBOVE (564) observed a case of paralysis of the right facial nerve from a blow with a horse's hoof. It was very curious to note that the patient could only speak by shutting his eyes. Contrarily it was seen that the angles of the mouth rose when the eyes were energetically closed. MARCKWORT.

In SNELL'S (565) case the atrophy ensued upon a fracture of the skull. Although the sight was lost directly after the injury, the atrophy could not be determined till some weeks later.

WERNER.

WHERRY'S (566) patient was a gentleman æt. fifty-six, who had had syphilis twenty-five years before. Three days before, while at table, he noticed that everything tasted bitter, and he began to see double. Both pupils dilated and immovable. Divergent squint. No evidence of difficulty of accommodation. Patches of numbness of skin in the left thigh and left little finger. He recovered at the end of a month whilst taking iodide of potassium up to 110 grains daily. WERNER.

THOMPSON (567) reports a case of monocular diplopia in full, and from a study of this and some other recorded cases he concludes that monocular diplopia is, in the majority of cases, one of the symptoms of hysteria, provided that there is no defect in the refraction. When it occurs in connection with recent or former squint, it is a symptom of a psychical condition, closely related to hysteria, in which auto-suggestion is easily excited. When it occurs in connection with cranial troubles, it points to the posterior convolutions of the occipital lobe as the seat of the disease.

BURNETT.

In the case reported by BLISS (568) a girl æt. eight years had amaurosis, temporal hemianopsia, contracted field of vision, color-blindness, nyctalopia, and the vision of each eye separately was less than $\frac{1}{200}$; with atropine, and with both eyes together, with + 1.5 D, vision was $\frac{15}{40}$. [The probable explanation, in the opinion of the Reviewer, is that the hemianopsia condition (which is not reported in full) is at the bottom of the phenomenon. The two normal fields supplement one another when both

eyes are used. It would be interesting to have accurate drawings of the fields.] BURNETT.

DUNN'S (569) two first cases have been reported elsewhere. In the third case all uncertain amblyopia and some restriction of the field of the left eye, associated with paralysis of the facial on the left side, disappeared on curing an abscess of the root of the second molar of the inferior maxillary on the left side. In the fourth case, a man had a blow on the right cheek, just below the orbit. The nasal and buccal cavities became inflamed and ulcerated, the vision was much impaired, and there was slight ptosis of the right upper lid. The patient was lost sight of. BURNETT.

MISCELLANEOUS NOTES.

Dr. ST. BERNHEIMER has been appointed Lecturer on Ophthalmology at the University of Vienna, and settled in that city.

The following gentlemen have been appointed Lecturers on Ophthalmology, viz.: Dr. ALBERT PETERS, at Bonn ; Dr. ELSCHNIG, at Graz (Austria) ; Dr. STÖWER, at Greifswald.

Dr. CZERMACK, of Vienna, has been appointed Extraordinary Professor of Ophthalmology at the University of Innsbruck ; Dr. BERGMEISTER, Extraordinary Professor at Vienna.

Prof. ALFRED GRÄFE has resigned his chair at the University of Halle, on account of ill health. Prof. SCHMIDT-RIMPLER, of Göttingen, and Prof. VON HIPPEL, of Königsberg, were proposed, *æquo loco*, as his successors by the medical faculty. VON HIPPEL has been appointed by the Prussian government.

OBITUARY.

On June 20, 1892, after a long sickness, Dr. E. MARCKWORT, of Antwerp, died at Brunswick, Germany, in the house of his parents. We lose in him a tried collaborator, who distinguished himself by the exactness and truthfulness of his abstracts from French literature in our reports on the progress of ophthalmology.

ERRATA.

In this volume, page 178, 4th line from bottom and 4th from top, read "Ehrlich" for 'Ulrich."

On page 205, 2d line from top, omit words "he, as well as."

INDEX TO VOLUME XXI.

Abadie, Therapeutic Value of Medicamentous and Subconjunctival Injections, 420

Accommodation, and Convergence, Points with Reference to Connection between, 430 ; and Refraction, Reports on Anomalies of, 135, 309, 430

Achromatopsia, Two Cases of Total, 426 ; Third Case of, 309

Acromegaly with Tabic Symptoms and Bilateral Hemianopsia, 414

Advancement, Modification of Ordinary Method, 439 ; of Muscles, Technique of Sutures in, 438

Albinism, a Curious Family History, 418

Alexia, Case of, 572

Amblyopia, Alcoholic during Cuban War, 568 ; from Tobacco and Alcohol, 408 ; Reflex, 573

Ametropia, Full Correction of, 430

Anæmia, Affection of the Eyes in Pernicious, 39

Anastomosis, Arterio-Venous, in Orbit, 442

Anatomy, Reports, on, 131, 307, 424 : Topographical, of External Angle of Eye, 438

Aneurism of Carotid in Cavernous Sinus, 572

Animals, Refraction of, 424

Anterior Chamber, Cyst of, 452 ; Eyelashes in, 451

Aorta, Aneurism of, 414

Aphakia, Correction of, with Lenses, 558

Aqueous Humor, Secretion of the, 132 ; Exits of, 426

Argyll Robertson, Case of Wound of the Sclerotic with Penetration of Eyelashes into the Anterior Chamber, 452 ; on a Modification of the Ordinary Method of Operating for Advancement of the Tendon of the Recti Muscles, 439

Arterial Sclerosis, Ophthalmological Examinations in, 414

Asepsis in Ophthalmic Surgery, 420

Astengo, Enormous Stone in the Orbital Cavity, 412

Astigmatic Accommodation, 310

Astigmatism against the Rule and the Associated Symptoms, 430

Astigmometer, Pocket, 420

Atropia and Homatropia, Comparative Effect, 431

Aubert, on the Accuracy of Ophthalmometric Measurements, 418

Axenfeld, on the Development of Lymphoma in the Orbit, 439

Ayres, S. C., Papilloma of the Cornea, 449

Bandage, New, for Simple Extraction, 558

Baquis, Histological Changes Following Temporary Anæmia of the Retina, 407

Baratz, a Case of Embolism of the Central Retinal Artery with Unusual Appearances in the Fundus of the Eye, 564
Barr, Extraction of Incipient Cataract, 557
Bartholow, a Few Observations on the Mydriatic Alkaloids, 420
Basedow's Disease, Paresis of Convergence in, 415; Symptomatology of, 414
Batten, Some Points on the Relationship of the Eye to the Cardio-Vascular System, 414
Bernheimer, on Changes in the Optic Nerve in High Degrees of Sclerosis of the Cerebral Arteries, 410; on a Certain Condition in the Optic Nerve, 567
Berry, Critical Remarks on the Theories of Fundamental Color-Sensation, 426; Note on an Unusual Result of Cataract Extraction, 558; Note on the Individual Differences in the Degrees of Latent Lateral Deviations of the Eye on Looking Upward and Downward, 438; on Some Points with Reference to the Connection between Accommodation and Convergence, 430
Bicycle Spectacles, 420
Bissell, Spasm of the Ciliary Muscle, 549
Black, Does Javal's Ophthalmometer Render the Use of Atropine Unnecessary? 333
Blennorrhœa in Child Born in Membranes, 444
Blepharitis, Vaccine, 215
Blickhahn, a Case of Chancre of the Right Upper Eyelid, 434
Blindness, Etiology in 32,000 Eye Patients, 51; Report on the Prevalence of, in the U. S., 193; Temporary, during Lactation, 572; with Good Pupillary Reflexes, 565
Bliss, a Curious Case of Vision Dependent on the Use of Both Eyes, 573
Boé, a Case of Homonymous Superior Hemianopsia, 533
Boé on Sympathetic Ophthalmia, 554
Bone, Formation of, on Optic Disk, 254
Bonn Clinic, Contributions from the, Saemisch, 568
Bordecker, a Case of Chronic Progressive Paralysis of the Eye Muscles in a Paralytic from Tabes, 415
Bowman, Sir William, Obituary Notice of, 330
Brailey, on Some Points in the Development of Cataract, 557; on Sympathetic Ophthalmia, 554
Bristowe, the Ophthalmoscopic Appearances of Hypermetropia and Their Significance, 430
British Medical Association, Discussion on the Vision of Railway Servants, 420
Bronner, Fifty Cases of Strabismus in Which the Rectus Muscle was Advanced according to the Method of Schweigger, 438
Brossage, Cases of, 444
Brown, Glioma of Retina, with History of Three Cases in One Family, 407
Brushing in Trachoma, 445
Bull, C. S., Tumors of the Orbit, Secondary or Consecutive to Tumors of the Neighboring Bony Cavities, 442
Bull, O., Synergetic Ocular Movements, 342; Another Case of Synchronous Movements of the Upper Lid and Lower Jaw, 354
Bunge, Siderosis of the Globe, 570
Burnett, S. M., Contributions to Clinical Ophthalmology, 248
Burnett, S. M., Further Contributions to Keratometry, 430; the Prism Dioptry *vs.* the Centrad, 430; Recent Views on the Pathology of Trachoma, 445;
Buphthalmus, Double Congenital, 552; Pathological Anatomy of, 552

Capei, Tincture of Iodine in Infectious Ophthalmia, 449
Capsule, Treatment of Lens, 558
Capsulotome Knife, 420
Cardio-Vascular System, Relation of Eye to, 414
Carpenter, Tuberculosis of Choroid, 550
Cassedy, Congenital Corectopia, 549
Cataract, Central, Pathology and Pathogenesis of, 557; Development of, 557; Extraction, Pressure on Globe after, 558; Extraction, Unusual Result of, 558; Extraction, 54 Cases, 398; Extraction, Apparatus for Protection after, 558: Extractions, Reports of 97, 558; Förster's Ripening of, 558; Hereditary Congenital, 557; Incipient, Extraction of, 557; Incipient, Etiology, Treatment, and Prognosis, 557; Infantile, Treatment of, 557; Lamellar, Treatment of, 557; Maturing of, 516; Operations, 557; Natural Course of, 558; Post-Operatory Complication, 558; Spontaneous Extraction of, 558; Zonular, 557
Cataracts, Anterior Capsular and Pyramidal, 557
Cervical Sympathetic, Rôle of, in Accommodation for Distance, 426
Chancre of Lid, 434
Charnley, A Rare Tumor of the Iris Removed by Operation, 548
Cheatham, Trachoma and its Treatment, 445
Cheney, a Case of Retraction of the Eyeball, 442
Chevallereau, Gouty Keratitis, 449
Chibret, Aspiration in the Extraction of Cysticercus in the Vitreous, 412; Iodine in Infectious Ulcers of the Cornea, 445; Pathogeny of Affections of the Conjunctiva in a Bacteriological Point of View, 444
Chisolm, Homatropia in Refractive Cases, 430; the Value of Weak Cylinders in the Cure of Spasm of the Ocular Muscles, 430
Choked Disk with Perfect Vision, 568
Choroid, Binocular Absence of the, 105; Carcinoma of, 550, 551; Detachment of, 272, 550; Ossification of, 550; Prognosis of Sarcoma of, 550; Reports on Diseases of the, 154, 320, 550; Sarcoma of, 155, 528; Tuberculosis of, 550; Tumors of the, Some Rarer Forms of, 76
Choroiditis Dissem. and Retinitis Hemor. in Same Eye, 550
Ciliary, Body, Glands of, 424; Muscle, Spasm of, 549
Clarke, Eyelash in Anterior Chamber, 452
Cocaine, Influence of, on Imbibition, 426
Cohn, on Nystagmus in Ear Affections, 572
Collins, on the Development and Abnormalities of the Zonula of Zinn, 424; the Glands of the Ciliary Body in the Human Eye, 424; a Late Epithelial Implantation Cyst in a Shrunken Globe Twenty-eight Years after Receipt of Injury, 556; Extensive Rupture of the Posterior Capsule of the Lens Following a Blow on the Eye from a Stone, 557; on the Operative Treatment of Glaucoma, 553; on the Pathology of Intraocular Cysts, 452; on a Case of Tumor in Each Orbit, Death, Necropsy, 442
Collins and Wilde, the Pathology of the Ophthalmoplegiæ, 439
Colloid Excrescences, 564
Color-Blindness, Case of Total, 426; Review of Tests for, 427
Color-Sensation, Theories of, 426
Congenital Anomalies, Developmental History of, 418
Conical Cornea, Perforation with Galvano-Cautery, 450
Conjunctiva, Affections of, from Bacterialogical Point of View, 444; Anatomy of Chronic Inflammations of, 444; Cornea, Sclera, and Ante-

Conjunctiva—*continued.*
rior Chamber, 148, 317, 444; Diffuse Lymphoma of, 445; Emphysema of, 445; Hemorrhage, Following Use of Silver Nitrate, into the, 318; Papilloma of, Encroaching on the Cornea, 91; Periodic Congestion of the, 260; Transplantation of, 445; Traumatic Retention Cyst of the, 231
Conjunctivitis, Diphtheritica, Treatment of, by Antiseptic Irrigations, 444; Granular, Pumice Stone, 445
Consensual Pupillary Reaction in Monocular Argyll-Robertson Pupil, 418
Contagious Eye Diseases, 417
Corectopia, Congenital, 549
Cornea, and Conjunctiva, Epithelioma of, 445; Blood-stains of, 449; Epithelial Plaque of, 449; Fistula and Astig. of, Cured by Operation, 452; Form of, and its Influence on Vision, 426; Papilloma of, 449; Sarcoma of the, 277; Successful Transplantation of the, 153; Transplantation of, 450; Ulcers of, Treatment with Acids, 449; Wrinkling of the, 261
Corneal Wounds, Personal Restraint in Healing of, 557
Cornu Cutaneum, Case of, 434
Cowell, a Case of Acromegaly with Atrophy of Both Optic Nerves, 568
COWGILL, Binocular Absence of the Choroid, 105
Conetoux, Bicycle Spectacles, 420; on Keratoconjunctivitis of Rhino-Pharyngeal Origin, 445
Critchett, a Capsulotome Knife, 420; Conical Cornea, Treated with the Galvano-Cautery, with Perforation, 450; Exceptional Cases in Ophthalmic Practice, 570
Critchett and Juler, Epithelioma of the Cornea and Conjunctiva, 445
Cross, Blood-Stained Tears, 436; Hydrophthalmus, 552; Iridectomy or No, in Cataract Extractions, 557
CULVER, Correlation of Cranial and Ocular Conformations, 68
Cyclopia, Mode of Formation of, 418
Cylinders, Value of Weak, 430
Cysticercus, in Vitreous, Aspiration in Extraction of a, 412; Early Developmental Stages of, 570; Giant Cells and Purulent Exudation in Region of a, 570
Cyst, Epithelial, in Shrunken Globe, 556; of Orbit, 442
Cysts, Pathology of Intraocular, 452

Dacryocystitis, Operative Treatment of, 436
Dareste, on the Mode of Formation of Cyclopia, 418
Darier, Presentation of Cases in which Brossage had been Performed, 445; Subconjunctival Injections of Sublimate in Ocular Therapeutics, 419
Davis, Contagious Eye Diseases with Statistical Remarks, 417
Debierre, a Case of Acromegaly with Tabic Symptoms and Bilateral Hemianopsia, 414
De Bono, Alterations of Retinal Epithelium and Colloid Excrescences, 564
Debove, Associated Movements in Facial Paralysis, 573
Denti, a Very Rare Reflex Pupillary Phenomenon, Due to Tænia, 570
Dermoid Cysts, Circumbulbar, Pathology of, 376
De Schweinitz, a Case of Persistent Hemorrhage from the Conjunctiva of an Infant, Following the Instillation of a Solution of Nitrate of Silver, 444; *a Handbook of Ophthalmic Practice*, reviewed, 453; a Note on Fluorescin Coloring and the Actual Cautery in Corneal Ulcers, 445; One Hundred Cases of Astigmatism against the Rule and the Associated Symptoms, 430; Perimetric Observations on the Influence of Eserine and Iridectomy in Chronic Glaucoma, 553

Despagnet, Curettage of the Lachrymal Sac, 436 ; Tubercle of the Iris, Spontaneously Cured, 548
Deviations, Latent, of the Eye in Looking Up and Down, 438
De Wecker, Scraping of the Lachrymal Sac, 436 ; the Indications for Simple Resection of the Optic Nerve, 411
Diplopia Monocular, 573
DODD, An Iris-Shield, 213
Dransart, Miner's Nystagmus in the North of France, 439
Drill, Lachrymal, 436
Dub, Contribution to the Knowledge of Zonular Cataracts, 557
Dubois de Lavigerie, Hyperplastic Epithelial Plaque of the Cornea, 449
DUNN, a Case of Reflex Micropia upon Posterior Hypertrophy of the Inferior Turbinates, 365
Dunn, Four Cases of Reflex Amblyopia, 573 ; Some Remarks upon the Ætiology and Treatment of the Phlyctenular Eye Diseases, 445

Eaton, Fracture of Base of Skull, with Paralysis of Portions of Fifth and Sixth Pairs, 412
Ehrlich's Methylin Blue Method, 424
ELSCHNIG, Detachment of the Choroid, 272
Embolism of Central Artery, 497, 564; Cured by Massage, 407 ; Retinal, 564
Entropium, the Operation of, 434 ; Transplantation in Minor Degrees of, 434
Enucleation, Death from Hemorrhage after, 63
Epithelioma of Lid, 434 ; of Limbus, 449
Eskridge, Gunshot Wound at the Left Cuneus, with Right Homonymous Hemianopsia, 571
Erb, on the Ætiology of Tabes, 572
Euriphen in Ophthalmology, 73
Exophthalmic Goitre, Points of Affinity between Rheumatoid Arthritis, Locomotor Ataxy, and, 415
Exophthalmus, Experimental Production of, 418 ; Following Strabotomy, Disappearance of, 439 ; Pulsating, in a New-Born Child, 442
Expression of the Morbid Material in Trachoma, 119
Extraction, Treatment of Capsule in and after, 558
Extractions, 109 Simple, 557
Eye, Diseases of, in Diabetes, 572 ; Lotions, Disinfection of, 305
Eyeball, Retraction of, 442
Eyelashes, in Ant. Chamber, 452
Eye Muscles, Paralysis of, in Tabes, 415

Faravelli, Right Homonymous Hemianopsia of Traumatic Origin, 571
Fellows, Ocular Massage, 445
Ferdinands, Investigations into the Eyesight of Children Attending Some of the Aberdeenshire Board Schools, 430
Fernandez, Clinical Note on Alcoholic Amblyopia during the Cuban War, 568
FERNANDEZ, Europhen and Cantharidate of Soda in Ophthalmology, 73
Fernandez, Loss of Sight Following a Gunshot Wound in the Periorbital Region, 412 ; on a Possible, but Remedial Accident in Keratotomy, 558 ; Spontaneous Diappearance of an Accident of Strabotomy, Exophthalmus, 439
Field of Vision, Contraction of, in Traumatic Neurosis, 565
FINLAY, Penetrating Wounds of the Eyeball, Sympathetic Ophthalmia, 457
Fischer, Contraction of Visual Field in Traumatic Neurosis, 565 ; Cure of a Case of Embolism of the Central Retinal Artery by Rubbing the Eye, 407

Fistula of Lachrymal Sac, Congenital, Cure of, 141
Fluorescin, Note on, etc., 445
Foreign Bodies, Inflammation of Eye Caused by, 22
Foreign Body in Fundus, Unsuccessful Attempt at Removal, 362
FOSTER, Embolism of Arteria Centralis Retinæ, 497
Fox, Resection of the Optic Nerve, 411
Fracture of Base of Skull, with Paralysis of Abducens, 415; with Paralysis of the Fifth and Sixth Pairs, 412
FRIEDENWALD, Binocular Metamorphopsia Produced by Correcting Glasses, 204
Friedenwald, Report of Ophthalmological Examination of Dr. Preston's Cases of Arterial Sclerosis, 414
Frontal Sinuses, Diseases of the, 145
Frothingham, Remarks on the Need of More Efficient Protection of the Eye after Cataract Extraction, and an Improved Apparatus for the Purpose, 558
Fuchs, on Lens Precipitates, 557
Fulton, Pathology and Ætiology of Trachoma, 445

Garnier, a Case of Myxo-Sarcoma of the Optic Nerve, 411
Gasperini, Diffuse Lymphoma of the Conjunctiva, 445
Gaupillat, New Device for Bandaging after Simple Extraction, 558
Gayet, Essay on the Investigation of the Acuteness of Sight after the Operation for Cataract, 558
General Ophthalmological Literature, Reports on, 128, 303, 417
GIFFORD, Further Experiments on the Lymph Spaces and Channels of the Eye, 171
Gillet de Grandmont, Syphilis or Tuberculosis of the Iris, 548
Glaucoma, Acute, in Man, Æt. Twenty-four, etc., 553; after discission of Secondary Cataract, 293; after Operation for Secondary Cataract, 558; Curability of, 553; Hemorrhagic, 553; in Aniridia, 322; Operative Treatment of, 553; Perimetric Observations on Influence of Eserine and Iridectomy in, 553; Reports on, 154, 322, 552; Simplex, 552; Unusual Family History of, 358
Glioma Retinæ, Sixty Cases, 564
Goitre, Exophthalmic, 442
Golowin, on the Use of Hydrogen Peroxide in Ophthalmic Practice, 420
Gould, Statistics and Results of 1,500 Cases of Refraction, 430
Graefe's Lid-Sign, 442
Granular Lids, Surgical Treatment of, 445
Granulations, Anatomy of, 151; New Method of Operating, 445
Granuloma of Glands of Moll, 434
Graves' Disease, Recovery from, 442
GREEFF, A remarkable Case of Pseudo-Trachoma, 505
Greeff, Investigations on Binocular Vision, with the Use of Hering's Test, 426
Green, Elbridge, a Review of the Tests for Color-Blindness, 427
Grippe as a Cause of Retrobular Neuritis and Other Ocular Lesions, 568
Groenouw, Bilateral Hemianopsia of Central Origin, 572
Guaita, Operative Treatment for the Rapid Cure of Dacryocystitis, 436
Guerenchi, Clinical Contributions to the Physiology of the Optic Ganglion, 412
Guldenarm, Contribution to Surgery, 415
Gunn, A Case of Hemorrhagic Disease of the Retina, 564
Gunshot Wound of Periorbital Region with Loss of Sight, 412
Gurwitsch, Hyaline Formation in the Disk and Retina in Bright's Disease, 568

Haab, Chronic Tuberculosis of Choroid, Specific Arterial Disease of Retina, 550; Remarks on Cataract Operations, 557
HASSELL and BELL, Statistical Paper on Blindness, 51
Hasner, Obituary Notice of Von, 331
Headache, Ocular, and States of Refraction, 431
Helmholtz, Festschrift zur Feier des Siebenzigsten Geburtstages von Hermann von, 326
Hemeralopia and Scurvy, 564
Hemiamblyopia, Recovery from, 408
Hemianopsia, 408; Case of Double, 572; Horizontal, 572; Inferior, Binocular, and other Sensory Disturbances in a Case of Functional Psychosis, 407; Inferior, with Functional Psychosis, 572; of Central Origin, 572; of Left and Blindness of Right Eye, 572; of Traumatic Origin, 571; Right, after Gunshot Wound of Left Cuneus, 571; Superior, 533; Two Cases of, 572; with Fracture of Skull, 572
Hemiopic Pupillary Reaction, Wernicke's Iridoplegia, 572
Hemorrhage after Use of Nitrate of Silver on Conjunctiva, 444
Hering, Examination of a Case of Total Color-Blindness, 426
Hering's Test, Investigations on Binocular Vision with, 426
Herrnheisser, on Serous Cysts of the Iris, 548
Herter, *The Diagnosis of Diseases of the Nervous System*, reviewed, 454
Hilbert, Pathology of Scintillating Scotoma, 565
Hill-Griffith, the Prognosis of Choroidal Sarcoma, 550
Hirschberg and Cirincione, Hyalin Bodies in the Papilla, 411
Hirschberg, Bloody Myodesopia, 556; Spontaneous Recovery in a Case of Detachment of the Retina in Myopia, 407; Sympathetic Blindness Permanently Cured, 554
Hoche, Binocular Hemianopsia Inferior and Other Sensory Disturbances in a Case of Functional Psychosis, 407
Hodges, Iodide of Silver in the Treatment of Trachoma, 444
HOLDEN, Case of Typical Inferior Coloboma of Iris, 499; Histology of Some of the Rarer Forms of Choroidal Tumors, 76
Hosch Ehrlich's Methylin Blue Method, 424
Homatropia in Refraction Cases, 430
Homatropine and Cocaine, Mixture of, in Refractive Work, 420
Hyaline Formation in Disc and Retina, 568
Hyaloid Artery, Persistent, 424, 556
Hydrogen Peroxide, Use of, in Ophth. Practice, 420
Hydrophthalmus, 552
Hypermetropia, Ophthalmoscopic Appearances of, 430

Injuries, Pathology of, 570; Foreign Bodies, etc., Reports Concerning, 161, 412, 570
Instruments and Remedies, Reports on, 305, 419
Intermittent Fever, Optic Neuritis after, 95
Iridectomy or No, in Cataract Extractions, 557
Irido-Dialysis, Treatment of, 548
Iris, a Rare Tumor of, Removed 548; Coloboma of, 499; Cyst of the, 252; Prolapse of, in Simple Extraction, 558; Reports on Diseases of the, 153, 320, 548; Serous Cysts of, 548; Shield, 213; Syphilis or Tuberculosis of, 548; Tubercle of, Spontaneously Cured, 548
Iritis, Ice in, 549; Syphilitic, with Statistics, 549; with Nodular Neoplasms, 320
Israel, Pulsating Exophthalmus, 442

Jackson, Pressure on the Globe after Cataract Extraction, 558; the Full Correction of Ametropia, 430

JAESCHE, Treatment of Trachoma, 113
Javal, on the Heredity of Myopia, 430.
Javal's Opthalmometer, 333
Jequirity, a Perfectly Safe Remedy in Eye Diseases, 48
Jessop, on the Consensual Pupillary Light Reflex in Cases Exhibiting the Argyll-Robertson Pupil Symptom in One Eye, 418 ; Two Cases of Complete Blindness with Good Pupillary Reflexes, 565
JOHNSON, Observations on the Macula Lutea, 1
Johnson, Eyelashes in Anterior Chamber, 451
JONES, E. L., Tilted Spherical Lens, Effect of, 301
Juler, the Operative Treatment of Pharyngitis, 438 ; Double Congenital Buphthalmus, 552
Jung, Contribution to the Differential Diagnosis of the Tuberculous and Gliomatous Diseases of the Eye, 418

Kalt, Arterio-Venous Aneurism of the Carotid in the Cavernous Sinus, 572 ; on Resection of the Optic Nerve as a Substitute for Enucleation, 568 ; Pathological Anatomy of Buphthalmus, 552
Keratitis, Gouty, 449
Kerato-Conjunctivitis of Rhino-Pharyngeal Origin, 445
Kerato-Conus, Five Cases Treated with the Galvano-Cautery, 540
Kerato-Malacia and Neuro-Retinitis in Meningitis, 414
Keratometry, Further Contributions to, 430
Keratotomy, Accident in, 558
Kessler, Intravaginal Fibro-Sarcoma of the Optic Nerve, 568
Keyser, Conjunctivitis Granulosa, Pumice Stone, 445
KNAPP, Attempt to Remove a Chip of Steel from Background of the Eye Unsuccessful through an Accident which might have been Avoided, 362; Five Cases of Kerato-Conus Treated with Galvano-Cautery, 540; Formation of Dark Angioid Streaks, an Unusual Metamorphosis of Retinal Hemorrhage, 289 ; Glaucoma after Secondary Discission of Cataract Cured by Iridectomy, 293 ; Treatment of Trachoma by Expression of the Morbid Material, 119
Knapp, Contribution to the Tuberculosis Question, 550 ; the Treatment of the Capsule during and after the Extraction of Cataract, 558
Knies, Glaucoma Simplex, 552
KOHN, Optic Nerve Atrophy in a Child, with Severe Cerebral Symptoms, 339
Kostenitch, Pathological Investigations of Gun-Cap Injuries of the Human Eye, 570
Kramer, on Hysterical Stammering, 407
KROTOSCHIN, Development of Myopia, 33

Lachrymal, Apparatus, General Reports on, 140, 313, 435 ; Blennorrhœa of Infants, 436; Gland, Fluxion of, 436 ; Passages, Report on Treatment of, 436 ; Sac, Curettage of, 436 ; Sac, Scraping of, 436 ; Sac Tuberculosis of the, 313
Lamy, Exophthalmic Goitre, 442.
Larvæ Living in the Conjunctival Sac, 110
Lawford, a Case of Recovery From Graves' Disease, 442 ; Eyelashes in the Anterior Chamber, 452
Lawford and Collins, Notes on Glioma Retinæ, with a Report of Sixty Cases, 564 ; Sarcoma of Uveal Tract, with Notes of 103 Cases, 550
Leber, on the Coincidence of Disseminated Choroiditis and Hemorrhagic Retinitis or Retinal Hemorrages in the Same Eye, 550 ; on Weakened Tuberculosis of the Eye 550

Le Fort, Pulsating Exophthalmus, *a propos* of a Case of Ligation of the Two Carotids for this Disease, 442
Lens, Dislocation of, under Conjunctiva, 256; Extraction of Floating, from the Vitreous, 258; Precipitates, 557; Reports on Diseases of the, 156, 324, 537; Traumatic Rupture of Posterior Capsule of, 557
Lenticonus, a Case of, 325
Leroy, a Micrometic Opthalmoscoptometer, 420
Leyden, Hemiopic Pupillary Reaction, the So-Called Wernicke's Iridoplegia, 572
Lids, Lymphoma of, 149; Reports Concerning, 137, 311, 434
Liebrecht, Retrobulbar Neuritis after the Use of Arsenic, 411
Literature, Reports on, 128, 303, 417
Lloyd, an Acute Glaucomatous Attack in the Right Eye of a Colored Man, Æt. 24, Left Eye Destroyed 6 Years Previously by a Pistol Ball, 553
Lombroso, the Visual Field in Epileptics and Feeble-Minded Persons, According to Ottolenghi, 572
LOPEZ, Traumatic Retention of Conjunctival Cyst, 231
Lymphoma of Orbit, 439
Lymph Spaces and Lymph Channels of the Eye, 171

Mackrocki, on the Symptomatology of Commotion of the Retina, 564
Macnamara, Address in Section of Ophthalmology at the Brit. Med. Asso. on Certain Points in Ophthalmic Practice, 558; the Treatment of Infantile Cataract, 557
Macula Lutea, Observations on the, 1
MADDOX, Objective Strabismometry, 56
Magnet Extraction of Piece of Steel in the Vitreous, 412
Manolescu, Brushing of Conjunctival Granulations Combined with Parasiticide, 445; Massage of the Optic Nerve in Certain Cases of Optic Atrophy, 568
Manora, Sympathetic Ophthalmia, 554
MANZ, Congenital Coloboma of the Optic Nerve, 263
Manz, Anatomical Description of a Coloboma of the Optic Nerve, 411; Examination of a Case of Embolism of the Central Retinal Artery, 564
Marchal, Comparison between Resection of the Optic Nerve and Enucleation, 568
MARLOW, Temporary Hypermetropic Astigmatism after Measles, 107
Marple, Grattage for Trachoma, 445
Martin, a Post-Operatory Complication of a Morgagnian Cataract, 558
Massage, Ocular, 445
Mauthner, Polyencephalitis and Sleep, 572
McHardy, Cyst in Anterior Chamber, 452
Measles, Optic Neuritis after the, 95; Temporary Hypermetropic Astigmatism after the, 107
Megrier, a New Optometer, 420
MENDOZA (SUAREZ DE), Treatment of Ulcerations of the Cornea with Acid in a Deliquescent State, 449
Mercury, Perchloride of, in Trachoma and Other Conjunctival Diseases, 444
Metamorphopsia, Binocular, Produced by Correcting Glasses, 204
Meyer, Contribution to the Ophthalmoscopic Diagnosis of Alterations in the Vascular Walls of the Retina, 564
MICHEL, Jequirity, a Perfectly Safe Remedy, 48
Minney, Transplantation in Minor Degrees of Entropium, 434
Mirrors, Models of, for Ophthalmoscopic Examination, 420
Miscellaneous Notes, 166, 455, 578
Mittendorf, One Thousand Cases of Ocular Headache and the Different States of Refraction Connected Therewith, 430

MITVALSKY, On the Pathology of Circumbulbar Dermoid Cysts, 376
Moauro, Granuloma of the Glands of Moll, 434
Morat and Doyen, on the Rôle of the Cervical Sympathetic in the Accommodation for Vision of Distant Objects, 426
Morton, Bilateral Paralysis of the External Recti Following Diphtheria, 439, 573
Motais, on the Refraction of Animals, 424
Movements of Eye, Investigations into Physiology of, 426
Müller, Two Cases of Aneurism of Aorta, 414
Muglich, Spontaneous Recoveries from Retinal Detachment, 564
Mules, Anterior Central Capsular and Pyramidal Cataracts, their Pathology, 557
Murell, to What Extent are Personal Restraints Essential during Healing of Corneal Wounds? 557
Muscles and Nerves, Reports on, 142, 314, 438
Muttermilch, Anatomy of the Chronic Inflammations of the Conjunctiva, 444
Mydriatic Alkaloids, Observations on, 420
Myodesopia, Bloody, 556
Myopia, Development of, 33; Ectasia at Posterior Pole in, 511; Heredity of, 430; Treatment of by Extraction of Lens, 430

Nervous Diseases, the Diagnosis of, 454
Nettleship, Cases of Temporary Blindness during Lactation, 572; Unusual Appearances in a Case of Retinal Embolism about Thirty Hours after its Occurrence, 564
Nieden, on a Case of Blennorrhœic Conjunctivitis in a Child Born in the Membranes, 444
Nikoljukin, Report of 97 Cataract Extractions, 558
NORTON, Removal of Tumor of Optic Nerve, with Preservation of the Eye, 356
Noyes, Hemianopsia, 408
Nystagmus, among South Wales Colliers, 439; in a Compositor, 439; in Ear Affections, 572; Miner's, in North of France, 439

Oatman, the Treatment of Diphtheritic Conjunctivitis by Constant Antiseptic Irrigations, 444
Obliqui, Symmetrical Action of, in Oblique Astigmatism, 430
Ocular Disturbances in Constitutional Affections, Reports on, 162, 414, 571
Ophthalmia, Infectious, Iodine in, 449; Occurring Despite Resection of the Optic Nerve, 553; of New-Born, Iodoform in Prophylaxis of, 444; Purulent, Analysis of Cases of Holmes-Spicer, 444
Ophthalmic Practice, Exceptional Cases in, 570; Hand-Book of, 453; Points in, 558
Ophthalmometer in Practice, 420
Ophthalmometers, Results of, Incorrect, 307, 310
Ophthalmometric Measurements, Accuracy of, 418
Ophthalmometry, Clinical, 420
Ophthalmoplegia Externa with Sarcoma of Neck, 439
Ophthalmoplegiæ, Pathology of, 439
Ophthalmoscope, Optometric and Plakometric, 420
Ophthalmoscoptometer, a Micrometic, 420
Optic, Atrophy with Cerebral Symptoms, 339; Ganglion, Clinical Contributions to Physiology of, 412; Nerve, a Condition of, 567; Anatomical Description of Coloboma of, 411; Congenital Coloboma of the, 263; Changes of, in Sclerosis of Cerebral Arteries, 410; Indications for Simple Resection of, 411; Intravaginal Sarcoma of, 568;

Optic—*continued.*
Myxo-Sarcoma of, 411; Resection of, 161, 411; Resection of, as a Substitute for Enucleation, 568; Reports on Diseases of the, 161, 567; Nerves, Atrophy of, with Acromegaly, 568; Case of Acute Atrophy of, 411; Massage of, in Atrophy, 568
Optometer, a New, 420
Orbit, Osteoma of, 442; General Report Concerning, 144, 317, 441; Secondary Tumors of, 442; Tumor in Each, 442
Orbital Cavity, Stone in, 412
Ostwalt, a few Words in the Correction of Aphakia with Lenses, 558; Clinical Ophthalmometry, 420; Syphilitic Retinitis and its Relations with the Retinal Arteries, and with Syphilitic Arteries of the Encephalon, 564

Panophthalmitis, Bacillus, 550
Papilla, Hyaline Bodies in the, 411
Paralgesia and Ophthalmoplegia, 573
Paralysis, Facial, Associated Movements in, 573
Parent, Models of Mirrors for Opthalmoscopic Examination in the Erect Image, 420; Optometric and Phakometric Ophthalmoscope, 420
Parinaud, Ætiology of Convergent Strabismus, 438; General Considerations on Strabismus, 438; Prolapse of Iris in Simple Extraction, 558
Pathology, Diagnosis, and Therapeutics, 113, 304, 418
Pauw, a Case of Acute Bilateral Atrophy of the Optic Nerves, 411
Percival, the Action and Uses of Prismatic Combinations, 430
Perles, Glioma of the Retina, 564
Peters, Case of Fracture of the Skull with Hemianopsia, 572; on the So-called Lachrymal Blennorrhœa of Infants, 436
Pflüger, Subconjunctival Injections of Trichloride of Iodine, 420
Phillipen, Note on a Case of Pulsating Exophthalmus in a New-born Child, 442
PHILLIPS, Living Larvæ in the Conjunctival Sac, 110
Phlyctenular Diseases, 445
Physiology, Report on, 134, 308, 426
PLANGE, Pigment Striæ in the Retina after Hemorrhage, 282
Polyencephalitis and Sleep, 572
Pooley, Intraorbital Cyst, Probably of a Dermoid Nature, 442; Operation for Secondary Catarrh with Subsequent Iridocyclitis and Glaucoma, 558
POPLAWSKA, Inflammation of the Eye after Injuries from Foreign Bodies, 22
Porywajew, Epibulbar Sarcoma, 450
Prentice, the Prismometric Scale, 420
Preston, Two Cases of Homonymous Hemianopsia, 572
Price, Persistent Hyaloid Artery, 424, 556
Prismatic Combinations, the Action and Use of, 420
Prism Dioptry *vs.* Centrad, 430
Prismometric Scale, 420
Prisms, Numeration of, 431
Progressive Paralysis of the Eye-Muscles, 316
Purtscher, on a New Form of Anterior Synechia Following Blunt Force, 548
PUSEY, Unusual Family History in Two Cases of Glaucoma, 360

Querenghi, Two Cases of Total Achromatopsia, 426
Quinine, Chemosis of Conjunctiva after Use of One Grain of, 259

Ramos, Errors of Refraction in Mexico, Compared with Those of Europe, 430
Randall, the Reformed Numeration of Prisms and the Centrad as a Unit, 431

RANDOLPH, a Valuable Experiment Bearing upon Sympathetic Ophthalmia with a Critical Review of the Subject, 367
Randolph, Hemorrhagic Glaucoma, with an Analysis of Three Cases, 553
Ransohoff, Retinitis Pigmentosa, 564
Ray, Syphilitic Iritis, with Statistics, 549
Recti, External Paralysis of, after Diphtheria, 439, 573
Reflex Micropsia, from Hypertrophied Turbinates, 365; Pupillary Phenomenon, Due to Tænia, 570
Refraction, and Accommodation, Reports on, 135, 309, 430; errors of, in Mexico Compared with Those in Europe, 430; Normal, of Eye, 431; Statistics of, 430
Reports on the Progress of Ophthalmology for 1891, 128, 316, 407, 548
Resection of Optic Nerve, and Enucleation, 568
Retina, Alterations in Vascular Walls of, 564; Anæsthesia of, 565; and Functional Disturbances, Report on, 157, 407, 563; Angioid Streaks after Hemorrhage into the, 289; Detachment of, Recovery, 407; Glioma of, 564; Glioma of, with History of Three Cases in One Family, 407; Hemorrhage of, Showing Scotoma, 408; Hemorrhagic Diseases of, 564; Pigment Striæ in the, after Hemorrhage, 282; Temporary Anæmia of, and Subsequent Changes, 407
Retinæ, Commotio, Symptomatology of, 564
Retinal, Detachment, Cured, 160, 564; Pigmentation, Peculiar Form of, 564
Retinitis, Albuminurica and Pregnancy, 563; Pigmentosa, 564; Syphilitica and its Relations to Arteritis, 564
Retrobulbar Neuritis, 248; after the Use of Arsenic, 411
Reviews, 166, 326, 453
Ried, Pocket Astigmometer, 420
Rindfleisch, Contribution to the Developmental History of Congenital Anomalies of the Eyes, 418
Risley, Incipient Cataract, Etiology, Treatment, and Prognosis, 557
Roberts, Topographical Anatomy of the External Angle of the Eye, from the Point of View of Strabotomy, 438
Rodes, Spontaneous Extraction of a Cateractous Lens, 558
Rosmini, One Hundred and Nine Simple Extractions, 557
RUMSCHEWITSCH, Sarcoma of the cornea, 277

Saemisch, Communications from the Bonn Clinic, 568
Sajeschko, Clinical Contributions to the Question of Transplantation of Conjunctiva, 445
Salzmann, Observation of the Earlier Developmental Stages of a Subretinal Cysticercus, 570
Samelsohn, Metastatic Carcinoma of the Choroid, 550; on Anæsthesia Retinæ, 565
Sarcoma, Epibulbar, 450; of Uveal Tract, 550
SARGENT, Profound Affection of the Eye in Pernicious Anæmia, 39
Sattler, a Case of Bacillus Panophthalmitis, 550
Savage, the Harmonic Symmetrical Action of the Obliqui, in All Cases of Oblique Astigmatism, 430
Schantz, Injury to the Eye by Shot-Wound, Recovery with Complete Vision, 412
Schapringer, a Second Case of Vaccine Blepharitis, 434
Schenk, Ice in Iritis, 549
Schirmer, on the Pathological Anatomy and Pathogenesis of Central Cataract, 557
Schmelew, on the Influence of Cocaine in the Imbibition from the Conjunctival Sac into the Anterior Chamber, 426

Schmidt-Rimpler, a Contribution to the Origin of Sympathetic Ophthalmia, 554
School Children, Vision of, 430
Scotoma Scintillans, Pathology of, 565
Scott, Perchloride of Mercury in the Curative Treatment of Trachoma and other Conjunctival Diseases, 444
SEABROOK, Squint Statistics, 234
Seabrook, the Natural Course of Cataract, 558
Sedan, a Word on the Employment of Tincture of Iodine in Ulcers of the Cornea, 445
Seggel, the Diseases of the Eye in Diabetes Mellitus, 572
Sgrosso, Contribution to the Casuistic of Osteoma of the Orbit, 442
Sharkey, on Graefe's Lid-Sign, 442
Shot Wound, Injury to Eye by, 412
Siderosis of the Globe, 570
Sight, Loss of, after Injuries to Head and Back, 573
Silex, Corneal Transplantation, 450
Simi, Alcohol and Tobacco Amblyopia, 408; Asepsis in Opthalmic Surgery, 420; Ophthalmia and the Spring, 414; the Tincture of Iodine in Infectious Ophthalmia, 449
SIMS, Papilloma of Conjunctiva, Encroaching on the Cornea, 91
Simulation of Visual Disturbances, Methods of Detection of, 408
Skiascopy, 420
Smith, Eugene, a New Method of Operating on Frog-Spawn-like Oculo-palpebral Folds, 445; How shall We Treat the Capsule? a New Cystitome Forceps, 558; Treatment of Irido-Dialysis from Contusions, Partial Iridenkleisis with or without Rupture, 548
Snell, Case of Nystagmus in a Compositor, 439; Immediate Loss of Sight after Injuries to Head and Back, 573; on Miner's Nystagmus, 439
Snellen, Skiascopy, 420
Soda, Cantharidate of, in Ophthalmology, 73
SPALDING, Idiopathic Vitreous Hemorrhages, 220
Specht, a Critical Review of the Methods for Detecting Simulation or Aggravation of Visual Disturbances, 408
Spender, on Points of Affinity between Rheumatoid Arthritis, Locomotor Ataxy, and Exophthalmic Goitre, 415
Spherical Lenses, Effect of Tilted, on Vision, 301
Spierer, Recovery from Hemiamblyopia Due to Fright, 408; Kerato-Malacia of the Left and Neuro-Retinitis of the Right Eye in Course of a Meningitis, 414
Spring, Ophthalmia in the, 414
Squint, Statistics of, 234
Staderini, on the Exits of the Aqueous Humor, 426
Stammering, Hysterical, 407
Starkey, An Experimental Study of the Comparative Mydriatic Effect of Atropia and Homatropia, 431
Stephenson, a Peculiar Form of Retinal Pigmentation, 564
Stilling, on the Experimental Production of Exophthalmus, 418
Story, Detachment of the Choroid, 550; Temporal Hemianopsia of Left and Blindness of Right Eye, 572; the Ophthalmometer in Practice, 420
Strabismometry, Objective, 56
Strabismus, Ætiology of Convergent, 438; Cases of Muscular Advancement, 438; General Considerations on, 438; Operative Treatment of, 438
Straub, Case of Corneal Fistula and Traumatic Astigmatism Cured by Operation, 452
Subconjunctival Injections, of Sublimate, 419; of Trichloride of Iodine, 420; Therapeutic Value of, 420

Sulzer, the Form of the Human Cornea and its Influence on Vision, 426
Surgery, Contribution to, 415
Swanzy and Werner, a Case of Double Hemianopsia, 572
Sym, Albinism, a Curious Family History, 418
Sympathetic, Blindness, Permanently Cured, 554; Ophthalmia, 554; an Experiment Bearing upon, 367; Despite Resection of Optic Nerve, 323, 554; Origin of, 554; Reports Concerning, 155, 323, 554
Synchronous Movements of Upper Lid and Lower Jaw, 354
Synechia, Anterior, Following Blunt Force, 548
Synergetic Ocular Movements, 342

Tabes, Ætiology of, 572
Tears, Blood-Stained, 436
Terson, Report on the Treatment of Affections of the Lachrymal Passages, 436
Theodor (Carl), Duke of Bavaria, a Case of Cornu Cutaneum of the Right Superior Eyelid, 434
Thompson, a Case of Retinal Hemorrhage Showing Scotoma, Embolism of a Branch of Retinal Artery, 408; Miner's Nystagmus among the South Wales Colliers, 439; Monocular Diplopia, 573; Note on Förster's Artificial Ripening of Cataract, 558
THOMPSON, J. H., Fatal Result of Enucleation, 63
Thompson, J. T., Emphysema of the Conjunctiva, 445
Trachoma, and its Treatment, 445; Blue Stone and Silver in, 148; Case of Pseudo-, 505; Iodine of Silver in Treatment of, 444; Operations for, 151; Pathology and Ætiology of, 445; Recent Views on Pathology of, 445; Treatment of, 113
Transplantation, Operations for, 140
Trousseau, Concerning Resection of the Optic Nerve, 568; Fluxion of the Lachrymal Gland, 436
Tuberculin in Eye Diseases, 306
Tuberculosis, Contribution to Question of, 550; of Choroid, etc., 550; Weakened, of Eye, 550
Tuberculous and Gliomatous Diseases, Differential Diagnosis of, 418
Tumor of Optic Nerve Removed, with Preservation of Eye, 354

Uhthoff, Examination of the Visual Learning of a Child of Seven, Born Blind, but Successfully Operated, 557; on the Doctrine of the Metastatic Carcinomata of the Choroid, 550
Ulcer, Rodent, of Lids, 434
Ulcers of Cornea, Iodine in, 445

Vacher, Treatment of Progressive Myopia and Prophylaxis of Detachment of the Retina, by Extraction of the Transparent Lens, 430
Valude, Anatomy of the Chronic Inflammations of the Conjunctiva, 444; Epithelioma of the Inner Angle of the Eyelids, 434; of the Sclero-Corneal Limbus, 449; Prophylaxis of the Ophthalmia of the New-Born by the Use of Pulverized Iodoform, 444
Van Duyse, Persistence of Cloquet's Canal, Remains of the Fœtal Hyaloid System, Coloboma of Optic Nerve, 554
Van Fleet, Retinitis Albuminurica and Pregnancy, 563; the Normal Refraction of the Eye, 431
Vaurelle, Contribution to the Study of the Ætiology of Epidemic Hemeralopia, and of its Relations to Scurvy, 564
Vision, Curious Case of, 573; of Railway Servants, Discussion on, 420

Visual, Acuity, Examination of, after Extraction, 558; Education of Child Born Blind, and Successfully Operated, 557; Field, Alterations, of, in Functional Nervous Disturbances, etc., 565; Field, in Epileptics and the Feeble-Minded, 572; Field, Typical Defects of, in Functional Nervous Disturbances, 408
Vitreous, Idiopathic Hemorrhages into, 220; Reports on, 155, 323, 556

Wagenmanr, on the Occurrence of Giant Cells and Purulent Exudation in the Region of an Intraocular Cysticercus, 570; Pathological Anatomy of Retinitis Pigmentosa, 564
Wagner, on the Question of the Curability of Glaucoma, 553; Rodent Ulcer of the Eyelids, 434; the Operation of Entropium, 434
Webster, a Case of Choked Disk with Unimpaired Vision, 568
WEBSTER and HOLDEN, a Case of Sarcoma of the Choroid and Ciliary Body, 528.
Weeks, La Grippe as a Cause of Retrobulbar Neuritis, and Other Ocular lesions, 568; Surgical Treatment of Granular Lids, 445
WEISS, Sharp-Cut Ectasia at the Posterior Pole in High-Grade Myopia, 511
Wherry, a Case of Paralgesia and Ophthalmoplegia, 573
WHITE, Remarks on Immature Cataract and the Best Method of Hastening Maturity, 516
Wilbrand, on Typical Defects of the Visual Field in Functional Disturbances of the Nervous System, 408; on Alterations in the Visual Field in Functional Disturbances of the Nervous System, and on the Oscillating Visual Field, 565
Williams, R., a Case of Arterio-Venous Anastomosis Communication in the Orbit, 442; a Case of Horizontal Hemianopsia, 572; a Case of Alexia, 572; Modification of the Ordinary Operation for the Advancement of the Tendon of the Rectus Muscles, 439
Wilmer, a New Lachrymal Drill, 436
Wilson, H., Hereditary Congenital Cataract, 557
Wood, Electro-Magnetic Extraction of Piece of Steel from the Vitreous Chamber of the Eye, 412; Mixture of Homatropine and Cocaine as a Substitute for Atropine and Duboisine in the Determination of Refractive Errors, 420
Wood, T. H., Ossification of Choroid, 550
Woods, Optic Neuritis after the Measles and Intermittent Fever, 95
WOODWARD, Fifty-Four Cases of Cataract Extraction, 398
Wounds, Penetrating, of Eye, 457
Wray, Points in the Treatment of Lamellar Cataract, 557; Suggested Technique to Prevent Strain on the Supra- and Infra-Corneal Sutures during the Re-attachment of the Advanced Muscles, 438
Wuerdemann, a Simple Skiascope, 420; Fibro-Sarcoma of the Neck with Temporary Ophthalmoplegia Externa and Sympathetic Paralysis, 439

Xerosis, Various Papers on, 148

ZIMMERMAN, Vaccine Blepharitis, 215
Zonula of Zinn, Development and Abnormalities of, 424

GENERAL INDEX TO VOLUMES XV. TO XXI., INCLUSIVE.

Abadie, Therapeutic Value of Medicamentous and Subconjunctival Injections, xxi., 420

Accommodation, and Convergence, Points with Reference to Connection between, xxi., 430; and Refraction, Instrument for Demonstration of, Howe, xv., 259; Unequal in Healthy Eyes and in Anisometropia, Fick, xviii., 292

Achromatopsia, Two Cases of Total, xxi., 426; Third Case of, xxi., 309

Acromegaly with Tabic Symptoms and Bilateral Hemianopsia, xxi., 414

ADAMUECK, Three Cases of Bony Ocular Tumors, xix., 234

Adamueck, *Text Book of Eye Diseases*, Review, xv., 100

Advancement, Modification of Ordinary Method, xxi., 439; of Muscles, Technique of Sutures in, xxi., 438

Agnew, Obituary Notice of, xvii., 129

Albinism, a Curious Family History, xxi., 418

Alcoholism, Effects of, on System, xvi., 366

Alexander, *Syphilis and the Eye*, Review, xviii., 124

Alexia, Case of, xxi., 572

Amaurosis, after Loss of Blood, xviii., 112; Cases of, xv., 131, 137, 382, 393

Amblyopia, Alcoholic during Cuban War, xxi., 568; from Tobacco and Alcohol, xxi., 408; Reflex, xxi., 573; Cases of, xv., 137, 382; Congenital, xvii., 390; Discussion Concerning Toxic, xvii., 388; from Astigmatism, xx., 560; Toxic, xix., 102; with Fluid from Nostrils, xviii., 113

Ametropia, Choroido-Retinitis of, Gould, xix., 30; Full Correction of, xxi., 430

Amyloid in the Cornea of a Staphylomatous Eye, Beselin, xvi., 313

Anæmia, Affection of the Eye, in a Case of Pernicious, Sargent, xxi., 39

Anastomosis, Arterio-Venous, in Orbit, xxi., 442

Anatomy, Reports on, xv., 107, 218, 350; xvi., 89, 222, 328, 463; xvii., 99, 234, 368, 496; xviii., 216, 492; xix., 310, 505; xx.. 423, 556; xxi., 131, 307, 424; Topographical, of External Angle of Eye, xxi., 438

Aneurism of Carotid in Cavernous Sinus, xxi., 572

Aniline Dyes in Ophthalmology, xx., 143

Animals, Refraction of, xxi., 424

Anomalies, of Refraction and Accommodation, Reports on, xv., 113, 222, 353; xvi., 94, 227, 333, 464; xvii., 103, 237, 373, 498; xviii., 217, 333, 498; xix., 312; xx., 148, 429, 558; xxi., 135, 309, 430; Congenital, at Posterior Pole of Eye, Birnbacher, xv., 257

Anterior Chamber, Cyst of, xxi., 452; Eyelashes in, xxi., 451
Antiseptics, Bacteriological Investigation into the Chief, Weeks, xvi., 375
Aorta, Aneurism of, xxi., 414
Aphakia, Correction of, with Lenses, xxi., 558; on the Question of Accommodation in, Silex, xviii., 274
Aqueous Humor, Secretion of the, xx., 556; xxi., 132; Exits of, xxi., 426
Argyll-Robertson, Case of Wound of the Sclerotic with Penetration of Eyelashes into the Anterior Chamber, xxi., 452; on a Modification of the Ordinary Method of Operating for Advancement of the Tendon of the Rectus Muscles, xxi., 439
Arlt, Ferd. Von, Obituary Notice of, xvi., 370
Arterial Sclerosis, Ophthalmological Examinations in, xxi., 414
Asepsis in Ophthalmic Surgery, xxi., 420
Astengo, Enormous Stone in the Orbital Cavity, xxi., 412
Astigmatic Accommodation, xxi., 310
Astigmatism against the Rule and the Associated Symptoms, xxi., 430; a New Device for Measuring, Gould, xviii., 435
Astigmometer, Pocket, xxi., 420
Atropia and Homatropia, Comparative Effect, xxi., 431
Atropine, Effects of, xvii., 98; Phenomena, xvi., 93
Auber, on the Accuracy of Ophthalmometric Measurements, xxi., 418
Axenfeld, on the Development of Lymphoma in the Orbit, xxi., 439
AYRES, Granulations of Conjunctiva from Prolonged Use of Cocain, xvii., 265; Ischæmia of Retina, xv., 4
Ayres, *Oculist's Index Rerum*, Review, xx., 472; Papilloma of the Cornea, xxi., 449
Bacteria, Experiments with, Knapp, xv., 24
BALDWIN, Excessive Hemorrhage Following Extraction of Cataract, xviii., 328
Bandage, New, for Simple Extraction, xxi., 558
Baquis, Histological Changes Following Temporary Anæmia of the Retina, xxi., 407
Baratz, on a Case of Embolism of the Central Retinal Artery with Unusual Appearances in the Fundus of the Eye, xxi., 564
Barr, Extraction of Incipient Cataract, xxi., 557
Bartholow, a Few Observations on the Mydriatic Alkaloids, xxi., 420
Basedow's Disease, Paresis of Convergence in, xxi., 415; Symptomatology of, xxi., 414
Batten, Some Points on the Relationship of the Eye to the Cardio-Vascular System, xxi., 414
BAXTER, Congenital Corectopia, xx., 108; Punctured Wounds of the Eye in Children, xx., 340; Punctured Wound of Sclera, Recovery, xx., 57
BEARD, Relief of Epilepsy by Correction of Convergent Strabimus, xix., 144
BEAUMONT, Sequelæ of Influenza, xx., 59
BEAVER, Urethral Stricture as a Cause of Hyperæsthesia of the Retina, xv., 163
BERGER, Prolapse of Retina into Anterior Chamber, xvi., 26; Visual Disturbances in Tabes, xix., 429
BERNHEIMER, Congenital Staphyloma of Cornea, xvii., 417; Development and Course of the Medullated Fibres in the Human Optic Chiasma, xx., 163; on Changes in the Optic Nerve in High Degrees of Sclerosis of the Cerebral Arteries, xxi., 410; a Certain Condition in the Optic Nerve, xxi., 567

Berry, Critical Remarks on the Theories of Fundamental Color-Sensation, xxi., 426; Note on an Unusual Result of Cataract Extraction, xxi., 558; Note on the Individual Differences in the Degrees of Latent Lateral Deviations of the Eye on Looking Upward and Downward, xxi., 438; on Some Points with Reference to the Connection between Accommodation and Convergence, xxi., 430; *Diseases of the Eye*, Review, xviii., 368

BESELIN, Zonular Cataract in an Adult, xvii., 318

Bicycle Spectacles, xxi., 420

Bifocal Lenses, an Improvement in, Gould, xviii., 432

BIRNBACHER, Congenital Anomaly at Posterior Pole of Eye, xv., 254; the Cilio-Retinal Blood-Vessels, xvi., 32

Bissell, Spasm of the Ciliary Muscle, xxi., 549

BLACK, Does Javal's Ophthalmometer Render the Use of Atropine Unnecessary? xxi., 333

Blennorrhœa, in Child Born in Membranes, xxi., 444; neonatorum, gonococci in, xv., 232

Blepharitis, Vaccine, Zimmerman, xxi., 215

Blepharoplasty, xix., 318

Blickhahn, a Case of Chancre of the Right Upper Eyelid, xxi., 434

Blind, Statistics of the, Magnus, xv., 51

Blindness, xvii., 95, 364; Etiology of, in 32,000 Eye Patients, Hansell and Bell, xxi., 51; Magnus on, xvi., 218; Report on the Prevalence of, in the U. S., xxi., 163; Temporary, during Lactation, xxi., 572; with Good Pupillary Reflexes, xxi., 565

Bliss, a Curious Case of Vision Dependent on the Use of Both Eyes, xxi., 573

BOÉ, a Case of Homonymous Superior Hemianopsia, xxi., 533

Boé on Sympathetic Ophthalmia, xxi., 554

Bohne, *Hand-Book for Opticians*, Review, xvii., 528

Bone in the Vitreous or Retina, Burnett, S. M., xxi., 254

Bonn Clinic, Contributions from, Saemisch, xxi., 568

Bony Tumors of the Eye, Adamueck, xix., 234

Bordecker, a Case of Chronic Progressive Paralysis of the Eye Muscles in a Paralytic from Tabes, xxi., 415

Bowman, Sir William, Obituary Notice of, xxi., 330

BRADFORD, Transplantation of Rabbit's Eye with Subsequent Enucleation, xvi., 182

Brailey, on Some Points in the Development of Cataract, xxi., 557; on Sympathetic Ophthalmia, xxi., 554

Brain Disease, and Eye Symptoms, xviii., 364

Brand, the Nerve Terminations in the Cornea, xviii., 456

BRIGGS, a new Instrument for Optico-Ciliary Neurotomy, xvi., 37

Bristowe, the Ophthalmoscopic Appearances of Hypermetropia and their Significance, xxi., 430

British Medical Association, Discussion on the Vision of Railway Servants, xxi., 420

Bronner, Fifty Cases of Strabismus in which the Rectus Muscle was Advanced according to the Method of Schweigger, xxi., 438

Brossage, Cases of, xxi., 444

Brown, Glioma of Retina, with History of Three Cases in One Family, xxi., 407

Brushing in Trachoma, xxi., 445

Buck, *Reference Hand-book of Medical Sciences*, Review, xv., 256

BULL, O., Synergetic Ocular Movements, xxi., 342; Another Case of Synchronous Movements of the

BULL, O.—*continued.*
Upper Lid and Lower Jaw, xxi., 354; Paralysis of Right Oculomotor, and Left Abducens, xvii., 144; Unilateral Tonic Spasm of Ciliary Muscle from Pressure on Carotid, xvii., 149
Bull, C. S., Tumors of the Orbit, Secondary or Consecutive to Tumors of the Neighboring Bony Cavities, xxi., 442
Buller, Injury to the Eye from Lightning Stroke, xvii., 131
Bunge, Siderosis of the Globe, xxi., 570
Buphthalmus, Double Congenital, xxi., 552; Pathological Anatomy of, xxi., 552
BURNETT, S. M., Contributions to Clinical Ophthalmology, xxi., 248; Skiascopy, with Description of an Apparatus, xix., 260; Tuberculosis of the Conjunctiva, xix., 113
Burnett, S. M., Further Contributions to Keratometry, xxi., 430; the Prism Dioptry *vs.* the Centrad, xxi., 430; Recent Views on the Pathology of Trachoma, xxi., 445; *Treatise on Astigmatism*, Review, xvi., 249
Butcher's Conjunctivitis, xviii.

CALLAN, Temporary Exophthalmus and Ophthalmoplegia Externa Following Influenza, xx., 327
Calomel, Abscesses, xvii., 367; Hypodermatic Use of, xix., 331
Cantharidate of Soda, Santos Fernandez, xxi., 73
Capei, Tincture of Iodine in Infectious Ophthalmia, xxi., 449
Capsule, Division of, during the Corneal Section in Extraction, Knapp, xviii., 169; Treatment of Lens, xxi., 558
Capsulotome Knife, xxi., 420
Carcinoma, Cases of Epibulbar, Heyder, xvii., 458; Cases of Metastatic, Mitvalsky, xx., 237
Cardio-Vascular System, Relation of Eye to, xxi., 414
Carpenter, Tuberculosis of Choroid, xxi., 550
Carredy, Congenital Corectopia, xxi., 549
Caruncle, Adenoma of the, Prudden, xv., 1
Cataract, Artificial, Production of, by Naphthaline, xvi., 483; a New Dressing after Extraction of, Gifford, xix., 42; Case of Uniocular Zonular, D'Oench, xx., 258; Central, Pathology and Pathogenesis of, xxi., 557; Dark Rooms and Bandages Discarded after Extraction of, Michel, C., xv., 318; Death after Extraction of, xvi., 485; Death after Extraction of, Webster, xviii., 449; Death after Extraction of, with Panophthalmitis, Webster, xvii., 25; Development of, xxi., 557; Discussions on Extraction of, xix., 344; Excessive Hemorrhage following Extraction of, Baldwin, xviii., 328; Extraction, Apparatus for Protection after, xxi., 558; Extraction, 54 Cases, xxi., 598; Extraction, High Degree of Astigmatism after, Improved by Operation, Schioetz, xvii., 295; Extraction, Pressure on Globe after, xxi., 558; Extractions, Report, of 97, xxi., 558; Extraction, Unusual Result of, xxi., 558; Extraction, *Résumé* of over 5,000 Operations for, xviii., 233; Extraction without Iridectomy, First Report on, Knapp, xvi., 54; Foerster's Ripening of, xxi., 558; Four Hundred and Fifty Simple Extractions of, Greeff, xx., 303; Glaucoma, after Discission of Secondary, Knapp, xxi., 293; Hereditary Congenital, xxi., 557; Incipient, Extraction of, xxi., 557; Incipient, Etiology, Treatment, and Prognosis, xxi., 557; Infantile, Treatment of, xxi. 557; Influence of Albuminuria on Formation of, xvi., 483; Intraocu-

Cataract—*continued.*
lar Hemorrhage after Extraction of, Hilemann, xvii., 268; Intraocular Hemorrhage after Extraction of, xix., 341; Lamellar, Treatment of, xxi., 557; Maturing of, xxi., 516; Operations, xxi., 557; Natural Course of, xxi., 558; One Hundred Extractions of, with Plaster on Lids, Chisolm, xvii., 1; One Hundred Simple Extractions of, Knapp, xvii., 51; Operations for Primary and Secondary, Schweigger, xvi., 253; Papers (see Lens); Post-Operatory Complication, xxi., 558; Report on a Third Hundred of Simple Extractions of, Knapp, xix., 280; Report of 25 Extractions of, Minor, xx., 60; Report of 200 Extractions of, Kerschbaumer, xx., 349; Report of 304 Extractions of, xx., 452; Rheindorf's Report on Extraction of, Rheindorf, xvii., 437; Recovery from Hernia of Iris after Extraction of, Harlan, xx., 81; Removal of, with Aid of Intraocular Injections, xviii., 102; Result of 206 Extractions of, St. John Roosa, xx., 207; *Résumé* of 1,600 Extractions of, xviii., 341; Second Series of One Hundred Simple Extractions of, Knapp, xviii., 1; See Papers under "Lens," Reports of, Spontaneous Extraction of, xxi., 558; Statistics of 1,000 Cases of Extraction of, xviii., 103; Suture of Cornea, in Cases of, xix., 344; the Cause of Senile, Schoen, xviii., 322; Vitreous Hemorrhage after Extraction of, Knapp, xx., 78; Zonular, xxi., 557; Zonular in an Adult, Beselin, xvii., 318

Cataracts, Anterior Capsular and Pyramidal, xxi., 557

Cautery, Use of, in Removing Neoplasm from the Eye, Millikin, xvi., 409

Ceccarini, Obituary Notice of, xviii., 245

Cerebral Tumor, Analysis of 197 Fatal Cases, xv., 253

Cervical Sympathetic, Rôle of, in Accommodation for Distance, xxi., 426

Chancre of Lid, xxi., 434

Charnley, a Rare Tumor of the Iris Removed by Operation, xxi., 548

CHEATHAM, Acute Mania Following Enucleation, xix., 60; Affection of Neuro-Retinal Circulation, xix., 61; Trachoma and its Treatment, xxi., 445

Cheney, a Case of Retraction of the Eyeball, xxi., 442

Chevallereau, Gouty Keratitis, xxi., 449

Chiasma, Course and Development of the Medullated Fibres at the, Bernheimer, xx., 163

Chibret, Aspiration in the Extraction of Cysticercus in the Vitreous, xxi., 412; Iodine in Infectious Ulcers of the Cornea, xxi., 445; Pathogeny of Affections of the Conjunctiva in a Bacteriological Point of View, xxi., 444

CHISOLM, One Hundred Cataract Extractions, xvii., 1; Varicose Tumor of Lower Eyelid, xvii., 151

Chisolm, Homatropia in Refractive Cases, xxi., 430; the Value of Weak Cylinders in the Cure of Spasm of the Ocular Muscles, xxi., 430

Choked Disk, and Œdema of the Optic Nerve-Trunk, xviii., 53; and Consecutive Atrophy of the Optic Nerve, Ulrich, xviii., 71; Causation of, Schmidt-Rimpler, xvii., 121, 397; with Unimpaired Vision, xxi., 568

Cholesterine in the Eye, Tangemann, xvii., 447

Choroid, Binocular Absence of the, Cowgill, xxi., 105; Carcinoma of, xxi., 550, 551; Detachment of, Elschnig, xxi., 272, 550; Detachment of the, after Extraction, Groenouw, xviii., 277; Horizontal

Choroid—*continued.*
Rupture of the, xvii., 392; Metastatic Carcinoma of the, Schultze, xix., 226; Nasal Coloboma of, De Schweinitz and Randall, xvii., 454; Ossification of, xxi., 550; Ossification of the, Wood, T. H., xix., 361, 388; Prognosis of Sarcoma of, xxi., 550; Rarer Forms of Tumor of the, Holden, xxi., 76; Reports on, xv., 237, 373; xvi., 122, 237, 347, 478; xvii., 249, 384; xviii., 97, 228, 346; xix., 93, 332, 522; xx., 278, 445, 570; xxi., 154, 320, 550; Rupture of, by a Rifle-Ball, Clark, xviii., 12; Sarcoma of, xxi., 155, 528; Sarcoma of, with Metastatic Infiltration, Webster, xvii., 29; Tuberculosis of, xxi., 550
Choroiditis Disseminata, with Good Vision, Randolph, xviii., 438; and Retinitis Hemor. in Same Eye, xxi., 550
Ciliary, Body, Glands of, xxi., 424; Body, Myoma of the, xix., 521; Muscle, Anatomy of the, xx., 140; Muscle, Spasm of, xxi., 549; Muscle, Tonic Spasm from Pressure on Carotid, Ole Bull, xvii., 149; Muscle, Varying Spasm of, xvii., 238
Cilio-Retinal Blood-Vessels, Birnbacher, xvi., 32
Circulation, Affection of Neuro-Retinal, Cheatham, xix., 61; of Eye in Disease, xviii., 121
Cloquet's Canal, Coloboma of Optic Nerve, xxi., 554
CLARK, Isolated Rupture of Iris and Choroid by a Rifle-Ball, xviii., 12
Clarke, Eyelash in Anterior Chamber, xxi., 452
Cocain, Granulations of Conjunctiva from Prolonged Use of, Ayres, xvii., 265; Influence of, on Imbibition, xxi., 426; Papers on, xv., 235; xvi., 120; xvii., 495
Coccius, Obituary Notice of, xx., 160
COHEN, Form of the Orbit in Myopia, xviii., 251
Cohn, on Nystagmus in Ear Affections, xxi., 572
Collins, on the Development and Abnormalities of the Zonula of Zinn, xxi., 424; the Glands of the Ciliary Body in the Human Eye, xxi., 424; a Late Epithelial Implantation Cyst in a Shrunken Globe Twenty-eight Years after Receipt of Injury, xxi., 556; Extensive Rupture of the Posterior Capsule of the Lens Following a Blow on the Eye from a Stone, xxi., 557; on the Operative Treatment of Glaucoma, xxi., 553; on the Pathology of Intraocular Cysts, xxi., 452; on a Case of Tumor in Each Orbit, Death, Necropsy, xxi., 442
Collins and Wilde, the Pathology of the Ophthalmoplegiæ, xxi., 439
Colloid excrescences, xxi., 564
Coloboma, Extra-Papillary, Johnson, xix., 1
Color, Blindness, Case of Total, xv., 221; xxi., 426; Reports on physiology of, xv., 113, 221; Review of Tests for, xxi., 427; Sense, testing of the, Seggel, xviii., 247; Sensation, Theories of, xxi., 426
Congenital Anomalies, Developmental History of, xxi., 418
Conical Cornea, Perforation with Galvano-Cautery, xxi., 450
Conjunctiva, Affections of, from Bacteriological Point of View, xxi., 444; Anatomy of Chronic Inflammations of, xxi., 444; Cornea, Sclera, Anterior Chamber, Reports on the, xv., 119, 231, 362; xvi., 112, 233, 342, 471; xvii., 109, 243, 380, 513; xviii., 224, 340, 509; xix., 324, 515; xx., 371, 438, 566; xxi., 148, 317, 444; Diffuse Lymphoma of, xxi., 445; Emphysema of, xxi., 445; Hemorrhage, Following Use of Silver Nitrate, into the, xxi., 318; Papilloma of, Encroaching on the

Conjunctiva—*continued.*
Cornea, xxi., 91 ; Periodic Congestion of the, xxi., 260; Follicular Diseases of the, xvii., 516 ; Lemon Juice in Diphtheria of, xvi., 115 ; Micro-Organisms in the Causation of Diseases of the, Gifford, xv., 180 ; Papilloma of the, Fuchs, xx., 537 ; Pemphigus of the, xv., 121 ; Polypoid Tumors of the, Elsching, xviii., 255 ; Transplantation of, xxi., 445 ; Traumatic Retention Cyst of the, Lopez, xxi , 231 ; Tuberculosis of, S. M. Burnett, xix., 113 ; Tuberculosis of the, Knapp, xix., 78 ; Two Cases of Papilloma of the, Sims, xxi., 91 ; Vaso-Motor Periodic Congestion of the, Burnett, S. M., xxi., 260 ; Xerosis of, xv., 121 ; Xerosis of, in Children, Weeks, xv., 332
Conjunctival Catarrh, Bacillus of, Weeks, xv., 441 ; Sac, Living Larvæ in the, Phillips, xxi., 110
Conjunctivitis, Diphtheritica, Treatment of, by Antiseptic Irrigations, xxi., 444 : Granular, Pumice Stone, xxi., 445 ; Gonorrhoic, without Inoculation, Hattenhoff, xv., 169
Consensual Pupillary Reaction in Monocular Argyll-Robertson Pupil, xxi., 418
Contact Lens, Fick, xvii., 215
Contagious Eye Diseases, xxi., 417
Corectopia, Case of Congenital, Baxter, xx., 108 ; Congenital, xxi., 549
Cornea, Action of Epithelium of, xvii., 114 ; and Conjunctiva, Epithelioma of, xxi., 445 ; Blood-stains of, xxi., 449 ; Cautery in Infiltration of the, Knapp, xv., 233 ; Congenital Staphyloma of, Bernheimer, xvii., 417 ; Correction by Glasses of Anomalies in the, Purtscher, xv., 264 ; Epithelial Plaque of, xxi., 449 ; Fistula and Astig. of, Cured by Operation, xxi., 452 ; Foreign bodies in the, Ritter, xviii., 281 ; Form of, and its Influence on Vision, xxi., 426 ; Granuloma of, Reuling, xvi., 210 ; Hemorrhage into the, xvii., 113, 522 ; Melanotic Epithelioma of the, xvii., 521 ; Nodular Opacities of the, Groenouw, xix., 245 ; Papilloma of, xxi., 449 ; Sarcoma of the, xxi., 277; Sarcoma of the, Rumschiewitsch, xxi., 277 ; Successful Transplantation of the, xxi., 153; the Nerve Terminations in the, Brand, xviii., 456 ; Transplantation of, xxi., 450 ; Ulcers of, Treatment with Acids, xxi., 449 ; Wrinkling of the, xxi., 261 ; Wrinkling of the, Burnett, S. M., xxi., 261
Corneal Wounds, Personal Restraint in Healing of, xxi., 557
Cornu Cutaneum, Case of, xxi., 434
Corrigenda, xx., 586
Cortical Blindness, xx., 293
Couetoux, Bicycle Spectacles, xxi., 420 ; on Kerato-Conjunctivitis of Rhino-Pharyngeal Origin, xxi. 445
Cowell, a Case of Acromegaly with Atrophy of Both Optic Nerves, xxi., 568
Cowgill, Binocular Absence of the Choroid, xxi., 105
Critchett, a Capsulotome Knife, xxi., 420 ; Conical Cornea, Treated with the Galvano-Cautery, with Perforation, xxi., 450 ; Exceptional Cases in Ophthalmic Practice, 570
Critchett and Juler, Epithelioma of the Cornea and Conjunctiva, xxi., 445
Cross, Blood-Stained Tears, xxi., 436 ; Hydrophthalmus, xxi., 552 ; Iridectomy or No, in Cataract Extractions, xxi., 557
Cullimore, Advancement of Plica Semilunaris, xvii., 22
Culver, Correlation of Cranial and Oculo-Orbital Conformations, xxi., 68
Cyclopia, Mode of Formation of, xxi., 418
Cylinders, Value of Weak, xxi., 430
Cyst, Epithelial, in Shrunken Globe, xxi., 556 ; of Orbit, xxi., 442

Cysticerci, Operations for, xv., 388
Cysticercus, Cases of, xv., 135, 242, 387; Extraction of, xvi., 142; in Vitreous, Aspiration in Extraction of a, xxi., 412; Early Developmental Stages of, xxi., 570; Giant Cells and Purulent Exudation in Region of a, xxi., 570; Removal of, from the eye, Treitel, xix., 217

Dacryocystitis, Operative Treatment of, xxi., 436
Dareste, on the Mode of Formation of Cyclopia, xxi., 418
Darier, Presentation of Cases in which Brossage had been Performed, xxi., 445; Subconjunctival Injections of Sublimate in Ocular Therapeutics, xxi., 419
DAVIS, A. E., The Retinal Light-Streak, xx., 44
Davis, Contagious Eye Diseases with Statistical Remarks, xxi., 417
DEBECK, Congenital Coloboma of Iris, xv., 8
Debierre, a Case of Acromegaly with Tabic Symptoms and Bilateral Hemianopsia, xxi., 414
De Bono, Alterations of Retinal Epithelium and Colloid Excrescences, xxi., 564
Debove, Associated Movements in Facial Paralysis, xxi., 573
Denti, a Very Rare Reflex Pupillary Phenomenon, Due to Tænia, xxi., 570
Dermoid Cysts, Circumbulbar, Pathology of, Mitvalsky, xxi., 376
DE SCHWEINITZ, Neuro-Paralytic Keratitis with Microscopical Examination of the Eye, xx., 26
De Schweinitz, A Case of Persistent Hemorrhage from the Conjunctiva of an Infant, following the Instillation of a Solution of Nitrate of Silver, xxi., 444; *A Handbook of Ophthalmic Practice*, Review, xxi., 453; a Note on Fluorescin Coloring and the Actual Cautery in Corneal Ulcers, xxi., 445; One Hundred Cases of Astigmatism against the Rule and the Associated Symptoms, xxi., 430; Perimetric Observations on the Influence of Eserine and Iridectomy in Chronic Glaucoma, xxi., 553
DE SCHWEINITZ and RANDALL, Nasal Coloboma of Choroid, xvii., 454
Despagnet, Curettage of the Lachrymal Sac, xxi., 436; Tubercle of the Iris, Spontaneously Cured, xxi., 548
Deviations, Latent, of the Eye in Looking Up and Down, xxi., 438
De Wecker, Scraping of the Lachrymal Sac, xxi., 436; the Indications for Simple Resection of the Optic Nerve, xxi., 411
Diabetes and Iritis, xv., 392; the eyes in, Kamocki, xvii., 41
Diplopia Monocular, xxi., 573
Distichiasis, Operations for, Smith, W. F., xvi., 117; Jaesche, xix., 411
Divergence, Measurement of, xvi., 103
DOBROWOLSKY, Colored Rings in Glaucoma, xv., 267
DODD, an Iris-Shield, xxi., 213
D'OENCH, a Case of Uniocular Cataract, xx., 258; Congenital Tumor and Coloboma of Upper Lid, xv., 81; Five Hundred Successive Enucleations at Dr. H. Knapp's Clinic, xvi., 187; Two Cases of Vertical Nystagmus, xvi., 293
Dransart, Miner's Nystagmus in the North of France, xxi., 439
Drill, Lachrymal, xxi., 436
DUANE, Proposed Numbering of Prisms, xx., 321
Dub, Contribution to the Knowledge of Zonular Cataracts, xxi., 557
Dubois de Lavigerie, Hyperplastic Epithelial Plaque of the Cornea, xxi., 449
DUNN, a Case of Reflex Micropia upon Posterior Hypertrophy of the Inferior Turbinates, xxi., 365; Case of Removal of Eye followed by Hysteroid Convulsions, xx., 36

Dunn, Four Cases of Reflex Amblyopia, xxi., 573; Some Remarks upon the Ætiology and Treatment of the Phlyctenular Eye Diseases, xxi., 445
Dyslexia, Nieden, xvii., 307; xviii., 118

Eaton, Fracture of Base of Skull, with Paralysis of Portions of Fifth and Sixth Pairs, xxi., 412
Echinococcus, Case of Epibulbar, Weeks, xviii., 31
Ectropium, Cured by Extraction of Tooth, xv., 355; Electrolysis in, xvi., 97; Landolt's Operation for, xv., 355
Egyptian Ophthalmia, Micro-Organisms of, Michel, J., xv., 452
Ehrlich's Methylin Blue Method, xxi., 424
Electric Light, Effect of on the Eyes, xix., 349; Influence on the Eye, xviii., 111, 115, 495
ELSCHNIG, Detachment of the Choroid, xxi., 272; Polypoid Tumors of the Conjunctiva, xviii., 255; the Metastatic Tumors of the Eye, xx., 370
Embolism, of Central Artery, xxi., 497, 564; Cured by Massage, xxi., 407; Retinal, xxi., 564
Enophthalmus Traumaticus, Gessner, xviii., 269
Entropium, Operations for, xv., 226; the Operation of, xxi., 434; Transplantation in Minor Degrees of, xxi., 434
Enucleation, Deaths from, xvi., 110, 232; xxi., 63; Followed by Acute Mania, Cheatham, xix., 60; of Eye, Followed by Hysteroid Convulsions, Dunn, xx., 36; Followed by Meningitis, xv., 392; Followed by Subjective Sensations of Light, Park, xx., 343
Enucleations, Report of 500, D'Oench, xvi., 187
Epilepsy, Cured after Enucleation, xvii., 124: Relief of, by Correction of Convergent Strabismus, Beard, xix., 144
Episcleritis, Actual Cautery in, xvii., 525
Epithelioma of Lid, xxi., 434; of Limbus, xxi., 449
Erb, on the Ætiology of Tabes, xxi., 572
Erythrophleine, xvii., 494
Erythropsia, xv., 135; xvii., 102, 125; xviii., 104
Eskridge, Gunshot Wound at the Left Cuneus, with Right Homonymous Hemianopsia, xxi., 571
Euriphen in Ophthalmology, xxi., 73
Exenteration, Cases of, xv., 238; xvii., 232; *vs.* Enucleation, xv., 127; of Globe, Modified Operation for, xviii., 332
Exophthalmic Goitre, Points of Affinity between Rheumatoid Arthritis, Locomotor Ataxy, and, xxi., 415
Exophthalmus, a Case of Pulsating, Wing, xx., 548; after Whooping Cough, xix., 352; Experimental Production of, xxi., 418; Following Strabotomy, Disappearance of, xxi., 439; Pulsating, in a New-Born Child, xxi., 442; Pulsating, xv., 119; Unilateral, xv., 118
Expression of the Morbid Material in Trachoma, xxi., 119
Extraction, Treatment of Capsule in and after, xxi., 558
Extractions, 109 Simple, xxi., 557
Eye, Diseases of, in Diabetes, xxi., 572; Lotions, Disinfection of, xxi., 305; Hyperplastic Inflammation of the Membranes of the, Schoebl, xix., 390; Muscles, Paralysis of, in Tabes, xxi., 415; Punctured Wounds of the, in Children, Baxter, xx., 340; Symptoms Due to Nasal Disease, Gradle, xvi., 391
Eyeball, Retraction of, xxi., 442
Eyelashes, in Ant. Chamber, xxi., 452
Eyes, Position of, When at Rest, xix., 512

Faravelli, Right Homonymous Hemianopsia of Traumatic Origin, xxi., 571
Fellows, Ocular Massage, xxi., 445
Ferdinands, Investigations into the Eyesight of Children Attending Some of the Aberdeenshire Board Schools, xxi., 430
FERNANDEZ, Europhen and Cantharidate of Soda in Ophthalmology, xxi., 73
Fernandez, Clinical Note on Alcoholic Amblyopia during the Cuban War, xxi., 568; Loss of Sight Following a Gunshot Wound in the Periorbital Region, xxi., 412; on a Possible but Remedial Accident in Keratotomy, xxi., 558; Spontaneous Disappearance of a Remedial Accident of Strabotomy, Exophthalmus, xxi., 439
"Festschrift zur Feier des Siebenzigsten Geburtstages von Hermann von Helmholtz," xxi., 326
FICK, a Contact lens, xvii., 215; Unequal Accommodation in Healthy Eyes and in Anisometropia, xviii., 292
Fick, *The Shadow Test*, Review, xxi., 166
Field, Co-excitation in the Region of Homonymous, Schiele, xvi., 317; of Vision, Contraction of, in Traumatic Neurosis, xxi., 565; Symmetrical Defect in Case of, xv., 380
FINLAY, Penetrating Wounds of the Eyeball, Sympathetic Ophthalmia, xxi., 457
First Cuban Medical Congress, 1890, xix., 533
Fischer, Contraction of Visual Field in Traumatic Neurosis, xxi., 565; Cure of a Case of Embolism of the Central Retinal Artery by Rubbing the Eye, xxi., 407
Fistula of Lachrymal Sac, Congenital, Cure of, xxi., 141
Flap Operation, the Return to the, Schweigger, xvi., 447.
Fluorescin, Note on, etc., xxi., 445
FOERSTER, Influence of Concave Glasses and Convergence on Myopia, xv., 399
Foreign Bodies, Inflammation of Eye Caused by, xxi,, 22; Tolerance of, in Eyes and Orbit, Gardner, xvi., 207
Foreign Body in Fundus, Unsuccessful Attempt at Removal, xxi., 362
FOSTER, Embolism of Arteria Centralis Retinæ, xxi., 497; Cystic Tumor of Lachrymal Gland, xx., 53
Fovea Centralis, Opacity at the, Knapp, xv., 380
Fox, Resection of the Optic Nerve, xxi., 411
Fox and Gould, *Compend. of Diseases of the Eye*, Review, xvi., 368
Fracture of Base of Skull, with Paralysis of Abducens, xxi., 415; with Paralysis of the Fifth and Sixth Pairs, xxi., 412
FRIEDENWALD, Binocular Metamorphopsia Produced by Correcting Glasses, xxi., 204; Retinitis Diabetica, xx., 544
Friedenwald, Report of Ophthalmological Examination of Dr. Preston's Cases of Arterial Sclerosis, xxi., 414
Frontal, Sinus, Inflammation of, xvii., 380; Sinuses, Diseases of the, xxi., 145
Frothingham, Remarks on the Need of More Efficient Protection of the Eye after Cataract Extraction, and an Improved Apparatus for the Purpose, xxi., 558
FUCHS, Papilloma of the Conjunctiva, xx., 537
Fuchs, *Text-Book of Ophthalmology*, Review, xviii., 515; on Lens Precipitates, xxi., 557
FULTON, Monocular Optic Neuritis, xviii., 127
Fulton, Pathology and Ætiology of Trachoma, xxi., 445

GARDNER, Tolerance of Foreign Bodies in the Eye and Orbit, xvi., 207; Is the Position of Rest the Cause of Strabismus?, xvi., 39

Garnier, a Case of Myxo-Sarcoma of the Optic Nerve, xxi., 411

Gasperini, Diffuse Lymphoma of the Conjunctiva, xxi., 445

Gaupillat, New Device for Bandaging after Simple Extraction, xxi., 558

Gayet, Essay on the Investigation of the Acuteness of Sight after the Operation for Cataract, xxi, 558

General, Pathology, Diagnosis, and Therapeutics, Reports on, xv., 103, 347; xvi., 82, 220, 325, 458; xvii., 96, 230, 365, 490; xviii., 212, 487; xix., 308, 305, 503; xx., 140, 418, 553; xxi., 130, 304

GESSNER, Enophthalmus Traumaticus, xviii., 269

GIFFORD, Answer to Randolph's Criticisms on Sympathetic Opthalmia, xvii., 362; Contribution to the Study of Sympathetic Ophthalmia, xv., 281; Direction of Lymph Streams in the Eye, xv., 153; Further Experiments on the Lymph Spaces and Channels of the Eye, xxi., 171; Micro-Organisms in Conjunctival Sac in Various Conjunctival and Corneal Diseases, xv., 180; New Dressing for Cataract Extraction, xix., 42

Gillet de Grandmont, Syphilis or Tuberculosis of the Iris, xxi., 548

Glaucoma, Acute, in Man, Æt. Twenty-four, etc., xxi., 553; after Discission of Secondary Cataract, xxi., 293; after Operation for Secondary Cataract, xxi., 558; Affections of the Optic Nerve in, Schweigger, xx., 475; after Extraction, xvii., 250; at the Age of Eleven Years, Randolph, xvi., 185; Cause of the Colored Rings Seen in, Dobrowolsky, xv., 267; Caused by Over-Exertion of Accommodation, Schoen, xvii., 33; Cocain in, Sargent, xvi., 205; Colored Rings in, xvi., 125; Contributions to the Knowledge of, Schnabel, xvi., 1; Curability of, xxi., 553; Division of Trochlear Nerve in, xv., 125; Family History of Blindness from, Howe, xvi., 72; Hemorrhagic, xxi., 553; in Aniridia, xxi., 322; in Aphakia, xx., 279; in a Man of Twenty-two, Pardee, xvii., 214; in a Child, Vilas, xvii., 427; of Twenty-two Years' Standing, xviii., 348; One Thousand Cases of, xix., 94; Operative Treatment of, xxi., 553; Pathogenesis of, Stilling, xvi, 440; Pathology of, xix., 96, 336; Perimetric Observations on Influences of Eserine and Iridectomy in, xxi., 553; Reports on, xv., 124, 241, 373; xvi., 123, 238, 348, 479; xvii., 116, 249, 385; xviii., 98, 228, 348; xix., 94, 334, 523; xx., 278, 446, 570; xxi., 154, 322, 552; Simplex, xxi., 552; Stretching of Infra-Trochlear Nerve in, xvi., 220; Value of Sclerotomy in, xviii., 99; Unusual Family History of, xxi., 358

Glioma Retinæ, Sixty Cases, xxi., 564

Glycogen in the Cornea and Conjunctiva of Pathological Eyes, Schiele, xviii., 457

Goitre, Exophthalmic, xxi., 442

Golowin, on the Use of Hydrogen Peroxide in Ophthalmic Practice, xxi., 420

GOULD, Ametropic Choroido-Retinitis, xix., 30; Astigmatic Bi-Focal Lenses, xx., 158; New Device for Measuring Astigmatism, xviii, 435; Obviation of the Light-Circle around Lenses, xviii., 434

Gould, Statistics and Results of 1,500 Cases of Refraction, xxi., 430; an Improvement in Bi-Focal Lenses, xviii., 432

Gouty Eyes, xv., 254

GRADLE, Ocular Symptoms due to Nasal Disease, xvi., 391

Graefe's, Lid-Sign, xxi., 442; Work, xv., 101
Grafting, Cases of Mucous, to Eye, Smith, W. F., xvii., 430
Granular Lids, Surgical Treatment of, xxi., 445; Treatment of, with Cantharidate of Potash, Santos Fernandez, xx., 345
Granulations, Anatomy of, xxi., 151; New Method of Operating, xxi., 445
Granuloma of Glands of Moll, xxi., 434
Graves' Disease, Recovery from, xxi., 442
GREEFF, a remarkable Case of Pseudo-Trachoma, xxi., 505; Four hundred and Fifty Simple Extractions, xx., 303
Greeff, Investigations on Binocular Vision, with the Use of Hering's Test, xxi., 426
Green, Elbridge, a Review of the Tests for Color-Blindness, xvi., 427
Grippe as a Cause of Retrobulbar Neuritis and Other Ocular Lesions, xxi., 568
GROENOUW, Detachment of the Choroid after Extraction, xviii., 277 Nodular Opacities of the Cornea, xix., 245
Groenouw, Bilateral Hemianopsia of Central Origin, xxi., 572
GROSSMAN, Partial Symblepharon of Lower Lid, xvii., 300; Skin and Mucous Grafting, xvii., 299; Sixfold Paralysis of Left Cerebral Nerves, xvii., 401
Guaita, Operative Treatment for the Rapid Cure of Dacryocystitis xxi., 436
GRUENING, Platinum Instruments, xx., 264
Guerenchi, Clinical Contributions to the Physiology of the Optic Ganglion, xxi., 412
Guinea Worm in the Eye, xv., 251
Guldenarm, Contribution to Surgery, xxi., 415
Gunn, a Case of Hemorrhagic Disease of the Retina, xxi., 564
Gunshot Wound of Periorbital Region with Loss of Sight, xxi., 412
Gurwitsch, Hyaline Formation in the Disk and Retina in Bright's Disease, xxi., 568

Haab, Chronic Tuberculosis of Choroid, Specific Arterial Disease of Retina, xxi., 550; Remarks on Cataract Operations, xxi., 557
Hair dye, an Effect of, on Vision and Eyes, xvii., 125
HALTENHOFF, Gonorrhoic Conjunctivitis without Inoculation, xv., 169
Handwriting, xvii., 497
HANSELL and BELL, Statistical Paper on Blindness, xxi., 51
HARLAN, Hernia of Iris after Simple Extraction, Recovery, xx., 81
Hasner, Obituary Notice of Von, xxi., 331
Headache, Ocular, and States of Refraction, xxi., 431
HEDDAEUS, the Investigation, and the Significance of the Pupillary Symptoms, xviii., 189
Helmholtz, Festschrift zur Feier des Siebenzigsten Geburtstages von Hermann von, xxi., 326
Hemeralopia and Scurvy, xxi., 564; Family History of, xv., 382
Hemiamblyopia, Recovery from, xxi., 408
Hemianopsia, xxi., 408; a Case of Cortical, Schmidt-Rimpler, xix., 147; Case of Double, xxi., 572; Centralis, xvi., 139; Bilateral Homonymous, Schweigger, xx., 83; Horizontal, xxi., 572; Inferior, Binocular, and Other Sensory Disturbances in a Case of Functional Psychosis, xxi., 407; Inferior, with Functional Psychosis, xxi., 572; of Central Origin, xxi., 572; of Left and Blindness of Right Eye, xxi., 572; of Traumatic Origin, xxi., 571; Right, after Gunshot Wound of Left Cuneus, xxi., 571; Superior, xxi., 533; Two Cases of, xxi., 572; with

Hemianopsia—*continued.*
Fracture of Skull, xxi., 572; with Agraphia and Amnesic Aphasia, Weeks, xx., 392
Hemiopic Pupillary Reaction, Wernicke's Iridoplegia, xxi., 572
Hemorrhage, after Use of Nitrate of Silver on Conjunctiva, xxi., 444; Appearances of Papilla after, xvii., 255; Following Use of Silver Nitrate, xvii., 245; Intraocular from a Fall on the Occiput, Schapringer, xvi., 35; Spontaneous, into Orbit, xvii., 511
Hering, Examination of a Case of Total Color-Blindness, xxi., 426
Hering's Test, Investigations on Binocular Vision with, xxi., 426
Herrnheisser, on Serous Cysts of the Iris, xxi., 548
Herter, *The Diagnosis of Diseases of the Nervous System*, Review, xxi., 454
HEYDER, Cases of Epibulbar Carcinoma, xvii., 458
HEYL, Treatment of Purulent Ophthalmia with Hot Water, xv., 311
HILBERT, Contribution to our Knowledge of Xanthopsia, xv., 196
Hilbert, Pathology of Scintillating Scotoma, xxi., 565
HILEMAN, Intraocular Hemorrhage after Extraction, xvii., 268
HILL-GRIFFITH, Intraocular Sarcoma at Central Region, xvii., 139
Hill-Griffith, the Prognosis of Choroidal Sarcoma, xxi., 550
Hirschberg, Bloody Myodesopia, xxi., 556; Spontaneous Recovery in a Case of Detachment of the Retina in Myopia, xxi., 407; Sympathetic Blindness Permanently Cured, xxi., 554
Hirschberg and Cirincione, Hyalin Bodies in the Papilla, xxi., 411
Hoche, Binocular Hemianopsia Inferior and Other Sensory Disturbances in a Case of Functional Psychosis, xxi., 407
Hodges, Iodide of Silver in the Treatment of Trachoma, xxi., 444
HOLDEN, Case of Typical Inferior Coloboma of Iris, xxi., 499; Histology of Some of the Rarer Forms of Choroidal Tumors, xxi., 76; Instrument for Testing Refraction and its Errors, and the Strength and Insufficiency of the Ocular Muscles, xvi., 295; New Instrument for Testing Insufficiencies of the Ocular Muscles, xvi., 403; on the Cylindrical Equivalent of Tilted Lenses, the Prismatic Equivalent of Decentred Lenses, and the Employment of Such Lenses in Practice, xx., 2
Homatropia in Refraction Cases, xxi., 430
Homatropine and Cocain, Mixture of, in Refractive Work, xxi., 420
Horner, Obituary Notice of, xvi., 252
HORSTMANN, Specific Optic Neuritis, xviii., 174
HOSCH, a Peculiar Case of Retinal Glioma, xviii., 287
Hosch, Ehrlich's Methylin Blue Method, xxi., 424
HOTZ, Excision of Retro-Tarsal Fold in Trachoma, xv., 147
HOWE, Family History of Blindness from Glaucoma. xvi., 72; Instrument for Demonstration of Accommodation and Refraction, xv., 259
Hyalin Formation in Disk and Retina, xxi., 568
Hyaloid Artery, Persistent, Tangemann, xvii., 270; xxi., 424
Hydrogen, Peroxide of, xvii., 99; Use of, in Ophth. Practice, xxi., 420
Hydrophthalmus, xxi., 552
Hypermetropia, Ophthalmoscopic Appearances of, xxi., 430
Hysterical Condition of Ocular Muscles, xvii., 258

Idiots, the Eye of, xv., 346
INOUYE, a Black Spot at the Macula in Embolism of the Central Retinal Artery, xx., 259

Influenza, Exophthalmus and Ophthalmoplegia Following, Callan, xx., 327; Eye Diseases after the, xx., 295; Ophthalmic Sequelæ of, Beaumont, xx., 59

Injuries, and Foreign Bodies (Parasites), Reports on, xv., 134, 251, 387; xvi., 142, 243, 358, 488; xvii., 121, 256, 391; xviii., 114, 239, 361; xix., 105, 352, 529; xx., 288, 462, 577; xxi., 161, 412, 570; Pathology of, xxi., 570

Injury, a Singular Case of, Smith, W. F., xix., 142

Instruments and Remedies, Reports on, xv., 106, 217, 348; xvi., 86, 221, 326, 459; xvii., 98, 214, 233, xviii., 333, 367, 491; xix., 310, 504; xx., 142, 418, 556; xxi., 305, 419

Intermittent Fever, Optic Neuritis after, Woods, xxi., 95

Intraocular Pressure, Graphic Illustration of, xvi., 224

Inunction by Pressure in Hyperplastic Conditions of the Eye, Ryerson, xx., 550

Iridectomy, Lenticular Astigmatism after, Schioetz, xv., 203; or No, in Cataract Extractions, xxi., 557

Iridiræmia, Case of Total, xv., 372

Iridodialysis, Case of Complete, xvii., 383; Treatment of, xxi., 548

Iridotomy, xvi., 478

Iris, a Rare Tumor of, Removed, xxi., 548; Case of Sarcoma of the, Webster, xviii., 15; Coloboma of, xxi., 499; Congenital Coloboma of, De Beck, xv., 8; Cyst of the, Burnett, S. M., xxi., 253; Cyst of, Destroyed with the Galvano-Cautery, Reuling, xvi., 210; Leucosarcoma of, with Iritis Serosa, Limbourg, xix., 239; Primary Sarcoma of, with Ossification of Choroid, Whiting, xix., 361; Prolapse of, in Simple Extraction, xxi., 553; Reports on Diseases of the, xv., 124, 236, 371; xvi., 121, 236, 346, 477; xvii., 115, 247, 362; xviii., 96, 227, 345; xix., 91, 330, 520; xx., 276, 443, 570; xxi., 153, 320, 548; Sarcoma of the, xix., 92; Serous Cysts of, xxi., 548; Shield, Dodd, xxi., 213; Spontaneous Cure of Prolapse of, after Simple Extraction, xx., 269; Syphilis or Tuberculosis of, xxi., 548; Three Cases of Coloboma of the, Pollak, xx., 410; Tubercle of, Spontaneously Cured, xxi., 548; Tubercle of the, xx. 277; Tuberculosis of the, xx., 444; Tumors of the, xv., 236

Iritis, after Epileptiform Seizure, xviii., 97; Ice in, xxi., 549; Syphilitic, with Statistics, xxi., 549; with Nodular Neoplasms, xxi., 320

Israel, Pulsating Exophthalmus, xxi., 442

Jackson, Pressure on the Globe after Cataract Extraction, xxi., 558; the Full Correction of Ametropia, xxi., 430

Jacobsohn, Obituary Notice of, xix., 110

JAESCHE, Distichiasis and Trichiasis; Operations for, xix., 411; How shall we Treat Trachoma To-day? xxi., 113; Treatment of Stenosis of the Lachrymal Duct, xix., 423; Treatment of Trachoma, xxi., 113

Javal, on the Heredity of Myopia, xxi., 430

Javal's Ophthalmometer, xxi., 333

Jequirity, a Perfectly Safe Remedy in Eye Diseases, xxi., 48; a Safe Remedy, C. Michel, xxi., 48

Jessop, on the Consensual Pupillary Light Reflex in Cases Exhibiting the Argyll-Robertson Pupil Symptom in One Eye, xxi., 418; Two Cases of Complete Blindness with Good Pupillary Reflexes, xxi., 565

JOHNSON, Extra-Papillary Colobomata, xix., 1; New Treatment for Trachoma, xix, 264; xx., 270; Observations on the Macula Lutea, xxi., 1

Johnson, Eyelashes in Anterior Chamber, xxi., 451
JONES, E. L., Extreme Cylindrical Effect of a Tilted Spherical Lens, xxi., 301
Juler, the Operative Treatment of Pharyngitis, xxi., 438; Double Congenital Buphthalmus, xxi., 552
Jung, Contribution to the Differential Diagnosis of the Tuberculous and Gliomatous Diseases of the Eye, xxi., 418

Kalt, Arterio-Venous Aneurism of the Carotid in the Cavernous Sinus, xxi., 572; on Resection of the Optic Nerve as a Substitute for Enucleation, xxi., 568; Pathological Anatomy of Buphthalmus, xxi., 552
KAMOCKI, Pathological Investigations of the Eyes of Diabetic Persons, xvii., 41
Keratitis, Bullosa, Tangemann, xvii., 92; Cases of Neuro-Paralytic, De Schweinitz, xx., 26; Gouty, xxi., 449; Interstitialis, xv., 234; xvii., 115; Punctata, xix., 328; xx., 417
Kerato-Conjunctivitis of Rhino-Pharyngeal Origin, xxi., 445
Kerato-Conus, xx., 569; and Eserine, xv., 233; Five Cases Treated with Galvano-Cautery, Knapp, xxi., 540
Kerato-Malacia and Neuro-Retinitis in Meningitis, xxi., 414
Keratometry, Further Contributions to, xxi., 430
Keratoplasty, xvii., 524
Keratotomy, Accident in, xxi., 558
KERSCHBAUMER, Rosa, Two Hundred Cataract Extractions, xx., 349
Kessler, Intravaginal Fibro-Sarcoma of the Optic Nerve, xxi., 568
Keyser, Conjunctivitis Granulosa, Pumice Stone, xxi., 445
KNAPP, Attempt to Remove a Chip of Steel from Background of the Eye Unsuccessful through an Accident which might have been Avoided, xxi., 362; Bacterial Experiments, xv., 24; Case of Lenticonus Posterior, xviii., 451; Cataract Extraction without Iridectomy, xvi., 54; Cautery in Corneal Infiltration, xv., 233; Designation of Meridians in Determination of Glasses and of the Visual Field, xv., 297; Dividing the Capsule during the Corneal Section in the Extraction of Cataract, xviii., 169; Embolism of Central Retinal Artery, xv., 380; Five Cases of Kerato-Conus Treated with Galvano-Cautery, xxi., 540; Formation of Dark Angioid Streaks, an Unusual Metamorphosis of Retinal Hemorrhage, xxi., 289; Glaucoma after Secondary Discission of Cataract Cured by Iridectomy, xxi., 293; Hemorrhage into the Vitreous after Extraction, xx., 78; One Hundred Simple Extractions, xvii., 51; On the Extraction of Lenses Dislocated in the Vitreous, xix., 53; Opacity at Fovea Centralis, xv., 380; Orbital Optic Neuritis Including Alcoholic and Tobacco Amaurosis, xx., 123; Report on a Third Hundred of Simple Extractions, xix., 280; Second Series of One Hundred Simple Extractions, xviii., 1; Small Orbital Osteoma, Removed with Chisel, xvii., 89; Suppuration Following Squint Operation, xv., 436; Treatment of Trachoma by Expression of the Morbid Material, xxi., 119; Tuberculosis of the Conjunctiva, xix., 78
Knapp, Contribution to the Tuberculosis Question, xxi., 550; the Treatment of the Capsule during and after the Extraction of Cataract, xxi., 558
Knies, Glaucoma Simplex, xxi., 552
KOHN, Optic Nerve Atrophy in a Child, with Severe Cerebral Symptoms, xxi., 339

KOLLER, Experimental Scotoma by Pressing on Globe, xvii., 227
Kostenitch, Pathological Investigations of Gun-Cap Injuries of the Human Eye, xxi., 570
Kramer, on Hysterical Stammering, xxi., 407
KROTOSCHIN, Development of Myopia, xxi., 33

Lachrymal, Apparatus, Reports on, xv., 115, 227, 357; xvi., 100, 229, 467; xvii., 239, 376, 504; xviii., 219, 337, 503; xix., 319, 511; xx., 152, 433, 562; xxi., 140, 313, 435; Blennorrhœa of Infants, xxi., 436; Diseases, Complications of, xvii., 376; Duct, Treatment of Stenosis of the, Jaesche, xix., 423; Gland, Cystic Tumor of the, Foster, xx., 53; Gland, Fluxion of, xxi., 436; Gland, Removal of, xvi., 100; Gland, Sarcoma of, xv., 357; Passages, Report on Treatment of, xxi., 436; Sac, Curettage of, xxi., 436; Sac, Scraping of, xxi., 436; Sac, Tuberculosis of the, xxi., 313
Lachrymation, Due to Nose Diseases, xvii., 108
Lamy, Exophthalmic Goitre, xxi., 442
LANDOLT, on the Numbering of Prismatic Glasses Used in Ophthalmology, xix., 497
Landolt, *Refraction and Accommodation of the Eye*, Review, xv., 395
Larvæ, Living in the Conjunctival Sac, Phillips, xxi., 110
Lawford, a Case of Recovery From Graves' Disease, xxi., 442; Eyelashes in the Anterior Chamber, xxi., 452
Lawford and Collins, Notes on Glioma Retinæ, with a Report of Sixty Cases, xxi., 564; Sarcoma of Uveal Tract, with Notes of 103 Cases, xxi., 550
Leber, on the Coincidence of Disseminated Choroiditis and Hemorrhagic Retinitis or Retinal Hemorrages in the Same Eye, xxi., 550; on Weakened Tuberculosis of the Eye, xxi., 550
Leber, *The Origin of Inflammation*, Review, xx., 470
Le Fort, Pulsating Exophthalmus, *a propos* of a Case of Ligation of the Two Carotids for this Disease, xxi., 442
Lens, Cylindrical Effect of a Tilted Spherical, Jones E. L., xxi., 301; Dislocation of, under Conjunctiva, xxi., 256; Extracting of Floating, from the Vitreous, xxi., 258; Extraction of, in the Vitreous, Knapp, xix., 53; Finer Anatomy of Suspension of, xvi., 463; Partial Dislocation of the, Burnett, S. M., xxi., 257; Precipitates, xxi., 557; Reports on Diseases of the, xv., 127, 244, 376; xvi., 129, 239, 351, 481; xvii., 117, 251, 383; xviii., 99, 231, 350; xix., 97, 338, 525; xx., 282, 449, 573; xxi., 156, 324, 537; Successful Extraction, of a Floating, from the Vitreous, Burnett, S. M., xxi., 258; Traumatic Rupture of Posterior Capsule of, xxi., 557
Lenses, and Prismospheres, Action of Decentred, Percival, xx., 193; a New Measurer of, Smith, xx., 131; Determination and Designation of Meridians of, Knapp, xv., 297; Equivalent of Tilted and Decentred, Holden, xx., 2; Instrument for Centring, Smith, A. L., xx., 266; Note on Astigmatic Bifocal, Gould, xx., 58; Notes on Bifocal, Percival, xix., 255; Notation of, xvii., 104; Obviation of the Light Circle around, Gould, xviii., 434
Lenticonus, a Case of, xxi., 325; Posterior, Cases of, Knapp, xviii., 103, 451; Posterior, Weeks, xx., 260
Leprosy of the Eye, Lopez, xviii., 404
Leroy, a Micrometic Opthalmoscoptometer, xxi., 420

Les Annales d'Oculistique, Review, xx., 472
Leyden, Hemiopic Pupillary Reaction, the So-Called Wernicke's Iridoplegia, xvi., 572
Lid, Congenital Tumor and Coloboma of the Upper, D'Oench, xv., 81; Transplantation of, with Unpedicled Flap, Weeks, xviii., 92; Varicose Tumor of Lower, Chisolm, xvii., 151
Lids, Contribution to the Study of the Tumors of the, Salzmann, xx., 380; Lymphoma of, xxi., 149; Reports on the, xv., 114, 225, 355; xvi., 96, 228, 336, 465; xvii., 106, 238, 374, 501; xviii., 218, 334, 501; xix., 315, 509; xx., 149, 433, 561; xxi., 137, 311, 434
Liebrecht, Retrobulbar Neuritis after the Use of Arsenic, xxi., 411
Light, Action of, on the Eye, xvii., 373; Influence of, upon the Eye, xix., 306; Sense, Testing of the, Seggel, xviii., 247; Streak, Explanation of the, Davis, A. E., xx., 44
Lightning, Injury to Eye from, Buller, xvii., 131, 333
LIMBOURG, Leucosarcoma of Iris with Iritis Serosa, xix., 239
LIPPINCOTT, on the Binocular Metamorphopsia Produced by Correcting Glasses, xviii., 18
Liquids in Eye, Laws of Exchange of, xv., 111
Literature, Reports on General Ophthalmological, xv., 212. 343; xvi., 77, 217, 322, 456; xvii., 229, 486; xviii., 208, 330; xix., 303; xx., 136, 552; xxi., 128, 303, 417
Lloyd, an Acute Glaucomatous Attack in the Right Eye of a Colored Man, æt. 24, Left Eye Destroyed Six Years Previously by a Pistol Ball, xxi., 553
Lombroso, the Visual Field in Epileptics and Feeble-Minded Persons, According to Ottolenghi, xxi., 572
LOPEZ, Ocular Leprosy, xviii, 404; Spontaneous Cure of Prolapse of Iris after Simple Extraction, xx., 269; Traumatic Retention Cyst of Conjunctiva, xxi, 231
Loring, E. G., Obituary Notice of, xvii., 261; *Text-Book on Ophthalmoscopy*, Review, xv., 139; xx., 468
Lymphatics in the Eye, Gifford, xv., 153
Lymphoma of Orbit, xxi., 439
Lymph Spaces and Lymph Channels of the Eye, xxi., 171

Mackrocki, on the Symptomatology of Commotion of the Retina, xxi., 564
Macnamara, Address in Section of Ophthalmology at the Brit. Med. Asso. on Certain Points in Ophthalmic Practice, xxi., 558; the Treatment of Infantile Cataract, xxi., 557
Macula Lutea, Observations on the, Johnson, xxi., 1; Two Cases of Coloboma of the, Silex, xviii., 86
MADDOX, Objective Strabismometry, xxi., 56
Magnet, Extraction of Piece of Steel in the Vitreous, xxi., 412; Operations, Neese, xvii., 341; Use of, for Foreign Bodies in Eye, xv., 389
MAGNUS, the Blind in Breslau, xv., 51
Maine Eye and Ear Infirmary, xxi., 168
Manolescu, Brushing of Conjunctival Granulations Combined with Parasiticide, xxi., 445; Massage of the Optic Nerve in Certain Cases of Optic Atrophy, xxi., 568
Manora, Sympathetic Ophthalmia, xxi., 554
MANZ, Congenital Coloboma of the Optic Nerve, xxi., 263
Manz, Anatomical Description of a Coloboma of the Optic Nerve, xxi., 411; Examination of a Case of Embolism of the Central Retinal Artery, xxi., 564

Marchal, Comparison between Resection of the Optic Nerve and Enucleation, xxi., 568
MARLOW, Temporary Hypermetropic Astigmatism after the Measles, xxi., 107
Marple, Grattage for Trachoma, xxi., 445
Martin, a Post-Operatory Complication of a Morgagnian Cataract, xxi., 558
Massage, Historical Review of, xx., 141; of the Eye, xviii., 488; Ocular, xxi., 445
Mast-Cells in an Injured Eye, xv., 252
MAUTHNER, "Ocular Palsies," xviii., 368
Mauthner, Polyencephalitis and Sleep, xxi., 572
MAY, Transplantation of a Rabbit's Eye into a Human Orbit, xvi., 47
McHardy, Cyst in Anterior Chamber, xxi., 452
Measles, Hypermetropic Astigmatism after the, xxi., 95; Optic Neuritis after the, Marlow, xxi., 107; Optic Neuritis after the, Woods, xxi., 95; Temporary Hypermetropic Astigmatism after the, Marlow, xxi., 107
Megrier, a New Optometer, xxi., 420
Melanotic Tumors of the Eye, Ole Bull and Gade, xviii, 163
MENDOZA (SUAREZ DE), Treatment of Ulcerations of the Cornea with Acid in a Deliquescent State, xxi., 449
Mercury, Perchloride of, in Trachoma and Other Conjunctival Diseases, xxi., 444
Metamorphopsia, Binocular, Produced by Correcting Glasses, Lippincott, xviii., 18; Metamorphopsia, Binocular, Produced by Correcting Glasses, Friedenwald, xxi., 204
Metastatic Ophthalmia after Miscarriage, xvii., 249; Tumors of the Eye, Elschnig, xx., 370
Meyer, *Treatise on Diseases of the Eye*, Review, xvi., 248; Contribution to the Ophthalmoscopic Diagnosis of Alterations in the Vascular Walls of the Retina, xxi., 564
MICHEL, C., Dark Rooms and Bandages Discarded after Cataract Extractions, xv., 318; Jequirity, a Perfectly Safe Remedy, xxi., 48; Micro-Organisms of Egyptian Ophthalmia, xv., 452
Micro-Organisms of Conjunctival Sac, xvii., 243, 366, 505
MILLIKIN, the Actual Cautery in Removing Neoplasms from the Eye, xvi., 209
Minney, Transplantation in Minor Degrees of Entropium, xxi., 434
MINOR, Twenty-five Cataract Extractions, xx., 69
Mirrors, Models of, for Ophthalmoscopic Examination, xxi., 420
Miscellaneous Notes, xv., 145, 255, 398, 494; xvi., 147, 251, 494; xvii., 129, 261, 396; xviii., 125, 244, 370; xix., 110, 360, 533; xx., 160, 298, 468; xxi., 166, 455, 578
Mittendorf, *Granular Lids and Contagious Ophthalmia*, Review, xvi., 493; One Thousand Cases of Ocular Headache and the Different States of Refraction Connected Therewith, xxi., 430
MITVALSKY, Metastatic Carcinoma of the Eyeball, xx., 237; On the Pathology of Circumbulbar Dermoid Cysts, xxi., 376
Moauro, Granuloma of the Glands of Moll, xxi., 434
Monocular Micropsia, xv., 381
Morat and Doyen, on the Rôle of the Cervical Sympathetic in the Accommodation for Vision of Distant Objects, xxi., 426
MORGAN, Artificial Vitreous Humor, xx., 32
Morton, Bilateral Paralysis of the External Recti following Diphtheria, xxi., 439, 573

Motais, on the Refraction of Animals, xxi., 424
Movements of Eye, Investigations into Physiology of, xxi., 426
Muglich, Spontaneous Recoveries from Retinal Detachment, xxi., 564
Mules, Anterior Central Capsular and Pyramidal Cataracts, their Pathology, xxi., 557
Müller, Two Cases of Aneurism of Aorta, xxi., 414
Murell, to What Extent are Personal Restraints Essential during Healing of Corneal Wounds? xxi., 557
Muscles, Anomalies of the Ocular; Stevens, xvi., 149; Stevens, xvii., 155, 371; Stevens, xx., 356; and Nerves, Reports on the, xv., 116, 228, 367; xvi., 101, 229, 337, 467; xvii., 107, 239, 376, 506; xviii., 220; 337, 504; xix., 320, 511; xx., 152, 434, 563; xxi., 142, 314, 438; Contribution to Theory of Relations of the Eye, Schioetz, xix., 157; Instrument for Testing the Ocular, Holden, xvi., 295, 403
Muttermilch, Anatomy of the Chronic Inflammations of the Conjunctiva, xxi., 444
Mydriatic Alkaloids, Observations on, xxi., 420
Myelitis and Optic Neuritis, xv., 387
Myodesopia, Bloody, xxi., 556
Myopia, Action of Length of Optic Nerve on, xv., 355; Anatomical Contributions to the Knowledge of the Development of, Korotschin, xxi., 33; Development of, xxi., 33; Due to Concave Glasses and Convergence, Foerster, xv., 399; Ectasia at Posterior Pole in, xxi., 511; Form of the Orbit in, Cohen, xviii., 251; Heredity of, xix., 313; xxi., 430; Origin of, xvii., 105; Paper on, by Stilling, xv., 296; Signs of Incipient, xv., 224; Treatment of, by Extraction of Lens, xxi., 430
Naphthaline, xviii., 489; Effect of, on Eyes, xvii., 230
NEESE, a Contribution to the Tuberculosis of the Eye, xvi., 434; Magnet Operations, xvii., 341.
Neoplasm in Brain, Localized by Eye Symptoms, Oliver, xx., 40.
Nervous Diseases, the Diagnosis of, xxi., 454
Nettleship, Cases of Temporary Blindness during Lactation, xxi., 572; Unusual Appearances in a Case of Retinal Embolism about Thirty Hours after its Occurrence, xxi., 564
Neuritis, Case of Relapsing, xvi., 135; Orbital Optic, Knapp, xx., 123; Optica, after Measles and Intermittent Fever, Woods, H., xxi., 95; Optica, Cases of, xvii., 256
Neurotomy, Optico-Ciliary, a New Instrument for Performing, Briggs, xvi., 37
NIEDEN, a Case of Dyslexia, xvii., 307; Globular Formations around the Optic Papilla, xviii., 198; on the Connection between Diseases of the Eye and Nose, xvi., 415
Nieden, on a Case of Blennorrhœic Conjunctivitis in a Child Born in the Membranes, xxi., 444
Nikoljukin, Report of 97 Cataract Extractions, xxi., 558
NORTON, Removal of Tumor of Optic Nerve, with Preservation of the Eye, xxi., 356
Nose, Bad Effect on Eye, of Cauterizing the, xvii., 126; Connection between Diseases of the, and the Eye, Nieden, xvi., 415
Noyes, *A Text-Book on the Diseases of the Eye*, Review, xix., 359
Noyes, Hemianopsia, xxi., 408
Nystagmus, among South Wales Colliers, xxi., 439; in a Compositor, xxi., 439; in Ear Affections, xxi.,

Nystagmus—*continued.*
572; Miner's, in North of France, xxi., 439; Two Cases of Vertical, D'Oench, xvi., 293

Oatman, the Treatment of Diphtheritic Conjunctivitis by Constant Antiseptic Irrigations, xxi., 444
Oblique Muscles, Insufficiency of the, Savage, xx., 105
Obliqui, Symmetrical Action of, in Oblique Astigmatism, xxi., 430
Obliquus Inferior, Tenotomy of the, xv., 229
Ocular, Affections in Constitutional Diseases, Reports on, xv., 136, 253, 309; xvi., 143, 244, 360, 489; xvii., 122, 258, 393; xviii., 116, 240, 362; xix., 106, 353, 530.; xx., 290, 463, 579; xxi., 162, 414, 571; Axes in Production of Myopia, xv., 399
Oculo-motor, Paralysis of, with Opposite Paralysis of Abducens, Ole Bull, xvii., 144
OLIVER, Intracranial Neoplasm with Localizing Eye Symptoms, xx., 40
Opaque Nerve Fibres, xv., 110
Ophthalmia, Infectious, Iodine in, xxi., 449; Occurring Despite Resection of the Optic Nerve, xxi., 553; of New-Born, Iodoform, a Prophylaxis of, xxi., 444; Purulent, Analysis of Cases of, Holmes-Spicer, xxi., 444; Treatment of Purulent, with Hot Water, Heye, xv., 311
Ophthalmic Practice, Exceptional Cases in, xxi., 570; Hand-Book of, xxi., 453; Points in, xxi., 558
Ophthalmometer, a New, by Javal, Speakman, xix., 76; in Practice, xxi., 420
Ophthalmometers, Results of Incorrect, xxi., 307, 310
Ophthalmometric Measurements, Accuracy of, xxi., 418
Ophthalmometry, Clinical, xxi., 420
Ophthalmoplegia, 117 Cases of, xviii., 222
Ophthalmoplegia Externa with Sarcoma of Neck, xxi., 439
Ophthalmoplegiæ, Pathology of, xxi., 439
Opthalmoscoptometer, a Micrometic, xxi., 420
Opthalmoscope, Optometric and Phakometric, xxi., 420
Optic, Atrophy with Cerebral Symptoms, xxi., 339; Ganglion, Clinical Contributions to Physiology of, xxi., 412; Nerve, a Condition of, xxi., 567; Nerve, Anatomical Description of Coloboma of, xxi., 411; Nerve, Central Scotoma in Diseases of the, Sachs, xviii., 133; Nerve, Changes of, in Sclerosis of Cerebral Arteries, xxi., 410; Nerve, Congenital Coloboma of the, Manz, xxi., 263; Nerve, Indications for Simple Resection of, xxi., 411; Nerve, Injuries of the, xv., 134; Nerve, Intravaginal Sarcoma of, xxi., 568; Nerve, Myxo-Sarcoma of, xxi. 411; Nerve, Resection of, as a Substitute for Enucleation, xxi., 568; Nerve, Reports on Diseases of the, xv., 132, 249 384; xvi., 141, 242, 358, 488; xvii., 120, 255, 390; xviii., 112, 239, 359; xix., 104, 351, 529; xx., 286, 460, 577; xxi., 161, 567; Nerves, Atrophy of, with Acromegaly, xxi., 568; Case of Acute Atrophy of, xxi., 411; Massage of, in Atrophy, xxi., 568; Neuritis, Cases of Monocular, Fulton, xviii., 127; Neuritis of Specific Origin, Horstmann, xviii., 174; Papilla, Globular Formations around the, Nieden, xviii., 198
Optometer, a New, xxi., 420
Orbit, and Eye, Correlation of Cranial Conformations with those of, Culver, xxi., 68; and Neighboring Cavities, Reports on, xv., 117, 230, 360; xvi., 106, 231, 340, 468; xvii., 107, 242, 379, 510; xviii., 223, 339, 507; xix., 322, 513; xx., 156, 438, 565; xxi., 144, 317, 441;

Orbit—*continued.*
Cavernous Tumor of, xvi., 108; Foreign Body Driven through Nose, into the, Taylor, xv., 262; Osteoma of, xxi., 442; Osteoma of, Removed with Chisel, Knapp, xvii., 89; Secondary Tumors of, xxi., 442; Tumor in Each, xxi., 442
Orbital Cavity, Stone in, xxi., 412
OSBORNE, Internal Strabismus with Crossed Diplopia, xx., 66
Ostwalt, a Few Words on the Correction of Aphakia with Lenses, xxi., 558; Clinical Ophthalmometry, xxi., 420; Syphilitic Retinitis and its Relations with the Retinal Arteries, and with Syphilitic Arteritis of the Encephalon, xxi., 564

Panophthalmitis, Bacillus, xxi., 550; Enucleation in, Seventy Cases of, xv., 240; Enucleation in, xvi., 325; xviii., 213; Pathological Anatomy of, Schoebl, xx., 84; Treatment of, xix., 332
Papilla, Hyaline Bodies in the, xxi., 411
Paralgesia and Ophthalmoplegia, xxi., 573
Paralysis, Cocain and Passive Motion in Ocular, Spalding, xv., 492; Facial, Associated Movements in, xxi., 573; Sixfold, of Cerebral Nerves, Grossmann, xvii., 301
Paralytic, Advancement of Muscles, xvii., 378; Vertical Deviations of the Eye, xviii., 504
PARDEE, Glaucoma in a Man æt. 22 years, xvii., 214
Parent, Models of Mirrors for Opthalmoscopic Examination in the Erect Image, xxi., 420; Optometric and Phakometric Ophthalmoscope, xxi., 420
Parinaud, Ætiology of Convergent Strabismus, xxi., 438; General Considerations on Strabismus, xxi., 438; Prolapse of Iris in Simple Extraction, xxi., 558
PARK, Subjective Light-Sensations following Enucleation, xx., 343
Pathology, Diagnosis, and Therapeutics, Reports on, xv., 103, 347; xvi., 82, 220, 325, 448; xvii., 230, 364, 490; xviii., 212, 489; xix., 305, 503; xx., 130, 304, 418, 553; xxi., 113, 304, 418
Pauw, a Case of Acute Bilateral Atrophy of the Optic Nerves, xxi., 411
PERCIVAL, Action of Prismospheres and Decentred Lenses, xx., 193; Action and Uses of Prismatic Combinations, xxi., 430; Notes on Bifocal Lenses, xix., 255
Perimeter, a Handy, Schweigger, xviii., 187; Self-Registering, xvii., 492
Perles, Glioma of the Retina, xxi., 564
Peters, Case of Fracture of the Skull with Hemianopsia, xxi., 572; on the So-called Lachrymal Blennorrhœa of Infants, xxi., 436
Pfluger, Subconjunctival Injections of Trichloride of Iodine, xxi., 420
Phillipen, Note on a Case of Pulsating Exophthalmus in a New-born Child, xxi., 442
PHILLIPS, Living Larvæ in the Conjunctival Sac, xxi., 110
Phlyctenular, Diseases, xxi., 445
Physiology, Reports on, xv., 110, 221, 351; xvi., 91, 223, 331, 463; xvii., 100, 236, 371, 497; xviii, 217, 494; xix., 311., 507; xx., 146, 426, 557; xxi., 134, 308, 426
Pilocarpine as a Diagnostic Remedy, xvii., 119
PLANGE, Pigment Striæ in the Retina after Hemorrhage, xxi., 282
Platinum, Instruments made of, Gruening, xx., 264
PLEHN, Apparatus for the Determination of Refraction and Acuteness of Vision, xvii., 74
Plica Semilunaris, Advancement of the, Cullimore, xvii., 22

Pneumophthalmitis, xv., 247
POLLAK, Three Cases of Coloboma of the Iris, xx., 410
Polyencephalitis and Sleep, xxi., 572
Polypoid Granulations of Conjunctiva, xvii., 515
Pooley, Intraorbital Cyst, Probably of a Dermoid Nature, xxi., 442; Operation for Secondary Cataract with Subsequent Iridocyclitis and Glaucoma, xxi., 558
POPLAWSKA, Inflammation of the Eye after Injuries from Foreign Bodies, xxi., 22
Porywajew, Epibulbar Sarcoma, xxi., 450
PRENTICE, Metric System of Numbering and Measuring Prisms, xix., 64, 128; Prismometer, xx., 109
Prentice, *Dioptric Formulæ for Combined Cylindrical Lenses*, Review, xvii., 527; the Prismometric Scale, xxi., 420; *Treatise on Simple and Compound Ophthalmic Lenses*, Review, xvi., 368
Preston, Two Cases of Homonymous Hemianopsia, xxi., 572
Price, Persistent Hyaloid Artery, xxi., 424, 556
Prismatic Combinations, the Action and Use of, xxi., 420
Prism Dioptry *vs.* Centrad, xxi., 430
Prismometer, Prentice, xx., 109
Prismometric Scale, xxi., 420
Prisms, System of Numbering and Measuring, Prentice, xix., 64; Numeration of, xxi., 431; on the Numbering of, Landolt, xix., 497 Proposed Numbering of, Duane, xx., 321
Progressive Paralysis of the Eye-Muscles, xxi., 316
Proptosis, Use of Ice in, xv., 119
PRUDDEN, Adenoma of Caruncle, xv., 1
Ptosis, Operations for Cure of, xv., 115
Pupils, Graphic Movements of the, xv., 112; Inequality of, in Various Diseases, xvi., 365; Investigation, and Significance of the Symptoms of the, Heddæus, xviii., 189; State of, after Injuries to Head, xvi., 477; Symptoms of, after Injuries to Head, xvii., 249
PURTSCHER, Correction by Glasses of Anomalies in Cornea, xv., 264
Purtscher, on a New Form of Anterior Synechia Following Blunt Force, xxi., 548
PUSEY, Unusual Family History in Two Cases of Glaucoma, xxi., 360

Querenghi, Two Cases of Total Achromatopsia, xxi., 426
Quinine, Blindness, xviii., 108; Chemosis of Conjunctiva after Use of One Grain of, xxi., 259

Rabbit's Eye, Transplantation of, Bradford, xvi., 47, 182
Ramos, Errors of Refraction in Mexico, Compared with Those of Europe, xxi., 430
Randall, the Reformed Numeration of Prisms and the Centrad as a Unit, xxi., 431
RANDOLPH, a Valuable Experiment Bearing upon Sympathetic Ophthalmia with a Critical Review of the Subject, xxi., 367; Bilateral Glaucoma Simplex at the Age of 11, xvi., 185; Disseminate Choroiditis with preservation of sight, xviii., 438; Experimental pathogenesis of sympathetic ophthalmia, xvii., 188
Randolph, Hemorrhagic Glaucoma, with an Analysis of Three Cases, xxi., 553
Ranney, *Lectures on Nervous Diseases*, Review, xviii., 242
Ransohoff, Retinitis Pigmentosa, xxi., 564
Ray, Syphilitic Iritis, with Statistics, xxi., 549
Reading Machine, xv., 191
Recti, External Paralysis of, after Diphtheria, xxi., 439; Paralysis of External, after Diphtheria, xxi., 573

Reflex, Micropsia, from Hypertrophied Turbinates, xxi., 365; Pupillary Phenomenon, Due to Tænia, xxi., 570

Refraction, Apparatus for Determining, Plehn, xvii., 74; Determination of, with Illumination-Test, Schweigger, xviii., 443; Errors of, in Mexico Compared with Those in Europe, xxi., 430; Instrument for Testing the, Holden, xvi., 295; Normal, of Eye, xxi., 431; Statistics of, xxi., 430

Report of the Ophthalmological Session of the Spanish Medical Congress, 1891, xx., 583

Reports on the Progress of Ophthalmology, xv., 100, 211, 343; xvi., 77, 217, 322, 456; xvii., 95, 229, 364, 486; xviii., 96, 208, 330, 484; xix., 91, 303, 502; xx., 131, 271, 416, 552; xxi., 128, 316, 407, 548

Resection of Optic Nerve, and Enucleation, xxi., 568

Retina, Alterations in Vascular Walls of, xxi., 564; Anæsthesia of, xxi., 565; and Functional Disturbances, Reports on, xv., 130, 247, 380; xvi., 134, 240, 355, 486; xvii., 119, 253, 387; xviii., 194, 236, 354; xix., 100, 347, 526; xx., 283, 454, 575; xxi., 157, 407, 563; Angioid Streaks after Hemorrhage into the, xxi., 289; Cases of Perivasculitis of the, Sheffels, xx., 251; Curability of Detachment of the, xvii., 254; Detachment of, Recovery, xxi., 160, 407, 564; Embolism of Central Artery of the, Knapp, xv., 380; Wood, C. A., xix., 203; Embolism of Central Artery with Black Spot at the Macula, Inouye, xx., 259; Finer Anatomy of the, xix., 505; Formation of Dark Angioid Streaks in the, after Hemorrhage, Knapp, xxi., 289; Glioma of, xxi., 564; Glioma of, with History of Three Cases in one Family, xxi., 407; Hemorrhage of, Showing Scotoma, xxi., 408; Hemorrhagic Diseases of, xxi., 564; Hyperæsthesia of, Due to Urethral Stricture, Beaver, xv., 163; Ischæmia of, Ayres, xv., 4; Peculiar Case of Glioma of the, Hosch, xviii., 287; Pigmentation of, Peculiar Form of, xxi., 564; Pigment Striæ in the, after Hemorrhage, Plange, xxi., 282; Prolapse of, into Anterior Chamber, Berger, xvi., 26; Recovery from Detachment of the, Thompson, xix., 47; Temporary Anæmia of, and Subsequent Changes, xxi., 407

Retinæ Commotio, Symptomatology of, xxi., 564

Retinitis, Albuminurica and Pregnancy, xxi., 563; Albuminurica, Pathology of, Weeks, xvii, 276; Albuminurica, Recovery from, xix., 100; Diabetica, Friedenwald, xx., 544; Hæmorrhagica, with Hematemesis, xv., 248; Leukæmica, xvii., 120; Pigmentosa, xxi., 564; Syphilitica, and its Relations to Arteritis, xxi., 564

Retrobulbar Neuritis, xxi., 248; after the Use of Arsenic, xxi., 411

Reuling, Cyst of Iris destroyed with Galvano-Cautery, xvi., 210; Granuloma Sarcomatosum Corneæ of Seven Years' Standing, xvi., 210; Syphiloma at Sella Turcica, Causing Choked Disk and Ending Favorably, xvi., 210

Reviews of Books, xv., 395; xvi., 248, 368, 493; xvii., 527; xviii., 123, 244, 366, 515; xix., 359; xx., 468; xxi., 166, 326, 453

RHEINDORF, Extraction of Cataract, xvii., 437

Ried, Pocket Astigmometer, xxi., 420

Rindfleisch, Contributions to the Developmental History of Congenital Anomalies of the Eyes, xxi., 418

Ring Scotoma, xviii., 107

Risley, Incipient Cataract, Etiology, Treatment, and Prognosis, xxi., 557

RITTER, Foreign Bodies in the Cornea, xviii., 281

Roberts, Topographical Anatomy of the External Angle of the Eye, from the Point of View of Strabotomy, xxi., 438
Rodes, Spontaneous Extraction of a Cateractous Lens, xxi., 558
Roosa, *On the Determination of the Necessity of Wearing Glasses*, Review, xvi., 493
ROOSA, Two Hundred and Six Cases of Cataract Extraction, xx., 207
Rosmini, One Hundred and Nine Simple Extractions, xxi., 557
RUMSCHIEWITSCH, Sarcoma of the Cornea, xxi., 277
RYERSON, Pressure Inunction in Certain Chronic Hyperplastic Conditions of the Eye, xx., 550

SACHS, Anatomical and Clinical Contributions to the Knowledge of Central Scotoma in Affections of the Optic Nerve, xviii., 133; Traumatic Rupture of the Sclera, xx., 526
Saemisch, Communications from the Bonn Clinic, xxi., 568
Sajeschko, Clinical Contributions to the Question of Transplantation of Conjunctiva, xxi., 445
SALZMANN, a Contribution to the Study of the Tumors of the Lids, xx., 380
Salzmann, Observation of the Earlier Developmental Stages of a Subretinal Cysticercus, xxi., 570
Samelsohn, Metastatic Carcinoma of the Choroid, xxi., 550; on Anæsthesia Retinæ, xxi., 565
SANTOS FERNANDEZ, Europhen and Cantharidate of Soda in Ophthalmology, xxi., 73; Treatment of Granular Eyelids with Cantharidate of Potash, xx., 345
Sarcoma, Epibulbar, xxi., 450; of Uveal Tract, xxi., 550; Intraocular, at Central Region, Hill-Griffith, xvii., 139
SARGENT, Cocain in Glaucoma, xvi., 205; Profound Affection of the Eye in Pernicious Anæmia, xxi., 39
Sattler, A Case of Bacillus Panophthalmitis, xxi., 550
SAVAGE, Insufficiency of the Obliqui, xx., 105
Savage, the Harmonic Symmetrical Action of the Obliqui, in all Cases of Oblique Astigmatism. xxi., 430
Schantz, Injury to the Eye by Shot Wound, Recovery with Complete Vision, xxi., 412
SCHAPRINGER, Intraocular Hemorrhage from a Fall on the Occiput, xvi., 35
Schapringer, a Second Case of Vaccine Blepharitis, xxi., 434
SCHEFFELS, Traumatic Dialysis of the Retina, xx., 403
Schenk, Ice in Iritis, xxi., 549
SCHIELE, Co-excitation in the Regions of Homonymous Visual Fields, xvi., 317; Glycogen in the Cornea and Conjunctiva of Pathological Eyes, xviii., 457
SCHIÖTZ, Contribution to the Theory of Muscular Relations of the Eyes, xix., 157; High Degree of Astigmatism after Extraction Improved by Operation, xvii., 295; Lenticular Astigmatism after Iridectomy, xv., 200; Recording of Optometric Observations, xv., 203
Schirmer, on the Pathological Anatomy and Pathogenesis of Central Cataract, xxi., 557
Schmelew, on the Influence of Cocain in the Imbibition from the Conjunctival Sac into the Anterior Chamber, xxi., 426
SCHMIDT-RIMPLER, Cortical Hemianopsia, xix., 147; Glioma of the Pons, a Case Bearing on Choked Disk, xvii., 397
Schmidt-Rimpler, a Contribution to the Origin of Sympathetic Ophthalmia, xxi., 554; *Ophthalmology and Ophthalmoscopy*, Review, xviii., 367

SCHNABEL, Contributions to the Knowledge of Glaucoma, xvi., 1
SCHOEBL, Hyperplastic Inflammation of the Membranes of the Eye, xix., 390; Pathological Anatomy of Panophthalmitis, xx., 84
Schoeler, *Operative Treatment of Detachment of the Retina*, Review, xviii., 243
SCHOEN, Over-exertion of Accommodation, and Glaucoma, xvii., 33; the Cause of Senile Cataract, xviii., 322
School Children, Vision of, xxi., 430
SCHULTZE, Metastatic Carcinoma of Choroid, xix., 226
SCHWEIGGER, a Handy Perimeter, xviii., 187; Bilateral Homonymous Hemianopsia, xx., 83; Determination of Refraction with the Illumination Test, xviii., 443; Glaucoma and Affections of the Optic Nerve, xx., 475; Operations for Primary and Secondary Cataract, xvi., 253; Return to the Flap Operation, xvi., 447
Sclera, Recovery from Punctured Wound of the, Baxter, xx., 57; Traumatic Rupture of the, Sachs, xx., 526
Sclerosis, Disseminated, with Optic Atrophy, Zimmermann, xx., 329
Scotoma, Two Hundred and Fifty-Nine Cases of Central, xx., 461; Experimental, by Pressure on the Globe, Koller, xvii., 227; Scintillans, Pathology of, xxi., 565
Scott, Perchloride of Mercury in the Curative Treatment of Trachoma and other Conjunctival Diseases, xxi., 444
SEABROOK, Squint Statistics, xxi., 234
Seabrook, the Natural Course of Cataract, xxi., 558
Sedan, a Word on the Employment of Tincture of Iodine in Ulcers of the Cornea, xxi., 445
SEGGEL, on the Testing of the Light-sense and Color-sense, xviii., 247
Seggel, the Diseases of the Eye in Diabetes Mellitus, xxi., 572
Sella Turcica, Syphiloma at, Reuling, xvi., 210
Sgrosso, Contribution to the Casuistic of Osteoma of the Orbit, xxi., 442
Sharkey, on Graefe's Lid-Sign, xxi., 442
SHEFFELS, Case of Perivasculitis Retinæ, xx., 251
Shot-Wound, Injury to Eye by, xxi., 412
Siderosis of the Globe, xxi., 570
Sight, Loss of, after Injuries to Head and Back, xxi., 573
SILEX, Affections of Eye from Lightning Stroke, xvii., 333; the Accommodation of the Aphakial Eye, xviii., 274; Two Cases of Coloboma of the Macula Lutea, xviii., 86
Silex, Corneal Transplantation, xxi., 450
Simi, Alcohol and Tobacco Amblyopia, xxi., 408; Asepsis in Opthalmic Surgery, xxi., 420; Ophthalmia and the Spring, xxi., 414; the Tincture of Iodine in Infectious Ophthalmia, xxi., 449
SIMS, Papilloma of Conjunctiva, Encroaching on the Cornea, xxi., 91
Simulation of Visual Disturbances, Methods of Detection of, xxi., 408
Sinus, Abscess of the Frontal, xx., 158
Skiascopy, xxi., 420; Apparatus for Employing, Burnett, S. M., xix., 260
Skin- and Mucous-Grafting, Grossman, xvii., 299
SMITH, A. L., Lens-Centring Measurer, xx., 131, 266
Smith, Eugene, a New Method of Operating on Frog-Spawn-like Oculo-palpebral Folds, xxi., 445; How shall We Treat the Capsule? a New Cystitome Forceps, xxi., 558; Treatment of Irido-Dialysis from Contusions, Partial Iridenkleisis with or without Rupture, xxi., 548

SMITH, W. F., Diffuse Hyperostosis of the Greater Wing of the Sphenoid, xvii., 9; Mucous Grafts from Mouth to Eye, xvii., 430; Operation for Distichiasis, xvi., 177; Singular Case of Injury, xix., 142; Transplantation of Rabbit's Eye, xix., 136.

Snell, Case of Nystagmus in a Compositor, xxi., 439; Immediate Loss of Sight after Injuries to Head and Back, xxi., 573; on Miner's Nystagmus, xxi., 439

Snellen, Skiascopy, xxi., 420

Soda, Cantharidate of, in Ophthalmology, xxi., 73

SPALDING, Cocain and Passive motion in Ocular Paralysis, xv., 492; Idiopathic Vitreous Hemorrhages, xxi., 220

SPEAKMAN, Javal's New Ophthalmometer, xix., 76

Specht, a Critical Review of the Methods for Detecting Simulation or Aggravation of Visual Disturbances, xxi., 408

Spender, on Points of Affinity between Rheumatoid Arthritis, Locomotor Ataxy, and Exophthalmic Goitre, xxi., 415

Sphenoid Diseases, and Those of the Eye, xvi., 107; Hyperostosis of the, Smith, W. F., xvii., 9

Spherical Lenses, Effect of Tilted, on Vision, Jones, xxi., 301

Spierer, Recovery from Hemiamblyopia Due to Fright, xxi., 408; Kerato-Malacia of the Left and Neuro-Retinitis of the Right Eye in Course of a Meningitis, xxi., 414

Spring, Ophthalmia in the, xxi., 414

Squint, Statistics of, xxi., 234

Staderini, on the Exits of the Aqueous, xxi., 426

Staining Methods, xvii., 235

Starkey, an Experimental Study of the Comparative Mydriatic Effect of Atropia and Homatropia, xxi., 431

Statistical Papers, xv., 101, 212, 345; xvi., 80, 219, 323, 457; xvii., 96, 230, 364, 487; xviii., 210, 331, 485; xix., 304

Stephenson, a Peculiar Form of Retinal Pigmentation, xxi., 564

Stereoscope, xvii., 507

STEVENS, Anomalies of the Ocular Muscles, xvi., 149; xvii., 155; xviii., 371; xx., 356

STILLING, On the Origin of Strabismus, xv., 270; on the Study of Myopia, xv., 296; the Pathogenesis of Glaucoma, xvi., 440

Stilling, on the Experimental Production of Exophthalmus, xxi., 418

Story, Detachment of the Choroid, xxi., 550; Temporal Hemianopsia of Left and Blindness of Right Eye, xxi., 572; the Ophthalmometer in Practice, xxi., 420

St. Petersburg Eye Hospital, Notes, xviii., 210

Strabismometry, Objective, Maddox, xxi., 56

Strabismus, Ætiology of Convergent, xxi., 438; Case of Convergent, with Myopia, Theobald, xv., 191; Cases of Muscular Advancement, xxi., 438; Convergens, with Crossed Diplopia, Osborne, xx., 66; General Considerations on, xxi., 438; Is the Position of Rest the Cause of? Gardiner, xvi., 39; Operative Treatment of, xxi., 43; Origin of, Stilling, xv., 270; Statistics of, Seabrook, xxi., 234; Suppuration following Operation for, Knapp, xv., 436

Strassburg, Notes of Ophthalmological Discussions of Meeting at, xv., 93

Straub, Case of Corneal Fistula and Traumatic Astigmatism Cured by Operation, xxi., 452

Subconjunctival Injections, of Sublimate, xxi., 419; of Trichloride of Iodine, xxi., 420; Therapeutic Value of, xxi., 420

Sulzer, the Form of the Human Cornea and its Influence on Vision, xxi., 426

Surgery, Contribution to, xxi., 415
Swanzy and Werner, a Case of Double Hemianopsia, xxi., 572
Sym, Albinism, a Curious Family History, xxi., 418
Symblepharon, Partial, of Lower Lid, Grossmann, xvii., 300
Sympathetic, Blindness, Permanently Cured, xxi., 554 ; Ophthalmia, xxi., 554 ; Ophthalmia after Removal of a Corneal Staphyloma, xviii., 349 ; Ophthalmia, an Experiment Bearing upon, xxi., 367 ; Ophthalmia, Cases of, xvii., 385 ; Ophthalmia, Causation of, Gifford, xv., 281 ; Ophthalmia, Cure of a Case of, xvi., 128 ; Ophthalmia, Despite Resection of Optic Nerve, xxi., 323, 554 ; Ophthalmia, Experimental Pathogenesis of, Randolph, xvii., 188 ; Ophthalmia, Origin of, xxi., 554 ; Ophthalmia, Pathogenesis of, xviii., 213 ; Ophthalmia, Reports on, xv., 126, 243, 375 ; xvi., 227, 238, 350, 480 ; xvii., 250, 385 ; xviii., 99, 230, 349 ; xix., 338, 523 ; xx., 280, 448, 572 ; xxi., 155, 323, 554
Synchronous Movements of Upper Lid and Lower Jaw, xxi., 354
Synechia, Anterior, Following Blunt Force, xxi.. 548
Synergetic Ocular Movements, xxi., 342
Syphilis of the Brain, xix., 531
Syphilitic Diseases of Eye, xvi., 137, 145, 246, 323

Tabes, Ætiology of, xxi., 572 ; Visual Disturbances in, Berger, xix., 429
TANGEMANN, Cholesterin in the Eyes, xvii., 447 ; Keratitis Bullosa, xvii., 92 ; Persistent Hyaloid Artery, xvii., 270
TAYLOR, L. H., Foreign Body Driven through Nose into Orbit, xv., 262
Tears, Blood-Stained, xxi., 436
Tenon's Capsule, Advancement of, xvi., 230 ; Anatomy of, xv., 108 ; xvi., 90
Terson, Report on the Treatment of Affections of the Lachrymal Passages, xxi., 436
Test-Type Critically Considered, xvi., 87
Text-Books, Monographs, etc., Reports on, xv., 395 ; xvi., 79 ; xvii., 95, 229, 364, 486 ; xviii., 208, 330, 484 ; xix., 303, 502 ; xx., 136, 416, 552 ; xxi., 128, 303
THEOBALD, Convergent Squint with Myopia, xv., 191
Theodor (Carl), Duke of Bavaria, a Case of Cornu Cutaneum of the Right Superior Eyelid, xxi., 434
Therapeutics, Reports on. *See* Pathology, etc.
Thompson, a Case of Retinal Hemorrhage Showing Scotoma, Embolism of a Branch of Retinal Artery, xxi., 408 ; Miner's Nystagmus among the South Wales Colliers, xxi., 439 ; Monocular Diplopia, xxi., 573 ; Note on Förster's Artificial Ripening of Cataract, xxi., 558
THOMPSON, J. H., Fatal Result of Enucleation, xxi., 63; Recovery from Detachment of the Retina, xix., 47
Thompson, J. T., Emphysema of the Conjunctiva, xxi., 445
Tobacco Scotoma, xviii., 107
Trachoma, a New Treatment for Chronic, Johnson, xix., 264 ; and its Treatment, xxi., 445 ; Blue Stone and Silver in, xxi., 148 ; Case of Pseudo-, xxi., 505 ; Excision of Retro-Tarsal Fold, in, xv., 147 ; Iodine of Silver in Treatment of, xxi., 444 ; Lectures on, xv., 365 ; Operations for, xvii., 517 ; xxi., 151 ; Pathology and Ætiology of, xxi., 445 ; Papers, xvii., 110, 381 ; Recent Views on Pathology of, xxi., 445 ; Treatment of, xxi., 113 ; Treatment of Chronic, xx., 270 ; Treatment of, in 1892, Jaesche, xxi., 113 ; Treatment of, with Roller-Forceps, Knapp, xxi., 119

Transplantation, Experiments on, xvii., 231; of Eyes, xv., 104, 215, 226; xvii., 257; Operations for, xxi., 140; of Rabbit's Eye, xvi., 83; Smith, W. F., xix., 136
TREITEL, Removal of Cysticercus from Eye, xix., 207
Trichiasis, Operations for, xix., 411
Trousseau, Concerning Resection of the Optic Nerve, xxi., 568; Fluxion of the Lachrymal Gland, xxi., 436
Tuberculin in Eye Diseases, xxi., 306
Tuberculosis, Contribution to Question of, xxi., 550; of Cornea, xvii., 247; of Choroid, etc., xxi., 550; of Eye, Neese, xvi., 434; Weakened, of Eye, xxi., 550
Tuberculous and Gliomatous Diseases, Differential Diagnosis of, xxi., 418
Tumor of Optic Nerve Removed, with Preservation of Eye, Ole Bull, xxi., 354

Uhthoff, Examination of the Visual Learning of a Child of Seven, Born Blind, but Successfully Operated, xxi., 557; on the Doctrine of the Metastatic Carcinomata of the Choroid, xxi., 550
Ulcer, Rodent, of Lids, xxi., 434
Ulcers of Cornea, Iodine in, xxi., 445
ULRICH, Choked Disk and Œdema of the Optic Nerve Trunk, xviii., 53, 71

Vaccine Blepharitis, Zimmermann, xxi., 215
Vacher, Treatment of Progressive Myopia and Prophylaxis of Detachment of the Retina, by Extraction of the Transparent Lens, xxi., 430
Valk, *Lectures on the Errors of Refraction, and their Correction with Glasses*, Review, xviii., 124
Valude, Anatomy of the Chronic Inflammations of the Conjunctiva, xxi., 444; Epithelioma of the Inner Angle of the Eyelids, xxi., 434; of the Sclero-Corneal Limbus, xxi., 449; Prophylaxis of the Ophthalmia of the New-Born by the Use of Pulverized Iodoform, xxi., 444
Van Duyse, Persistence of Cloquet's Canal, Remains of the Fœtal Hyaloid System, Coloboma of Optic Nerve, xxi., 554
Van Fleet, Retinitis Albuminurica and Pregnancy, xxi., 563; the Normal Refraction of the Eye, xxi., 431
Vaurelle, Contribution to the Study of the Ætiology of Epidemic Hemeralopia, and of its Relations to Scurvy, xxi., 564
VILAS, a Case of Glaucoma in a Child, xvii., 427
Vision, Apparatus for Determining Acuteness of the, Plehn, xvii., 74; Curious Case of, xxi., 573; of Railway Servants, Discussion on, xxi., 420
Visual, Acuity, Examination of, after Extraction, xxi., 558; Centres, xx., 144; Education of Child Born Blind, and Successfully Operated, xxi., 557; Field, Alterations of, in Functional Nervous Disturbances, etc., xxi., 565; Field, Determination of Meridians of the, Knapp, xv., 297; Field, in Epileptics and the Feeble-Minded, xxi., 572; Field, Typical Defects of, in Functional Nervous Disturbances, xxi., 408
Vitreous, Cases of Artificial, Morgan, xx., 32; Idiopathic Hemorrhages into, xxi., 220; Reports, on Diseases of the, xv., 130, 247, 379; xvi., 133, 354, 486; xvii., 118, 253, 487; xviii., 104, 235, 354; xix., 99, 346, 526; xx., 283, 454; xxi., 155, 323, 556

Wagenmann, on the Occurrence of Giant Cells and Purulent Exudation in the Region of an Intraocu-

Wagenmann—*continued.*
lar Cysticercus, xxi., 570; Pathological Anatomy of Retinitis Pigmentosa, xxi., 564
Wagner, on the Question of the Curability of Glaucoma, xxi., 553; Rodent Ulcer of the Eyelids, xxi., 434; the Operation of Entropium, xxi., 434
WEBSTER, a Case of Sarcoma of the Iris, xviii., 15; Death from Meningitis after an Extraction with Panophthalmitis, xvii., 25; Death after Cataract Extraction, xviii., 449; Sarcoma of Choroid with Metastatic Infiltration of Optic Nerve, xvii., 29
Webster, a Case of Choked Disk with Unimpaired Vision, xxi., 568
WEBSTER and HOLDEN, a Case of Sarcoma of the Choroid and Ciliary Body, xxi., 528
Wecker and Masselon, *Text-Book of Ophthalmology*, Review, xviii., 336
WEEKS, Albuminuric Retinitis, xvii., 276; Bacillus of Acute Conjunctival Catarrh, xv., 441; Bacteriological Investigation of the Antiseptics used in Ophthalmology, xvi., 375; Epibulbar Echinococcus, xviii., 31; Injuries of Eyes; with Microscopical Appearances, xv., 85; Lenticonus Posterior, xx., 260; Lid Transplantation without a Pedicled Flap, xviii., 92; two Cases of Hemianopsia with Agraphia, Amnesic Aphasia, and Associated Symptoms, xx., 392; Xerosis of Conjunctiva in Infants, xv., 332
Weeks, La Grippe as a Cause of Retrobulbar Neuritis, and Other Ocular lesions, xxi., 568; Surgical Treatment of Granular Lids, xxi., 445
WEISS, Sharp-Cut Ectasia at the Posterior Pole in High-Grade Myopia, xxi., 511
Wherry, a Case of Paralgesia and Ophthalmoplegia, xxi., 573
WHITE, Remarks on Immature Cataract and the Best Method of Hastening Maturity, xxi., 516
WHITING, Case of Primary Sarcoma of the Iris with Formation of Bone in the Choroid, xix., 361
Wilbrand, on Typical Defects of the Visual Field in Functional Disturbances of the Nervous System, xxi., 408; on Alterations in the Visual Field in Functional Disturbances of the Nervous System, and on the Oscillating Visual Field, xxi., 565
Williams, R., a Case of Arterio-Venous Anastomosis Communication in the Orbit, xxi., 442; a Case of Horizontal Hemianopsia, xxi., 572; a Case of Alexia, xxi., 572; Modification of the Ordinary Operation for the Advancement of the Tendon of the Recti Muscles, xxi., 439
Williams, E., Obituary Notice of, xvii., 532
Wilmer, a New Lachrymal Drill, xxi., 436
WING, a Case of Pulsating Exophthalmus, xx., 548
Wilson, H., Hereditary Congenital Cataract, xxi., 557
WOOD, C. A., Embolism of Superior Branch of Retinal Artery, xix., 203
Wood, Electro-Magnetic Extraction of Piece of Steel from the Vitreous Chamber of the Eye, xxi., 412; Mixture of Homatropine and Cocain as a Substitute for Atropine and Duboisine in the Determination of Refractive Errors, xxi., 420
Wood, T. H., Ossification of Choroid, xxi., 550
Woods, Optic Neuritis after the Measles and Intermittent Fever, xxi., 95
WOODWARD, Fifty-four Cases of Cataract Extraction, xxi., 398
Wounds, Penetrating, of Eye, xxi., 457

Wray, Points in the Treatment of Lamellar Cataract, xxi., 557; Suggested Technique to Prevent Strain on the Supra- and Infra-Corneal Sutures, during the Re-attachment of the Advanced Muscles, xxi., 438

Wuerdemann, a Simple Skiascope, xxi., 420; Fibrosarcoma of the Neck with Temporary Ophthalmoplegia Externa and Sympathetic Paralysis, xxi., 439

Yellow Glasses in Photophobia, xvii., 101

Xanthopsia, Contribution to our Knowledge of, Hilbert, xv., 196

Xerosis, Various Papers on, xxi., 148

ZIMMERMANN, Disseminated Sclerosis, with Bilateral Optic Atrophy, xx., 329; Vaccine Blepharitis, xxi., 215

Zonula of Zinn, Development and Abnormalities of, xxi., 424

Fig. 1.

Fig. 2.



Fig. 3.

Dr. Greeff, Berlin, phot. Photogravure u. Druck H. Riffarth, Berlin.

Verlag v. J. F. Bergmann, Wiesbaden.

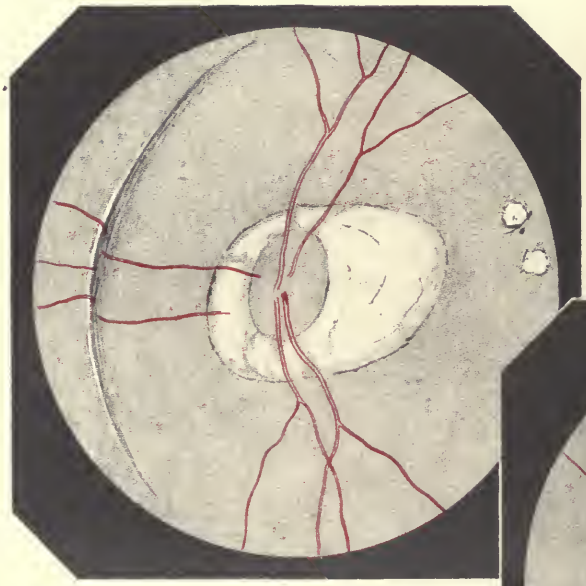

Fig. 1.

Fig. 4.

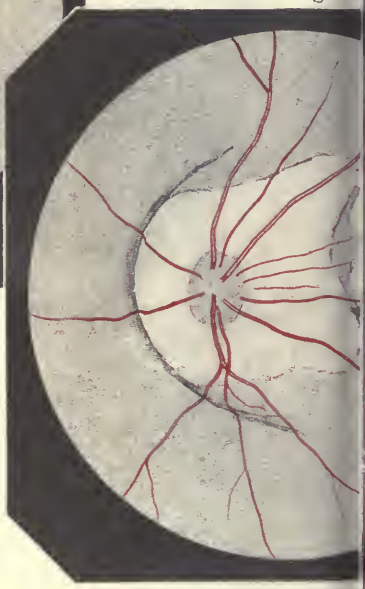

Fig. 3.

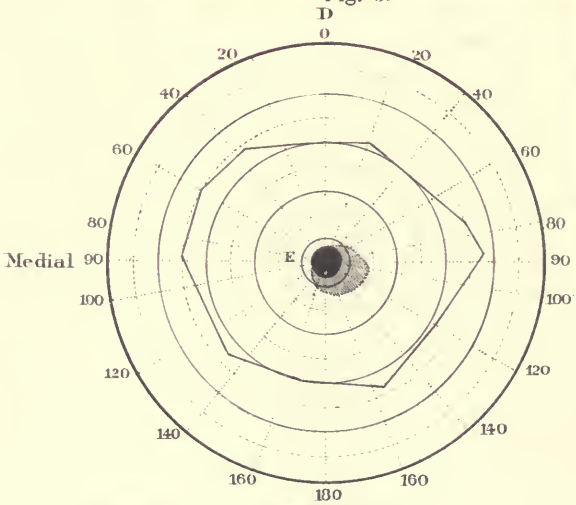

VERLAG VON J. F. BERGMANN IN WIESBADEN.

Taf. VIII.

Fig. 2

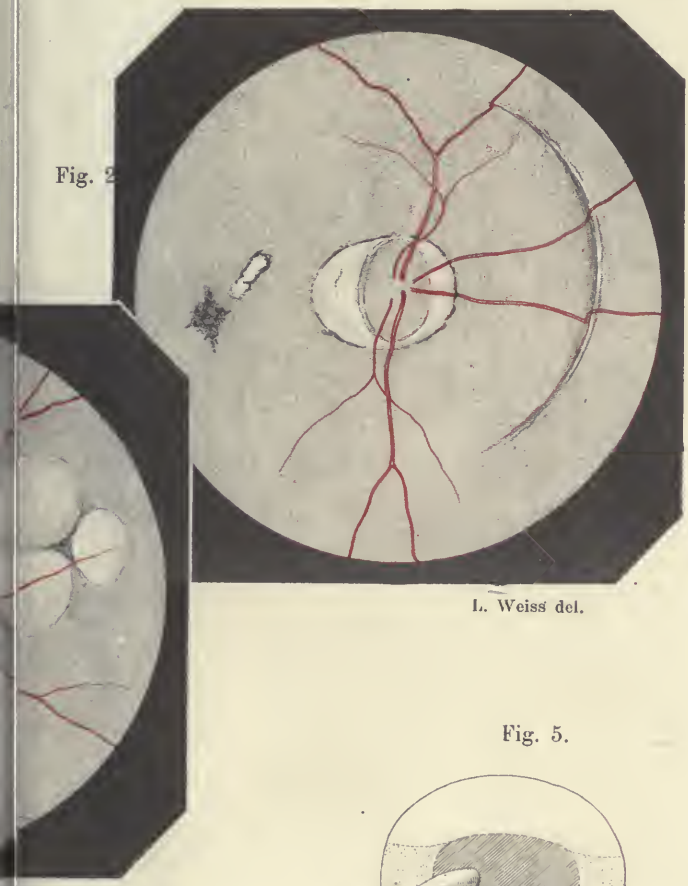

L. Weiss del.

Fig. 5.

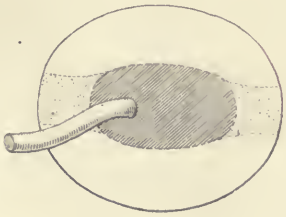

UNDE XXIII.

KGL. UNIVERSITÄTSDRUCKEREI VON H. STÜRTZ IN WÜRZBURG.

L
a.c.
c.m.
c.h.
v.v.

X

RE
1
A74
v.21

Biological
& Medical
Serials

Archives of ophthalmology

PLEASE DO NOT REMOVE
CARDS OR SLIPS FROM THIS POCKET

UNIVERSITY OF TORONTO LIBRARY

STORAGE